

Deep Vein Thrombosis in Upper Limb in a Weightlifter

Montserrat Pérez Pinar, Regina Pastor Toledo, Luis Broseta Viana, Julián Solís García del Pozo*

General Hospital of Villarrobledo, Villarrobledo (Albacete), Spain

Abstract

AIM: We report an unusual case of a male weightlifter with upper extremity venous thrombosis.

CASE PRESENTATION: Thrombosis affecting subclavian-axillo-humeral venous trunk produced by the compression of these veins by the trained muscles of the shoulder girdle (Paget-Schroetter syndrome) has been reported. During the study, a renal carcinoma was detected. Renal carcinoma has rarely been associated with thrombosis in the upper extremities.

CONCLUSION: This case shows the importance of performing a complete study to rule out malignancies in patients with unusual venous thromboembolism.

Citation: Pérez Pinar M, Pastor Toledo R, Broseta Viana L, Solís García del Pozo J. Deep Vein Thrombosis in Upper Limb in a Weightlifter. Open Access Maced J Med Sci. 2017 Apr 15; 5(2):228-230. <https://doi.org/10.3889/oamjms.2017.027>

Keywords: Upper extremity deep vein thrombosis; Renal carcinoma; Paget-Schroetter.

***Correspondence:** Julián Solís García del Pozo, General Hospital of Villarrobledo, Villarrobledo (Albacete), Spain. E-mail: julianeloysois@gmail.com

Received: 09-Dec-2016; **Revised:** 20-Dec-2016; **Accepted:** 07-Feb-2017; **Online first:** 06-Mar-2017

Copyright: © 2017 Montserrat Pérez Pinar, Regina Pastor Toledo, Luis Broseta Viana, Julián Solís García del Pozo. This is an open-access article distributed under the terms of the Creative Commons Attribution-NonCommercial 4.0 International License (CC BY-NC 4.0).

Funding: This research did not receive any financial support.

Competing Interests: The authors have declared that no competing interests exist.

Introduction

Deep vein thrombosis (DVT) of the upper extremities is an unusual finding, which appears only in 5% of cases of the venous thromboembolic disease. The aetiology of these thromboses can be classified into primary causes when it is located in the area of thrombosis, or secondary causes.

The Paget-Schroetter syndrome has been described as a primary cause of upper extremity DVT. This disorder is a thrombosis affecting subclavian-axillo-humeral venous trunk produced by the compression of these veins by the trained muscles of the shoulder girdle [1, 2].

The most common cause of secondary upper limb DVT is the use of subclavian venous catheters [1]. Other secondary causes include malignancies, mainly adenocarcinomas. 30% of cases of upper extremity DVT are secondary to malignancy. On the other hand, 15% of patients with neoplasia will undergo an episode of venous thromboembolism which only rarely affects the upper extremities.

Appropriate diagnosis requires the performance of venous doppler ultrasound. A computed tomography (CT) scan may be needed to rule out other causes of compression or confirm the diagnosis in cases of high suspicion despite a normal doppler ultrasound. Anticoagulant drugs are required for treatment, and clinical follow-up should last at least one year [3].

We report an unusual case of a young patient with upper extremity venous thrombosis in which the cause could be both primary and secondary.

Case Description

We present a 47-year-old patient with a history of intensive care unit admission in 2010 secondary to influenza with severe respiratory failure and pneumonia with septic shock.

In the current episode, the patient comes to

the hospital with pain and oedema in the left upper extremity during the previous five days. He had no chest pain, dyspnea, weight loss or other symptoms. He reported doing daily physical exercise. In the morning he ran on the treadmill, and in the evenings he practised weightlifting.

In initial laboratory tests, a D-dimer of 1220 mcg/L was detected. A venous Doppler ultrasound was performed, and signs of DVT in the left upper limb affecting axillary vein (Fig. 1), subclavian, and probably affecting brachiocephalic trunk were observed. A superficial thrombophlebitis of basilica vein was also detected.

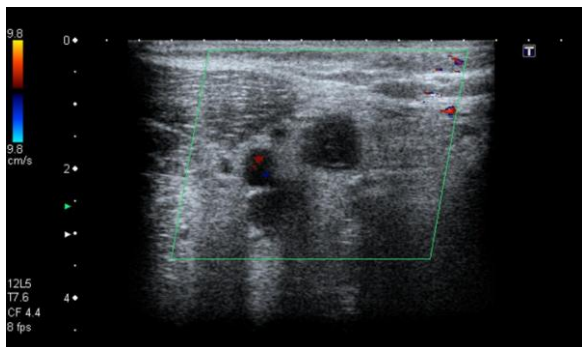


Figure 1: Doppler ultrasound showing left axillary vein thrombosis

Determinations of factor VIII, factor XII, protein C, protein S, cardiolipin and homocysteine were normal. Detection of mutations in prothrombin gene, factor V Leiden and JAK-2 were also negative. Lupus anticoagulant was weakly positive. The patient was treated with low molecular weight heparin.

A chest CT showed multiple bilateral hilar lymphadenopathies. The spleen had multiple focal non-specific lesions. These findings suggested a differential diagnosis between the lymphoproliferative syndrome and sarcoidosis. An abdominal computed tomography scan was performed also showing a right renal cortical cystic mass grade 4 in Bosniak classification (Fig. 2).

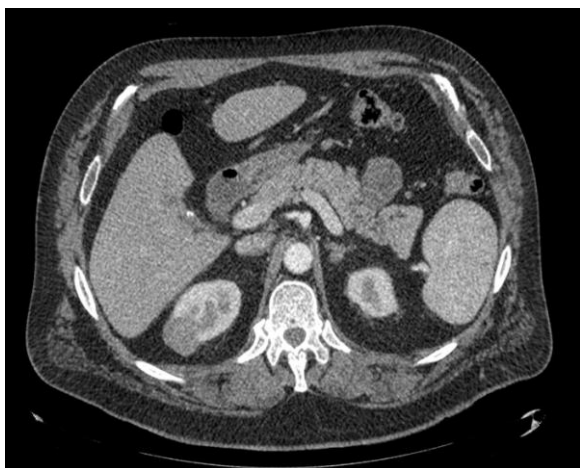


Figure 2: CT scan showing right renal cortical cystic mass grade 4 in Bosniak classification

A bronchoscopy and a biopsy in the left main bronchus that showed no relevant alterations were performed. A slight decrease in CD4 percentage (35.5%) and normal CD8 percentage (25.74%) with a decreased ratio CD4/CD8 were detected. The angiotensin converting enzyme serum level was normal. A Positron Emission Tomography - Computed Tomography (PET/CT) did not show data compatible with malignant pathology or inflammatory process. Therefore, the diagnoses of lymphoproliferative syndrome or sarcoidosis were discarded. An abdominal magnetic resonance imaging (MRI) confirms the diagnostic of renal cystic mass grade 4 of the Bosniak classification. A partial right nephrectomy was performed. The anatomopathological study of the surgical specimen gives the diagnosis of papillary renal carcinoma type 2, grade 2-3 of Fuhrman classification. The clinical course of the patient has been favourable after two years of follow-up.

Discussion

We present the case of a young male weightlifter, who had suffered a DVT in the upper extremity. Although Paget-Schroetter syndrome has been reported as the cause of this unusual location of DVT [4, 5], in this patient the results of CT scan posed other possible diagnoses such as lymphoproliferative disorder, sarcoidosis or renal neoplasia, as predisposing factors to suffer venous thromboembolic disease. Sarcoidosis has been reported by other authors as a predisposing condition of thrombosis [6, 7]. The study ruled out this disease and a lymphoproliferative disorder, concluding that the lesions observed in CT scan should be residual after their previous admission due to sepsis and influenza pneumonia.

The patient was diagnosed with renal carcinoma treated with surgery. Although renal cell carcinoma has been associated with venous thrombotic events and thrombosis of vena cava [8, 9], it has rarely been associated with thrombosis in the upper extremities. A PubMed search using the terms "(upper limb OR upper extremity) AND thrombosis AND renal carcinoma" only yield one case with this association [10].

The Paget-Schroetter syndrome relates the development of shoulder girdle muscles due to physical training with the compression of the venous drainage of the upper limb and subsequently the production of venous thrombosis at this level. There are clinical cases published reporting upper limb DVT in sports players who use such extremities, such as those practising baseball, basketball, lacrosse, golf, canoeing or weight lifters [1, 2, 4, 5, 11].

Therefore, it is difficult to conclude whether

the main cause of DVT in our patient has been neoplasia, weightlifting or both. The practice of weightlifting alone could have explained the patient clinical picture. However, this case shows the importance of performing a complete study to rule out malignancies in patients with unusual venous thromboembolism.

References

1. Rosa Salazar V, Otálora Valderrama Sdel P, Hernández Contreras ME, García Pérez B, Arroyo Tristán Adel A, García Méndez Mdel M. Multidisciplinary management of Paget-Schroetter syndrome. A case series of eight patients. Arch Bronconeumol. 2015;51(8):e41-3. <https://doi.org/10.1016/j.arbr.2015.05.026>
2. Moreno C, Torres JA, Ingelmo A. Síndrome de Paget-Schroetter (trombosis de esfuerzo). A propósito de un caso. Archivos de Medicina del Deporte. 2007; 24: 141-3.
3. Kearon C, Akl EA, Ornelas J, et al. Antithrombotic Therapy for VTE Disease: CHEST Guideline and Expert Panel Report. Chest. 2016; 149(2):315-52. <https://doi.org/10.1016/j.chest.2015.11.026> PMID:26867832
4. DeLisa LC, Hensley CP, Jackson S. Diagnosis of Paget-Schroetter Syndrome/Primary Effort Thrombosis in a Recreational Weight Lifter. Phys Ther. 2016. <https://doi.org/10.2522/ptj.20150692> PMID:27587803
5. Shennib H, Hickie K, Bowles B. Axillary vein thrombosis induced by an increasingly popular oscillating dumbbell exercise device: a case report. J Cardiothorac Surg. 2015; 10: 73. <https://doi.org/10.1186/s13019-015-0264-3> PMID:25986625 PMCid:PMC4446062
6. Rebeitz TJ, Mahfouz R, Taher A, Charafeddine Kh, Kanj N. Unusual presentation of a sarcoid patient: multiple arterial and venous thrombosis with chest lymphadenopathy. J Thromb Thrombolysis. 2009;28:245-7. <https://doi.org/10.1007/s11239-008-0270-6> PMID:18792762
7. Vahid B, Wildemore B, Marik PE. Multiple venous thrombosis in a Young man with sarcoidosis: is there a relation between sarcoidosis and venous thrombosis? South Med J. 2006;99:998-9. <https://doi.org/10.1097/01.smj.0000233188.45688.41> PMID:17004536
8. Farge-Bancel D, Bounameaux H, Brenner B, et al. Implementing thrombosis guidelines in cancer patients: A review. Rambam Maimonides Med J. 2014; 5: e0041. <https://doi.org/10.5041/RMMJ.10175> PMID:25386357 PMCid:PMC4222430
9. Haddad AQ, Leibovich BC, Abel EJ, et al. Preoperative multivariable prognostic models for prediction of survival and major complications following surgical resection of renal cell carcinoma with suprahepatic caval tumor thrombus. Urol Oncol. 2015;33: 388. e1-9.
10. Harewood GC, Gupta D, Litin SC. 64-year-old man with venous thrombosis and abnormal liver enzymes. Mayo Clin Proc. 1999;74:285-8. <https://doi.org/10.4065/74.3.285> PMID:10089999
11. Ilhan E, Ture M, Yilmaz C, Arslan M. Subclavian Vein Thrombosis Extending into the Internal Jugular Vein: Paget-von Schroetter Syndrome. J Clin Med Res. 2009; 1:178-80. <https://doi.org/10.4021/iocmr2009.07.1248>