

Prognostic Value of Vascular Endothelial Growth Factor A in the Prediction of the Tumor Aggressiveness in Clear Cell Renal Cell Carcinoma

Fahredin Veselaj¹, Suzana Manxhuka-Kerliu², Arber Neziri¹, Labinot Shahini², Shefki Xharra³, Liridon Selmani¹, Lloreta Kerliu⁴, Floren Kavaja^{5*}

¹Clinic of Urology, UCC of Kosovo, Prishtina, Kosovo; ²Department of Pathology, UCC of Kosovo, Prishtina, Kosovo; ³Regional Hospital, Prizren, Kosovo; ⁴Massachusetts College of Pharmacy and Health Sciences (MCPHS), 179 Longwood Avenue, Boston, MA 02115, USA; ⁵Clinic of Surgery, UCC of Kosovo, Prishtina, Kosovo

Abstract

Citation: Veselaj F, Manxhuka-Kerliu S, Neziri A, Shahini L, Xharra S, Selmani L, Kerliu L, Kavaja F. Prognostic Value of Vascular Endothelial Growth Factor A in the Prediction of the Tumor Aggressiveness in Clear Cell Renal Cell Carcinoma. Open Access Maced J Med Sci. 2017 Apr 15; 5(2):167-172. https://doi.org/10.3889/oamjms.2017.035

Keywords: Clear cell RCC; Angiogenesis; VEGF-A; prognostic factors.

***Correspondence:** Floren Kavaja. Clinic of Surgery, UCC of Kosovo, Prishtina, Kosovo. E-mail: fkavaja@hotmail.com

Received: 09-Feb-2017; **Revised:** 10-Mar-2017; **Accepted:** 12-Mar-2017; **Online first:** 10-Apr-2017

Copyright: © 2017 Fahredin Veselaj, Suzana Manxhuka-Kerliu, Arber Neziri, Labinot Shahini, Shefki Xharra, Liridon Selmani, Lloreta Kerliu, Floren Kavaja. This is an open-access article distributed under the terms of the Creative Commons Attribution-NonCommercial 4.0 International License (CC BY-NC 4.0).

Funding: This research did not receive any financial support.

Competing Interests: The authors have declared that no competing interests exist.

BACKGROUND: Clear cell renal cell carcinoma (CCRCC) is the most predominant renal tumour with unpredictable tumour behaviour. The aim of the study is to investigate the prognostic value of vascular endothelial growth factor A (VEGF-A) expression in CCRCC and to correlate it with other histological parameters as well as with patient's survival.

MATERIAL AND METHODS: Tumour blocks were taken from 40 patients with histopathology diagnosis of CCRCC and tissue block from 20 normal kidneys as a control group were examined using the immunohistochemical staining for VEGF-A.

RESULTS: The VEGF A expression in CCRCC was significantly higher than in the normal kidney tissues ($U' = 720, P < 0.0001$). VEGF A expression values in CCRCC were positively correlated with Disease Free Survival ($r = 0.335, P = 0.034$) and the tumor necrosis degree ($r = 0.181, P = 0.262$). VEGF-A expression values in CCRCC did not correlate with CD 31 expression ($r = -0.09, P = 0.549$), and Progression Free Survival ($r = -0.07, P = 0.838$). VEGF A expression values in CCRCC were negatively correlated with the tumor nuclear grade ($r = -0.161, P = 0.318$); the pathological tumor stage ($r = -0.371, P = 0.018$); the tumor size ($r = -0.361, P = 0.022$); the degree of tumor hemorrhage ($r = -0.235, P = 0.143$); and Cancer Specific Survival ($r = -0.207, P = 0.713$).

CONCLUSIONS: VEGF-A expression can be used to stratify advanced and metastatic CCRCC patients into low-benefit and high-benefit groups. Based on this study outcome it would be useful to perform IHC staining for VEGF-A expression in all patients with advanced and metastatic CCRCC.

Introduction

Renal cell carcinomas (RCCs) are the seventh most common histological type of cancer in the Western world and have maintained an increasing prevalence, representing 1% to 3% of all malignant visceral neoplasms [1]. The mortality incidence ratio is higher in RCC than in other urological malignancies [2]. RCC has been reported to be resistant to radiation or chemotherapy, and the prognosis for these patients remains poor [3]. Histopathological evaluations of RCC have revealed that highly vascularized neoplasm is demonstrating clear evidence of abundant angiogenesis and abnormal blood vessel

development [4]. This notion has thus raised considerable concerns regarding the development of anti-angiogenic suppressive therapies for RCC. Until now, many angiogenic molecules have been identified [5]. Vascular endothelial growth factor (VEGF) is a potent endothelial cell mitogen and is an important component of the angiogenic stimulus in a range of human neoplasias [6]. VEGF is a multifunctional cytokine that can increase microvascular permeability [7] and stimulate endothelial cell growth and angiogenesis [8]. Several factors can influence VEGF expression, including hypoxia [9] and transform growth factor- β [10]. Once VEGF binds to VEGF receptors, receptor dimerization and autophosphorylation are induced and downstream signalling via

several secondary messengers, including several protein kinases and phosphatases, are activated. This supports a proangiogenic phenotype [11].

The aim of the study is to investigate the prognostic value of VEGF-A expression in Clear cell renal cell carcinoma (CCRCC) and to correlate it with other histological parameters as well as with patient's survival rate.

Materials and Methods

Patients

The study included a total of 40 patients with histopathologically verified RCC after surgery in the period between January 2008 and July 2014. Before surgery, all patients signed an informed consent form. This research was approved by the ethics committee at the Medical Faculty - Prishtina University. There were 19 men and 21 women, with a median age of 60.3 years (range 36 – 81 years). Among 40 patients, 32 patients undergone nephrectomy, seven partial nephrectomies (NSS), and one bilateral radical nephrectomy due to bilateral RCC. None of the patients had been treated with radiation, chemotherapy, or immunotherapy before surgery. Most of the patients were followed-up using clinical and radiological examinations at regular intervals. Survival was determined from the nephrectomy time to the latest follow-up. At the latest follow-up, 33 patients were alive with a median follow-up time of 26 months, (range 2 – 72 months), 6 of them died of RCC with a median survival rate of 9 months (range 2 – 24 months), and one patient died of unrelated causes 10 months after nephrectomy.

The control group included tissue sections of normal kidneys from 20 cases provided by forensic autopsies at the Department of Forensic Pathology in Prishtina, Kosovo.

Morphological grading

Histopathological nuclear grading has been performed by pathologists in the Institute of Pathology, University Clinical Center of Kosovo, based on the worse histological features, according to Fuhrman and co-workers [12]. As a result, 25 (62.5 %) cases were classified as Fuhrman grade 2; 13 (32.5 %) cases as Fuhrman grade 3, and 2 (5.0 %) cases as Fuhrman grade 4. Nuclear grade was assessed by combining nuclear grades 1 and 2 into one group, and nuclear grades 3 and 4 as another group.

Tumor staging

The tumour stage has been determined by TNM classification system 2010 [13]. This classification system has been used to evaluate the tumour size, the status of the regional lymph nodes and the perinephric tissue, and tumour invasion through the renal capsule into perirenal fat or major renal veins at the renal hilum. There have been identified 17 cases of stage I (42.5%), 8 cases of stage II (20.0 %), 12 cases of stage III (30.0 %), and 3 cases of stage IV (7.5%). The tumour size has been measured as the maximal diameter of the tumour mass. The median tumour diameter was 71.0 mm (range 13-125 mm).

Tissue collection and preparation

Tumour and kidney cortex tissue samples were obtained from the surgical specimen. Each sample was divided into smaller pieces (1-2 cm²). Samples were formalin fixed and paraffin embedded for immuno-histochemical staining and morphologic examination.

Immunohistochemistry

Representative paraffin tumour blocks were selected by primary evaluation of haematoxylin/eosin-stained slides. For immunohistochemical evaluation 4-µm, thick paraffin blocks were sliced. Slides were treated with standard procedures of deparaffinisation, rehydration, microwave heating and immuno-histochemical (IHC) staining. For the IHC techniques, the antibodies VEGF-A (A-20, 1:150 dilution; Santa Cruz Biotechnology Inc, CA, USA) were used.

IHC results were independently evaluated by two specialised pathologists, blinded to each patient's clinical data. VEGF-A protein expression mainly was observed in the cytoplasm of the tumour cells. IHC VEGF-A expression was quantified by estimating the volume density and staining intensity on a three-grade scale. A semiquantitative scoring system was used, based on staining intensity (0, negative; 1, weak; 2, intermediate; 3, strong), which was corresponded to the percentage of positive stained cells (0, 0%; 1, < 25% positive; 2, 26-50% positive; 3, ≥ 50% positive) [14].

The positive and uniform IHC VEGF-A expressions in normal kidney tubular cells were used as a control for immuno-histochemical evaluation of positive IHC VEGF-A expression in tumour cells.

Microvessel counting was used for angiogenesis assessment. Immunostained tumour sections were scanned at high power magnification (200 x) to identify the areas with highest vascular density so-called "hot -spots". Determining microvessel density was expressed as the number of stained microvessels per optical field. Any cell or cell

cluster showing positive CD31 staining was counted as a vessel, as described in the Weidner method [15].

The degree of necrosis and degree of haemorrhage has been assessed with the presence versus absence of haemorrhage and necrosis.

Statistical methods

The Mann-Whitney U test was used to identify differences in not-parametric variables for two independent groups, and the Kruskal-Wallis test was used for comparison of more than two groups. Spearman rank correlation test was used to compare the relationship between sets of non-parametric variables that did not demonstrate a linear relation. Chi-Square test was used to evaluate differences in proportions of observations between independent groups. Fisher's exact test was used when the sample size was too small to use the chi-square test. The median value was chosen as the cut-off value. Survival data was analysed using the Kaplan-Meier method, and comparison of survival times for groups was performed with the log-rank test. The variables were dichotomously tested and analysed as continuous in a univariate Cox regression analysis. Survival time was measured from the date of nephrectomy to the date of death or latest follow-up. In all tests, a two-tailed significance level was set to < 0.05.

Results

Immunohistochemical assessment of VEGF-A expression

In normal renal tissues, VEGF-A expression was limited to the cytoplasm of tubular epithelium, smooth muscle cells and macrophages in the interstitial tissue, and mesangial cells in the glomerule (Fig. 1).

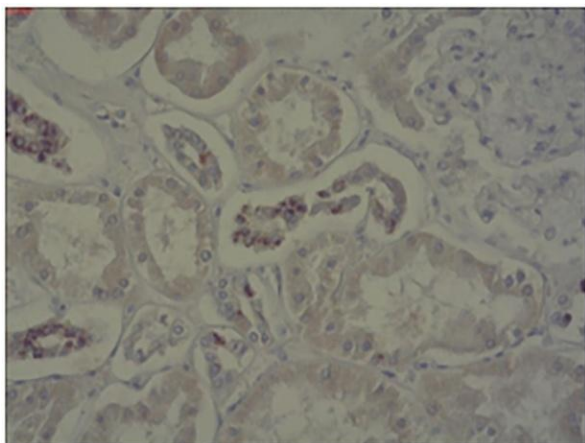


Figure 1: IHC staining of VEGF-A in control group (200 x)

In CCRCC, VEGF-A was expressed in the cytoplasm of tumour cells, endothelial cells, and stromal fibroblasts (Fig. 2).

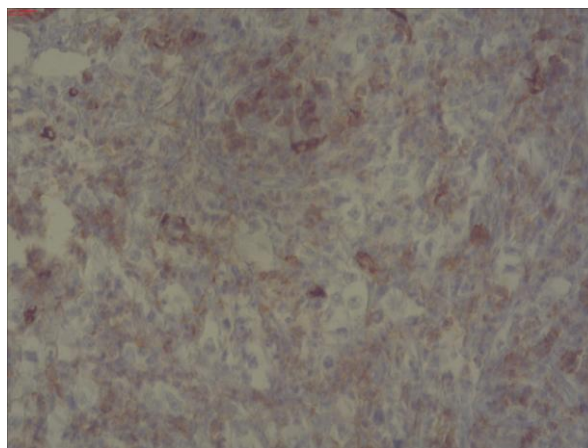


Figure 2: IHC staining of VEGF-A in CCRCC

The average value of VEGF-A expression in CCRCCs group was 2.75 (DS \pm 0.44), and 1.8 (DS \pm 0.41) in the control group. The study provided a difference with an important statistical significance between VEGF-A expression in CCRCC group and non-malignant kidney tissues group ($U' = 720$, $P < 0.0001$). No significant difference has been recorded for the values of VEGF-A between both genders ($U' = 224.5$, $P = 0.494$). Using Kruskal-Wallis test no difference with an important statistical significance between VEGF-A values regarding tumour size was detected ($KW = 6.06$, $P = 0.048$) (Table 1).

Table 1: Results of VEGF expression in CCRCC according to study groups, genders and tumour size

Characteristics	VEGF-An expression
Study groups	
Control	1.80 (SD \pm 0.41)
CCRCC	2.75 (SD \pm 0.44)
Sex	
Male	2.68 (SD \pm 0.48)
Female	2.81 (SD \pm 0.40)
Tumor size	
< 40 mm	2.80 (SD \pm 0.45)
40-70 mm	2.90 (SD \pm 0.31)
>70 mm	2.53 (SD \pm 0.52)

The average value of VEGF-A expression in patients with CCRCC nuclear grade 2 was 2.80 (DS \pm 0.41), while in patients with CCRCC nuclear grade 3 and 4 was 2.67 (DS \pm 0.49). The statistical analysis showed no difference between VEGF-A values and the tumour nuclear grade ($U' = 212.5$, $P = 0.484$). The average value of VEGF-A expression in patients with CCRCC pathological stage I and II was 2.88 (DS \pm 0.33), while in patients with CCRCC pathological stage III and IV was 2.53 (DS \pm 0.52). Additionally no difference between VEGF-A values regarding the tumor stage was recorded ($U' = 252.5$, $P = 0.067$).

Correlations between VEGF A and other clinicopathologic parameters

VEGF A expression values in CCRCC was positively correlated with Disease free survival (DFS) ($r = 0.335$, $P = 0.034$) and the tumor necrosis degree ($r = 0.181$, $P = 0.262$). VEGF A expression values in CCRCC was not correlated with CD 31 expression ($r = -0.09$, $P = 0.549$) and Progression free survival (PFS) ($r = -0.07$, $P = 0.838$).

Table 2: Correlations between VEGF A expression and other prognostic factors

Clinicopathologic parameters	VEGF-A
Tumor size	$r = -0.361$
Tumor hemorrhage	$r = -0.235$
Tumor necrosis	$r = 0.181$
Nuclear grade	$r = -0.161$
Pathological stage	$r = -0.371$
CD 31	$r = -0.090$
DFS	$r = 0.335$
PFS	$r = -0.070$
CSS	$r = -0.207$

VEGF A expression values in CCRCC were negatively correlated with the tumor nuclear grade ($r = -0.161$, $P = 0.318$), the pathological tumor stage ($r = -0.371$, $P = 0.018$), the tumor size ($r = -0.361$, $P = 0.022$), tumor hemorrhage degree ($r = -0.235$, $P = 0.143$), Cancer specific survival (CSS) ($r = -0.207$, $P = 0.713$) (Table 2).

Discussion

Angiogenesis is controlled by angiogenic factors that regulate extracellular matrix remodelling, endothelial cell proliferation, capillary differentiation, and anastomosis necessary to establish a blood supply. Angiogenic stimuli are released by tumour cells, stromal cells, and inflammatory cells recruited to the tumour site [16]. Among several identified peptides with angiogenic properties, the vascular endothelial growth factor (VEGF) is thought to play a major role in tumour angiogenesis [17]. Tumour angiogenesis has been well documented both in experimental and clinical studies, and the degree of angiogenesis was closely associated with tumour progression and shorter patient survival in many types of cancers [18], whereas data for RCC are controversial [19].

The results showed that the VEGF-A expression in patients with CCRCC was higher than in normal kidney tissues. Despite other studies in which the control group consisted of non-tumorous tissue from the surrounding of the tumour, the control group of our study included normal kidney tissues provided by the forensic autopsies. Given that VEGF-A expression was higher in CCRCC, it could be postulated that VEGF-A expression might have an effect on the non-tumorous tissue of the same kidney

making such control group unreliable for comparison. On the other hand, the control tissues of this study did not show pathological changes and therefore can be deemed more credible.

In the current research, VEGF-A expression in CCRCC was positively correlated with the tumor necrosis degree ($r = 0.181$, $P = 0.262$). In Rioux-Leclercq N [20] study, VEGF expression was also correlated with tumour necrosis ($P = 0.001$). Based on IHC data, several investigators have reported that VEGF overexpression in CCRCC was associated with tumour stage, pathological grade, histological vein invasion and prognosis [21, 22]. Tumour angiogenesis was reported to be the only significant predictor of prognosis in low stage RCC [23]. However, angiogenesis was not related to the tumour malignancy or patient survival of RCC [24]. Verheul et al. reported that VEGF expression using IHC in CCRCC was not significantly correlated with prognosis [25].

An important finding of our study was that VEGF-A expression is significantly correlated with prognosis. This discrepancy in IHC results could be due to several factors including differences in fixation, scoring and staining methods [25-27].

Compared to other studies, our approach was to comprehend different factors such as the tumour grade and stage with macroscopic features such as tumour size, haemorrhage degree and tumour necrosis degree. Our study showed a decrease in VEGF-A expression in more advanced tumour grade and stage and large tumour sizes. Although not statistically significant, the study results showed that higher VEGF expression is a good prognostic factor for low pathologic tumour stage CCRCCs, similarly to that described in the study of Nativ et al. [23].

Our study showed a positive correlation between VEGF-A expression tumour necrosis degree and a negative correlation between VEGF-A expression and tumour haemorrhage degree. Minardi et al. in his study could not find a correlation between the endothelial and tumoral cells cytoplasmic expression of VEGF and tumour necrosis [26].

Also, a correlation between VEGF-A expression and Microvessel density (MVD) measured through CD31 was not recorded. Even though, Djordjevic et al. reported an inverse correlation between VEGF expression and MVD, which can be found in CCRCC [27].

In our study, lower VEGF-A expression was also associated with an increased risk of renal cancer death and recurrence in CCRCC patients. Surgical removal of CCRCC with high VEGF-A expression in the lower stages, without metastasis, is associated with increased cancer-free survival. These circumstances explain VEGF-A expression is closely linked with better survival.

The trend of decreasing levels of VEGF expression in advanced tumour stages may indicate that angiogenic activity is an early event in tumour growth, but during later tumour progression, the role of VEGF is less clear. Jacobsen et al. [28] postulate that lower VEGF-A expression in higher tumour nuclear grade and pathological tumour stage can result due to other proliferative and angiogenic factors overcoming VEGF-A expression. Thus, these other factors may have a key role in disease progression and short survival in patients with metastatic CCRCC. The complexities of multiple different growth factors are not completely understood, and their role and relationship remain important as a subject of future investigation in RCC [29].

In conclusion, this study demonstrates that tumour VEGF-A expression is a valuable prognostic indicator of low-grade CCRCC and can be used to stratify advanced and metastatic CCRCC patients into low-benefit and high-benefit groups. High VEGF-A expression patients will benefit from anti-angiogenic treatment with VEGF blockers or VEGF receptor blockers. On the other hand, low VEGF-A expression patients will not benefit from this therapy, and they should be treated with alternative medications.

Therefore, we recommend that performing IHC staining for VEGF-A expression would be very useful in the treatment strategy of patients with CCRCC.

Author Contributions

F. Veselaj: Project development, Data collection and management, Manuscript writing; S. Manxhuka-Kërliu: Project development, Data Management, Made critical revisions and approved final version; A. Neziri: Data collection and management; L. Shahini: Data collection and management; Sh. Xharra: Data collection and management; L. Selmani: Data collection and management; L. Kerliu: Literature review and language editing; F. Kavaja: Data collection and management. All authors reviewed and approved of the final manuscript.

Ethical standards

Authors disclose no potential conflicts of interest. Before publication all authors have given confirmation of agreement to article publication and compliance with all applicable ethical and legal requirements, including the accuracy of author and contributor information, compliance with ethical requirements relating to human study participants.

References

1. Jemal A, Siegel R, Ward E, et al. Cancer statistics, 2008. *CA Cancer J Clin*. 2008; 58: 71–96. <https://doi.org/10.3322/CA.2007.0010> PMID:18287387
2. Socialstyrelsen: Cancer Incidence in Sweden 2003. The National Board of Health and Welfare, Centre for Epidemiology, 2004.
3. Yagoda A. (1990) Phase II cytotoxic chemotherapy trials in renal cell carcinoma: 1983–1988. *Prog Clin Biol Res*. 1990;350:227–241. PMID:2201045
4. Yoshino S, Kato M. and Okada K. Clinical significance of angiogenesis, proliferation and apoptosis in renal cell carcinoma. *Anticancer Res*. 2000; 20:591–594. PMID:10769700
5. Cockerill GW, Gamble JR, Vadas MA. Angiogenesis: models and modulators. *Int Rev Cytol*. 1995; 159:113–60. [https://doi.org/10.1016/S0074-7696\(08\)62106-3](https://doi.org/10.1016/S0074-7696(08)62106-3)
6. Ferrara N, Davis ST. The biology of vascular endothelial growth factor. *Endocr Rev*. 1997;18: 4–25. <https://doi.org/10.1210/edrv.18.1.0287> PMID:9034784
7. Senger DR, Connolly DT, Van de Water L, Feder J, Dvorak HF. Purification and NH₂-terminal amino acid sequence of guinea pig tumor-secreted vascular permeability factor. *Cancer Res*. 1990; 50:1774–1778. PMID:2155059
8. Leung DW, Cachianes G, Kuang WJ, Goeddel DV, Ferrara N. Vascular endothelial growth factor is a secreted angiogenic mitogen. *Science*. 1989; 246:1306–1309. <https://doi.org/10.1126/science.2479986> PMID:2479986
9. Shweiki D, Itin A, Soffer D, Keshet E. Vascular endothelial growth factor induced by hypoxia may mediate hypoxia-initiated angiogenesis. *Nature*. 1992; 359:843–845. <https://doi.org/10.1038/359843a0> PMID:1279431
10. Frank S, Hubner G, Breier G, Longaker MT, Greenhalgh DG, Werner S. Regulation of vascular endothelial growth factor expression in cultured keratinocytes. Implications for normal and impaired wound healing. *J Biol Chem*. 1995; 270:12607–12613. <https://doi.org/10.1074/jbc.270.21.12607> PMID:7759509
11. Takahashi H, Shibuya M. The vascular endothelial growth factor (VEGF)/VEGF receptor system and its role under physiological and pathological conditions. *Clin Sci (Lond)*. 2005; 109:227–241. <https://doi.org/10.1042/CS20040370> PMID:16104843
12. Fuhrman SA, Lasky LC, Limas C. Prognostic significance of morphologic parameters in renal cell carcinoma. *Am J Surg Pathol*. 1982;6: 655-663. <https://doi.org/10.1097/0000478-198210000-00007> PMID:7180965
13. Edge SB, Byrd DR, Compton CC, et al. *AJCC Cancer Staging Manual*. 7th ed. New York, NY: Springer, 2011: 479-89.
14. Sang HS. In Gab J, Dalsan Y, et al. VEGF/VEGFR2 and PDGF-B/PDGFR- β expression in non-metastatic renal cell carcinoma: a retrospective study in 1,091 consecutive patients. *Int J Clin Exp Pathol*. 2014; 7(11):7681-7689.
15. Weidner N, Semple JP, Welch WR, Folkman J. Tumor angiogenesis and metastasis-correlation in invasive breast carcinoma. *N Engl J Med*. 1991; 324:1–8. <https://doi.org/10.1056/NEJM199101033240101> PMID:1701519
16. Takano S, Yoshii Y, Kondo S, Suzuki H, Maruno T, Shirai S, Nose T. Concentration of vascular endothelial growth factor in the serum and tumor tissue of brain tumor patients. *Cancer Res*. 1996;2185–2190. PMID:8616870
17. Ferrara N, Henzel WJ. Pituitary follicular cells secrete a novel heparin-binding growth factor specific for vascular endothelial cells. *Biochem Biophys Res Commun*. 1989; 161:851–8. [https://doi.org/10.1016/0006-291X\(89\)92678-8](https://doi.org/10.1016/0006-291X(89)92678-8)
18. Weidner N. Intratumor microvessel density as a prognostic factor in cancer. *Am J Pathol*. 1995; 147: 9–19. PMID:7541613 PMID:PMC1869874
19. Yoshino S, Kato M, Okada K. Evaluation of the prognostic significance of microvessel count and tumor size in renal cell

- carcinoma. *Int J Urol.* 1998; 5:119–23. <https://doi.org/10.1111/j.1442-2042.1998.tb00258.x> PMID:9559835
20. Rioux-Leclercq N, Fergelot P, Zerrouki S, Leray E, Jouan F, Bellaud P, Epstein JI, Patard JJ. Plasma level and tissue expression of vascular endothelial growth factor in renal cell carcinoma: a prospective study of 50 cases. *Human Pathology.* 2007; 38(10):1489-1495. <https://doi.org/10.1016/j.humpath.2007.02.014> PMID:17597181
21. Paradis V, Lagha NB, Zeimoura L, Blanchet P, Eschwege P, Ba N, Benoît G, Jardin A, Bedossa P. Expression of vascular endothelial growth factor in renal cell carcinomas. *Virchows Arch.* 2000; 436: 351-356. <https://doi.org/10.1007/s004280050458> PMID:10834538
22. Yildiz E, Gokce G, Kilicarslan H, Ayan S, Goze OF, Gultekin EY. Prognostic value of the expression of Ki-67, CD44 and vascular endothelial growth factor, and microvessel invasion, in renal cell carcinoma. *BJU Int.* 2004; 93: 1087-1093. <https://doi.org/10.1111/j.1464-410X.2004.04786.x> PMID:15142169
23. Nativ O, Sabo E, Reiss A, Wald M, Madjar S, Moskovitz B. Clinical significance of tumor angiogenesis in patients with localized renal cell carcinoma. *Urology.* 1998; 51: 693–6. [https://doi.org/10.1016/S0090-4295\(98\)00019-3](https://doi.org/10.1016/S0090-4295(98)00019-3)
24. Kohler HH, Barth PJ, Siebel A, Gerharz EW, Bittinger A. Quantitative assessment of vascular surface density in renal cell carcinomas. *Br J Urol.* 1996; 77: 650–4. <https://doi.org/10.1046/j.1464-410X.1996.08544.x> PMID:8689104
25. Verheul HM, van Erp K, Homs MY, Yoon GS, van der Groep P, Rogers C, Hansel DE, Netto GJ, Pili R. The relationship of vascular endothelial growth factor and coagulation factor (fibrin and fibrinogen) expression in clear cell renal cell carcinoma. *Urology.* 2010; 75:608-614. <https://doi.org/10.1016/j.urology.2009.05.075> PMID:19683801
26. Minardi, G. Lucarini, G. Milanese et al. Tumor necrosis, microvessel density growth factor and hypoxia inducible factor -1 α in patients with Clear Cell Renal Carcinoma after radical nephrectomy in a long term follow-up. *Internation Journal of Immunopathology and Pharmacology.* 2008; 21(2):0394-6320.
27. Djordjevic G, Mozetic V, Vrdoljak–Mozetic D, et al. Prognostic significance of vascular endothelial growth factor expression in clear cell renal cell carcinoma. *Pathology–Research and Practice.* 2007; 203:99–106. <https://doi.org/10.1016/j.prp.2006.12.002> PMID:17270362
28. Jacobsen J, Rasmuson T, Grankvist K, Ljungberg B. Vascular endothelial growth factor as prognostic factor in renal cell carcinoma. *Journal of Urology.* 2000; 163(1): 343-7. [https://doi.org/10.1016/S0022-5347\(05\)68049-4](https://doi.org/10.1016/S0022-5347(05)68049-4)
29. Jacobsen J, Grankvist K, Rasmuson T, Bergh A, Landberg G, Ljungberg B. Expression of vascular endothelial growth factor protein in human renal cell carcinoma. *BJU Int.* 2004; 93(3):297-302. <https://doi.org/10.1111/j.1464-410X.2004.04605.x> PMID:14764126