

Prenatally Diagnosis and Outcome of Fetuses with Cardiac Rhabdomyoma – Single Centre Experience

Ramush Bejiqi^{1*}, Ragip Retkoceri¹, Hana Bejiqi²

¹Division of Cardiology, Pediatric Clinic, University Clinical Center of Kosovo, Prishtina, Kosovo; ²Main Center of Family Medicine, Prishtina, Kosovo

Abstract

Citation: Bejiqi R, Retkoceri R, Bejiqi H. Prenatally Diagnosis and Outcome of Fetuses with Cardiac Rhabdomyoma – Single Centre Experience. Open Access Maced J Med Sci. <https://doi.org/10.3889/oamjms.2017.040>

Keywords: cardiac rhabdomyoma; fetal echocardiography; tuberous sclerosis complex.

***Correspondence:** Ramush Bejiqi, Division of Cardiology, Pediatric Clinic, University Clinical Center of Kosovo, Prishtina, Kosovo. E-mail: rbejiqi@hotmail.com

Received: 25-Jan-2016; **Revised:** 22-Feb-2017; **Accepted:** 24-Feb-2017; **Online first:** 20-Mar-2017

Copyright: © 2017 Ramush Bejiqi, Ragip Retkoceri, Hana Bejiqi. This is an open-access article distributed under the terms of the Creative Commons Attribution-NonCommercial 4.0 International License (CC BY-NC 4.0).

Funding: This research did not receive any financial support.

Competing Interests: The authors have declared that no competing interests exist.

BACKGROUND: Cardiac rhabdomyoma (CRs) are the most common primary tumour of the heart in infants and children. Usually are multiple and, basing on the location can cause a haemodynamic disturbance, dysrhythmias or heart failure during the fetal and early postnatal period. CRs have a natural history of spontaneous regression and are closely associated with tuberous sclerosis complex (TSC). It has an association with tuberous sclerosis (TS), and in those, the tumour may regress and disappear completely, or remain consistent in size.

AIM: We aimed to evaluate the prenatal diagnosis, clinical presentation and outcome of CRs and their association with TSC in a single centre. The median follow-up period was three years (range: 6 months - 5 years).

MATERIAL AND METHODS: We reviewed medical records of all fetuses diagnosed prenatally with cardiac rhabdomyoma covering the period January 2010 to December 2016 which had undergone detailed ultrasound evaluation at a single centre with limited technical resources.

RESULTS: Twelve fetuses were included in the study; mostly had multiple tumours and a total of 53 tumours were identified in all patients - the maximum was one fetus with 16 tumours. All patients were diagnosed prenatally by fetal echocardiography. In two patient's haemodynamic disturbances during the fetal period was noted and pregnancies have been terminated. After long consultation termination of pregnancy was chosen by the parents in totally 8 cases. In four continuing pregnancies during the first year of live tumours regressed. TSC was diagnosed in all patients during the follow-up.

CONCLUSIONS: Cardiac rhabdomyoma are benign from the cardiovascular standpoint in most affected fetuses. An early prenatal diagnosis may help for an adequate planning of perinatal monitoring and treatment with the involvement of a multidisciplinary team. Large tumour size, the number of tumours and localisation may cause hydrops, and they are significantly associated with poor neonatal outcome.

Introduction

In 1982, DeVore et al. first reported the prenatal diagnosis of a cardiac tumour. With the advancement of fetal echocardiography and magnetic resonance imaging (MRI), prenatal diagnosis of fetal cardiac tumours has become feasible, and the number of case series reported has increased in this past decade [1].

With the estimated incidence 1 in 20,000 births are the most common fetal cardiac tumour. Cardiac rhabdomyoma (CRs) are often multiple and can represent up to 90% of cardiac tumours in the paediatric population [1]. The majority are diagnosed during the fetal period or before the age of 1 year. CRs diagnosed on fetal echocardiography are typical of TSC [2]. It may be isolated or associated with other specific lesions of TSC, namely cortical tubers and

subependymal nodules, or, rarely, renal lesions. The association of CR with such specific lesions during fetal life strongly supports the diagnosis of TSC [2, 3]. As cerebral lesions are responsible for the most severe clinical manifestations of the disease, such as seizures, mental retardation and behavioural abnormalities, the neurodevelopmental outcome is a critical issue when cerebral lesions are observed during fetal life. The absence of a brain or renal lesions, however, excludes neither the diagnosis of TSC nor the possibility of future neurodevelopmental complications, because lesions may develop progressively after birth [3, 4]. Tuberous sclerosis complex is an autosomal dominant genetic disease with an incidence of about 1/6000 to 1/10 000 live births. It is characterised by the widespread development of hamartomas in different tissues. It is caused by mutations in either the TSC1 or the TSC2 gene, located on chromosomes 9q34 and 16p13.3, respectively [5].

Table 1: Demographic data of the 12 patients diagnosed cardiac rhabdomyoma

Case	GA (weeks)	Sex	Family history	Hydrops	Termination of pregnancy	Number of tumours	Tuberous sclerosis	Location	Largest diameter (mm)
GA - gestational age; F- female, M-male; IVS - interventricular septum; LV - left ventricle; RV - right ventricle;									
1	17	F	none	-	+	Multiple	-	RV + LV	41
2	29	M	none	-	-	Multiple	+	RV + IVS	11
3	26	M	none	-	-	Multiple	+	RV + LV	30
4	34	F	+	+	-	Multiple	-	RV + LV	34
5	18	M	none	-	-	Multiple	+	RV + LV	22
6	18	F	-	-	-	Multiple	+	RV + LV	16
7	31	F	none	+	-	Multiple	+	RV	14
8	18	F	none	-	+	Multiple	-	RV	8
9	20	M	-	-	+	Multiple	-	RV	23
10	19	F	none	-	+	Single	-	LV	20
11	19	F	-	-	+	Single	-	LV	20
12	21	F	none	-	+	Single	-	RV	16

The exact incidence of rhabdomyoma coexisting with TS in fetuses is unknown; although an estimate of one in 10 000 in routine necropsies of all ages was reported. With improved sonographic, MRI and molecular analytical technology, a fetal diagnosis of cardiac rhabdomyoma may be of great clinical significance [3, 6].

The purpose of this meta-analysis, with the addition of 12 cases from our hospital, was to evaluate outcome in cases diagnosed with fetal cardiac rhabdomyoma using prenatal sonography.

Study design

We reviewed the medical records of all cases diagnosed prenatally by fetal echocardiography, with cardiac rhabdomyoma, between January 2010 and December 2016.

Results

Twelve fetuses with cardiac rhabdomyoma were diagnosed at 21.4 ± 6.0 weeks' gestational age. Of ten continued pregnancies, there were two spontaneous intrauterine deaths, in 8 cases termination of pregnancies was chosen by parents and four were delivered at term. Although, of continuing pregnancies, none had prenatal hemodynamic complications, after birth none had cardiac symptoms. Over the same period, all patients were diagnosed with cardiac rhabdomyoma postnatally. All were referred for cardiac assessment after findings suggesting TSC. On follow-up, TSC was confirmed in all patients including neurodevelopmental disease. The incidence of cardiac symptoms and TSC was not statistically different between the prenatal and postnatal diagnosis groups.

The demographics of the 12 cases of fetal cardiac rhabdomyoma from our hospital are shown in

Table 1. There were nine cases with multiple tumours (Figure 1 and 2) and three cases with single tumours (Figure 3).

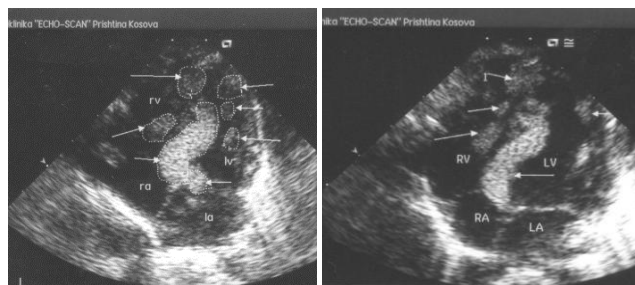


Figure 1: Fetus in the 34th gestational week of pregnancy with multiple rhabdomyoma – we counted 16 tumours in different heart structures

The mean diameter of the tumour mass at detection was 17 (range, 6–29) mm. Seven cases of cardiac rhabdomyoma were detected before 20 weeks of gestation. Of the four surviving neonates, all were associated with TS, and all had multiple tumours. There was no survivor when fetal hydrops or fetal dysrhythmia occurred.

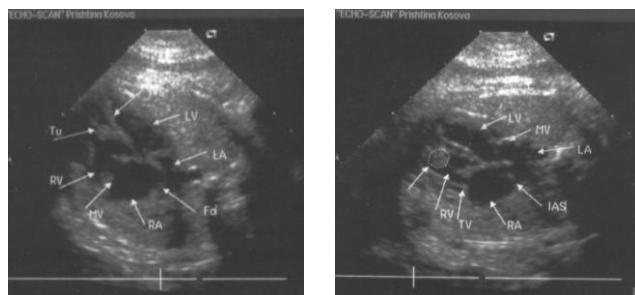


Figure 2: Fetus in the 19th gestational week of pregnancy with isolated rhabdomyoma

Discussion

Cardiac rhabdomyoma are the most common fetal cardiac tumours during prenatal and neonatal periods, accounting for 60–86% of primary fetal cardiac tumours. Prenatally, they are usually diagnosed during the second or third trimester [6, 7].

On ultrasound, rhabdomyomas appear as round, homogeneous, hyperechogenic masses in the ventricles, and they sometimes appear as multiple foci in the ventricles and septal wall. Differential diagnosis between rhabdomyoma, fibroma or myxoma using ultrasonography for a single cardiac mass remains difficult.

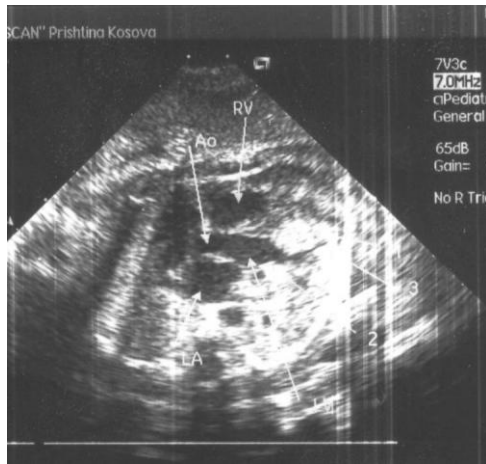


Figure 3: Fetus in the 26th gestational week of pregnancy with multiple rhabdomyoma

On the contrary, other primary cardiac tumours in fetuses such as teratoma and hemangioma are easily distinguishable, both clinically and using imaging studies. Hemangiomas show a more complex echogenicity, with cystic and solid parts mixed with calcifications, and are usually found in the right atrium. Teratomas are extracardiac masses that are located in the pericardial cavity, always associated with pericardial effusion and weakly associated with TS. Cardiac complications are rare and mainly involve fetal dysrhythmia (brady or tachyarrhythmia), but other complications such as intracardiac obstruction and cardiac failure also may be associated [8-10].

The earliest antenatal sonographic detection of a cardiac tumour in our study was at 17 weeks of gestation whereas half of them were detected after 20 weeks of gestations.

The smallest detectable tumour mass was 6 mm, and the largest was 29 mm in diameter. Although the difference was not statistically significant, smaller tumours tended to be multiple and a search for more tumours when the cardiac mass size is small is therefore recommended. In our study, all cardiac rhabdomyoma showed an increase in size in utero, but rapid growth was uncommon. Both foetuses with perinatal death had the tumour mass bigger than ≥ 20 mm in diameter. Although histologically benign, larger tumours carry a greater risk of causing hemodynamic disturbances and dysrhythmias, which could result in poorer outcome at the fetal age [8, 10, 11].

In our cases, we didn't find cardiac or extracardiac structural defects. Also, there was no any coexistence of cardiac rhabdomyoma with trisomy 21

or any other chromosomal anomalies.

CRs may have different presentations and clinical course. Surgery is only necessary when a hemodynamically significant obstruction is present.¹²

As CRs are associated with long-term development of TSC and other diagnostic features are not yet typically apparent in the prenatal and neonatal periods, careful evaluation and follow-up are essential to exclude TSC.¹³

The genetic basis of TS is heterogeneous, and TS may be caused by the mutation of the tumour suppressor genes TSC1 or TSC2. A genetic method of screening for TS patients has not been established. Cardiac rhabdomyoma may be the earliest sign of TS in utero and precede the detection of brain or kidney lesions. TS follows an autosomal dominant hereditary pattern with variable expression, and 50–80% of childhood cases are considered to result from spontaneous mutations. The detection of cardiac tumours, which can be achieved using prenatal echocardiography, should be used as a warning sign for TS during the counselling of at-risk families.^{2, 3, 9}

Despite the aforementioned limitations on the number of cases and lack of MRI investigations, this report showed that a positive family history of TS and multifocality of fetal cardiac rhabdomyoma are two strong predictors of neonatal outcome. Large tumours, hydrops and fetal dysrhythmias are usually correlated with hemodynamic disturbances, resulting in poor outcomes during the fetal life. Fetal echocardiography is useful in the detection of cardiac rhabdomyoma, providing a clue for the detection of TS.

To better predict neurodevelopmental prognosis, further investigation is required to evaluate the number, size and location of specific cerebral lesions in cases that are diagnosed prenatally with CR.

References

- De Vore GR, Hakim S, Kleinman CS, et al. The in utero diagnosis of an interventricular septal cardiac rhabdomyoma by means of real-time directed, M-mode echocardiography. *Am J Obstet Gynecol.* 1982;143:967–9. [https://doi.org/10.1016/0002-9378\(82\)90484-7](https://doi.org/10.1016/0002-9378(82)90484-7)
- Identification and characterization of the tuberous sclerosis gene on chromosome 16. The European Chromosome 16 Tuberous Sclerosis Consortium. *Cell.* 1993; 75: 1305 – 1315. [https://doi.org/10.1016/0092-8674\(93\)90618-Z](https://doi.org/10.1016/0092-8674(93)90618-Z)
- O'Callaghan FJ, Shiell AW, Osborne JP, Martyn CN. Prevalence of tuberous sclerosis estimated by capture-recapture analysis. *Lancet.* 1998; 351:1490. [https://doi.org/10.1016/S0140-6736\(05\)78872-3](https://doi.org/10.1016/S0140-6736(05)78872-3)
- Roach ES, Gomez MR, Northrup H. Tuberous sclerosis complex consensus conference: revised clinical diagnostic criteria. *J Child Neurol.* 1998;13:624–8. <https://doi.org/10.1177/088307389801301206> PMID:9881533
- Pipitone S, Mongiovi M, Grillo R, Gagliano S, Sperandeo V. Cardiac rhabdomyoma in intrauterine life: clinical features and natural history. A case series and review of published reports. *Ital*

Heart J. 2002; 3: 48 – 52. PMID:11899590

6. Allan L. Fetal cardiac tumors. In: Allan L, Hornberger L, Sharland G, editors. Textbook of fetal cardiology. London: Greenwich Medical Media Limited, 2000: 358–65. PMID:11065052

7. Isaacs H, Jr. Fetal and neonatal cardiac tumors. *Pediatr Cardiol.* 2004; 25: 252 – 273. <https://doi.org/10.1007/s00246-003-0590-4> PMID:15360117

8. Chao AS, Chao A, Wang TH, et al. Outcome of antenatally diagnosed cardiac rhabdomyoma: case series and a meta-analysis. *Ultrasound Obstet Gynecol.* 2008; 31(3):289–95. <https://doi.org/10.1002/uog.5264> PMID:18307215

9. Saada J, Hadj Rabia S, Fermont L, Le Bidois J, Bernades-Stein L, Martinovic J, Sonigo P, Dumez Y, Bonnet D, Benachi A. Prenatal diagnosis of cardiac rhabdomyomas: incidence of associated cerebral lesions of tuberous sclerosis complex. *Ultrasound Obstet Gynecol.* 2009;34: 155–159. <https://doi.org/10.1002/uog.6367> PMID:19606448

10. Fesslova V, Villa L, Rizutti T, et al. Natural history and long-term outcome of cardiac rhabdomyomas detected prenatally. *Prenat Diagn.* 2004; 24:241–8. <https://doi.org/10.1002/pd.825> PMID:15065096

11. Tworetzky W, McElhinney DB, Margossian R, et al. Association between cardiac tumors and tuberous sclerosis in the fetus and the neonate. *Am J Cardiol.* 2003;92:487–9. [https://doi.org/10.1016/S0002-9149\(03\)00677-5](https://doi.org/10.1016/S0002-9149(03)00677-5)

12. Holley DG, Martin GR, Brenner JI, et al. Diagnosis and management of fetal cardiac tumors: a multicenter experience and review of published reports. *J Am Coll Cardiol.* 1995;26:516–20. [https://doi.org/10.1016/0735-1097\(95\)80031-B](https://doi.org/10.1016/0735-1097(95)80031-B)

13. Yinon Y, Chitayat D, Blaser S, Seed M, Amsalem H, Yoo S, Jaeggi E. Fetal cardiac tumors: a single-center experience of 40 cases. *Prenatal Diagnosis.* 2010;30:941–949. <https://doi.org/10.1002/pd.2590> PMID:20721876