

Primary Fallopian Tube Carcinoma: A Case Report and Literature Review

Meral Rexhepi^{1*}, Elizabeta Trajkovska², Hysni Ismaili³, Florin Besimi¹, Nagip Rufati¹

¹Clinical Hospital Tetovo, Department of Gynecology and Obstetrics, University of Tetovo, Faculty of Medical Sciences, Tetovo, Republic of Macedonia; ²Clinical Hospital Tetovo, Department of Pathology, Tetovo, Republic of Macedonia; ³University of Tetovo, Faculty of Medical Sciences, Tetovo, Republic of Macedonia

Abstract

Citation: Rexhepi M, Trajkovska E, Ismaili H, Besimi F, Rufati N. Primary Fallopian Tube Carcinoma: A Case Report and Literature Review. Open Access Maced J Med Sci. 2017 Jun 15; 5(3):344-348. <https://doi.org/10.3889/oamjms.2017.044>

Keywords: fallopian tube; serous cystadenocarcinoma; post-menopausal female; intraoperative assessment; histopathological diagnosis.

***Correspondence:** Meral Rexhepi, Clinical Hospital Tetovo, Department of Gynecology and Obstetrics, University of Tetovo, Faculty of Medical Sciences, Tetovo, Republic of Macedonia. E-mail: dr.meralrexhepi@gmail.com

Received: 13-Jan-2017; **Revised:** 16-Mar-2017; **Accepted:** 17-Mar-2017; **Online first:** 20-May-2017

Copyright: © 2017 Meral Rexhepi, Elizabeta Trajkovska, Hysni Ismaili, Florin Besimi, Nagip Rufati. This is an open-access article distributed under the terms of the Creative Commons Attribution-NonCommercial 4.0 International License (CC BY-NC 4.0).

Funding: This research did not receive any financial support.

Competing Interests: The authors have declared that no competing interests exist.

BACKGROUND: Primary fallopian tube carcinoma (PFTC) is a rare tumour of the female genital tract with an incidence of 0.1-1.8% of all genital malignancies, and it is very difficult to diagnose preoperatively, because of its non-specific symptomatology. In most cases, it is an intraoperative finding or a histopathological diagnosis. It is a tumour that histologically and clinically resembles epithelial ovarian cancer.

CASE PRESENTATION: We are reporting a case of a 62-year-old, postmenopausal woman with primary fallopian tube carcinoma of the right fallopian tube in stage IA. The patient has lower abdominal pain, watery vaginal discharge and repeated episodes of bleeding from the vagina. The clinical and radiological findings suggested a right adnexal tumour with elevated CA-125 levels. Total abdominal hysterectomy, bilateral salpingo-oophorectomy, omentectomy and peritoneal washing were performed. Pathologic confirmation of primary serous cystadenocarcinoma of the right fallopian tube was made. Peritoneal washings were negative for malignancy. FIGO stage was considered as IA, and the patient received no courses of chemotherapy and postoperative radiation because she refused it. Ten months after initial surgery, the patient is alive and in good condition.

CONCLUSION: Cytoreduction surgery followed by adequate cycles of chemotherapy is an important strategy to improve patients' prognosis.

Introduction

Primary fallopian tube carcinoma (PFTC) is a very rare gynecologic malignant tumor and accounts for approximately 0.14-1.8% of female genital malignancies [1-7]. In 1847, Renaud first described fallopian tube malignancy. In 1888, Orthmann presented the first genuine case report [7]. Since then over 2000 cases have been reported in literature.

Its incidence has been rising during the last decades and varied between 2.9/1,000,000 and 5.7/1,000,000 [8]. Histologic, molecular and genetic evidence shows that from 40-60% of tumours that were classified as high-grade serous carcinomas of the ovary or peritoneum may have originated in the fimbrial and of the fallopian tube. Therefore the

incidence of fallopian tube cancers may have been underestimated [9]. The aetiology of this tumour is unknown enough; it is suggested to be associated with chronic tubal inflammation, infertility, tuberculous salpingitis and tubal endometriosis [10]. Similar to ovarian malignancy, a BRCA germline mutation and TP53 mutation are associated with fallopian tube malignancy [11, 12].

Clinical symptoms and signs are non-specific and include lower abdominal, pelvic pain, serosanguinous vaginal discharge and pelvic mass [13, 14]. The rate of preoperative diagnosis was in the range of 0%-10% [15] and most cases it is an intraoperative finding or a histopathological diagnosis [16]. We are reporting a rare case of fallopian tube carcinoma in a 62-year-old female, with a review of the literature.

Case Report

We present a 62-year-old, post menopausal women who was gravid 4, para 2, living child 2 (Parity Index –G4P2L2), married, with no significant personal or family history. Her two deliveries were spontaneous vaginal deliveries, and she had been post-menopausal since past 16 years. She presented with the complaints of severe lower abdominal pain and intermittent vaginal bleeding and discharge that had occurred for the previous six months. The abdominal pain was a dull ache in the right lower abdomen which propagated to the back. The vaginal discharge was watery in consistency. For her medical history, she had taken antihypertension medication for the past eight years. On the admission day, her blood pressure was 140/90 mmHg, the puls rate was 80 beats per minute, and her temperature was 37.5°C. She had already tried conservative treatment, which had not improved her symptoms. Her hemogram, hepatic and renal functions were normal. Blood sugar and urine examination were normal.

On the physical examination was noticed left lateral lower quadrant tenderness. The pelvic examination revealed a normal sized anteverted uterus with cervical motion and adnexal tenderness. Speculum examination showed minimal bleeding with a healthy cervix and vagina.

Transabdominal sonography showed uterus with normal echostructure, measuring 64x52x38 mm. Endometrial thickness was 5 mm. Left ovary measured 20 x 15 x 10 mm and had normal echostructure. Unilateral heterogenous longitudinal mass, multilocular cyst with incomplete septation showed in the right adnexa, and the mass measured 7.2 x 4.6, which suggested right tube-ovarian abscess.

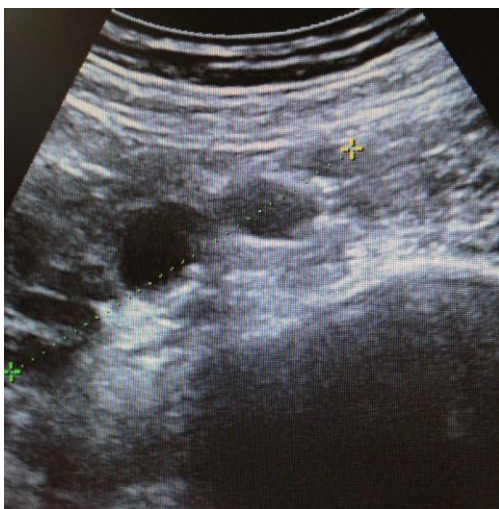

Figure 1: Transabdominal ultrasonography showing a multilocular cyst with incomplete septation

Free fluid was not seen in the abdomen.

Computerised tomography (CT) was not done. The white cell count on admission was $18.4 \times 10^9/L$, and the C-reactive protein level was 14.26 mg/dl. The Ca 125 antigen level was 162.20 U/ml (normal up to 35 U/ml), the Ca 19-9 and CEA levels was normal. Based on the clinical pictures and laboratory results a right tube-ovarian abscess was suspected, and broad spectrum parenteral antibiotics were established. The Pap smear was within normal limits.

A diagnostic curettage was performed which showed atrophic endometrium. In exploratory laparotomy was found hydrosalpinx on the right side with severe adhesions between the right adnexa, intestine and uterus. The patient underwent total abdominal hysterectomy, bilateral salpingo-oophorectomy, partial omentectomy with adhesiolysis and peritoneal washing was performed. The bilateral ovarian masses, fallopian tubes, uterus, omentum and sample of peritoneal washing were sent for histopathological analysis. The histopathologic examination showed primary serous cyst adenocarcinoma of the right fallopian tube with no serosa invasion. The tuba was tortuous, 17 cm in length with 5 cm long dilatation in the proximal third. In the dilated part, few exophytic, neoplastic, white-grayish soft lesions were found.

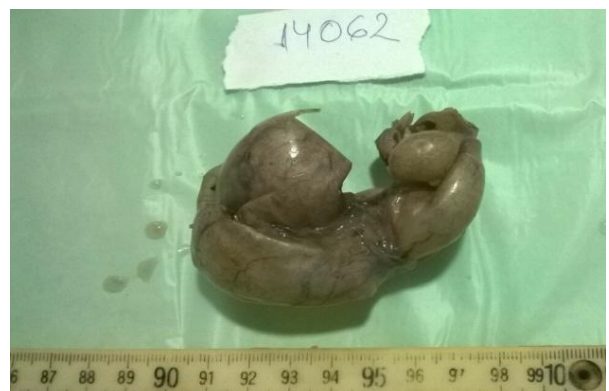

Figure 2: Tortuous fallopian tube (up), exophytic, neoplastic white grayish soft lesions (down)

The histopathologic examination revealed areas of in situ as well as high-grade primary serous adenocarcinoma of the fallopian tube with lamina propria involvement.

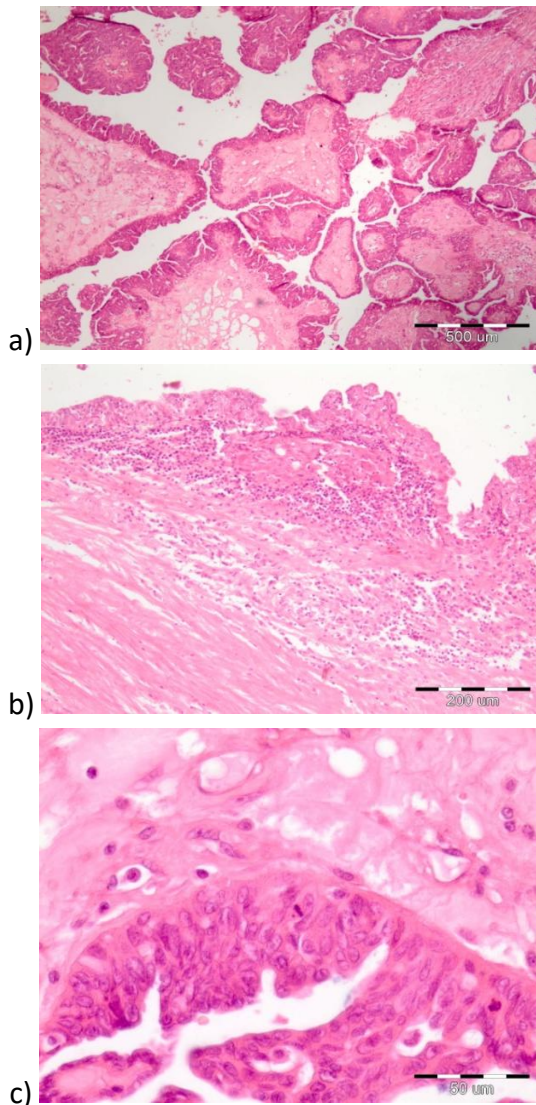


Figure 3: a) HE x 4 Adenocarcinoma tube; b) HE x 10 intact musculature; c) HE x 40 malignant epithelium

The malignant cells were positive for CK7, WT1 and P53, the tumour did not infiltrate the muscle layer, so it was defined as FIGO stage IA (pTNM = pT1A pNx pMx stage IA).

The uterus, ovaries, left the fallopian tube and the peritoneal washing fluid was free of tumour. In our case the pre-operative diagnosis was incorrect. This is the fact that Fallopian tube carcinomas are almost difficult to diagnose preoperatively due to the rarity and silent course of this neoplasm. The patient was discharged, seven days after the surgery and was referred to an oncologist for chemotherapy.

Discussion

Primary Fallopian tube carcinoma is the rarest malignancy of the female genital tract and was first

described by Renand in 1897 [17]. Rokitansky recorded the first microscopic description in 1861 and Orthman presented a first case report in 1888 [18]. Clinically and histologically (PFTC) resemble epithelial ovarian cancer (EOC), and it is difficult to distinguish from serious epithelial ovarian cancer or primary peritoneal serous carcinoma during or after operation [19].

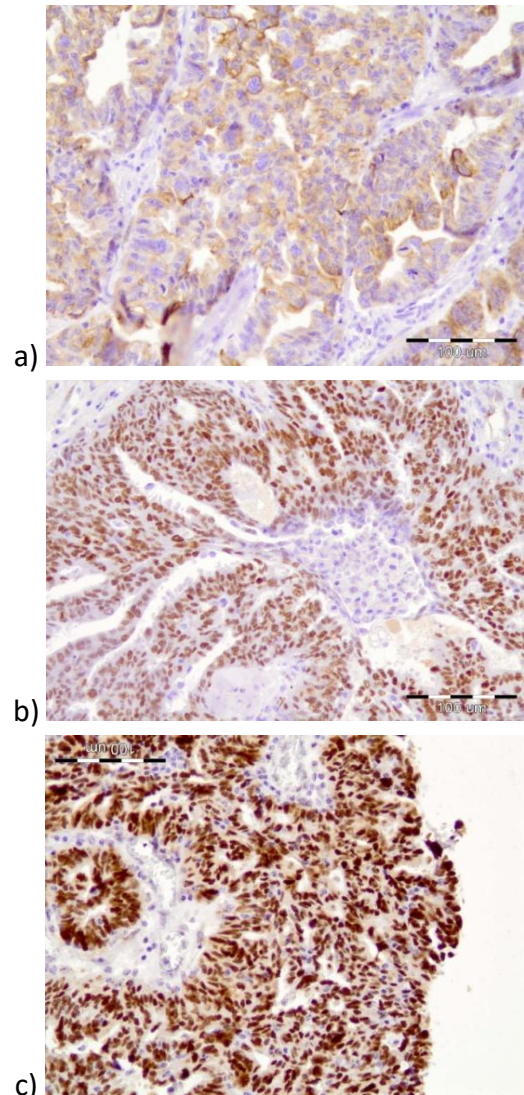


Figure 4: a) CK7 x 10 immunostaining positive with CK7 antibody; b) WT1 x 20 immunostaining positive with WT1 antibody; c) P53 x 20 immunostaining positive with P53 antibody

EOC is often diagnosed at an advanced stage, but PFTC is found more in an early stage, because of abdominal pain from tubal distension and a shorter history of symptoms in PFTC than in EOC [20]. The aetiology of this cancer is unknown. High parity has been reported to be protective, and use of oral contraceptives and pregnancy decreases the risk of PFTC [8]. Most patients with PFTC are postmenopausal. The peak incidence is between the ages 60 and 64 years, with the mean age of incidence being 55 years (age range 17-88 years) [21].

Our patient was postmenopausal. She doesn't have a predisposing factor. Pelvic inflammatory disease, nulliparity and subfertility were not present in our case.

The clinical symptoms and signs of PFTC are not specific. The most common symptoms and signs are abdominal pain, which may be colicky as a result of forced tubal peristalsis or dull as a result of tubal distension and vaginal bleeding or watery discharge [22]. The Latzko's triad of typical symptoms consists of intermittent profuse serosanguinous vaginal bleeding, colicky pain relieved by discharge and an abdominal or pelvic mass. This triad was reported in only 15% of PFTC cases [14].

In our case, all of these symptoms were presented. In most cases, the preoperative diagnosis of PFTC is extremely rare [23]. The rate of preoperative diagnosis was in the range of 0%-10% [24], and up to 50% are missed intraoperatively [25].

PFTC should be included in the differential diagnosis and if the patient has clinical symptoms such as vaginal discharge or abnormal genital bleeding or spotting with negative diagnostic curettage. Pap smear positivity occurs in 10%-36% of cases [14, 26].

In our patient diagnostic curettage and Pap smear were negative. The CA-125 level is raised. CA-125 is a useful tumour marker for the diagnosis, assessment of response to treatment and detection of tumour recurrence during follow-up. 80% of patients with PFTC have elevated pretreatment serum levels of CA 125 [27].

The diagnostic criteria for PFTC were first established by Hu and colleagues and later slightly modified by Sidles. Accordingly, PFTC is diagnosed if: grossly, the main tumor is in the tube and arises from the endo salpinx; the histological pattern reproduces the epithelium of tubal mucosa; transition from benign to malignant tubal epithelium should be demonstrated, and ovaries and endometrium are either normal or have a much smaller tumor volume than that of the tube [28, 29].

Approximately 90% of ovarian cancers are carcinomas (malignant epithelial tumors) and based on histopathology, immunohistochemistry and molecular genetic analyzes, at least 5 main types are currently distinguished: high-grade serous carcinoma (HGSC, 70%); endometrioid carcinoma (EC, 10%); clear-cell carcinoma (CCC, 10%); mucinous carcinoma (MC, 3%); and low-grade serous carcinoma (LGSC, <5%) [30].

Imaging for suspected gynecologic malignancies includes ultrasound, computed tomography (CT) scan and magnetic resonance imaging (MRI) of the abdomen. Transvaginal and transabdominal ultrasound is the simplest and usually initial imaging investigation. Although the ultrasound

findings of tubal carcinoma are nonspecific and mimic other pelvic diseases such as an ovarian tumour or tube-ovarian abscess, several findings may provide a diagnostic clue preoperatively. The echogram may show a cystic mass with spaces and mural nodules, a sausage-shaped mass or a multilobular mass with a cog-and-wheel appearance [31, 32].

The lesion can have the appearance of a small, solid, lobulated mass on CT scan or MRI. On CT scan, a solid papillary intratubal mass allows for easy prediction of PFTC. MRI is considered a better method than CT or ultrasound for detecting tumour infiltration of extramural organs [33].

Surgery is the treatment of choice for PFTC and is similar to that for ovarian carcinoma-cytoreductive surgery with the removal of the tumour as much as possible. The procedure of choice is total abdominal hysterectomy, bilateral salpingo-oophorectomy, omentectomy, selective pelvic and para-aortic lymphadenectomy for any stage of fallopian tube carcinoma [9, 13]. Postoperative platinum-based combination adjuvant chemotherapy is the most commonly used therapy for these patients, similar to EOC patients. The role of postoperative radiotherapy is even less clear [4, 9].

The reported overall responses rates are 53-92%. The stage of disease at the time of diagnosis is the most important factor affecting the prognosis [6]. The other prognostic factors include the residual volume of the tumour after cytoreduction, the presence of ascites and the histologic grade of the tumour [6, 9].

In conclusion, primary fallopian tube carcinoma is a rare gynecologic malignancy that accounts for less than 1% of all malignancies of the female genitalia. Preoperative diagnosis of fallopian tube carcinoma is difficult due to the silent course of this neoplasm and is usually first appreciated at the time of operation or by a pathologist. PFTC histologically and clinically resembles epithelial ovarian carcinoma. The symptom complex of "hydrops tube pro fluenta" said to be pathognomonic for this tumour, is rarely encountered. It should be considered in differential diagnosis of peri and postmenopausal women who present with unexplained uterine bleeding, pelvic pain, adnexal mass, abnormal cervical smear and complicated pelvic inflammatory disease. The treatment approach is similar to that of ovarian carcinoma, and it should consist of a total abdominal hysterectomy with bilateral salpingo-oophorectomy, omentectomy and lymph node dissection from the pelvic and the para-aortic regions.

References

1. Kalampokas E, Kalampokas T, Tourontous I. Primary fallopian tube carcinoma. *Eur J Obstet Gynecol Reprod Biol.* 2013; 169:155-

61. <https://doi.org/10.1016/j.ejogrb.2013.03.023> PMID:23622731
2. Lau HY, Chen YJ, Yen MS, et al. Primary fallopian tube carcinoma: a clinicopathologic analysis and literature review. *J Chin Med Assoc.* 2013;76(10):583-7. <https://doi.org/10.1016/j.jcma.2013.06.010> PMID:23890835
3. Ma Y, Duan W., Clinical and survival analysis of 36 cases of primary fallopian tube carcinoma. *World Journal of Surgical Oncology.* 2014;12(1):311. <https://doi.org/10.1186/1477-7819-12-311> PMID:25307473 PMCid:PMC4200227
4. Pectasides D, Pectasides E, Economopoulos T. Fallopian tube carcinoma: a review. *Oncologist.* 2006; 11(8):902-12. <https://doi.org/10.1634/theoncologist.11-8-902> PMID:16951394
5. Horng HC, Teng SW, Huang BS, et al. Primary fallopian tube cancer: domestic data and up-to-date review. *Taiwan J. Obstet Gynecol.* 2014; 53(3):287-92. <https://doi.org/10.1016/j.tjog.2014.07.003> PMID:25286779
6. Hariprasad PSH, Srinivas T, Shetty KJJ. Primary bilateral fallopian tube carcinoma the report of a single case with review of the literature. *Clin Diagn Res.* 2013;7(5):930-2. <https://doi.org/10.7860/jcdr/2013/5483.2980>
7. Orthmann EG. Primareskarzinom in Einertuberkulosen. *Ztschr Geburtsh Gynaek.* 1888; 15:212.
8. Riska A, Leminen A. Determinants of incidence of primary fallopian tube carcinoma (PFTC). *Methods Mol Biol.* 2009;472:387-96. https://doi.org/10.1007/978-1-60327-492-0_18 PMID:19107444
9. Berek S.J, Crum Ch, Friedlander M, Cancer of the ovary, fallopian tube, and peritoneum *International Journal of Gynecology & Obstetrics.* 2015; 131(2):S111–S122.
10. Mladenovic-Segedi L. Primary fallopian tube carcinoma. *Med Pregled.* 2009; 62(1-2): 31-6 <https://doi.org/10.2298/MPNS0902031M> PMID:19514598
11. Howitt BE, Hanamornroongruang S, Lin DI, Conner JE, Schulte S, Horowitz N, Crum CP, Meserve EE. Evidence for a dualistic model of high-grade serous carcinoma: BRCA mutation status, histology, and tubal intraepithelial carcinoma. *Am J Surg Pathol.* 2015;39(3):287-93. <https://doi.org/10.1097/PAS.0000000000000369> PMID:25581732
12. Quartuccio SM, Karthikeyan S, Eddie SL et al., Mutant p53 expression in fallopian tube epithelium drives cell migration. *Int J Cancer.* 2015; 137(7):1528-38. <https://doi.org/10.1002/ijc.29528> PMID:25810107 PMCid:PMC4503498
13. Gomes FV, Dias JL, Lucas R, Cunha TM. Primary fallopian tube carcinoma: review of MR imaging findings. *Insights Imaging.* 2015; 6:431–439. <https://doi.org/10.1007/s13244-015-0416-y> PMID:26150249 PMCid:PMC4519813
14. Lau H-Y. Primary fallopian tube carcinoma: a clinicopathologic analysis and literature review. *J Chin Med Assoc.* 2013;76(10):583-7. <https://doi.org/10.1016/j.jcma.2013.06.010> PMID:23890835
15. Jeung ICh, Lee YS, Lee HN, et al. Primary Carcinoma of the Fallopian Tube: Report of Two Cases with Literature Review, *Cancer Research and Treatment.* 2009; 41(2):113-6. <https://doi.org/10.4143/crt.2009.41.2.113> PMID:19707511 PMCid:PMC2731206
16. Puig F, Lapresta M, Lanzon A, Crespo R. Fallopian tube carcinoma: incidental finding during surgery for acute pelvic inflammatory disease--case report. *Eur J Gynaecol Oncol.* 2006; 27(5):526-7. PMID:17139993
17. Nordin AJ. Primary carcinoma of the fallopian tube: a 20-year literature review. *Obstet Gynecol Surv.* 1994; 49(5):349-61. <https://doi.org/10.1097/00006254-199405000-00026> PMID:8015756
18. Kalyani R, Kumar ML, Srikanthia SH. Primary adenocarcinoma of fallopian tube-a case report. *Indian J Pathol Microbiol.* 2005;48(2):219-21. PMID:16758673
19. Tahiri Elousrouti L, Erragad FZ, Jayi S, et al. Primary Adenocarcinoma of the Fallopian Tube: Report of Two Cases. *Journal of Clinical Case Reports.* 2016; 6:5.
20. Moore KN, Moxley KM, Fader AN, et al. Serous fallopian tube carcinoma: a retrospective, multi-institutional case-control comparison to serous adenocarcinoma of the ovary. *Gynecol Oncol.* 2007;107:398–403. <https://doi.org/10.1016/j.ygyno.2007.09.027> PMID:17997146
21. Jeung IC, Lee YS, Lee HN, Park EK. Primary carcinoma of the fallopian tube: report of two cases with literature review. *Cancer Res Treat.* 2009;41(2):113-6. <https://doi.org/10.4143/crt.2009.41.2.113> PMID:19707511 PMCid:PMC2731206
22. Horng HC, Teng SW, Huang BS, et al. Primary fallopian tube cancer: domestic data and up-to-date review. *Obstet Gynecol.* 2014;53(3):287-92. <https://doi.org/10.1016/j.tjog.2014.07.003>
23. Koo, Yu-Jin K, Kyoung-Shil I, Yong-Soon K. Primary fallopian tube carcinoma: a clinicopathological analysis of a rare entity, *International Journal of Clinical Oncology.* 2011; 16(1):45-49. <https://doi.org/10.1007/s10147-010-0128-8> PMID:20878435
24. Huber-Buchholz MM, Buchholz NP, Staehelin JJ. Analysis of 23 cases of primary carcinoma of the fallopian tube over 50 years. *Obstet Gynaecol Res.* 1996;22(3):193-9. <https://doi.org/10.1111/j.1447-0756.1996.tb00966.x>
25. Cheng Horng H, Teng S.W, Huang B. Primary fallopian tube cancer: Domestic data and up-to-date review, *Taiwanese Journal of Obstetrics and Gynecology.* 2014; 53(3):287–292. <https://doi.org/10.1016/j.tjog.2014.07.003> PMID:25286779
26. Chaudhry S, Hussain R, Zuberi MM, Zaidi ZJ. Rare primary fallopian tube carcinoma; a gynaecologist's dilemma. *Pak Med Assoc.* 2016;66(1):107-10.
27. Chaudhry S, Hussain R, Zuberi MM, Zaidi Z. Rare primary fallopian tube carcinoma; a gynaecologist's dilemma. *J Pak Med Assoc.* 2016;66(1):107-10. PMID:26712194
28. Hu, CY, Taymor, ML, and Hertig, AT. Primary carcinoma of the fallopian tube. *Am J Obstet Gynecol.* 1950; 50: 58–67. [https://doi.org/10.1016/0002-9378\(50\)90341-3](https://doi.org/10.1016/0002-9378(50)90341-3)
29. Sedlis A. Carcinoma of the fallopian tube. *Surg Clin North Am.* 1978; 58: 121–129. [https://doi.org/10.1016/S0039-6109\(16\)41439-8](https://doi.org/10.1016/S0039-6109(16)41439-8)
30. Saida T, Tanaka YO, Matsumoto K, Satoh T, Yoshikawa H, Minami M. Revised FIGO staging system for cancer of the ovary, fallopian tube, and peritoneum: important implications for radiologists. *Jpn J Radiol.* 2016;34(2):117-24. <https://doi.org/10.1007/s11604-015-0513-3> PMID:26696400
31. Ludovisi M, De Blasis I, Virgilio B, Fischerova D, Franchi D, Pascual MA, Savelli L, Epstein E, Van Holsbeke C, Guerriero S, Czekierdowski A, Zannoni G, Scambia G, Jurkovic D, Rossi A, Timmerman D, Valentin L, Testa AC. Imaging in gynecological disease (9): clinical and ultrasound characteristics of tubal cancer. *Ultrasound Obstet Gynecol.* 2014;43(3):328-35. <https://doi.org/10.1002/uoq.12570> PMID:23893713
32. Balaya. V, Metzger U, Lecuru F. Ultrasonographic features in the preoperative diagnosis of primitive fallopian tube carcinoma. *J Gynecol Obstet Biol Reprod (Paris).* 2016;45(1):11-20. <https://doi.org/10.1016/j.jgyn.2015.06.023> PMID:26183176
33. Katabathina VS, Amanullah FS, Menias CO, Chen MM, Valente PT, Chintapalli KN, Prasad SR. Extruterine Pelvic Serous Carcinomas: Current Update on Pathology and Cross-sectional Imaging Findings. *Radiographics.* 2016;36(3):918-32. <https://doi.org/10.1148/rq.2016150130> PMID:27163599