

Histopathological Features of Methotrexate Induced Pulmonary Lesions in Rheumatoid Arthritis Patients: A Systematic Review of Case Reports

Anthony Thaniyan^{1*}, Foad F. A. Ayman², Hyder O. Mirghani³, Badr A. Al-Sayed³, Tarig H. Merghani⁴

¹Department of Pharmacology, Faculty of Medicine, University of Tabuk, Saudi Arabia; ²Department of Pathology, Faculty of Medicine, University of Tabuk, Saudi Arabia; ³Department of Medicine, Faculty of Medicine, University of Tabuk, Saudi Arabia; ⁴Department of Physiology, Faculty of Medicine, University of Tabuk, Saudi Arabia

Abstract

Citation: Thaniyan A, Ayman FFA, Mirghani HO, Al-Sayed BA, Merghani TH. Histopathological Features of Methotrexate Induced Pulmonary Lesions in Rheumatoid Arthritis Patients: A Systematic Review of Case Reports. Open Access Maced J Med Sci. 2017 Apr 15; 5(2):266-270. <https://doi.org/10.3889/oamjms.2017.049>

Keywords: Methotrexate; Pulmonary; Histopathology; Rheumatoid arthritis; Case reports.

***Correspondence:** Dr Antony Thaniyan. Department of Pharmacology, Faculty of Medicine, University of Tabuk. P.O. BOX. 741, Postal code 71491, Tabuk, Saudi Arabia. FAX: +966-4-44262597. E-mail: thaniyan1@gmail.com

Received: 11-Feb-2017; **Revised:** 02-Mer-2017; **Accepted:** 04-Mar-2017; **Online first:** 08-Apr-2017

Copyright: © 2017 Antony Thaniyan, Foad F. A. Ayman, Hyder O. Mirghani, Badr A. Al-Sayed, Tarig H. Merghani. This is an open-access article distributed under the terms of the Creative Commons Attribution-NonCommercial 4.0 International License (CC BY-NC 4.0).

Funding: This research did not receive any financial support.

Competing Interests: The authors have declared that no competing interests exist.

BACKGROUND: Methotrexate (MTX) is the most commonly used disease-modifying drug in the treatment of rheumatoid arthritis (RA); however, it causes many side effects, including pulmonary lesions. In this review, we characterised the histopathological features of MTX-induced pulmonary lesions in RA patients.

AIM: We carried out an electronic search of the relevant literature published during the period from 1990 to 2016. We included only the cases with definitive histo-pathological findings caused by MTX therapy.

MATERIAL AND METHODS: The total number of cases is 27. Male: female ratio was 1:3, and ages ranged from 48 to 87 years old, with a mean (SD) = 65.7 (1.0). The cases were originally from Asia (55%), Europe (41%), and America (4%). The major complications of methotrexate therapy were lymphoproliferative disorders (42%) followed by interstitial fibrosis (33), and infections (25%). The incidence of these complications significantly increases with the duration of MTX treatment ($p = 0.044$). Among the infections, the most common causative organism was pneumocystis jiroveci. The majority of patients who developed infections following methotrexate therapy were from Europe whereas the majority of those who developed lymphoproliferative disorders were from Asia ($p = 0.003$).

CONCLUSION: In conclusion, methotrexate therapy in rheumatoid arthritis patients causes different types pulmonary complications.

Introduction

Rheumatoid arthritis (RA) is a systemic inflammatory disorder with articular and extra-articular manifestations. The pulmonary complications are a well-recognized extra-articular manifestation of RA and important cause of morbidity and mortality [1]. They include interstitial lung disease, pleural thickening, pleural effusions, airways obstruction, pulmonary vasculitis and pulmonary hypertension. Post-mortem evaluation in RA patients showed a possibility of 50% prevalence of pleural involvement [2].

The lung involvement in these patients is not always due to the systemic effects of the disease; the therapeutic agents, as well as other causes, are also

contributing to the pulmonary parenchymal damage as adverse side effects. Methotrexate (MTX) is one of the widely used drugs in many autoimmune diseases, holds a first line drug status in the management of rheumatoid arthritis patients, and holds the longest duration of a therapeutic segment [3, 4]. In many clinical trials, methotrexate has been found as an effective immunosuppressive agent that efficiently slows the progression of the disease; however, it causes many side effects such as alopecia, stomatitis, gastrointestinal toxicity, liver function abnormalities, and pulmonary lesions [4].

About 2-7% pulmonary involvement has been reported in previous literature, even with a low dose of MTX. The reported incidence of pulmonary toxicity with methotrexate in RA patients is higher than that of liver toxicity. The most prevalent induced MTX

pulmonary complication is the acute hypersensitivity pneumonitis [5]. It is estimated that acute pulmonary toxicity develops in about 12.5% of patients on methotrexate therapy for all rheumatic conditions, including rheumatoid arthritis, but other studies suggest an incidence as high as 33% [6, 7]. Table 1 lists the major and the minor criteria for the diagnosis of MTX-induced pulmonary complication in rheumatoid arthritis patients, and how definite or probable cases are diagnosed [8]. In correlation with clinical features, the histopathological features can be valuable in diagnosing drug-induced lung toxicity and in guiding treatment interventions. Although the surgical lung biopsy is usually large enough to allow the pathologist to give a complete description of the pulmonary process, a minimally invasive procedure, such as bronchoscopic biopsy or Broncho-alveolar Lavage (BAL), can provide valuable data [9, 10]. The histopathological features of MTX-induced pulmonary lesions vary from patient to patient, and the present evidence provide no definite characteristic for pulmonary involvement in these patients [11]. In this review of case reports, the main objective is to characterise the histo-pathological features of MTX-induced pulmonary lesions in RA patients and to investigate the association with the demographic features and the duration of treatment.

Table 1: Diagnostic criteria for the adverse pulmonary events associated with methotrexate treatment in rheumatoid arthritis patients [8]

Major	
1.	Hypersensitivity pneumonitis by histo-pathologic examination (and without evidence of pathogenic organisms)
2.	Radiologic evidences of pulmonary interstitial or alveolar infiltrates
3.	Blood (if febrile) and initial sputum (if produced) cultures negative for pathogenic organisms
Minor	
1.	Shortness of breath of <8weeks duration
2.	Non-productive cough
3.	O ₂ saturation ≤ 90% at the time of initial evaluation on room air
4.	DLCO (Diffusing capacity of carbon monoxide) ≤ 70% of that predicted for age
5.	WBC (White blood cell count) ≤ 15000 per mm ³
	• Definite cases were defined as the presence of major criteria 1, or major 2 and 3 and 3 of 5 minor criteria
	• Probable cases: Presence of major criteria 2 and 3 and 2 minor criteria

Methodology

An electronic search is carried out for the relevant literature published during the period from 1990 to 2016 in the databases of COCHRANE Review, MEDLINE Ovid (from 1990 to 2015 November 25), CINAHL PLUS, Scopus and EMBASE. The following search terms “methotrexate” “rheumatoid arthritis” “lung lesions” “lung complications” “pulmonary lesions” and „pulmonary complications” were used along with appropriate Boolean operators such as AND or OR. The further search criteria were the articles in English language and human adults. Also, we used forward as well as backwards chaining for the relevant articles cited in retrieved publications to get relevant results. We included the case reports

of adult rheumatoid arthritis patients on methotrexate treatment and with findings on histopathology of lung lesions. The excluded articles were those reporting pulmonary complications due to pulmonary toxic agents other than methotrexate. Two authors independently searched and retrieved the articles for the second stage selection process of reading the title and abstract to avoid duplication. During second stage evaluation, the same authors analysed for the availability of required data in the evidence.

Inclusion criteria

1. Case reports on adult rheumatoid arthritis patients on methotrexate treatment; 2. Case reports with data on histopathology of lung lesions; and 3. Articles on both seropositive and negative rheumatoid arthritis patients

Exclusion criteria

1. The use of pulmonary toxic agents other than methotrexate and 2. Articles without a description of histo-pathological features of lesions.

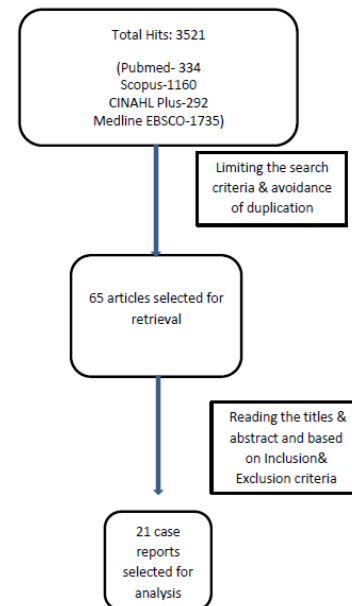


Figure 1: Flow chart of events in literature search

After removing duplication and reading abstracts of retrieved articles, the relevant evidence were selected based on the above inclusion and exclusion criteria. The data extracted from the selected articles were the type of study, year of publication, population studied (country), the number of patients, age and gender of patients, dose and duration of MTX treatment, and pathological characters/ features of the lesions. The relevant data were analysed using the Statistical Package for the Social Sciences (SPSS Inc., Chicago, IL) version 20.

Table 2: Descriptions of evidence selected for analysis

Author /Year/Reference	Country	Gender	Age	MTX Dose	Duration	Type of infection
Cormelissen, et al., 1991 [12]	England	Female	71	Low	9	Nocardia Infections
Hilliquin & Menkes, 1991 [13]	France	*		Low	*	E.coli Infections
Hilliquin & Menkes, 1991 [13]	France	*		Low	*	Pneumocystis jiroveci
Hilliquin & Menkes, 1991 [13]	France	*		Low	*	Pneumocystis jiroveci I
Wollner et al., 1991 [14]	England	Female	59	Low	*	Pneumocystis jiroveci
Okuda et al., 1995 [15]	Japan	Female	70	Low	2.5	Pneumocystis jiroveci
Roux et al., 1996 [16]	France	Female	62	Low	7	Pneumocystis jiroveci
Roux et al., 1996 [16]	France	Female	85	Low	8	Pneumocystis jiroveci
Schnabel et al., 1997 [17]	England	Female	59	High	*	Pneumocystis jiroveci
Schnabel et al., 1997 [17]	England	Female	66	Low	*	Interstitial Pneumonitis
Schnabel et al., 1997 [17]	England	Female	60	Low	*	Interstitial Pneumonitis
Schnabel et al., 1997 [17]	England	Male	57	Low	*	Interstitial Pneumonitis
Eboe et al., 2003 [18]	USA	Male	54	Low	60	Lymphoproliferative
Hsu et al., 2003 [19]	Taiwan	Female	55	Low	54	Interstitial fibrosis
Shimada et al., 2004 [20]	Japan	Male	64	Low		Interstitial fibrosis
Cho et al., 2007 [9]	Japan	Male	66	Low	5	Interstitial fibrosis
Kameda et al., 2007 [21]	Japan	Male	71	Low	24	Lymphoproliferative
Shimada et al., 2007 [22]	Japan	Female	54	Low	120	Lymphoproliferative
Minagawa et al., 2008 [23]	Japan	Female	62	Low	*	Interstitial fibrosis
Inaba et al., 2011 [24]	Japan	Male	76	Low	*	Lymphoproliferative
Kudoh et al., 2014 [25]	Japan	Female	75	Low	60	Lymphoproliferative
Sakai et al., 2014 [26]	Japan	Female	87	Low	120	Lymphoproliferative
Tokuyama et al., 2014 [27]	Japan	Female	68	Low	18	Lymphoproliferative
Yamakawa et al., 2014 [28]	Japan	Male	78	Low	*	Lymphoproliferative
Tajima et al., 2015 [29]	Japan	Female	64	Low	142	Lymphoproliferative
Akiyama et al., 2015 [30]	Japan	Female	56	Low	24	Lymphoproliferative
Koji et al., 2016 [31]	Japan	Female	48	Low	572	Lymphoproliferative

* Not Mentioned

Results

The initial total number of search hits was 3521 articles. After removing duplications and irrelevant results, the number was reduced to 64 articles. Then after revision of the contents and application of the inclusion and exclusion criteria, a total of 21 pieces of evidence were selected for analysis (Fig 1).

Twelve pieces of evidence (44%) were published during 1990-2000 and 15(56%) evidence during 2001-2016. Three pieces of evidence presented data of more than one patient, and the total number of cases reached 27 (Table 2).

Male: female ratio was 1:3, ages ranged from 48 to 87 years old, with a mean (SD) = 65.7 (1.0). The cases were originally from Asia (55%), Europe (41%), and America (4%) (Fig. 2).

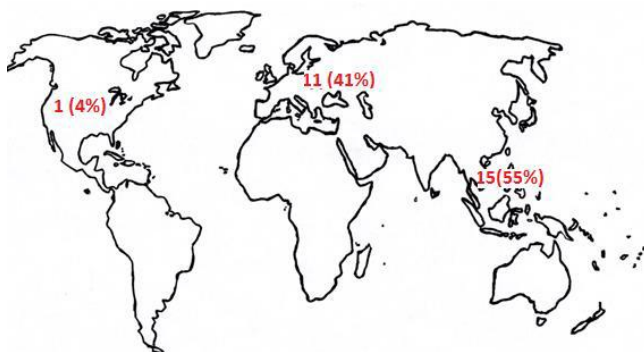


Figure 2: Regional distribution of the case reports

Table 3 shows that the major complications of methotrexate therapy were the lymphoproliferative

disorders (42%) followed by interstitial fibrosis (33), and infections (25%), with the insignificant difference between the male and female cases ($p = 0.191$).

Table 3: Pulmonary Complications of methotrexate therapy about gender of the reported cases

Complication	Male	Female	Total
Infections	0 (0%)	6 (25%)	6 (25%)
Interstitial fibrosis	3 (13%)	5 (21%)	8 (33%)
Lymphoproliferative disorders	4 (17%)	6 (25%)	10 (42%)

P = 0.191.

After exclusion of the missing values, the duration of treatment had a significant effect on the type of pulmonary complications ($P = 0.044$), Table 4.

Table 4: Complications of methotrexate therapy in relation to duration of treatment

Complication	< 6 month	6 – 18 month	> 18 month
Infections	1 (7%)	3 (21%)	0 (0%)
Interstitial fibrosis	1 (7%)	0 (0%)	2 (14%)
Lymphoproliferative disorders	0 (0%)	1 (7%)	6 (43%)

P = 0.044.

The majority of patients who developed infections following methotrexate therapy were from Europe whereas the majority of those who developed lymphoproliferative disorders were from Asia (Table 5). The regional distribution of these lesions was statistically significant ($P = 0.003$).

Table 5: Regional incidence of MTX induced pulmonary complications

Complication	Europe	Asia	America	Total
Infections	8 (30%)	1 (4%)	0 (0%)	9 (33%)
Interstitial fibrosis	3 (11%)	5 (18%)	0 (0%)	8 (30%)
Lymphoproliferative disorders	0 (0%)	9 (33%)	1 (4%)	10 (37%)

P = 0.003.

Discussion

Methotrexate (MTX) is the most common disease modifying anti-rheumatoid drug (DMARD) used in the treatment of RA patients. It is metabolised intracellularly to polyglutamate, which inhibit dihydro folate reductase enzyme and other folate-dependent enzymes and ultimately causes inhibition of chemotaxis and pro-inflammatory cytokine activity such as IL-1, IL-2 and IL-6 [32]. It exerts both an anti-inflammatory and immune-modulating effects for the management of rheumatoid arthritis [33]. The lung biopsy performed in patients with MTX pneumonitis has demonstrated interstitial inflammation, fibrosis, granulomas, giant cells, tissue eosinophils, type II pneumocyte hyperplasia and increased intra-alveolar macrophages [34]. The lung injury induced by methotrexate are due to several factors such as interference in folate metabolism by methotrexate, hypersensitivity reaction to the drug, and impaired immunity which predisposes to infection [8, 35].

In this review, the authors identified 21 articles on case reports describing the details of 27 patients who developed pulmonary lesions while receiving methotrexate for the treatment of rheumatoid arthritis. The case reports of 12 patients were reported during 1990-2000, and the remaining cases were reported during the period between 2001 and 2016. The majority of evidence (55%) are published from the Asian continent, followed by Europe. Among the nations, the Japanese patients are the most dominant. However, this distribution does not reflect the geographical prevalence of RA. With the exclusion of 3 unmentioned data about the gender of some patients, a higher rate of pulmonary complications are reported among the females compared to the males. This gender variation in MTX-induced pulmonary lesions is most probably due to the higher prevalence of RA among the females compared to the males [36].

We found an insignificant age-related difference in the development of pulmonary complications due to MTX therapy. The histopathological examinations of lung biopsy samples in this review revealed three major categories of pulmonary lesions: infections (25%), interstitial fibrosis (33%) and lymphoproliferative disorders (42%). The high incidence of lymphoproliferative disorders may be due to the propensity of RA Patients to develop Epstein Barr viral infection, secondary to methotrexate induced iatrogenic immunodeficiency [35]. The incidence of these disorders significantly increases with the duration of MTX treatment. However, there is no significant gender-related difference for these lesions. Among the infections, the most common causative organism was *pneumocystis jiroveci*, which affected seven patients of the infection group. The superimposed pulmonary infection attributed to the immunosuppressive status with opportunistic

infectious agents, notably pneumocystis and nocardia, is one of the prime notified complication associated with MTX therapy [34]. The incidence of infection is higher in European region when compared to other regions whereas the incidence of lymphoproliferative disorders is higher among the Asian patients.

In this study, we could not exclude the pulmonary effects of the other medications that were used in combination with the MTX, and not excluded because they are not known to be pulmo-toxic. On the other hand, the exclusion of the patients who received known pulmo-toxic agents in addition to methotrexate caused a large reduction in the number of our cases. Another limitation of this study are the direct effects of rheumatoid arthritis on the pleura and lung parenchyma. Also, the impure preparation of methotrexate in some laboratories is a recognised cause of toxicity [33].

In conclusion, methotrexate therapy in rheumatoid arthritis patients causes three categories of pulmonary lesions: lymphoproliferative disorders (42%), interstitial fibrosis (33), and infections (25%). The incidence of these complications significantly increases with the duration of MTX treatment. Among the infections, the most common causative organism was pneumocystis jiroveci. Further reviews are recommended to evaluate its side effects in comparison with the side effects of the other immunosuppressive agents.

References

1. Bilgici A, Ulusoy H, Kuru O, Celenk C, Unsa M, and Danaci M. Pulmonary involvement in rheumatoid arthritis. *Rheumatol Int.* 2005;25: 429-435. <https://doi.org/10.1007/s00296-004-0472-y> PMID:16133582
2. Corcoran JP, Ahmad M, Mukherjee R, et al. Pleuro-pulmonary complications of rheumatoid arthritis. *Respir Care.* 2014;59: e55–e59. <https://doi.org/10.4187/respcare.02597> PMID:23962501
3. Ortendahl M, Holmes T, Schettler JD, and Fries JF. The methotrexate therapeutic response in rheumatoid arthritis. http://aramis.stanford.edu/downloads/MTX_Orten.pdf Accessed 2nd November 2015.
4. Cornstein, B. Low dose methotrexate: A mainstay in the treatment of rheumatoid arthritis. *Pharmacol Rev.* 2005;57:163–172. <https://doi.org/10.1124/pr.57.2.3> PMID:15914465
5. Provenzano G. Chronic pulmonary toxicity of methotrexate and rheumatoid arthritis. *Rheumatology.* 2003;42:802–803. <https://doi.org/10.1093/rheumatology/kep188> PMID:12771440
6. Saravanan V, Kelly C. Drug-related pulmonary problems in patients with rheumatoid arthritis. *Rheumatology (Oxford).* 2006;45:787. <https://doi.org/10.1093/rheumatology/kei075> PMID:16527879
7. Amital H, Arnson Y, Chodick G, Shalev V. Hepatotoxicity rates do not differ in patients with rheumatoid arthritis and psoriasis treated with methotrexate. *Rheumatology.* 2009;48:1107–1110. <https://doi.org/10.1093/rheumatology/kep176> PMID:19578136
8. Kremer JM, Alarcon GS, Weinblatt ME et al. Clinical, laboratory, radiographic, and histopathologic features of methotrexate-associated lung injury in patients with rheumatoid arthritis: a multicenter study with literature review. *Arthritis Rheum.*

- 1997;40(10):1829–37. <https://doi.org/10.1002/art.1780401016> PMID:9336418
9. Cho I, Mori S, Imamura F, Kiyofuji C, Sugimoto M. Methotrexate pneumonia lacking dyspnea and radiographic interstitial patterns during treatment for early rheumatoid arthritis: bronchoalveolar lavage and transbronchial lung biopsy in a differential diagnosis. *Mod Rheumatol*. 2007;17(3):256–261. <https://doi.org/10.3109/s10165-007-0578-7> PMID:17564786
10. Romagnoli M, Bigliuzzi C, Casoni G, et al. The role of transbronchial lung biopsy for the diagnosis of diffuse drug-induced lung disease: a case series of 44 patients. *Sarcoidosis Vasc Diffuse Lung Dis*. 2008;25:36–45. PMID:19070259
11. Padley SP, Adler B, Hansell DM, Muller NL. High-resolution computed tomography of drug-induced lung disease. *Clin Radiol*. 1992;46:232–6. [https://doi.org/10.1016/S0009-9260\(05\)80161-8](https://doi.org/10.1016/S0009-9260(05)80161-8)
12. Cornelissen JJ, Bakker LJ, Van der Veen MJ, Rozenberg-Arska M, Bijlsma JW. Nocardia asteroides pneumonia complicating low dose methotrexate treatment of refractory rheumatoid arthritis. *Ann Rheum Dis*. 1991;50(9):642–644. <https://doi.org/10.1136/ard.50.9.642> PMID:1929588 PMID:PMC1004510
13. Hilliquin P, Menkes CJ. Lung diseases and treatment with methotrexate in rheumatoid arthritis. *Rev Pneumol Clin*. 1991;47(4):179–182. PMID:1775874
14. Wollner A, Mohle-Boetani J, Lambert RE, Perruquet JL, Raffin TA, McGuire JL. Pneumocystis carinii pneumonia complicating low dose methotrexate treatment for rheumatoid arthritis. *Thorax*. 1991;46(3):205–207. <https://doi.org/10.1136/thx.46.3.205> PMID:2028435 PMID:PMC463037
15. Okuda Y, Oyama T, Oyama H, Miyamoto T, Takasugi K. Pneumocystis carinii pneumonia associated with low dose methotrexate treatment for malignant rheumatoid arthritis. *Ryumachi*. 1995;35(4):699–704. PMID:7482069
16. Roux N, Flipo RM, Cortet B, et al. Pneumocystis carinii pneumonia in rheumatoid arthritis patients treated with methotrexate. A report of two cases. *Rev Rhum Engl Ed*. 1996;63(6):453–456. PMID:8817757
17. Schnabel A, Richter C, Bauerfeind S, Gross WL. Bronchoalveolar lavage cell profile in methotrexate induced pneumonitis. *Thorax*. 1997;52(4):377–379. <https://doi.org/10.1136/thx.52.4.377> PMID:9196524 PMID:PMC1758545
18. Ebeo CT, Girish MR, Byrd RP, Roy TM, Mehta JB. Methotrexate-induced pulmonary lymphoma. *Chest*. 2003;123(6):2150–2153. <https://doi.org/10.1378/chest.123.6.2150> PMID:12796204
19. Hsu P-C, Lan J-L, Hsieh T-Y, Jan Y-J, Huang W-N. Methotrexate pneumonitis in a patient with rheumatoid arthritis. *J Microbiol Immunol Infect*. 2003;36(2):137–140. PMID:12886966
20. Shimada T, Nishimura Y, Funada Y, et al. A case of pneumocystis carinii pneumonia associated with low dose methotrexate treatment for rheumatoid arthritis and trimethoprim-sulphamethoxazole induced pancytopenia. *Arerugi*. 2004;53(6):575–581. PMID:15247519
21. Kameda H, Okuyama A, Tamaru J-I, Itoyama S, Iizuka A, Takeuchi T. Lymphomatoid granulomatosis and diffuse alveolar damage associated with methotrexate therapy in a patient with rheumatoid arthritis. *Clin Rheumatol*. 2007;26(9):1585–1589. <https://doi.org/10.1007/s10067-006-0480-2> PMID:17200802
22. Shimada K, Matsui T, Kawakami M, et al. Methotrexate-related lymphomatoid granulomatosis: a case report of spontaneous regression of large tumours in multiple organs after cessation of methotrexate therapy in rheumatoid arthritis. *Scand J Rheumatol*. 2007;36(1):64–67. <https://doi.org/10.1080/03009740600902403> PMID:17454938
23. Minagawa S, Takayanagi N, Hara K, et al. A case of rheumatoid arthritis complicated with methotrexate-induced pneumonitis and pneumocystis pneumonia. *zasshi = J Japanese Respir Soc*. 2008;46(3):237–242.
24. Inaba M, Ushijim S, Hirata N, Saisyoji T, Kitaoka M, Yoshinaga T. Methotrexate-related lymphomatoid granulomatosis in a patient with rheumatoid arthritis. *Nihon zasshi = J Japanese Respir Soc*. 2011;49(8):597–601.
25. Kudoh M, Harada H, Matsumoto K, Sato Y, Omura K, Ishii Y. Methotrexate-associated lymphoproliferative disorder arising in the retromolar triangle and lung of a patient with rheumatoid arthritis. *Oral Surg Oral Med Oral Pathol Oral Radiol*. 2014;118(4):e105–e110. <https://doi.org/10.1016/j.oooo.2014.02.029> PMID:24811204
26. Sakai T, Tamura S, Miyoshi T, Nesumi N, Nagai K, Oshima K. Development of myeloid sarcoma after long-term methotrexate use for rheumatoid arthritis. *Int J Hematol*. 2014;99(4):493–498. <https://doi.org/10.1007/s12185-014-1506-1> PMID:24504437
27. Tokuyama K, Okada F, Matsumoto S, et al. EBV-positive MTX-diffuse large B cell lymphoma in a rheumatoid arthritis patient. *Jpn J Radiol*. 2014;32(3):183–187. <https://doi.org/10.1007/s11604-013-0280-y> PMID:24408079
28. Yamakawa H, Yoshida M, Katagi H, et al. Pulmonary and retroperitoneal lesions induced by methotrexate-associated lymphoproliferative disorder in a patient with rheumatoid arthritis. *Mod Rheumatol*. 2014;1(4). <https://doi.org/10.3109/14397595.2014.898559>
29. Tajima S, Takanashi Y, Koda K, Fukayama M. Methotrexate-associated lymphoproliferative disorder presenting as extranodal NK/T-cell lymphoma arising in the lungs. *Pathol Int*. 2015;65(12):661–665. <https://doi.org/10.1111/pin.12346> PMID:26459854
30. Akiyama N, Toyoshima M, Kono M, Nakamnuva Y, Funai K, and Suda T. Methotrexate induced accelerated pulmonary nodulosis. *Am J Respi Crit Care Med*. 2015;192(20):252–253.
31. Koji H, Yazawa T, Nakabayashi K, Fujioka Y, Kamma H, Yamada A. CD8-positive T-cell lymphoproliferative disorder associated with Epstein-Barr virus-infected B-cells in a rheumatoid arthritis patient under methotrexate treatment. *Mod Rheumatol*. 2016;26(2):271–275. PMID:24386983
32. Furst DE. The rational use of methotrexate in rheumatoid arthritis and other rheumatic diseases. *British Journal of Rheumatology*. 1997;36: 1196–1204. <https://doi.org/10.1093/rheumatology/36.11.1196> PMID:9402864
33. Balk RA. Methotrexate induced lung injury. *Wolters Kluwer*, 2016.
34. Imokawa S, Colby TV, Leslie KO, and Helmers RA. Methotrexate pneumonitis: review of the literature and histopathological findings in nine patients. *Eur Respir*. 2000;15: 373–381. <https://doi.org/10.1034/j.1399-3003.2000.15b25.x>
35. Gaulard P, Swerdlow SH, Harris L, Jaffe ES, Sundstrom C. Other iatrogenic immunodeficiency-associated lymphoproliferative disorders. WHO Classification of Tumours of Haematopoietic and Lymphoid Tissues, 4th edn. Lyon: IARC Press, 2008; 350–51.
36. Bajraktari IH, Teuta BC, Vjollca SM, Bajraktari H, Krasniqi VSB, Muslimi F. Demographic Features of Patients with Rheumatoid Arthritis in Kosovo. *Med Arch*. 2014;68(6): 407–410. <https://doi.org/10.5455/medarh.2014.68.407-410> PMID:25649180 PMID:PMC4314179