

# Treatment of Decubitus Ulcer Stage IV in the Patient with Polytrauma and Vertical Share Pelvic Fracture, Diagnosed Enterocolitis and Deep Wound Infection with *Clostridium Difficile* with Combined Negative Pressure Wound Therapy (NPWT) and Faecal Management System: Case Report

Slavcho Stojmenski<sup>1\*</sup>, Igor Merdzanovski<sup>1</sup>, Andrej Gavrilovski<sup>1</sup>, Sofija Pejškova<sup>2</sup>, Gjorge Dzokic<sup>2</sup>, Smilja Tudzarova<sup>2</sup>

<sup>1</sup>University Clinic for Traumatology, JZU – Clinic for TOARILUC, Medical Faculty, Ss Cyril and Methodius University of Skopje, Skopje, Republic of Macedonia; <sup>2</sup>University Clinic for Plastic and Reconstructive Surgery, Medical Faculty, Ss Cyril and Methodius University of Skopje, Skopje, Republic of Macedonia

## Abstract

**Citation:** Stojmenski S, Merdzanovski I, Gavrilovski A, Pejškova S, Dzokic G, Tudzarova S. Treatment of Decubitus Ulcer Stage IV in the Patient with Polytrauma and Vertical Share Pelvic Fracture, Diagnosed Enterocolitis and Deep Wound Infection with *Clostridium Difficile* with Combined Negative Pressure Wound Therapy (NPWT) and Faecal Management System: Case Report. Open Access Maced J Med Sci. 2017 Jun 15; 5(3):349-351. <https://doi.org/10.3889/oamjms.2017.060>

**Keywords:** decubitus ulcer stage iv; polytrauma; vertical share pelvic fracture; enterocolitis; deep wound infection; clostridium difficile; combined negative pressure wound therapy (NPWT); faecal management system.

**\*Correspondence:** Slavcho Stojmenski, University Clinic for Traumatology, JZU – Clinic for TOARILUC, Medical Faculty, Ss Cyril and Methodius University of Skopje, Skopje, Republic of Macedonia. E-mail: [stojmenski@on.net.mk](mailto:stojmenski@on.net.mk)

**Received:** 11-Feb-2017; **Revised:** 24-Mar-2017; **Accepted:** 30-Mar-2017; **Online first:** 03-Jun-2017

**Copyright:** © 2017 Slavcho Stojmenski, Igor Merdzanovski, Andrej Gavrilovski, Sofija Pejškova, Gjorge Dzokic, Smilja Tudzarova. This is an open-access article distributed under the terms of the Creative Commons Attribution-NonCommercial 4.0 International License (CC BY-NC 4.0).

**Funding:** This research did not receive any financial support.

**Competing Interests:** The authors have declared that no competing interests exist.

**AIM:** The aim of this paper was to present a case with the successful treatment of decubitus ulcer stage IV in the patient with polytrauma and vertical share pelvic fracture and diagnosed enterocolitis combined with deep wound infection with *Clostridium difficile* treated with combined Negative Pressure Wound Therapy (NPWT) and faecal management system.

**CASE REPORT:** Patient D.S.1967 treated on Traumatology Clinic after tentamen suicide on 9.2.2015 with diagnosis: brain contusion; contusion of thoracal space; vertical share pelvic fracture; open fracture type II of the right calcaneus; fracture of the left calcaneus; fracture on the typical place of the left radius; fracture of the right radius with dislocation. As a first step during the treatment in Intensive care unit we perform transcondylar extension of the left leg, and in that time we cannot operate because of the brain contusion. Four weeks after this treatment we intent to perform stabilisation of the pelvic ring, fixation of both arms, and fixation of both calcaneal bones. But at the time before performing the saurgery, the patient got an intensive enterocolitis from *Escherichia coli* and *Clostridium difficile*, and during the inadequate treatment of enterocolitis she got a big decubitus on both gluteal regia Grade IV and deep muscular necrosis. Several times we perform a necrectomy of necrotic tissue but the wound become bigger and the infection have a progressive intention. In that time we used VAK system for 6 weeks combined with faecal management system and with local necrectomy and system application of Antibiotics and Flagyl for enterocolitis in doses prescribed from specialists from Infective clinic. This new device to manage faecal deep decubital infection and enterocolitis with *Clostridium difficile* are considered as adequate. 8Flexi-Seal® FMS has been also used. After two months we succeed to minimize the gluteal wound on quoter from the situation from the beginning and we used for next two months wound treatment from Departement for Plastic and Reconstructive Surgery.

**CONCLUSION:** When faecal incontinence as a result of enterocolitis with *Clostridium difficile* does occur, a limiting contact with the patient's skin is extremely important as breakdown can occur rapidly. In addition to tissue injury, faecal incontinence can have a major impact on the patient's dignity and result in prolonged hospital stay. The main outcomes assested in the case studies were resolution of of decubital ulcers as a result of faecal incontinence, patient comfort and ease of application of the FMS and NPWT. The soft flexible catheter was easily inserted without discomfort to the patients. It gently conformed to the rectal vault, reducing significantly the risk of necrosis, and the risk for prolonged necrosis in cases with previously developed necrosis. FMS was successful in diverting faecal fluid away from the perineal tissue and resolved any decubitus ulcer developed previously in combination with use of NPWT. So, we can recommend this combination in those cases especially with polytraumatism, vertical share pelvis fracture combined with diarrhea and deep wound infection of decubital ulcers Grade IV infected with *Cl. difficile*.

## Introduction

A decubitus ulcer, also known as a pressure ulcer, pressure sore, or bed sore, is an open wound on the skin [1-5]. Decubitus ulcers often occur on the skin covering bony areas. The most common places for a decubitus ulcer are on buttocks [6, 7]. In cases, with decubitus gluteal ulcer and enterocolitis with identified *Clostridium difficile* the main goal is to avoid

contact between faecal masses and decubitus ulcer. New devices to manage this problem is the use of Flexi-Seal® FMS [2]. This device has been developed to assist clinicians in the management of faecal incontinence, but also in infection control and associated skin damage. 8 Flexi-Seal® FMS is a temporary containment device consisting of a soft, flexible, silicone catheter, attached to a closed end collection bag. This device combined with Negative pressure Wound therapy may be a method of choice

in patients with decubitus ulcer Grade IV combined with pelvic fracture and enterocolitis and deep wound infection with *Clostridium difficile*.

Appearance of decubitus ulcer is common among elderly and disabled people who stand long period in bed on supracondylar extension associated with polytrauma and vertical share pelvis fracture.

According to *National Pressure Ulcer Advisory Panel (NPUAP)*, the patient had Stage 4 decubitus ulcer, so many layers are affected in this stage, including muscles and bones. A dark substance called "eschar" may be found inside the store. Direct pressure is one of the main causes of a decubitus ulcer.

diagnosis: brain contusion; contusion of thoracal space; vertical share pelvic fracture; open fracture type II of the right calcaneus; fracture of the left calcaneus; fracture on the typical place of the left radius; fracture of the right radius with dislocation.

As a first step during the treatment in an Intensive care unit, we perform transcondylar extension of the left leg. Four weeks after this treatment we intent to perform stabilisation of pelvic ring, fixation of both arms, and fixation of both calcaneus bones. But at the time before performing the surgery, the patient got an intensive enterocolitis from *Escherichia coli* and *Clostridium difficile*, and during the inadequate treatment of enterocolitis, she got a big decubitus on both gluteal regia Grade IV and deep muscular necrosis. Several times we perform a necrectomy of necrotic tissue but the wound become bigger, and the infection has a progressive intention.

### Case Presentation

Patient D.S.1967 treated on Traumatology Clinic after tentamen suicidi on 9.2.2015 with the

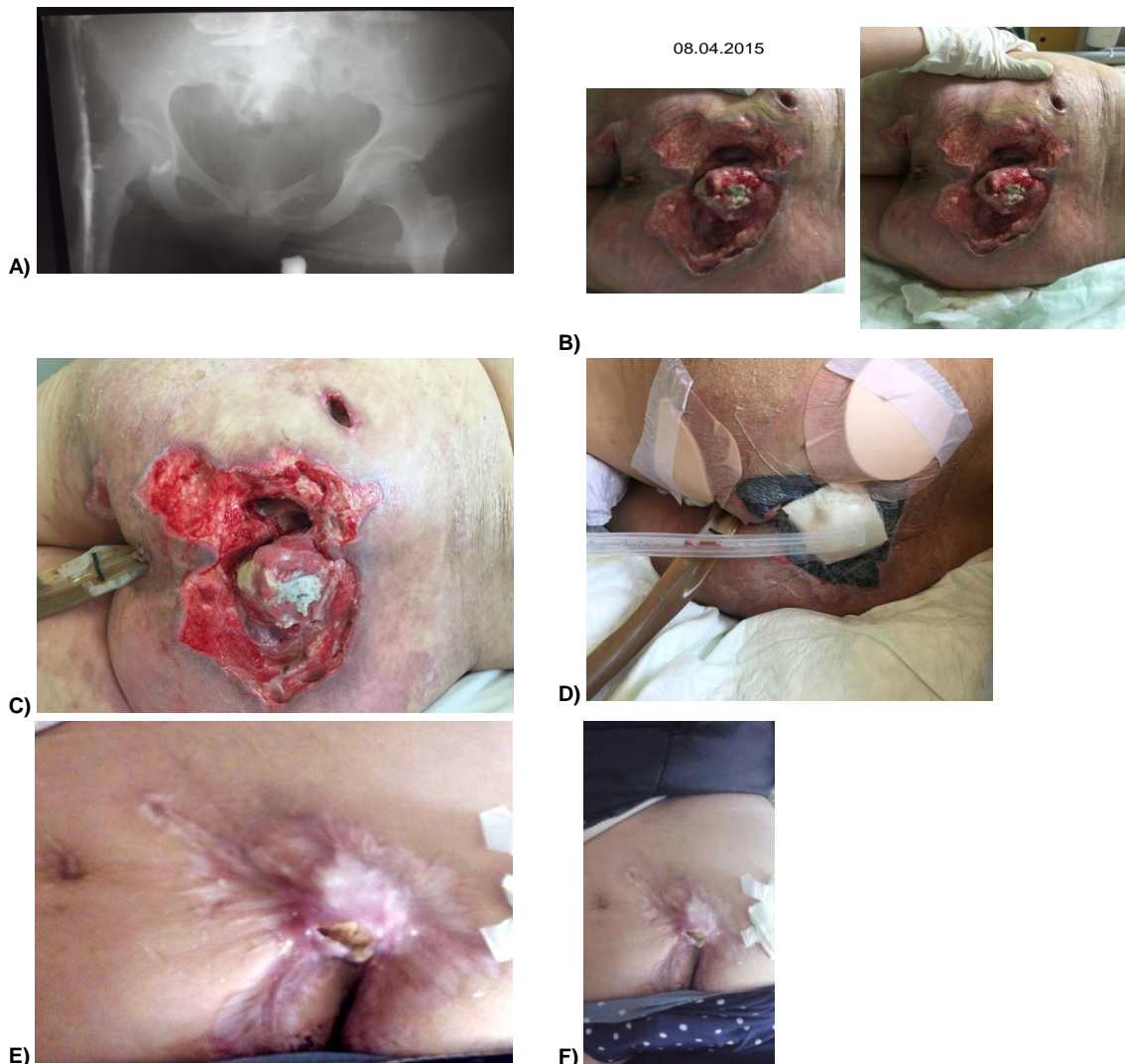


Figure 1: A) X-ray of pelvic vertical share fracture; B) situation before starting with treatment; C) Application of FMS; D) Application of VAK system; E, F) situation after the treatment

In that time we used VAK system for 6 weeks combined with the faecal management system and with local necrectomy and system application of Antibiotics and Flagyl for enterocolitis in doses prescribed from specialists from Infective Clinic. This new device to manage faecal deep decubital infection and enterocolitis with *Clostridium difficile* are considered as adequate. Flexi-Seal® FMS has been developed to assist clinicians in the management of faecal infection control associated with deep skin damage. Flexi-Seal® FMS is a temporary containment device consisting of a soft, flexible, silicone catheter, attached to a closed end collection bag.

After two months we succeed to minimize the gluteal wound on ¼ from the situation from the beginning and we used for next two months wound treatment from Plastic and reconstructive surgery. We offer to the patient eventually fixation of the left radius because of the evident limitation of pronation of the forearm, but she refused any kind of operation. After 6 months the patient can go with support, and we send her to physiotherapy for rehabilitation. After 8 months she can walk without support.

## Discussion

Bacteria are present in infected faeces and may be a source of worsening of decubital ulcers of gluteal region. The disposable, closed end collection bag with no return valve and integrated cap helped to minimize the risk of spreading infection, while also providing effective odor control. The soft, flexible silicone catheter diverted stools away from the patient, minimizing the risk of further skin breakdown and also facilitating the monitoring of frequency and characteristics of the patients stools. Following insertion of the FMS, perianal dermatitis caused by faecal incontinence was reduced within 24 hours especially when we combined this device with Negative pressure wound therapy for decubital ulcers. Hartley (2005) [8] reported on a recent mandatory study of acute and specialist trusts in England where cases of *C. difficile* related diarrhea were reported from January 2004, 44488 cases were identified.

Management of this health care – associated infection and other causes of faecal incontinence pose many challenges for health care professionals [9, 10]. Traditional methods of managing faecal incontinence have their shortfalls and are considered inadequate (Birdsall, 1986) [1]. As well as diverting faecal fluid away from the skin, closed systems such as the Flexi-Seal FMS may assist with the control of the infection, and allow for more accurate fluid balance and melena

monitoring.

In conclusion, when faecal incontinence as a result of enterocolitis with *clostridium difficile* does occur, a limiting contact with the patient's skin is extremely important as breakdown can occur rapidly. In addition to tissue injury, faecal incontinence can have a major impact on the patient's dignity and result in a prolonged hospital stay. The main outcomes assessed in the case studies were the resolution of decubital ulcers as a result of faecal incontinence, patient comfort and ease of application of the FMS and NPWT.

The soft, flexible catheter was easily inserted without discomfort to the patients. It gently conformed to the rectal vault, reducing significantly the risk of necrosis, and the risk for prolonged necrosis in cases with previously developed necrosis. FMS was successful in diverting faecal fluid away from the perineal tissue and resolved any decubitus ulcer developed previously in combination with the use of NPWT.

So, we can recommend this combination in those cases especially with polytraumatism, vertical sacrum fracture combined with diarrhea and deep wound infection of decubital ulcers Grade IV infected with *Cl. difficile*.

## References

- Birdsall C. Clinical savvy: Would you put a foley catheter in the rectum? Am J Nurs. 1986; 29(4): 193–201. <https://doi.org/10.2307/3424994>
- Conva Tec. FMS Cost-effective Survey. Data on File, ConvaTec, Ickenham, UK, 2003.
- Cutting KF, White RJ. Maceration of the skin 1: the nature and causes of skin maceration. J Wound Care. 2002; 11(7): 275–8. <https://doi.org/10.12968/jowc.2002.11.7.26414> PMID:12192848
- Defloor T, Schoonoven L, Fletcher J, et al. Pressure ulcers and moisture lesions. European Pressure Ulcer Advisory Panel Open Meeting, Aberdeen (Oral presentation), 2005.
- Faria DT, Shwayder T, Krull EA. Perineal skin injury: extrinsic environmental factors. Ostomy Wound Management. 1996; 42(7): 28–34. PMID:8826118
- Gray M, Ratcliff C, Donovan A. Perineal skin care for the incontinent patient. Advances in Skin and Wound Care. 2002; 15(4): 170–5. <https://doi.org/10.1097/00129334-200207000-00008> PMID:12151983
- Grogan TA, Kramer DJ. The rectal trumpet: use of a nasopharyngeal airway to contain faecal incontinence in critically ill patients. JWCON. 2002; 29(4): 193–201. <https://doi.org/10.1097/00152192-200207000-00008>
- Hartley J. C. Diff rates expose wider HAI challenge. Nursing Times. 2005; 101(35): 2.
- Martin AM. Concise Colour Medical Dictionary. Oxford University Press, Oxford: 133 Figure 6. Perineal dermatitis, 1998.
- Timbury MC, McCartney AC, Thakker B, Ward KN. Notes on Medical Microbiology. Churchill Livingstone, Edinburgh, 2003.