

# Late Onset Achromatic Melanoma Arising in a Giant Congenital Melanocytic Nevus

Georgi Tchernev<sup>1\*</sup>, James W. Patterson<sup>2</sup>, Ilko Bakardzhiev<sup>3</sup>, Torello Lotti<sup>4</sup>, Jacopo Lotti<sup>5</sup>, Katlein França<sup>6</sup>, Atanas Batashki<sup>7</sup>, Uwe Wollina<sup>8</sup>

<sup>1</sup>Department of Dermatology, Venereology and Dermatologic Surgery, Medical Institute of Ministry of Interior, and Onkoderma Polyclinic for Dermatology and Dermatologic Surgery, Sofia, Bulgaria; <sup>2</sup>Departments of Pathology and Dermatology, University of Virginia Health System, Hospital Expansion, 3<sup>rd</sup> Floor, 1215 Lee Street, Charlottesville, VA, USA; <sup>3</sup>Medical College, Medical University of Varna, Varna 9000, Bulgaria; <sup>4</sup>Department of Biotechnology, Delft University of Technology, 2628 BC, Delft, The Netherlands; <sup>5</sup>Department of Nuclear, Subnuclear and Radiation Physics, University of Rome "G. Marconi", Rome, Italy; <sup>6</sup>Institute for Bioethics & Health Policy; Department of Dermatology & Cutaneous Surgery; Department of Psychiatry & Behavioral Sciences, University of Miami Miller School of Medicine - Miami, FL, USA; <sup>7</sup>Department of Special Surgery, Medical University of Plovdiv, bul. "Peshtersko shose" Nr 66, 4000, Plovdiv, Bulgaria; <sup>8</sup>Department of Dermatology and Allergology, Academic Teaching Hospital Dresden-Friedrichstadt, Friedrichstrasse 41, 01067, Dresden, Germany

## Abstract

**Citation:** Tchernev G, Patterson JW, Bakardzhiev I, Lotti T, Lotti J, França K, Batashki A, Wollina U. Late Onset Achromatic Melanoma Arising in a Giant Congenital Melanocytic Nevus. Open Access Maced J Med Sci. 2017 Jul 25; 5(4):533-534. <https://doi.org/10.3889/oamjms.2017.077>

**Keywords:** melanoma; congenital nevus; surgery; progression; outcome; prevention.

**\*Correspondence:** Professor Dr Georgi Tchernev PhD, Chief of 1) Department of Dermatology, venereology and Dermatologic Surgery, Medical Institute of Ministry of Interior (MVR), General Skobelev 79, 1606 Sofia; 2) Onkoderma- Polyclinic for Dermatology and Dermatologic Surgery, General Skobelev 26, Sofia, Bulgaria. GSM: 00359885588424. E-mail: georgi\_tchernev@yahoo.de

**Received:** 21-Mar-2017; **Revised:** 29-Mar-2017; **Accepted:** 03-Apr-2017; **Online first:** 18-Jul-2017

**Copyright:** © 2017 Georgi Tchernev, James W. Patterson, Ilko Bakardzhiev, Torello Lotti, Jacopo Lotti, Katlein França, Atanas Batashki, Uwe Wollina. This is an open-access article distributed under the terms of the Creative Commons Attribution-NonCommercial 4.0 International License (CC BY-NC 4.0).

**Funding:** This research did not receive any financial support.

**Competing Interests:** The authors have declared that no competing interests exist.

A 61-year-old woman, with a lifelong history of a giant congenital melanocytic nevus in the occipital region with secondary development of giant melanoma is presented. Surgical excision was performed, and the histopathological evaluation confirmed the diagnosis of Giant Malignant Melanoma (GMM) with a maximum tumour thickness of 16 mm. Nowadays, there is tremendous uncertainty regarding how giant congenital melanocytic nevi (GCMN) should be treated. The standard approach to patients with late onset giant congenital melanocytic nevi (GCMN) is based on two main considerations: (1) obtain an acceptable cosmetic results with the purpose to decrease the psychosocial inconvenience to each patient, and (2) to attempt to minimise the risk of development of malignant transformation. Unfortunately complete surgical removal of the GCMN is usually difficult and very often impossible without subsequent functional or cosmetic mutilations.

A 61-year-old woman, with a lifelong history of a giant congenital melanocytic nevus involving the occipital scalp, posterior neck and shoulders, and upper back, presented with a six-month history of an ulcerated tumour in the occipital region (Fig. 1a, 1b, 1c). Magnetic resonance imaging confirmed the presence of an exophytic cutaneous tumour measuring 11.5 cm in greatest diameter as well as spinal stenosis in the area of C6 and C7. Abnormal laboratory studies included an increased C-reactive protein and an elevated serum S100 level (0.122 mcg/l). Radiographic and ultrasonographic studies failed to show evidence of disease progression to lungs, lymph nodes or abdominal structures. A wide

local excision was done, and the histopathology confirmed the diagnosis of malignant melanoma with a maximum thickness of 16 mm (Fig. 1d, 1e, 1f). Additional reexcision with 1,5cm safety margins was planned. Immunohistopathological stainings with HMB-45 (diffusely positive) and S-100 showed a strong positive reaction. The patient denied sentinel lymph node biopsy. Tumour was staged as IIB (T4aN0M0). A prophylactic interferon therapy (3 MU/m<sup>2</sup>, 3 x weekly) was planned.

Congenital melanocytic nevus (CMN) is defined, clinically, as a melanocytic lesion present at birth or which develops during infancy from preexistent melanocytes [1, 2]. The risk of developing

melanoma over a CMN is a nowadays very well established subject [1, 3]. It is believed that this risk is directly proportional to nevus size, varying from 2.6% to 4.9% for small and medium nevi and from 6% to 20% for giant nevi [3]. For these reasons, surgical resection of giant congenital nevi is frequently recommended before puberty and when located in areas difficult to monitor [2]. Nowadays, there is tremendous uncertainty regarding how giant congenital melanocytic nevi (GCMN) should be treated. The standard approach to patients with GCMN is based on two main considerations: (1) obtain an acceptable cosmetic result to decrease the psychosocial inconvenience to the patient, and (2) attempt to minimise the risk of malignancy.

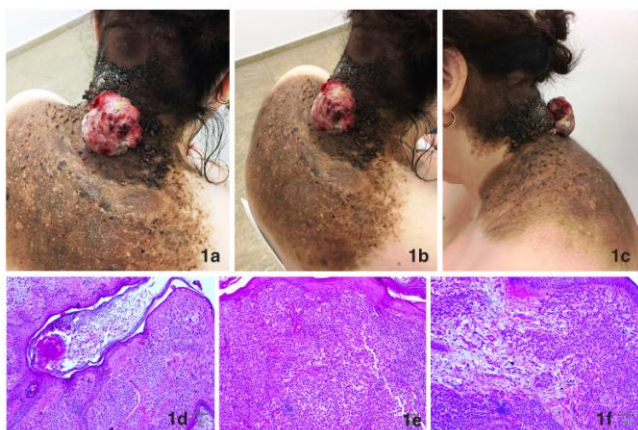


Figure 1: 1a-1c, Clinical pictures of patient with Giant melanoma located on the basis of Giant Congenital Melanocytic Nevus; 1d-1f, Histopathological evaluation showing deep penetrating tumour cells

To date, no absolute guidelines to treat these nevi have been given to our knowledge, and therefore, this subject remains one of the most controversial issues in dermatologic surgery and dermatologic oncology [4-6].

Complete removal of the GCMN is usually difficult and very often impossible without functional or cosmetic mutilation. Moreover, even after complete excision of GCMN down to the muscle fascia, the malignancy risk is not completely eradicated as malignant melanoma can occur at extracutaneous sites [7].

The most promising results of treating GCMN were originally reported by Moss in 1987 [8]. He performed curettage on GCMN during the first weeks of life to remove the superficially distributed nevus cells based on the fact that at that time, there seems to be a cleavage plane between the upper and the

lower dermis. This technique offers the best alternative to classic surgery when the nevi are too large to perform complete excision, and it is a technique that is of benefit for these patient groups [9]. Treatment with targeted therapies, after phenotype characterization, should also be considered in selected cases [10, 11].

## References

1. Paschoal FM. Nevo melanocítico congênito. *An Bras Dermatol*. 2002;77:649–656. <https://doi.org/10.1590/S0365-05962002000600002>
2. Yun SJ, Kwon OS, Han JH, Kweon SS, Lee MW, Lee DY, et al. Clinical characteristics and risk of melanoma development from giant congenital melanocytic naevi in Korea. *Br J Dermatol*. 2012;166:115–123. <https://doi.org/10.1111/j.1365-2133.2011.10636.x> PMID:21923752
3. Khashashneh I, Shatnawi M, Tawalbeh A, Alhaji M, Rajjal M. Giant congenital hairy nevus on the scalp. *Sudan J Med Sci*. 2008;3:343–347.
4. Arons MS, Hurwitz S. Congenital endocellular nevus: a review of treatment controversy. *Plast Reconstr Surg*. 1983;72:355-365. <https://doi.org/10.1097/00006534-198309000-00019>
5. Alper JC. Congenital nevi: the controversy rages on [editorial]. *Arch Dermatol*. 1985;121:734-735. <https://doi.org/10.1001/archderm.1985.01660060048018>
6. De Raeve LE. Management of congenital nevi. *Eur J Ped Derm*. 1998;8:161-164.
7. de David M, Orlow SJ, Provost N et al. Neurocutaneous melanosis: clinical features of large congenital melanocytic nevi in patients with manifest central nervous system melanosis. *J Am Acad Dermatol*. 1996;35: 529-538. [https://doi.org/10.1016/S0190-9622\(96\)90674-X](https://doi.org/10.1016/S0190-9622(96)90674-X)
8. Moss ALH. Congenital "giant" naevus: a preliminary report of a new surgical approach. *Br J Plast Surg*. 1987;40:410- 419. [https://doi.org/10.1016/0007-1226\(87\)90046-4](https://doi.org/10.1016/0007-1226(87)90046-4)
9. De Raeve LE, De Coninck AL, Dierickx PR, Roseeuw DI. Neonatal curettage of giant congenital melanocytic nevi. *Arch Dermatol*. 1996;132(1):20-2. <https://doi.org/10.1001/archderm.1996.03890250022005> PMID:8546479
10. Russo A, Ficili B, Candido S, Pezzino FM, Guarneri C, Biondi A, Travali S, McCubrey JA, Spandidos DA, Libra M. Emerging targeted therapies for melanoma treatment (review). *Int J Oncol*. 2014;45(2):516-24. <https://doi.org/10.3892/ijo.2014.2481>
11. Bevelacqua V, Bevelacqua Y, Candido S, Skarmoutsou E, Amoroso A, Guarneri C, Strazzanti A, Gangemi P, Mazzarino MC, D'Amico F, McCubrey JA, Libra M, Malaponte G. Nectin like-5 overexpression correlates with the malignant phenotype in cutaneous melanoma. *Oncotarget*. 2012;3(8):882-92. <https://doi.org/10.18632/oncotarget.594> PMID:22929570 PMID:PMC3478464