

# Genistein Ameliorates Cyclophosphamide - Induced Hepatotoxicity by Modulation of Oxidative Stress and Inflammatory Mediators

Dina F. Mansour, Dalia O. Saleh\*, Rasha E. Mostafa

Pharmacology Department, Medical Division, National Research Centre, (ID: 60014618), Dokki, Giza, Egypt

## Abstract

**Citation:** Mansour DF, Saleh DO, Mostafa RE. Genistein Ameliorates Cyclophosphamide-Induced Hepatotoxicity by Modulation of Oxidative Stress and Inflammatory Mediators. Open Access Maced J Med Sci. <https://doi.org/10.3889/oamjms.2017.093>

**Keywords:** Cyclophosphamide; genistein; interleukin-1 $\beta$ ; Myeloperoxidase; Oxidative stress.

\***Correspondence:** Dalia O. Saleh, Pharmacology Department, Medical Division, National Research Centre, (ID: 60014618), Dokki, Giza, Egypt. E-mail: doabdefattah@yahoo.com

**Received:** 30-Mar-2017; **Revised:** 07-May-2017; **Accepted:** 16-May-2017; **Online first:** 01-Nov-2017

**Copyright:** © 2017 Dina F. Mansour, Dalia O. Saleh, Rasha E. Mostafa. This is an open-access article distributed under the terms of the Creative Commons Attribution-NonCommercial 4.0 International License (CC BY-NC 4.0).

**Funding:** This research did not receive any financial support.

**Competing Interests:** The authors have declared that no competing interests exist.

**AIM:** The present study investigated the protective effect of the phytoestrogen, genistein (GEN), against (CP)-induced acute hepatotoxicity in rats.

**MATERIAL AND METHODS:** Male adult rats were randomly assigned into five groups. Normal control group received the vehicles; CP group received a single dose of CP (200 mg/kg, i.p). The other three groups received subcutaneous GEN at doses of 0.5, 1 and 2 mg/kg/day, respectively, for 15 consecutive days prior CP injection. Sera and liver tissues were collected forty-eight hours after CP injection for assessment of liver function enzymes (ALT and AST) in rat sera, the hepatic oxidative/nitrosative biomarkers (GSH, MDA and NOx), hepatic interleukin-1 $\beta$ , and myeloperoxidase activity. Immunohistochemistry of cyclooxygenase-2 and histopathological examination of liver tissues were also conducted.

**RESULTS:** The CP-induced acute liver damage was evidenced by elevated serum ALT and AST accompanied by increased hepatic oxidative stress and inflammatory biomarkers. Immunohistochemical outcomes revealed hepatic cyclooxygenase-2 expression in CP group with distortion of liver architecture. GEN-pretreatment significantly ameliorated the deterioration of liver function and exerted significant anti-oxidant and anti-inflammatory activity with a marked decline in hepatic cyclooxygenase-2 expression in a dose dependent-manner.

**CONCLUSION:** The present study demonstrated that the antioxidant and anti-inflammatory activities of GEN might contribute to its protective effects against CP-induced liver damage.

## Introduction

Cyclophosphamide (CP) is an oxazaphosphorine derivative of the traditional alkylating agent nitrogen mustard [1]. Cyclophosphamide is widely used in the treatment of several human cancers [2] including solid tumours, lymphomas and leukaemia [3], as well as many non-neoplastic diseases, such as systemic lupus erythematosus and rheumatoid arthritis [4, 5]. The therapeutic dose of CP has been shown to cause liver toxicity; which often restricts its clinical use [6-8]. Growing evidence suggests that oxidative stress plays a major role in CP-induced hepatotoxicity [9, 10] via causing severe cellular damage accompanied by lipid peroxidation and changes in cellular nucleic acids [11, 12]. CP is metabolised by the hepatic microsomal cytochrome P450 (CYP450), giving rise to

phosphoramidate mustard and acrolein [13]. Acrolein; a highly reactive metabolite of CP with short biological half-life; inhibits CYP450 by alkylating the reduced glutathione (GSH) sulfhydryl groups thus inducing oxidative stress and causing hepatotoxicity [14, 15]. Furthermore, CP damages mitochondria and impairs cellular respiration [16]. Thus it interferes with hepatic intracellular oxidant/antioxidant balance leading to reactive oxygen species (ROS) accumulation [9]. ROS then induces lipid peroxidation and activates multiple signalling cytotoxicity pathways including nuclear transcription factor kappa-B (NF- $\kappa$ B) and mitogen-activated protein kinases (MAPKs), thus initiating different steps in the inflammatory pathway [17]. Thus, introducing some anti-oxidant agents may be useful in alleviating the toxic side effect of anti-cancer drugs. Earlier studies have shown that some plant extracts with antioxidant activity protect against CP hepatotoxicity [18-20]. Accordingly, chemotherapeutic-treatment protocol combined with potent and safe

antioxidants could be a desirable tool to mitigate CP-induced hepatotoxicity.

Genistein (GEN), a phytoestrogen present in soy products, possesses structural similarity to estrogen. GEN acts like human estrogen and binds to estrogen receptors [21] which justifies its use for treatment of symptoms of menopause [22]. Previous studies suggested that GEN possesses anti-osteoporotic, anti-neoplastic, cardio-protective, anti-proliferative, anti-apoptotic, anti-necrotic, antioxidant and anti-inflammatory actions [23].

It has been well-established the link between the estrogenic activity of GEN and its antioxidant effect via decreasing oxidative stress as a consequence of increased expression of antioxidant defence genes [24]. Recently, GEN has been shown to improve the endothelium-dependent relaxation in insulin-resistant ovariectomized rats with further modulation of the elevated blood pressure [25]. Previous studies reported GEN-hepatoprotective activity against several models of hepatotoxicity [26, 27].

Therefore, the current study aims at exploring the potential protective effects of GEN against cyclophosphamide-induced hepatotoxicity in rats.

## Materials and Methods

### Animals

Forty adult male Sprague-Dawley rats weighing 180-200 g were utilised in the present study. Standard food pellets and tap water were supplied ad libitum. Animals and food pellets were obtained from the animal house colony of the National Research Center (NRC, Egypt). The study was conducted by ethical procedures and policies outlined in the Canadian Council of Animal Care guidelines (NAC 2011) and was approved by the Medical Research Ethics Committee (MREC) of the National Research Centre (approval no. 16/434).

### Drugs and chemicals

Genistein (LC Laboratories, Woburn, Massachusetts, USA; purity > 99%) and cyclophosphamide (CP, Endoxan®, Baxter Oncology GmbH, Germany) were used in the study. GEN was dissolved in 5 ml DMSO (1.25%) and divided into equal aliquots [28]. Every day, an aliquot of the drug was freshly diluted by distilled water and injected subcutaneously. The concentration was adjusted so that each 100 g animal body weight received 0.25 ml, 0.5 ml and 1 ml for doses 0.5, 1 and 2 mg/kg, respectively [29]. CP was injected intraperitoneally in

a single hepatotoxic dose of 200 mg/kg [7]. All of the other chemicals were of highest analytical grade available.

### Experimental design and treatment protocol

Animals were randomly allocated into five groups (8 rats each). Rats of the 1<sup>st</sup> group received subcutaneous injections of the corresponding vehicle (DMSO) and served as normal control group. Acute hepatotoxicity was induced in the remaining four groups by single intraperitoneal injection of cyclophosphamide (CP; 200 mg/kg) on the 15<sup>th</sup> day of treatment. Group 2 received only the vehicle (saline) subcutaneously for 15 days before CP treatment and served as CP control group. Groups 3, 4 and 5 received genistein (GEN; 0.5, 1 and 2 mg/kg/day, s.c.) respectively for 15 days before CP treatment on day 15. All animals were sacrificed 48 h after CP injection.

### Serum biochemical analysis

Forty-eight hours after CP injection, rats were anaesthetised with diethyl ether, and blood samples were withdrawn from the retro-orbital venous plexus. Collected blood samples were allowed to stand for 10 min at room temperature then centrifuged at 4°C using cooling centrifuge (Laborezentrifugen, 2k15, Sigma, Germany) at 3000 r.p.m for 10 min and sera were separated for the assessment of levels of aspartate aminotransferase (AST) and alanine aminotransferase (ALT) according to the methods of Reitman and Frankel (1957) using commercially available colorimetric assay kits (Biodiagnostic, Egypt) [30].

### Hepatic Tissue biochemical analysis

Directly after collecting the last blood sample in the experiment, rats were sacrificed by cervical dislocation and liver tissues were collected, washed with normal saline and then divided into 3 parts: one part was homogenized (using MPW-120 homogenizer, Med instruments, Poland); the homogenate was centrifuged using a cooling centrifuge (Laborezentrifugen, 2k15, Sigma, Germany) at 3000 r.p.m for 10 min; the supernatant was assessed for hepatic levels of reduced glutathione (GSH), lipid peroxides as malondialdehyde (MDA) [32], and nitric oxide (NO) metabolites [33]. Moreover, inflammatory markers such as myeloperoxidase (MPO) [34], interleukin-1 $\beta$  (IL-1 $\beta$ ) were assessed using enzyme-linked immunosorbent assay (ELISA) kits (Hycult Biotech, Netherlands) and (R&D Systems, USA), respectively, according to the manufacturer's instructions.

### Immunohistochemistry of Cyclooxygenase-2 (COX-2)

Liver COX-2 was assessed by immunohistochemical staining. Liver sections on polylysine-coated slides obtained were fixed in neutral buffered formalin, and embedded in paraffin and were treated for COX-2 antibodies for immunohistochemical analysis. Following deparaffinization and rehydration, sections were irradiated in 0.1 mol/L sodium citrate buffer [pH 6.0] in a microwave oven [medium low temperature] for 20 min. Then the sections were exposed to 3% H<sub>2</sub>O<sub>2</sub> for 10 min to bleach endogenous per-oxidases, followed by rinsing three times in Tris buffer (pH 7.4) for 10 min. Sections were selectively incubated under humid conditions using an anti-COX-2 antibody [1:200; Santacruz Biotechnology, Inc., USA] [10].

### Histopathological examination

The other parts of the livers were fixed in 10% neutral buffered formalin and embedded in paraffin wax. 4 µm thick sections were stained with Hematoxylin and Eosin (H&E) and examined using binocular Olympus CX31 microscope [35].

### Statistical analysis

All the values are presented as means ± standard error of the means (SEM) of eight experiments. Comparisons between different groups were carried out using one-way analysis of variance (ANOVA) followed by Tukey's multiple comparison post hoc tests. The difference was considered significant when  $P < 0.05$ . GraphPad prism® software (version 6 for Windows, San Diego, California, USA) was used to carry out these statistical tests.

## Results

### Effects of GEN on serum liver microsomal enzymes in CP-induced hepatotoxicity in rats

Cyclophosphamide (CP, 200 mg/kg, i.p.) resulted in acute liver damage in rats as evidenced by the significant elevation of serum alanine transaminase (ALT) and aspartate transaminase (AST) to 477% and 285%, respectively, as compared to the normal control group. Pretreatment of rats with GEN (0.5, 1 or 2 mg/kg/day, s.c.) significantly decreased the elevated serum AST and ALT in a dose-dependent manner as compared to the CP-control group. Genistein treatment at 2 mg/kg recorded normal levels of ALT and improved both ALT and AST significantly compared to the other dose levels (Figure 1).

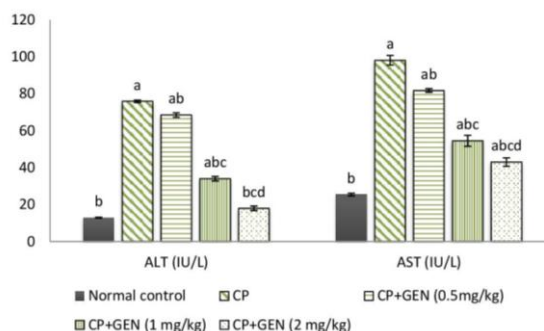


Figure 1: Effects of genistein on serum alanine transaminase (ALT) and aspartate transaminase (AST) in cyclophosphamide-induced hepatotoxicity in rats. Rats of the normal control group received s.c. Injections of DMSO. Acute hepatotoxicity was induced in the remaining four groups by single intraperitoneal injection of cyclophosphamide (CP; 200 mg/kg) on the 15th day of treatment. Group 2 received only saline s.c. for 15 days and served as CP control group. Groups 3, 4 and 5 received genistein (GEN; 0.5, 1 and two mg/kg/day, s.c.) respectively for 15 days before CP treatment. All animals were sacrificed 48 h after CP injection, blood samples were collected, and sera were separated. Data are presented as mean ± SEM (n = 8). a, Significantly different from Normal control group at  $p < 0.05$  (Tukey's post hoc test). b, significantly different from CP control group at  $p < 0.05$  (Tukey's post hoc test). c, Significantly different from CP+GEN (0.5 mg/kg) group at  $p < 0.05$  (Tukey's post hoc test). d Significantly different from CP+GEN (1 mg/kg) group at  $p < 0.05$  (Tukey's post hoc test)

### Effects of GEN on hepatic oxidative/nitrosative stress parameters in CP-induced hepatotoxicity in rats.

Cyclophosphamide (CP, 200 mg/kg, i.p.) resulted in acute liver damage in rats as evidenced by a significant decrease in hepatic GSH by 77%, with a marked increase in hepatic MDA and NO as compared to the normal control group.

Pretreatment of rats with GEN, at 1 and 2 mg/kg, significantly elevated the decreased liver GSH while GEN at 0.5 mg/kg failed to exert significant increase in GSH as compared to the CP-control group. On the other hand, GEN-pretreatment (0.5, 1 and 2 mg/kg/day, s.c.) for 15 days prior CP injection significantly reduced the elevation in hepatic MDA and NO in a dose-dependent manner compared to the CP-control group, recording normal levels of NO at GEN dose of 2 mg/kg/day with insignificant difference from normal control group (Table 1).

### Effects of GEN on hepatic inflammatory marker (MPO) and the cytokine (IL-1β) in CP-induced hepatotoxicity in rats

Cyclophosphamide (CP, 200 mg/kg, i.p.) resulted in acute liver damage in rats as evidenced by an increase in hepatic MPO and IL-1β content as compared to the normal control group. Pretreatment of rats with GEN (0.5, 1 and 2 mg/kg/day, s.c.) for 15 days prior CP injection significantly reduced the elevation in hepatic MPO and IL-1β in a dose-dependent manner compared to the CP-control group, recording normal levels of MPO and IL-1β at GEN

dose of 2 mg/kg/day with insignificant difference from normal control group (Table 1).

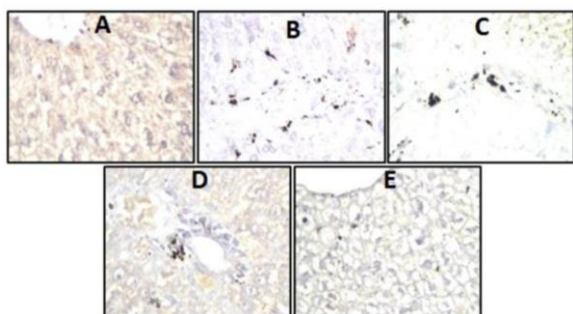
**Table 1: Effects of genistein on reduced hepatic glutathione (GSH), malondialdehyde (MDA), nitric oxide (NO) metabolites, myeloperoxidase (MPO), and interleukin one beta (Dtp) contents in cyclophosphamide-induced hepatotoxicity in rats**

Groups	Liver tissue oxidative/ nitrosative stress Parameters			Liver inflammatory marker	Liver tissue Cytokine
	GSH	MDA	NO	MPO	IL-1 $\beta$
	( $\mu\text{mol/g}$ )	( $\text{nmol/g}$ )	( $\mu\text{mol/g}$ )	( $\text{U/g}$ )	( $\text{pg/g}$ )
Normal Control	4.00 <sup>b</sup> $\pm$ 0.14	12.03 <sup>b</sup> $\pm$ 0.48	2.04 <sup>b</sup> $\pm$ 0.05	1.88 <sup>b</sup> $\pm$ 0.085	8.11 <sup>b</sup> $\pm$ 0.44
CP-Control (200 mg/kg, i.p.)	0.93 <sup>a</sup> $\pm$ 0.01	36.32 <sup>a</sup> $\pm$ 0.28	24.10 <sup>a</sup> $\pm$ 0.67	12.2 <sup>a</sup> $\pm$ 0.7	47.15 <sup>a</sup> $\pm$ 0.45
CP + GEN (0.5 mg/kg, s.c.)	1.31 <sup>a</sup> $\pm$ 0.05	28.43 <sup>ab</sup> $\pm$ 0.21	11.7 <sup>ab</sup> $\pm$ 0.30	5.73 <sup>ab</sup> $\pm$ 0.26	27.25 <sup>ab</sup> $\pm$ 0.91
CP + GEN (1 mg/kg, s.c.)	2.64 <sup>bc</sup> $\pm$ 0.04	23.9 <sup>bc</sup> $\pm$ 0.61	5.8 <sup>bc</sup> $\pm$ 0.40	2.66 <sup>bc</sup> $\pm$ 0.15	13.48 <sup>bc</sup> $\pm$ 0.56
CP + GEN (2 mg/kg, s.c.)	2.90 <sup>bc</sup> $\pm$ 0.08	16.85 <sup>bcd</sup> $\pm$ 0.43	3.8 <sup>cd</sup> $\pm$ 0.05	1.48 <sup>bc</sup> $\pm$ 0.056	8.26 <sup>cd</sup> $\pm$ 0.43

Rats of the normal control group received s.c. injections of DMSO. Acute hepatotoxicity was induced in the remaining four groups by single intraperitoneal injection of cyclophosphamide (CP; 200 mg/kg) on the 15th day of treatment. Group 2 received only saline s.c. for 15 days and served as CP control group. Groups 3, 4 and 5 received genistein (GEN; 0.5, 1 and 2 mg/kg/day, s.c.) respectively for 15 days before CP treatment. All animals were sacrificed 48 h after CP injection. The livers were removed, homogenized, and the homogenate was obtained. Data are presented as mean  $\pm$  SEM (n = 8). a, Significantly different from Normal control group at  $p < 0.05$  (Tukey's post hoc test). b, Significantly different from CP control group at  $p < 0.05$  (Tukey's post hoc test). c, Significantly different from CP+GEN (0.5 mg/kg) group at  $p < 0.05$  (Tukey's post hoc test). d Significantly different from CP+GEN (1 mg/kg) group at  $p < 0.05$  (Tukey's post hoc test)

### Effect of GEN on Cyclooxygenase-2 (COX-2) expression in liver tissue

Pretreatment with genistein for 15 days before CP injection showed a dose-dependent reduction in hepatic COX-2 expression ranging from mild, moderate and negative COX-2 immunostaining of the kupffer cells and the hepatocytes at 0.5, 1 and 2 mg/kg of GEN, respectively, compared to CP-treated liver tissues.

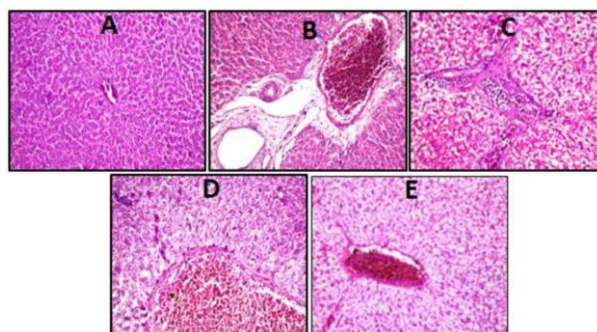


**Figure 2: A.** Photomicrograph of liver sections prepared from a normal control rat showing negative COX-2 immunostaining of the kupffer cells and the hepatocytes (COX-2 immunohistochemistry H&E X 80). **B.** Photomicrograph of liver sections prepared from a cyclophosphamide-control rat showing severe COX-2 immunostaining of the kupffer cells and the hepatocytes (COX-2 immunohistochemistry H&E X 80). **C.** Photomicrograph of liver sections prepared from a rat treated with genistein (0.5 mg/kg/day, s.c.) for 15 days before CP treatment showing moderate COX-2 immunostaining of the kupffer cells and the hepatocytes (COX-2 immunohistochemistry H&E X 80). **D.** Photomicrograph of liver sections prepared from a rat treated with genistein (1 mg/kg/day, s.c.) for 15 days before CP treatment showing mild COX-2 immunostaining of the kupffer cells and the hepatocytes (COX-2 immunohistochemistry H&E X 80). **E.** Photomicrograph of liver sections prepared from a rat treated with genistein (2 mg/kg/day, s.c.) for 15 days before CP treatment showing negative COX-2 immunostaining of the kupffer cells and the hepatocytes (COX-2 immunohistochemistry H&E X 80)

Cyclophosphamide caused severe COX-2 immunostaining of the kupffer cells and the hepatocytes compared to normal tissues (Figure 2).

### Effect of GEN on in liver histopathological picture

Cyclophosphamide exerted severe distortion in the hepatic architecture showing severe congestion and dilatation of the central and portal veins associated with degeneration in the hepatocytes surrounding the central vein and oedema in the portal area after 48 hours of injection (Figure 3). While GEN-pretreatment restored the histopathological picture of the liver causing mild to a moderate improvement compared to CP-treated liver tissues (Figure 3).



**Figure 3: Photomicrograph of a liver section of a rat from a normal control group (H&E X 40) showing no histopathological alteration and the normal histological structure of the central vein and surrounding hepatocytes were recorded (Figure 3A). Photomicrograph of a liver section of a rat from the cyclophosphamide-control group (H&E X 40) showing severe congestion and dilatation of the central and portal veins associated with degeneration in the hepatocytes surrounding the central vein and oedema in the portal area (Figure 3B). Photomicrograph of a liver section of a rat that received genistein (0.5 mg/kg/day, s.c.) for 15 days before CP treatment (H&E X 40) showing mild improvement in the overall histopathological picture. Inflammatory cells infiltration was apparent in the portal area while the hepatocytes showed degenerative change (Figure 3C). Photomicrograph of a liver section of a rat that received genistein (1 mg/kg/day, s.c.) for 15 days before CP treatment (H&E X 40) showing minimal improvement in the overall histopathological picture. Dilatation and congestion in the central veins associated with degeneration in the surrounding adjacent hepatocytes were apparent (Figure 3D). Photomicrograph of a liver section of a rat that received genistein (2 mg/kg/day, s.c.) for 15 days before CP treatment (H&E X 40) showing moderate improvement in the overall histopathological picture. Congestion in the central and portal veins along with degeneration in the surrounding hepatocytes was also apparent (Figure 3E)**

## Discussion

Chemotherapy-induced oxidative stress causes severe cellular and tissue damage and usually results in many undesirable side effects [36]. Cyclophosphamide, a widely known chemotherapeutic agent used in the treatment of several human cancers, is well known to induce prominent oxidative



stress in the liver [13]. Even low doses of CP can produce significant hepatotoxicity in humans which often stands as a barrier against its clinical use [4, 37].

In the present study, CP-treated animals showed significant elevation of liver function enzymes AST and ALT, important markers for the evaluation of liver injury since their leakage into serum defines the severity of liver damage [38]. Liver tissue oxidative stress parameters; MDA and NO, inflammatory enzymes; MPO and liver tissue cytokine IL-1 $\beta$  were significantly elevated while liver tissue GSH content was significantly decreased when compared to normal counterparts. Cyclophosphamide administration exerted severe expression of hepatic cyclooxygenase-2 (COX-2) as well. Moreover, CP caused severe deterioration of the overall histopathological picture of the liver tissue when compared to normal control group. Our results are in line with previous reports that stated severe hepatotoxicity associated with elevated AST, ALT [4] and lactate dehydrogenase (LDH) [10, 39] with a significant elevation in oxidative stress marker; MDA and a significant decrease in GSH, along with deteriorated histopathological picture in CP-treated rats [9]. Linking oxidative stress to inflammation, myeloperoxidase (MPO) was found to exert a primary role in chronic inflammation [40] and demonstrates an essential mechanistic link between oxidation and inflammation [41]. Increased levels of MPO and the pro-inflammatory cytokine; IL-1 $\beta$  after CP administration was reported after 48 hours in the present study. In a recent study, COX-2 expression in liver of rats received CP was increased along with significant elevation in serum ALT, liver NF- $\kappa$ B p65, TNF- $\alpha$ , IL-1 $\beta$ , MDA, NO, Bax/Bcl-2 ratio, inducible nitric oxide synthetase (iNOS), caspases 3 and 9 activities while decreased hepatic total antioxidant capacity [42]. Furthermore, TNF- $\alpha$  and IL-1 $\beta$  play crucial roles in stimulation of iNOS and COX-2 [23, 43], which further explains the increased levels of NO after CP administration. Others reported elevation in pro-inflammatory mediators like TNF- $\alpha$ , IL-1 $\beta$ , IL-6 and COX-2 along with increased ROS, LPO, decreased GSH and antioxidant enzymes (SOD, CAT, GST, and GSH-Px) in liver tissues of CP-treated animals [44]. These further support current data of increased oxidation and inflammation in CP hepatotoxicity.

Since its discovery in 1987, genistein has been investigated in a myriad of research fields, especially after reporting no side effects or toxicity with high doses of genistein in vivo [45]. GEN; a phytoestrogen found abundantly in soy and widely used an alternative to estrogens; possesses immunomodulatory effects of estrogen without exhibiting its side effects [21]. GEN mainly undergoes hepatic metabolism through cytochrome P450 system to give monohydroxyl and dihydroxyl metabolites [46]. Exhibiting well-established antioxidant and anti-inflammatory properties against different models of hepatotoxicity, pretreatment of rats with GEN (0.5, 1

and 2 mg/kg/day, s.c.) for 15 days significantly protected against CP-induced deterioration of liver function and showed marked anti-oxidant and anti-inflammatory properties that were demonstrated by the reduction of serum AST and ALT, hepatic MDA, NO, MPO and IL-1 $\beta$  while elevation of hepatic GSH content when compared to CP group. Previous studies revealed the potent hepatoprotective effect of GEN through elevation of liver GSH and reduction of liver MDA in thioacetamide- [29] and CCl<sub>4</sub>- [26, 47] induced hepatotoxicity. GEN exhibited protective effects against oxidative stress hepatic injury as manifested by increased activity of hepatic SOD, catalase, glutathione peroxidase and reduction of MDA level [48, 49]. Meanwhile, GEN exerted ameliorative effects on hepatic injury and fibrosis induced by chronic alcohol in rats [50]. Some researchers attributed the anti-inflammatory effects of GEN to its antioxidant effects [51] where significant low levels of plasma TNF- $\alpha$  was reported in non-alcoholic steatohepatitis by GEN antioxidant properties [52]. A Recent study revealed protective effects of GEN against CP-induced ovarian toxicity by mitigating oxidative stress and inflammation through elevating GSH, SOD while reducing MDA along with modulation of IL-1 $\beta$  and iNOS, respectively [29].

Moreover, GEN was shown to inhibit NO production from activated macrophages by LPS and IFN- $\gamma$  through inhibition of iNOS expression [53] by suppression of STAT-1 and NF- $\kappa$ B activation, which are important transcription factors for iNOS [54] that further supports our current observations. The anti-inflammatory effects of GEN were demonstrated earlier [55], which was in line with current results that revealed reduced hepatic levels of MPO and IL-1 $\beta$  after CP administration. In a rat model of D-galactosamine-induced fulminant hepatic failure, GEN supplementation exerted an anti-inflammatory activity via modulation of iNOS and COX-2, thereby reducing NO and prostaglandin-E<sub>2</sub> (PGE<sub>2</sub>) levels, respectively. Also, pro-inflammatory cytokines; TNF- $\alpha$  and IL-1 $\beta$  are reduced with the suppression of NF- $\kappa$ B activation, IKK $\alpha$ / $\beta$  and mitogen-activated protein kinase (MAPK) with a significant reduction in the serum AST and ALT levels as well as serum and liver tissue MDA accompanied by significant elevation of liver tissue GSH concentration [23].

Being contributed to the pathogenesis of inflammation-related diseases, a recent study demonstrated the relation between COX-2 and IL-1 $\beta$  as COX-2 catalyzes the synthesis of PGE<sub>2</sub> and increases IL-1 $\beta$  by increasing NF- $\kappa$ B activation and enhancing caspase-1 activation through triggering mitochondrial damage, mitochondrial reactive oxygen species production and subsequent release of mitochondrial DNA into cytosol via pyrin domain-containing 3 (NLRP3) inflammasome, a reactive oxygen species-sensitive multiprotein complex, that regulates IL-1 $\beta$  maturation in the spleen and liver of LPS-challenged mice [56]. Hence, linking decreased

level of hepatic IL-1 $\beta$  and COX-2 expression by GEN-pretreatment in a dose-dependent manner in CP-treated liver tissues, providing a new insight of GEN as a potential protective agent in inflammatory liver disease. Eventually, GEN caused significant improvement of the overall histopathological picture of the liver when compared to CP-control group.

From the current study, it can be concluded that GEN possesses potent ameliorative effects against hepatotoxic actions of CP from various aspects. GEN significantly decreased the elevated serum levels of hepatic microsomal enzymes, reduced oxidative stress parameters as MDA and NO, augmented anti-oxidation via elevating GSH along with decreased inflammatory mediators; MPO, IL-1 $\beta$  and COX-2 expression. Hence, it may provide effective protection against liver damage via anti-oxidative and anti-inflammatory activities.

## Acknowledgments

The authors are thankful to Prof. Adel Bekir, Department of Pathology, Faculty of Veterinary Medicine, Cairo University, Egypt, for the kind help in histopathology and immunohistochemistry.

## References

- Moignet A, Hasanali Z, Zambello R, Pavan L, Bureau B, Tournilhac O, Roussel M, Fest T, Awwad A, Baab K, Semenzato G, Houot R, Loughran TP, Lamy T. Cyclophosphamide as a first-line therapy in LGL leukemia. *Leukemia*. 2014;28:1134-1136. <https://doi.org/10.1038/leu.2013.359> PMID:24280867 PMID:PMC4017255
- Jurado JM, Sanchez A, Pajares B, Perez E, Alonso L, Alba E. Combined oral cyclophosphamide and bevacizumab in heavily pre-treated ovarian cancer. *Clinical & translational oncology*. 2008;10:583-586. <https://doi.org/10.1007/s12094-008-0254-7>
- Kim SH, Lee IC, Ko JW, Moon C, Kim SH, Shin IS, Seo YW, Kim HC, Kim JC. Diallyl Disulfide Prevents Cyclophosphamide-Induced Hemorrhagic Cystitis in Rats through the Inhibition of Oxidative Damage, MAPKs, and NF-kappaB Pathways. *Biomolecules & therapeutics*. 2015; 23: 180-188. <https://doi.org/10.4062/biomolther.2014.126> PMID:25767687 PMID:PMC4354320
- Cuce G, Cetinkaya S, Koc T, Esen HH, Limandal C, Balci T, Kalkan S, Akoz M. Chemoprotective effect of vitamin E in cyclophosphamide-induced hepatotoxicity in rats. *Chemico-biological interactions*. 2015; 232: 7-11. <https://doi.org/10.1016/j.cbi.2015.02.016> PMID:25779342
- Sinanoglu O, Yener AN, Ekici S, Midi A, Aksungar FB. The protective effects of spirulina in cyclophosphamide induced nephrotoxicity and urotoxicity in rats. *Urology*. 2012;80(6):1392.e1-6. <https://doi.org/10.1016/j.urology.2012.06.053> PMID:22951000
- De Jonge ME, Huitema AD, Beijnen JH, Rodenhuis S. High exposures to bioactivated cyclophosphamide are related to the occurrence of veno-occlusive disease of the liver following high-dose chemotherapy. *British journal of cancer*. 2006;94(9):1226-30. <https://doi.org/10.1038/sj.bjc.6603097> PMID:16622453 PMID:PMC2361415
- Habibi E, Shokrzadeh M, Chabra A, Naghshvar F, Keshavarz-Maleki R, Ahmadi A. Protective effects of Origanum vulgare ethanol extract against cyclophosphamide-induced liver toxicity in mice. *Pharmaceutical biology*. 2015;53(1):10-5. <https://doi.org/10.3109/13880209.2014.908399> PMID:25026348
- Tsai-Turton M, Luong BT, Tan Y, Luderer U. Cyclophosphamide-induced apoptosis in COV434 human granulosa cells involves oxidative stress and glutathione depletion. *Toxicological sciences*. 2007;98(1):216-30. <https://doi.org/10.1093/toxsci/kfm087> PMID:17434952
- Fahmy SR, Amien AI, Abd-Elgleel FM, Elaskalany SM. Antihepatotoxic efficacy of *Mangifera indica* L. polysaccharides against cyclophosphamide in rats. *Chemico-biological interactions*. 2016;244:113-20. <https://doi.org/10.1016/j.cbi.2015.11.009> PMID:26615121
- Nafees S, Rashid S, Ali N, Hasan SK, Sultana S. Rutin ameliorates cyclophosphamide induced oxidative stress and inflammation in Wistar rats: role of NFkB/MAPK pathway. *Chemico-biological interactions*. 2015;231:98-107. <https://doi.org/10.1016/j.cbi.2015.02.021> PMID:25753322
- El-Sheikh AA, Rifaai RA. Peroxisome proliferator activator receptor (PPAR)- $\gamma$  ligand, but not PPAR- $\alpha$ , ameliorates cyclophosphamide-induced oxidative stress and inflammation in rat liver. *PPAR research*. 2014;2014.
- Lata S, Singh S, NathTiwari K, Upadhyay R. Evaluation of the antioxidant and hepatoprotective effect of *Phyllanthus fraternus* against a chemotherapeutic drug cyclophosphamide. *Applied biochemistry and biotechnology*. 2014;173(8):2163-73. <https://doi.org/10.1007/s12010-014-1018-8> PMID:24993488
- Zarei M, Shivanandappa T. Amelioration of cyclophosphamide-induced hepatotoxicity by the root extract of *Decalepis hamiltonii* in mice. *Food and chemical toxicology*. 2013;57:179-84. <https://doi.org/10.1016/j.fct.2013.03.028> PMID:23542512
- Marinello AJ, Gurtoo HL, Struck RF, Paul B. Denaturation of cytochrome P-450 by cyclophosphamide metabolites. *Biochemical and biophysical research communications*. 1978;83(4):1347-53. [https://doi.org/10.1016/0006-291X\(78\)91369-4](https://doi.org/10.1016/0006-291X(78)91369-4)
- Zhu H, Long MH, Wu J, Wang MM, Li XY, Shen H, Xu JD, Zhou L, Fang ZJ, Luo Y, Li SL. Ginseng alleviates cyclophosphamide-induced hepatotoxicity via reversing disordered homeostasis of glutathione and bile acid. *Scientific reports*. 2015;5:17536. <https://doi.org/10.1038/srep17536> PMID:26625948 PMID:PMC4667192
- Souid AK, Tacka KA, Galvan KA, Penefsky HS. Immediate effects of anticancer drugs on mitochondrial oxygen consumption. *Biochemical pharmacology*. 2003;66(6):977-87. [https://doi.org/10.1016/S0006-2952\(03\)00418-0](https://doi.org/10.1016/S0006-2952(03)00418-0)
- Kim HG, Yoon DH, Lee WH, Han SK, Shrestha B, Kim CH, Lim MH, Chang W, Lim S, Choi S, Song WO. *Phellinus linteus* inhibits inflammatory mediators by suppressing redox-based NF-kB and MAPKs activation in lipopolysaccharide-induced RAW 264.7 macrophage. *Journal of ethnopharmacology*. 2007;114(3):307-15. <https://doi.org/10.1016/j.jep.2007.08.011> PMID:17936530
- Haque R, Bin-Hafeez B, Ahmad I, Parvez S, Pandey S, Raisuddin S. Protective effects of *Emblca officinalis* Gaertn. in cyclophosphamide-treated mice. *Human & experimental toxicology*. 2001;20(12):643-50. <https://doi.org/10.1191/096032701718890568> PMID:11936579
- Kumar KB, Kuttan R. Chemoprotective activity of an extract of *Phyllanthus amarus* against cyclophosphamide induced toxicity in mice. *Phytomedicine*. 2005;12(6):494-500. <https://doi.org/10.1016/j.phymed.2004.03.009> PMID:16008127
- Sharma N, Trikha P, Athar M, Raisuddin S. Inhibitory effect of *Emblca officinalis* on the in vivo clastogenicity of benzo alypyrene and acyclophosphamide in mice. *Human & experimental toxicology*. 2000;19(6):377-84. <https://doi.org/10.1191/096032700678815945> PMID:10962512

21. Verdrengh M, Jonsson IM, Holmdahl R, Tarkowski A. Genistein as an anti-inflammatory agent. *Inflammation Research*. 2003;52(8):341-6. <https://doi.org/10.1007/s00011-003-1182-8> PMID:14504672
22. Ogbuewu IP, Uchegbu MC, Emenalom OO, Okoli IC, Iloeje MU. Overview of the chemistry of soy isoflavones, potential threats and potential therapeutic benefits. *Electronic Journal of Environmental, Agricultural & Food Chemistry*. 2010;9(4).
23. Ganai AA, Khan AA, Malik ZA, Farooqi H. Genistein modulates the expression of NF- $\kappa$ B and MAPK (p-38 and ERK1/2), thereby attenuating d-Galactosamine induced fulminant hepatic failure in Wistar rats. *Toxicology and applied pharmacology*. 2015;283(2):139-46. <https://doi.org/10.1016/j.taap.2015.01.012> PMID:25620059
24. Borrás C, Gambini J, Gómez-Cabrera MC, Sastre J, Pallardó FV, Mann GE, Vi-a J. Genistein, a soy isoflavone, up-regulates expression of antioxidant genes: involvement of estrogen receptors, ERK1/2, and NF $\kappa$ B. *The FASEB Journal*. 2006;20(12):2136-8. <https://doi.org/10.1096/fj.05-5522fje> PMID:16966488
25. Saleh DO, El-Awdan SA, Nofel SM, El-Eraky WI, El-Khatib AS, Kenawy SA. Estrogens improve the cardiovascular alterations in fructose-induced insulin resistant ovariectomized rats. *International Journal of Pharmacy and Pharmaceutical Sciences*. 2015;7(7):241-7.
26. Kuzu N, Metin K, Dagli AF, Akdemir F, Orhan C, Yalniz M, Ozercan IH, Sahin K, Bahcecioğlu IH. Protective role of genistein in acute liver damage induced by carbon tetrachloride. *Mediators of inflammation*. 2007;2007.
27. Saleh DO, Abdel Jaleel GA, El-Awdan SA, Oraby F, Badawi M. Thioacetamide-induced liver injury: protective role of genistein. *Canadian journal of physiology and pharmacology*. 2014;92(11):965-73. <https://doi.org/10.1139/cjpp-2014-0192> PMID:25358106
28. Vera R, Galisteo M, Villar IC, Sanchez M, Zarzuelo A, Pérez-Vizcaíno F, Duarte J. Soy isoflavones improve endothelial function in spontaneously hypertensive rats in an estrogen-independent manner: role of nitric-oxide synthase, superoxide, and cyclooxygenase metabolites. *Journal of Pharmacology and Experimental Therapeutics*. 2005;314(3):1300-9. <https://doi.org/10.1124/jpet.105.085530> PMID:15958720
29. Saleh DO, Mansour DF. Ovario-protective effects of genistein against cyclophosphamide toxicity in rats: Role of anti-müllerian hormone and oestradiol. *European journal of pharmacology*. 2016;789:163-71. <https://doi.org/10.1016/j.ejphar.2016.07.026> PMID:27448503
30. Reitman S, Frankel S. A colorimetric method for the determination of serum glutamic oxalacetic and glutamic pyruvic transaminases. *American journal of clinical pathology*. 1957;28(1):56-63. <https://doi.org/10.1093/ajcp/28.1.56> PMID:13458125
31. Beutler E. Improved method for determination of blood glutathione. *J Lab Clin Med*. 1963;61(5):882-8. PMID:13967893
32. Uchiyama M, Mihara M. Determination of malonaldehyde precursor in tissues by thiobarbituric acid test. *Analytical biochemistry*. 1978;86(1):271-8. [https://doi.org/10.1016/0003-2697\(78\)90342-1](https://doi.org/10.1016/0003-2697(78)90342-1)
33. Miranda KM, Espey MG, Wink DA. A rapid, simple spectrophotometric method for simultaneous detection of nitrate and nitrite. *Nitric oxide*. 2001;5(1):62-71. <https://doi.org/10.1006/niox.2000.0319> PMID:11178938
34. Roelofs JJ, Rouschop KM, Leemans JC, Claessen N, de Boer AM, Frederiks WM, Lijnen HR, Weening JJ, Florquin S. Tissue-type plasminogen activator modulates inflammatory responses and renal function in ischemia reperfusion injury. *Journal of the American society of nephrology*. 2006;17(1):131-40. <https://doi.org/10.1681/ASN.2005010089> PMID:16291841
35. Bancroft J, Stevens A, Turner D. *Theory and practice of histological techniques*: Churchill Livingstone New York. the text, 1996:766.
36. Weijl N, Cleton F, Osanto S. Free radicals and antioxidants in chemotherapy-induced toxicity. *Cancer treatment reviews*. 1997; 23:209-240. [https://doi.org/10.1016/S0305-7372\(97\)90012-8](https://doi.org/10.1016/S0305-7372(97)90012-8)
37. Subramaniam SR, Cader RA, Mohd R, Yen KW, Ghafor HA. Low-dose cyclophosphamide-induced acute hepatotoxicity. *The American journal of case reports*. 2013;14:345. <https://doi.org/10.12659/AJCR.889401> PMID:24023976 PMID:PMC3767583
38. Yagalakshmi B, Viswanathan P, Anuradha CV. Investigation of antioxidant, anti-inflammatory and DNA-protective properties of eugenol in thioacetamide-induced liver injury in rats. *Toxicology*. 2010;268(3):204-12. <https://doi.org/10.1016/j.tox.2009.12.018> PMID:20036707
39. Senthilkumar S, Devaki T, Manohar BM, Babu MS. Effect of squalene on cyclophosphamide-induced toxicity. *Clinica Chimica Acta*. 2006;364(1):335-42. <https://doi.org/10.1016/j.cca.2005.07.032> PMID:16150433
40. Podrez EA, Abu-Soud HM, Hazen SL. Myeloperoxidase-generated oxidants and atherosclerosis. *Free Radical Biology and Medicine*. 2000;28(12):1717-25. [https://doi.org/10.1016/S0891-5849\(00\)00229-X](https://doi.org/10.1016/S0891-5849(00)00229-X)
41. Rao AM, Anand U, Anand CV. Myeloperoxidase in chronic kidney disease. *Indian Journal of Clinical Biochemistry*. 2011;26(1):28-31. <https://doi.org/10.1007/s12291-010-0075-1> PMID:22211010 PMID:PMC3068762
42. Fouad AA, Qutub HO, Al-Melhim WN. Punicalagin alleviates hepatotoxicity in rats challenged with cyclophosphamide. *Environmental toxicology and pharmacology*. 2016;45:158-62. <https://doi.org/10.1016/j.etap.2016.05.031> PMID:27310207
43. Ghosh S, Hayden MS. New regulators of NF- $\kappa$ B in inflammation. *Nature Reviews Immunology*. 2008;8(11):837-48. <https://doi.org/10.1038/nri2423> PMID:18927578
44. Jnaneshwari S, Hemshekhar M, Thushara RM, Shanmuga Sundaram M, Sebastin Santhosh M, Sunitha K, Shankar RL, Kemparaju K, Girish KS. Sesamol ameliorates cyclophosphamide-induced hepatotoxicity by modulating oxidative stress and inflammatory mediators. *Anti-Cancer Agents in Medicinal Chemistry (Formerly Current Medicinal Chemistry-Anti-Cancer Agents)*. 2014;14(7):975-83.
45. Lau DT, Luxon BA, Xiao SY, Beard MR, Lemon SM. Intrahepatic gene expression profiles and alpha-smooth muscle actin patterns in hepatitis C virus induced fibrosis. *Hepatology*. 2005;42(2):273-81. <https://doi.org/10.1002/hep.20767> PMID:15986378
46. Rimbach G, De Pascual-Teresa S, Ewins BA, Matsugo S, Uchida Y, Minihane AM, Turner R, Vafei Adou K, Weinberg PD. Antioxidant and free radical scavenging activity of isoflavone metabolites. *Xenobiotica*. 2003;33(9):913-25. <https://doi.org/10.1080/0049825031000150444> PMID:14514441
47. Aneja R, Upadhyaya G, Prakash S, Dass SK, Chandra R. Ameliorating effect of phytoestrogens on CCl4-induced oxidative stress in the livers of male Wistar rats. *Artificial cells, blood substitutes, and biotechnology*. 2005;33(2):201-13. <https://doi.org/10.1081/BIO-200055908>
48. Lee JS. Effects of soy protein and genistein on blood glucose, antioxidant enzyme activities, and lipid profile in streptozotocin-induced diabetic rats. *Life sciences*. 2006;79(16):1578-84. <https://doi.org/10.1016/j.lfs.2006.06.030> PMID:16831449
49. Wei H, Bowen R, Cai Q, Barnes S, Wang Y. Antioxidant and antipromotional effects of the soybean isoflavone genistein. *Proceedings of the Society for Experimental Biology and Medicine*. 1995;208(1):124-30. <https://doi.org/10.3181/00379727-208-43844> PMID:7892286
50. Huang Q, Huang R, Zhang S, Lin J, Wei L, He M, Zhuo L, Lin X. Protective effect of genistein isolated from *Hydrocotyle sibthorpioides* on hepatic injury and fibrosis induced by chronic alcohol in rats. *Toxicology letters*. 2013;217(2):102-10. <https://doi.org/10.1016/j.toxlet.2012.12.014> PMID:23274713
51. Mizutani K, Ikeda K, Nishikata T, Yamori Y. Phytoestrogens

attenuate oxidative DNA damage in vascular smooth muscle cells from stroke-prone spontaneously hypertensive rats. *Journal of hypertension*. 2000;18(12):1833-40.

<https://doi.org/10.1097/00004872-200018120-00018>

PMid:11132608

52. Yalniz M, Bahcecioglu IH, Kuzu N, Poyrazoglu OK, Bulmus O, Celebi S, Ustundag B, Ozercan IH, Sahin K. Preventive role of genistein in an experimental non-alcoholic steatohepatitis model. *Journal of gastroenterology and hepatology*. 2007;22(11):2009-14.

<https://doi.org/10.1111/j.1440-1746.2006.04681.x> PMid:17914984

53. Wang J, Mazza G. Inhibitory effects of anthocyanins and other phenolic compounds on nitric oxide production in LPS/IFN- $\gamma$ -activated RAW 264.7 macrophages. *Journal of Agricultural and Food Chemistry*. 2002;50(4):850-7.

<https://doi.org/10.1021/jf010976a> PMid:11829656

54. Hämäläinen M, Nieminen R, Vuorela P, Heinonen M, Moilanen E. Anti-inflammatory effects of flavonoids: genistein, kaempferol, quercetin, and daidzein inhibit STAT-1 and NF- $\kappa$ B activations, whereas flavone, isorhamnetin, naringenin, and pelargonidin inhibit only NF- $\kappa$ B activation along with their inhibitory effect on iNOS expression and NO production in activated macrophages. *Mediators of inflammation*. 2007;2007.

55. Guo Q, Rimbach G, Packer L. Nitric oxide formation in macrophages detected by spin trapping with iron-dithiocarbamate complex: effect of purified flavonoids and plant extracts. *Methods in enzymology*. 2001;335:273-82. [https://doi.org/10.1016/S0076-6879\(01\)35250-3](https://doi.org/10.1016/S0076-6879(01)35250-3)