

Cutaneous Angioleiomyoma – A Rare Cause of Posterior Heel Pain: A Case Report

Uwe Wollina^{1*}, Jacqueline Schönlebe², Georgi Tchernev³, Serena Gianfaldoni⁴, Torello Lotti⁴

¹Department of Dermatology and Allergology, Academic Teaching Hospital of the Technical University of Dresden, 01067 Dresden, Germany; ²Institute of Pathology “Georg Schmoll”, Hospital Dresden-Friedrichstadt, Academic Teaching Hospital of the Technical University of Dresden, 01067 Dresden, Germany; ³Department of Dermatology, Venereology and Dermatologic Surgery, Medical Institute of Ministry of Interior, and Onkoderma Polyclinic for Dermatology and Dermatologic Surgery, Sofia, Bulgaria; ⁴University of Rome G. Marconi, Rome, Italy

Abstract

Heel pain is a common presentation in outpatient clinics. Here, we report a 69-year-old woman who complaint about a painful nodule on her left posterior heel. There was no history of trauma. The lesion developed during ten weeks without any bleeding or ulceration. On examination, we observed a subcutaneous firm nodule of about 1 cm in diameter. The lesion was hypoechoic in diagnostic sonography suggesting a fibromatous tumour, which was removed surgically. Histologic investigations confirmed the diagnosis of cutaneous angioleiomyoma. The occurrence of this benign tumour on the heel is quite uncommon but obvious a possible cause for heel pain. During follow-up, no recurrence was observed.

Citation: Wollina U, Schönlebe J, Tchernev G, Gianfaldoni S, Lotti T. Cutaneous Angioleiomyoma – A Rare Cause of Posterior Heel Pain: A Case Report. Open Access Maced J Med Sci. 2017 Jul 25; 5(4):436-438. <https://doi.org/10.3889/oamjms.2017.110>

Keywords: angioleiomyoma; heel pain; histology; immunohistology; surgery.

***Correspondence:** Uwe Wollina. Department of Dermatology and Allergology, Academic Teaching Hospital Dresden-Friedrichstadt, Friedrichstr. 41, 01067 Dresden, Germany. E-mail: wollina-uw@khdf.de

Received: 15-Apr-2017; Revised: 21-Apr-2017; Accepted: 22-Apr-2017; Online first: 19-Jul-2017

Copyright: © 2017 Uwe Wollina, Jacqueline Schönlebe, Georgi Tchernev, Serena Gianfaldoni, Torello Lotti. This is an open-access article distributed under the terms of the Creative Commons Attribution-NonCommercial 4.0 International License (CC BY-NC 4.0).

Funding: This research did not receive any financial support.

Competing Interests: The authors have declared that no competing interests exist.

Introduction

Cutaneous angioleiomyoma (ALM) is a benign smooth-muscle tumour. It occurs in several subtypes, i.e. venous, cavernous, solid, and lipomatous AL. The tumours can develop a variable degree of hyalinization or calcification. The vascular subtypes show a predilection for the lower limbs [1-3].

These tumours represent as painful well-circumscribed nodules in about 50% of cases. AL can occur at any age but reach a peak incidence between the 4th and 6th decade of life. Women are almost as double as much affected as men [4].

The following case report points to AL as a rare possible cause for heel pain.

Case Report

A 69-year-old woman presented with a painful nodule on her left posterior heel. She did not remember any trauma. The lesion developed during ten weeks without any bleeding or ulceration. Her medical history was unremarkable so far. She had no medications.

On examination, we observed a firm subcutaneous nodule covered by a callus reaction of skin on the left posterior heel of approximately 1 cm in diameter (Fig. 1a). Sonographic examination described a 10 x 7 x 5 mm large subcutaneous, well circumscribed, hypoechoic lesion closely related but not attached to the Achilles tendon.

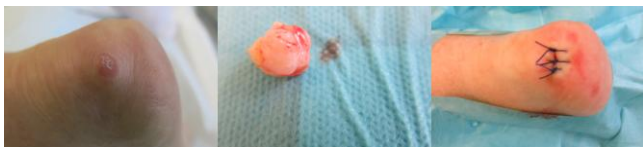

Figure 1: Cutaneous angioleiomyoma on the left heel. (a) Clinical presentation as a firm subcutaneous nodule covered by epidermal callus formation (left). (b) Surgical specimen of a well-circumscribed tumour with a smooth surface (middle). (c) After wound closure (right)

We performed surgery under local anaesthesia to remove the lesion completely and obtain a histopathologically confirmed diagnosis. During surgery, we observed a well circumscribed firm tumour of about 1 cm in diameter with a smooth pseudocapsular surface (Fig. 1b). The tumour was not attached to deeper structures but skin.

The wound was sutured, and the subsequent healing process was uneventful (Fig. 1c).

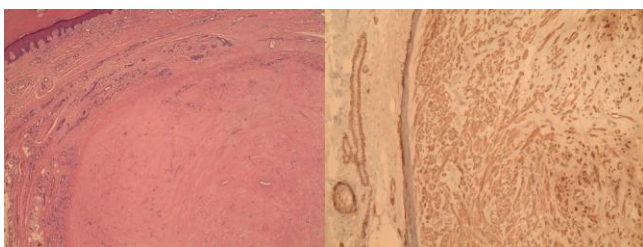


Figure 2: Histological examination of cutaneous angioleiomyoma. (a) A nodular hyalinized tumor of dermis and upper subcutaneous tissue with a pseudo capsule covered by hyperplastic, compact, orthokeratotic epidermis (hematoxylin-eosin, x 4) (left); (b) The tumor consisted of actin-positive spindle cells with uniform oval nuclei without atypia or increased mitotic activity (immunoperoxidase stain with monoclonal actin-antibody, x 10) (right)

Histologic examination revealed a nodular hyalinized tumour of the dermis and upper subcutaneous tissue covered by hyperplastic, compact, orthokeratotic epidermis. The tumour consisted of actin-positive spindle cells with uniform oval nuclei without atypia or increased mitotic activity. The vascular component was CD34-positive with thickened vessel walls. There was no expression of S100 (Fig. 2).

The diagnosis of AL, the venous type with hyalinization, was made. During follow-up of 12 months, no recurrence occurred.

Discussion

Our patient presented with posterior heel pain. Heel pain is not uncommon in outpatient clinics. Several differential diagnoses have to be considered. Plantar fasciitis is the most common cause, with medial plantar heel pain after long periods of rest. A

calcaneal stress fracture is progressively worsening during activity. Nerve entrapment, heel pad syndrome, neuromas, plantar warts, Achilles tendinopathy, Haglund deformity of the calcaneus, tarsal tunnel syndrome or sinus tarsi syndrome are other possible pathologies causing heel pain as well [5].

AL has rarely been described on the heel [6-9]. Since the tumours may be painful AL is an important differential diagnosis in heel pain, independent from the level of calcification.

AL is a benign tumour of smooth muscle origin. Diagnostic sonography demonstrates a well circumscribed hypoechoic nodule. AL has a characteristic histopathology that confirms the clinically suspected diagnosis [4]. In contrast to sporadic infantile or solitary adult myofibrosarcomas somatic mutations of platelet-derived growth factor-receptor B are absent among AL's [10]. Treatment of choice is surgery, and the patient will become pain-free. In the case of complete excision, relapses are very uncommon [11].

The rare occurrence of AL on the heel and its clinical presentation as chronic heel pain prompted us to report this case. AL is a rare but possible cause of heel pain – in the present case of posterior heel pain. Complete pain-free remission is achieved by surgical removal of the benign tumour

References

- Kacerovska D, Michal M, Kreuzberg B, Mukensnabl P, Kazakov DV. Acral calcified vascular leiomyoma of the skin: a rare clinicopathological variant of cutaneous vascular leiomyomas: report of 3 cases. *J Am Acad Dermatol.* 2008; 59:1000-1004. <https://doi.org/10.1016/j.jaad.2008.07.008> PMID:19022102
- Upreti S, Morine A, Ng D, Bigby SM. Lipomatous variant of angiofibrosarcoma: a case report and review of the literature. *J Cutan Pathol.* 2015;42:222-226. <https://doi.org/10.1111/cup.12450> PMID:25407897
- Díaz-Flores L, Gutiérrez R, Alvarez-Argüelles H, González-Gómez M, García Mdel P, Díaz-Flores L Jr. Ultrastructure and histogenesis of the acral calcified angioleiomyoma. *Ultrastruct Pathol.* 2016;40:24-32. <https://doi.org/10.3109/01913123.2015.1120839> PMID:26691377
- Zhang JZ, Zhou J, Zhang ZC. Subcutaneous angioleiomyoma: clinical and sonographic features with histopathologic correlation. *J Ultrasound Med.* 2016;35:1669-1673. <https://doi.org/10.7863/ultra.15.06056> PMID:27371376
- Tu P, Bytomski JR. Diagnosis of heel pain. *Am Fam Physician.* 2011;84:909-916. PMID:22010770
- Pastore RL, Ianiro G. Cutaneous angioleiomyoma. *J Am Podiatr Med Assoc.* 1999;89:145-147. <https://doi.org/10.7547/87507315-89-3-145> PMID:10095339
- Murata H, Matsui T, Horie N, Sakabe T, Konishi E, Kubo T. Angioleiomyoma with calcification of the heel: report of two cases. *Foot Ankle Int.* 2007;28:1021-1025. <https://doi.org/10.3113/FAI.2007.1021> PMID:17880879
- Cheung MH, Lui TH. Plantar heel pain due to vascular leiomyoma (angioleiomyoma). *Foot Ankle Spec.* 2012;5:521-523. <https://doi.org/10.1177/1938640012457677> PMID:22935412

9. Szolomayer LK, Talusan PG, Chan WF, Lindskog DM. Leiomyoma of the foot and ankle: A case series. *Foot Ankle Spec.* 2016;pii: 1938640016670243. [Epub ahead of print]. PMID:27654461

10. Agaimy A, Bieg M, Michal M, Geddert H, Märkl B, Seitz J, Moskalev EA, Schlesner M, Metzler M, Hartmann A, Wiemann S, Michal M, Mentzel T, Haller F. Recurrent somatic PDGFRB mutations in sporadic infantile/solitary adult myofibromas but not in angioleiomyomas and myopericytomas. *Am J Surg Pathol.*

2017;41(2):195-203.

<https://doi.org/10.1097/PAS.0000000000000752> PMID:27776010

11. Scapinelli R, Iacobellis C, Tagliavoro G, Blandamura S, Baggio ME. Vascular leiomyoma of the limbs. *Chir Organi Mov.* 2001;86:143-152. PMID:12025046