

Madelung's Disease – Case Series and Treatment by Tumescant Liposuction or Lipectomy

Uwe Wollina^{1*}, Birgit Heinig²

¹Department of Dermatology and Allergology, Academic Teaching Hospital Dresden-Friedrichstadt in Dresden, Dresden, Germany; ²Center for Physical and Rehabilitative Medicine, Hospital Dresden-Friedrichstadt, Academic Teaching Hospital, Friedrichstrasse 41, 01067, Dresden, Germany

Abstract

Citation: Wollina U, Heinig B. Madelung's Disease – Case Series and Treatment by Tumescant Liposuction or Lipectomy. Open Access Maced J Med Sci. 2017 Jul 25; 5(4):427-431. https://doi.org/10.3889/oamjms.2017.114

Keywords: Lipomatosis; Madelung disease; adipose tissue; comorbidities; lipectomy; tumescant liposuction.

***Correspondence:** Uwe Wollina, Department of Dermatology and Allergology, Academic Teaching Hospital Dresden-Friedrichstadt, Friedrichstr. 41, 01067 Dresden, Germany. E-mail: wollina-uw@khd.f.de

Received: 07-Apr-2017; Revised: 22-Apr-2017; Accepted: 23-Apr-2017; Online first: 19-Jul-2017

Copyright: © 2017 Uwe Wollina, Birgit Heinig. This is an open-access article distributed under the terms of the Creative Commons Attribution-NonCommercial 4.0 International License (CC BY-NC 4.0).

Funding: This research did not receive any financial support.

Competing Interests: The authors have declared that no competing interests exist.

Madelung disease is a disfiguring disorder belonging to the heterogeneous group of lipomatosis. The aetiology is not well understood, but alcohol consumption has been regarded as of importance. The reported incidence is about 1 in 25,000 inhabitants. We reviewed our files of the last ten years and identified eight adult patients with an equal gender distribution. Their age was between 60 and 85 years of life. Comorbidities are frequent. Clinical presentation may vary. Surgical treatment is reported and discussed. Both cold steel surgery and tumescant liposuction have their place in treatment.

Introduction

Madelung's disease (MD) is a rare disorder of adipose tissue, characterised by disfiguring massive non-capsulated adipose tissue proliferations in the neck, shoulder, and the arms. It may be associated with gynecomastia or lipomastia nearly one-third of patients. The age peak is between 30 to 60 years of age with a male to female-ratio of 15:1 to 30:1. The incidence is about one affected person in 25,000 inhabitants. Most cases are sporadic patients [1, 2].

The aetiology of MD is not well understood. Since 86 to > 95% of patients report chronic alcohol consumption, secondary metabolic effect may be of importance [2, 3]. Alcohol can induce abnormalities in the catecholamine-adipose tissue interactions. Adrenergic lipolysis becomes impaired and may result in excessive adipose tissue. Furthermore, a reduction of mitochondrial enzymes and increased adipose tissue lipoprotein-lipase activity have been reported [4].

Adipocytes in MD seem to be closer to brown adipocytes than to white adipocytes according to ultrastructural investigations. In culture, pre-

adipocytes of MD develop large mitochondria with parallel cristae and show multi-vacuolar lipid deposits [5]. Investigations on cultured pre-adipocytes demonstrated synthesis of inner mitochondrial membrane protein UCP-1, which is a selective marker of brown adipose tissue (BAT) [6]. There are more arguments supporting MD as a disease of BAT: uncoupling protein-1 mRNA (selective BAT marker), and adipocyte fatty-acid protein-2 (a selective marker of BAT and immature adipocytes) have been observed in patients with MD in affected adipose tissue [4].

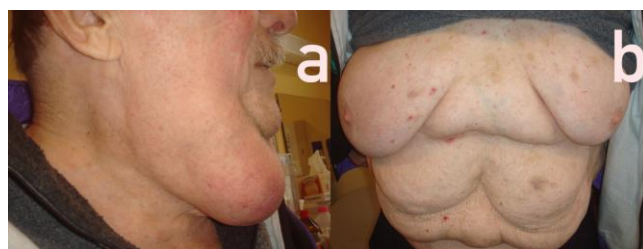

Figure 1: Madelung's disease with major disfigurement (Case 1). (a) Massive enlargement of subcutaneous adipose tissue under the chin; (b) Severe gynecomastia

Comparing affected and non-affected adipocytes of patients with MD disclosed not

differences in their surface marker profile. However, adipose tissue-derived stem cells had a higher proliferative activity. There were marked changes in the genetic profile for proliferation control, mitochondria, and hormonal regulation demonstrated by polymerase chain reaction (PCR) arrays [7].

MD patients show multiple comorbidities, such as hepatic disease (60%), metabolic syndrome (40%), chronic obstructive pulmonary disease (COPD; 23%), hypothyroidism (10%), malignant tumors of the upper airways (rarely), and chronic alcohol consumption (> 95%) [2].

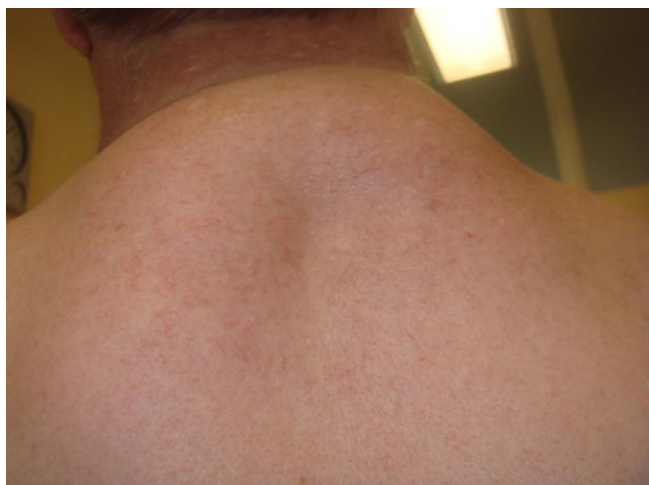

Figure 2: Moderate growth of adipose tissue of the neck in Madelung's disease with development of multiple telangiectasias (Case 2)

MD must be differentiated from Cushing syndrome and syndromic lipomatosis types of the head and neck region such as Familial Multiple Lipomatosis (FML), Encephalo-Cranio-Cutaneous Lipomatosis (ECCL), Congenital Infiltrating Lipomatosis of the Face (CIL-F), and Nasopalpebral Lipoma-Coloboma Syndrome (NLCS) [8, 9].

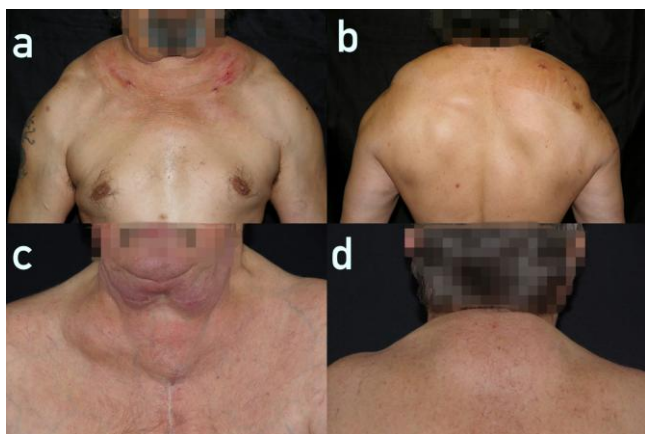

Figure 3: Improvement of Madelung's disease by tumescent liposuction (Case 3). Before treatment (a, b) and after liposuction (c, d)

Patients and Methods

We searched our files for patients with MD seen at the Department of Dermatology and Allergology during 2007 to 2017, their clinical presentation, comorbidities, and three cases of surgical treatment.

Results

We identified eight adult patients with MD, four males and four females. Most patients had significant metabolic comorbidities. Two underwent bypass surgery after myocardial infarction; two suffered from renal insufficiency. The demographics and co-morbidities are summarised in Table 1 and Figures 1 - 8.

Table 1: Demographics, clinical findings, and comorbidities in MD

Patient	Age (years)	Gender	Affected areas	Co-morbidities
1	75	Male	Neck, shoulders, gynecomastia	Hepatocellular carcinoma, alcoholic liver cirrhosis, compensated renal insufficiency
2	67	Male	Neck	Hypertension
3	68	Male	Neck, shoulders, upper arms, gynecomastia	Metabolic syndrome, myocardial infarction with bypass surgery, gonarthrosis
4	60	Female	Neck, shoulders	Cervical spine syndrome, bullous pemphigoid,
5	84	Female	Neck, upper back	myocardial infarction with bypass surgery, diabetes mellitus type II, arterial hypertension, osteoporosis
6	66	Female	Neck, shoulders, arms, lipomastia	Cervical spine syndrome
7	54	Male	Neck and upper back	Arterial hypertension, hypothyreosis, pulmonary fibrosis
8	79	Female	Neck, shoulders	Renal nephrectomy after renal cell carcinoma, chronic anaemia, chronic renal insufficiency, arterial hypertension, cholecystolithiasis, knee-TEP-surgery

Surgical treatment

Case 1 (Fig. 3)

A 68-year-old male patient presented with symmetrical progressive lipomatosis of MD-type. He suffered from impairment of neck mobility and pain sensations. Therefore, he wanted treatment for the neck region.

His medical history was positive for arterial hypertension, hyperlipidemia, bypass surgery after myocardial infarction 2013 with oral anticoagulation, and gonarthrosis of the right knee.

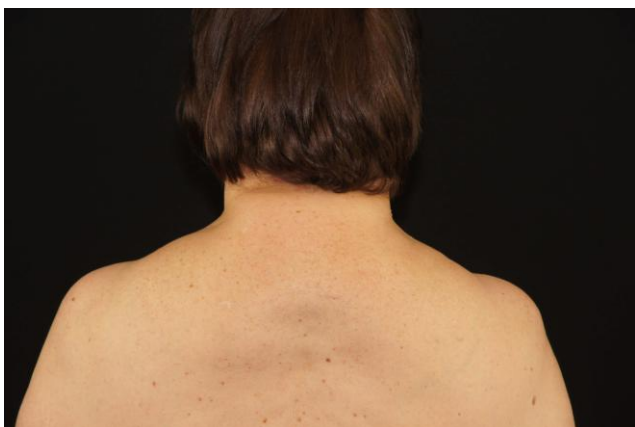

Figure 4: Moderate growth of subcutaneous adipose tissue with some telangiectasias (Case 4)

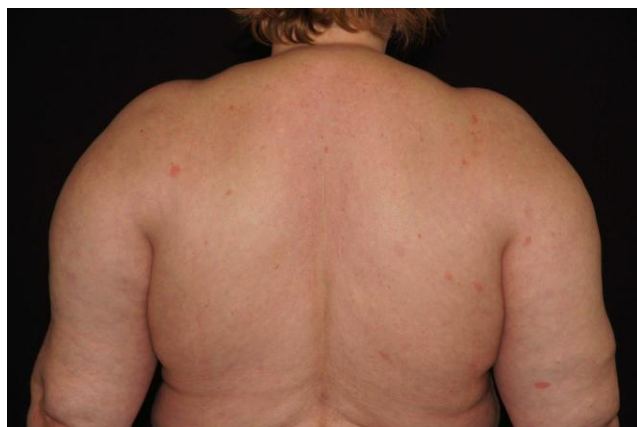

Figure 6: Pseudo-athletic appearance in Madelung's disease (Case 6)

On examination, there were massive disfiguring adipose tissue deposits on neck, shoulders, arms and gynecomastia. The largest neck circumference was 50 cm.

Case 2 (Fig. 7)

A 54-year-old male patient presented with longstanding, progressive subcutaneous, symmetrical adipose tissue deposits on the neck and upper back. He had a relapse after lipectomy.

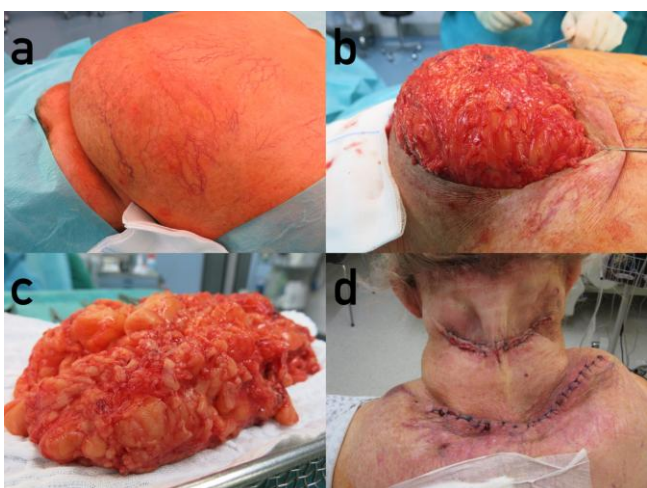


Figure 5: Massive tumor-like swelling of the neck (Case 5) with obvious telangiectasias (a). (b) Operation situs demonstrates non-encapsulated subcutaneous adipose tissue. (c) Resection specimen with massive enlarged adipocytes. (d) Two days after surgery

Laboratory investigations revealed the following pathologic parameters: GGT 3.45 μ kat/l, (normal range <1), CRP 15.4 mg/l (< 5), creatinin 111 μ mol/l (< 90).

Histology: the Diffuse non-septal proliferation of adult enlarged mono vacuolar adipocytes with infiltration of adjacent structures.

Treatment and Course: He had a lipectomy in a plastic surgical department six years ago that relapsed. We performed two sessions of tumescant liposuction. The total amount of lipoaspiration was 600 ml. The procedures were well tolerated. After the second liposuction, he developed a symptomatic methemoglobinemia that was treated by intravenous injection of toluidine blue solution.

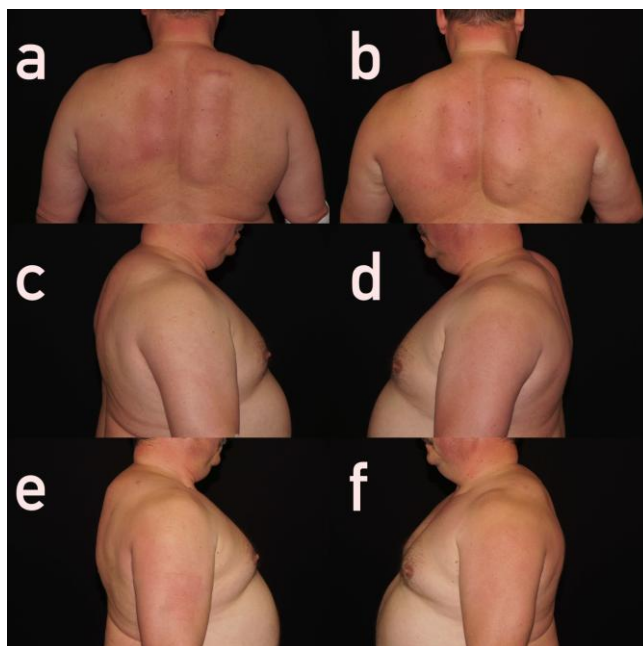

Figure 7: Fibrotic Madelung's disease with dynamic growth (a and b), relapse after lipectomy; Stepwise improvement by tumescant liposuction from (c, d) to (e, f)

Treatment and course: We treated him in 2014 by two tumescant liposuction sessions. Although the lipoaspirate was only 500 ml, he reported on significant improvement of pain sensations and mobility. After two years, he experienced a partial relapse that was treated again by tumescant liposuction with good functional results (lipoaspirate 200 ml).

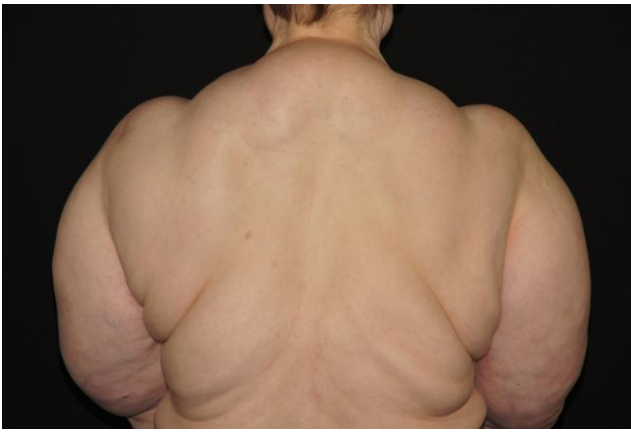

Figure 8: Massive disfigurement of the pseudo-athletic type of Madelung's disease (Case 8)

Case 3 (Fig. 5)

An 83-year-old female patient presented with large disfiguring lipoma-like subcutaneous masses of the neck region. We decided to perform combined lipectomy and dermato- lipectomy in general anaesthesia. Healing was unremarkable. The patient was satisfied by the functional and esthetic outcome. There was no relapse in the following 12 months.

Discussion

MD can lead to severe clinical complications, such as mediastinal syndrome, tracheobronchial obstruction, dysphagia, dysphonia, limited mobility of the neck, and somatic and autonomic neuropathies [6]. Such complications are an indication to surgical treatment [2, 10].

In the past, the only available treatment was open surgery [11]. Open surgery is characterised by a high rate of complications, mostly due to the severe comorbidities in MD patients. In a large series of 59 MD patients, complications by surgery (lipectomy/dermato- lipectomy) were observed in 17.8%. However, the authors preferred surgery in advanced cases [4].

Since relapses occur frequently, less invasive techniques were developed – either as adjuvant treatment or as a substitute for extensive classical surgery such as injection lipolysis and tumescent liposuction [12-14]. Injection lipolysis, however, causes fibrosis and adhesions which prohibit the use of liposuction in the case of recurrence and possibly complicates lipectomy surgery as well. It is therefore not considered as an ideal treatment for MD [15].

Tumescent liposuction is an established technique not only for esthetic procedures but a

variety of medical conditions. It offers a combination of adipose tissue removal and skin tightening [16].

Constandinidis et al. (2003) used a combined lipectomy and liposuction in 11 patients with MD. They started with lipectomy in the first place followed by liposuction in a second “course with liposuction” being done at a second session. Their mean follow-up was 2.7 years. Nine of 11 patients were satisfied with the esthetic outcome. Two relapses after 1.5 years and two years were observed [17].

In one study seven MD patients were treated by liposuction successfully. Mean follow-up of 18 months revealed a high patient satisfaction with the outcome of the procedure [18].

We report on ten adult patients with MD. The clinical presentation can vary widely concerning the areas involved and the degree of disfigurement and functional impairment. Both the clinical features of MD and the frequent occurrence of comorbidities has an impact on treatment options. In case 1, lipectomy had been performed before the patient present to our department, but there was a significant relapse. In this patient as well as in the more limited type seen in case 2, liposuction in tumescent anaesthesia was a useful and safe procedure leading to minor down-time without extensive scars. In more advanced situations, lipectomy and dermato- lipectomy may be used in the first place as demonstrated in case 3. Surgical approaches are the only treatment options with a significant improvement of MD, often with improved functionality and satisfying esthetic outcome. Although alcohol abuse is a common pathology, there is no scientific proof for reduced risk of progression and relapses if the patient stops alcohol consumption. Nevertheless, comorbidities need to be considered for an optimal long-term outcome of patients with MD.

References

- González-García R, Rodríguez-Campo FJ, Sastre-Pérez J, Muñoz-Guerra MF. Benign symmetric lipomatosis (Madelung's disease): case reports and current management. *Aesthetic Plast Surg.* 2004;28(2):108-12. <https://doi.org/10.1007/s00266-004-3123-5> PMID:15164232
- Brea-García B, Comeselle-Teijeiro J, Couto-González I, Taboada-Suárez A, González-Álvarez E. Madelung's disease: comorbidities, fatty mass distribution, and response to treatment of 22 patients. *Aesthetic Plast Surg.* 2013;37(2):409-16. <https://doi.org/10.1007/s00266-012-9874-5>
- Pinto CI, Carvalho PJ, Correia MM. Madelung's disease: Revision of 59 surgical Cases. *Aesthetic Plast Surg.* 2016.
- Plummer C, Spring PJ, Marotta R, Chin J, Taylor G, Sharpe D, Athanasou NA, Thyagarajan D, Berkovic SF. Multiple symmetrical lipomatosis--a mitochondrial disorder of brown fat. *Mitochondrion.* 2013;13(4):269-76. <https://doi.org/10.1016/j.mito.2013.03.003> PMID:23524250
- Zancanaro C, Sbarbati A, Morroni M, Carraro R, Cigolini M, Enzi G, Cinti S. Multiple symmetric lipomatosis. Ultrastructural

- investigation of the tissue and preadipocytes in primary culture. *Lab Invest.* 1990;63(2):253-8. PMID:2381166
6. Enzi G, Busetto L, Sergi G, Coin A, Inelmen EM, Vindigni V, Bassetto F, Cinti S. Multiple symmetric lipomatosis: a rare disease and its possible links to brown adipose tissue. *Nutr Metab Cardiovasc Dis.* 2015;25(4):347-53. <https://doi.org/10.1016/j.numecd.2015.01.010> PMID:25770761
7. Prantl L, Schreml J, Gehmert S, Klein S, Bai X, Zeitler K, Schreml S, Alt E, Gehmert S, Felthaus O. Transcription profile in sporadic multiple symmetric lipomatosis reveals differential expression at the level of adipose tissue-derived stem cells. *Plast Reconstr Surg.* 2016;137(4):1181-90. <https://doi.org/10.1097/PRS.0000000000002013> PMID:27018673
8. Horev L, Lees MM, Anteby I, Gomori JM, Gunny R, Ben-Neriah Z. Oculoectodermal syndrome with coarctation of the aorta and moyamoya disease: expanding the phenotype to include vascular anomalies. *Am J Med Genet A.* 2011;155A(3):577-81. <https://doi.org/10.1002/ajmg.a.33104> PMID:21337683
9. Tadisina KK, Mlynek KS, Hwang LK, Riazi H, Papay FA, Zins JE. Syndromic lipomatosis of the head and neck: a review of the literature. *Aesthetic Plast Surg.* 2015;39(3):440-8. <https://doi.org/10.1007/s00266-015-0478-8> PMID:25860506
10. Sharma N, Hunter-Smith DJ, Rizzitelli A, Rozen WM. A surgical view on the treatment of Madelung's disease. *Clin Obes.* 2015;5(5):288-90. <https://doi.org/10.1111/cob.12111> PMID:26246230
11. Brackenbury ET, Morgan WE. Surgical management of Launois-Bensaude syndrome. *Thorax.* 1997;52(9):834-5. PMID:9371221
12. Samdal F, Kleppe G, Tonvang G. Benign symmetric lipomatosis of the neck treated by liposuction. Case report. *Scand J Plast Reconstr Surg Hand Surg.* 1991;25(3):281-4. <https://doi.org/10.3109/02844319109020633> PMID:1780727
13. Faga A, Valdatta LA, Thione A, Buoro M. Ultrasound assisted liposuction for the palliative treatment of Madelung's disease: a case report. *Aesthetic Plast Surg.* 2001;25(3):181-3. <https://doi.org/10.1007/s002660010118> PMID:11426308
14. Hasegawa T, Matsukura T, Ikeda S. Mesotherapy for benign symmetric lipomatosis. *Aesthetic Plast Surg.* 2010;34(2):153-6. <https://doi.org/10.1007/s00266-009-9374-4> PMID:19488808
15. Andou E, Komoto M, Hasegawa T, Mizuno H, Hayashi A. Surgical excision of Madelung disease using bilateral cervical lymphnode dissection technique-its effect and the influence of previous injection lipolysis. *Plast Reconstr Surg Glob Open.* 2015;3(4):e375. <https://doi.org/10.1097/GOX.0000000000000337> PMID:25973353 PMID:PMC4422206
16. Atiyeh B, Costagliola M, Illouz YG, Dibo S, Zgheib E, Rampillon F. Functional and therapeutic indications of liposuction: Personal experience and review of the literature. *Ann Plast Surg.* 2015;75(2):231-45. <https://doi.org/10.1097/SAP.0000000000000055> PMID:25695452
17. Constantinidis J, Steinhart H, Zenk J, Gassner H, Iro H. Combined surgical lipectomy and liposuction in the treatment of benign symmetrical lipomatosis of the head and neck. *Scand J Plast Reconstr Surg Hand Surg.* 2003;37(2):90-6. <https://doi.org/10.1080/02844310310005612> PMID:12755508
18. Tremp M, Wettstein R, Tchang LA, Schaefer DJ, Rieger UM, Kalbermatten DF. Power-assisted liposuction (PAL) of multiple symmetric lipomatosis (MSL)--a longitudinal study. *Surg Obes Relat Dis.* 2015;11(1):155-60. PMID:25973353