

Incontinentia Pigmenti: A Case Report of a Complex Systemic Disease

Serena Gianfaldoni^{1*}, Georgi Tchernev², Uwe Wollina³, Torello Lotti⁴

¹University G. Marconi of Rome, Dermatology and Venereology, Rome 00192, Italy; ²Medical Institute of the Ministry of Interior, Dermatology, Venereology and Dermatologic Surgery; Onkoderma, Private Clinic for Dermatologic Surgery, Dermatology and Surgery, Sofia 1407, Bulgaria; ³Krankenhaus Dresden-Friedrichstadt, Department of Dermatology and Venereology, Dresden, Sachsen, Germany; ⁴Universitario di Ruolo, Dipartimento di Scienze Dermatologiche, Università degli Studi di Firenze, Facoltà di Medicina e Chirurgia, Dermatology, Via Vittoria Colonna 11, Rome 00186, Italy

Abstract

Citation: Gianfaldoni S, Tchernev G, Wollina U, Lotti T. Incontinentia Pigmenti: A Case Report of a Complex Systemic Disease. Open Access Maced J Med Sci. <https://doi.org/10.3889/oamjms.2017.128>

Keywords: Incontinentia Pigmenti; genodermatosis; NEMO; cutaneous manifestations; systemic disease.

***Correspondence:** Serena Gianfaldoni. University G. Marconi of Rome, Dermatology and Venereology, Rome 00192, Italy. E-mail: serena.gianfaldoni@gmail.com

Received: 13-Apr-2017; Revised: 22-Apr-2017; Accepted: 23-Apr-2017; Online first: 23-Jul-2017

Copyright: © 2017 Serena Gianfaldoni, Georgi Tchernev, Uwe Wollina, Torello Lotti. This is an open-access article distributed under the terms of the Creative Commons Attribution-NonCommercial 4.0 International License (CC BY-NC 4.0).

Funding: This research did not receive any financial support.

Competing Interests: The authors have declared that no competing interests exist.

Incontinentia Pigmenti is an uncommon X-linked genodermatosis, caused by mutations in the NEMO gene. It is a systemic disease that involves tissue of ectodermic and mesodermic origin, including cutaneous tissue, teeth, eyes and the central nervous system, amongst other organs. The Authors report a rare case of Incontinentia Pigmenti in a female newborn.

Introduction

First described by Bloch in 1926, and Sulzberger in 1928, incontinentia pigmenti (IP) is a rare X-linked genodermatosis [1, 2], which name is related to the histological characteristics of the lesions in the third stage (or pigmentary stage) of the disease (Tab.1), consisting in the melanin incontinence by melanocytes of the basal epidermal layer and by its presence in the superficial dermis.

IP is a systemic disease which involves tissues of both ectodermic and mesodermic origin, including cutaneous tissue, teeth, eyes and the central nervous system, amongst other organs [3]. It is a hereditary, X-linked dominant disorder, with high penetrance and variable expressivity. It derives by mutations in the NEMO/IKK γ /IKBKG gene, located on Xq28. NEMO is the essential modulator of NF- κ B, a transcription factor involved in immune and inflammatory responses, and in protecting cells from

tumour necrosis factor-induced apoptosis. Disruption of the NEMO gene leads to diminish the NF- κ B activity and to increase the cells susceptibility to apoptosis [4, 5]. Also, inflammatory reactions and epidermal eosinophil recruitment, observed in the first stages of IP, seems to be important in the pathogenesis of the disease. It seems possible that the epidermal eosinophil accumulation is related to an eosinophil-selective chemokine (eotaxin), produced by specific leucocytes (e.g. eosinophils, macrophages, T-cells) and some structural cells (e.g. endothelial cells, fibroblasts and epithelial cells) [6].

In male patients, NEMO mutation is linked to their embryonic lethality. Female survival is due to the lyonization phenomenon (or X chromosome inactivation), which occur during early embryogenesis.

Although its epidemiological data are unknown, IP seems to occur in approximately 1 in 40.000 newborns [7]. About 50% of the IP cases have a positive family history of the same disease. The disease is predominant in women (F: M = 37:1). Less

than 3% of cases are described in males. Many of them have Klinefelter's syndrome (47, XXY karyotype), where the second X chromosome seems to play an important role in their survival from the natural intrauterine death. In the other male cases, different genetic mutations have also been described, such as hypomorphic alleles or somatic mosaicism for the common IKBKG deletion [8, 9].

Case report

A newborn female, 20 days old, affected by a diffuse vesiculo-bullous rash showed up to our Clinic (Fig. 1).

The baby was born at term by a spontaneous vaginal delivery, which was carried out after 3 hours by the membranes rupture.

The entire pregnancy had taken place regularly, without any complication.

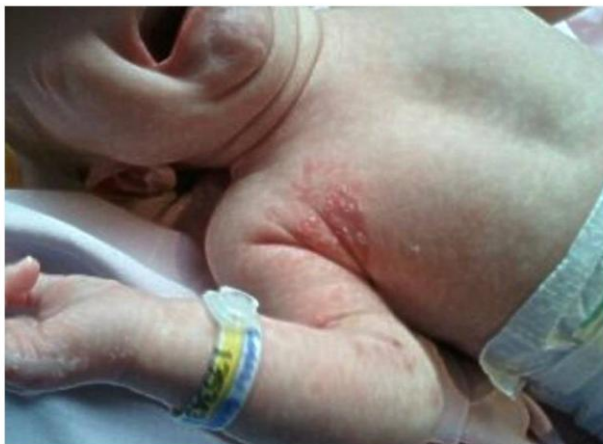

Figure 1: Blisters and bullae, on inflammatory ground, localised on the trunk, in a linear arrangement which follows the lines of Blaschko

The patient's mother was an otherwise healthy single woman of 31 years old. She did not have previous pregnancies or abortions. During her childhood, the woman had suffered from varicella, rubeola, parotitis and rubella.

The woman told us to be affected by epilepsy. Her medical treatment, also during the pregnancy, consisted of carbamazepine. No other diseases or drugs assumptions had been reported. Her familial history was insignificant.

At the mother's clinical evaluation we did not observe any form of cutaneous, nail or hair alterations. Maternal serology was negative for VDRL, HIV, HBV, HCV.

Unfortunately, no news about the newborn's father had been reported to us.

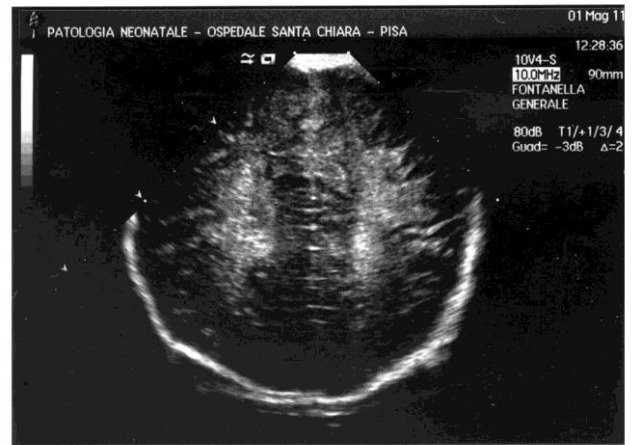


Figure 2: Cranial ultrasound shows an immature central nervous system, as demonstrated by the bilateral periventricular hyperechogenicity of the white substance

During the clinical evaluation, the young patient was 48 cm in height, and 2.6 kg of weight, which is less than normal. She had normal blood pressure, pulse rate and breathing. The musculoskeletal system was normal, except for an hypoplastic mandible. She did not have ocular or abdominal alterations.

From birth, the newborn suffered from seizures. The EEG showed a severely abnormal pattern with frequent multi-focal spikes; the head ultrasound showed a pattern of immature neurological development (Fig. 2). Even if, in a first moment, the neurologist thought how seizures could be the result of the carbamazepine abstinence, seizures never stopped as they were a primary disease. During the dermatologic examination, we observed clear, tense blister and bullae, on inflammatory base. Lesions were localised on the extremities and the trunk, in a linear arrangement which followed the lines of Blaschko, and seemed to be asymptomatic. The Nikolsky test was negative. No other lesions were observed in the other cutaneous or mucosal areas.

Hairs were less than normal, wiry and coarse. Nails were dystrophic.

Routine blood testing for inflammation, infections and autoimmune diseases were negative, except for a peripheral eosinophilia (> 20%). C-reactive protein and procalcitonin were normal. A punch biopsy performed on a lesion showed, in the epidermis, a mild acanthosis, foci of eosinophilic spongiosis and occasional dyskeratotic keratinocytes. In the same time, the dermis showed an infiltrate of lymphocytes, eosinophils and nuclear dust derived from eosinophilic karyorrhexis (Fig. 3).

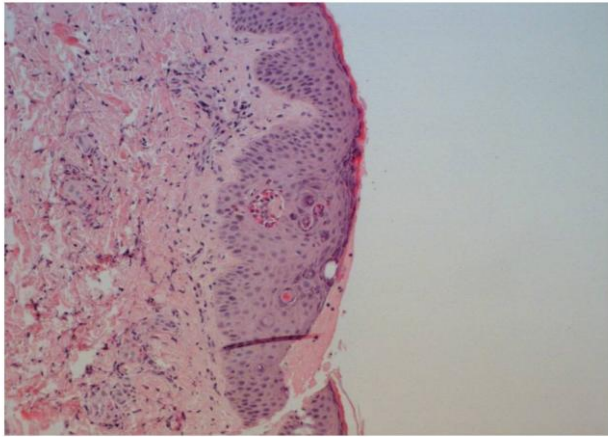


Figure 3: Histology: The epidermis shows mild acanthosis, foci of eosinophilic spongiosis and occasional dyskeratotic keratinocytes. The dermis is characterised by an infiltrate of lymphocytes, many eosinophils and nuclear dust derived from eosinophilic karyorrhexis

On the basis of the patient's clinical pattern and of the histological examination, we made the diagnosis of IP.

Because of the spontaneous improvement and resolution of skin lesions, we prescribed only an antibiotic therapy to avoid secondary infections of the lesions.

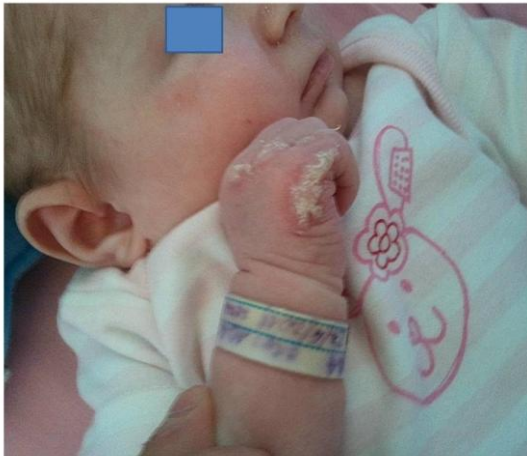

Figure 4: Warty lesions on the right hand

Two weeks later, during a follow-up, the dermatologic manifestations had been changed, as the classic evolution of IP. Linear warty lesions appeared on the side of the previous vesicular-bullous rash.

Discussion

The clinical presentation of IP varies considerably, even among the family members of the same patient [10]. They range from subtle cutaneous and dental involvement to a complex syndrome,

sometimes deadly.

Although IP may affect many organs, the cutaneous manifestations are the most commonly described (1). Typically the cutaneous lesions occur along the Blaschko's lines and evolve through four stages (Table 1) [11-13].

The first one (bullous stage) is described in 90% of patients at birth or within the first two weeks of life. Sometimes, it may occur in utero and doesn't progress after birth. Clinically, it is characterised by clear, tense bullae on inflammatory bases. Lesions are mainly described on the extremities (linear pattern) and the trunk (linear or circumferential pattern). Even if the face is usually spared, scalp lesions are quite common. The rash disappears by the age of 18 months. Recurrences can seldom be observed, also several years after the neonatal period, but they are usually shorter and less severe than the original eruption. The second stage (verrucous one) is characterised by a hypertrophic, wart-like rash, with the same localisation of initial lesions. Usually, stage 2 starts between the second and sixth weeks of life and persists for a few months. The third stage (hyperpigmentation stage) is the most characteristic one. It usually begins at the age six-twelve months and persists into the adulthood. Clinically, it is characterised by brownish linear and whorled streaks which follow the Blaschko's lines. The pigmentation ranges in colour from blue-grey or slate to brown. The bizarre splashed or Chinese figure distribution is diagnostic. Linear or macular telangiectasia may also be described. The last stage (fourth stage or atretic one) is described only in 14 % patients. Clinically, it is characterised by hypopigmentary and atrophic lesions, in the same areas of the previous hyperpigmentation.

Table 1: Stages of incontinentia pigmenti

| STAGE | CLINICAL CHARACTERISTICS | HISTOLOGIC FEATURES |
|-----------------------------------|---|---|
| STAGE 1 - BULLOUS STAGE | Clear, tense bullae and vesicles on inflammatory bases. | Eosinophilic spongiosis, intraepidermal vesicles. Inflammation of the dermis, with a cellular, infiltrate, including numerous eosinophils. |
| STAGE 2 - VERRUCOUS STAGE | Hypertrophic, wart-like rash. | Dyskeratotic keratinocytes, hyperkeratosis, acanthosis and papillomatosis. Macrophages laden with melanin may be present in the upper dermis. Possible signs of epidermal and dermal inflammation (epidermal spongiosis, cellular infiltrate including numerous eosinophils). |
| STAGE 3 - HYPERPIGMENTATION STAGE | Brownish linear and whorled streaks. | Melanin incontinence by melanocytes in the basal epidermal layer and its presence in the superficial dermis. |
| STAGE 4 - ATRETIC STAGE | Hypopigmentary and atrophic lesions. | Epidermal atrophy and decreased, normal or small melanocytes. Skin appendages may be absent. |

In reality, the onset and duration of each stage vary among individuals, and not all individuals experience all four stages. Stage 1 and three are more commonly observed than stage 2 and 4. Some patients may show additional cutaneous manifestations such as palmoplantar hyperhidrosis, port wine stain, abnormalities of mammary tissue, hair

(e.g. alopecia, woolly hair) and nails alterations (e.g. onycho-dystrophy, onychogryphosis, pitting, yellow discoloration, subungual and periungual keratotic tumours) [14,15]. Extracutaneous manifestations may also be described.

Among these, the dental abnormalities (e.g. delayed dentition, partial anodontia, hypodontia, abnormally shaped teeth) are the most commonly reported, occurring in more than 80% of all patients [16,17].

Ocular defects occur in about 40% of all the cases. They include strabismus, cataract, conjunctival pigmentosa uveitis, optic nerve atrophy, retinal vascular abnormalities, blue sclera, exudative chorioretinitis, retinal glioma [18].

About 25% of patients have neurological disorders, like seizures, spastic or paralytic quadriplegia, hemiparesis, cerebral atrophy, microcephaly and encephalopathy [19, 20]. The incidence of mental retardation is about 25-35%.

Other extracutaneous manifestations include abnormalities of the musculoskeletal system (e.g. hemivertebra, hemiatrophy, syndactyly, congenital dislocation of the hip, club foot, dwarfism, scoliosis, supernumerary ribs), and of the cardiovascular one (e.g. atrial septal defects, acyanotic tetralogy of Fallot, ventricular endomyocardial fibrosis, tricuspid insufficiency, primary pulmonary hypertension) [21].

Also, immunologic abnormalities are common in IP. They include functional abnormalities of neutrophils and lymphocytes and defects in polymorphonuclear chemotaxis. Eosinophilia up to 50% in the peripheral blood is common in the first inflammatory stage of IP.

Unfortunately, to date, no strict diagnostic criteria for IP exist. The diagnosis is mainly clinical, and it is based on recognition of the typical cutaneous lesions. The presence of dental, hair, nails and ocular alterations support the diagnosis. Peripheral eosinophilia is a suggestive sign in the earlier diagnosis. Eventually, a family history of X-linked inheritance or a history of multiple miscarriages may also support the hypothetic diagnosis.

The diagnosis may be confirmed only with the histological examination of a skin biopsy, and molecular genetic test (NEMO mutation).

In conclusion, because IP is a systemic disorder, a multidisciplinary approach to the patients is crucial. A complete neurologic examination is recommended for all IP infants.

Regular visits to a paediatric ophthalmologist are essential during the first year of life. Laser photocoagulation and vascular endothelial growth factor inhibitor seem to be good treatments for retinal vascular abnormalities [22].

Concerning teeth, a radiologic evaluation and dental intervention by the age of two years is an appropriate therapeutic approach.

The dermatological management in the newborn period is aimed at reducing the risk of infection of blisters using antibiotics and hygienic preventive measures. Spontaneous improvement and resolution of skin lesions is general the rule. Topical and systemic steroids may be prescribed to limit the rash of the first two stages [23]. The use of laser therapies to treat the hyperpigmented lesions of should be discouraged because it has been reported to trigger an extensive vesicular-bullous eruption [24].

References

1. Woon-Kyong Chung, Deok-Woo Lee, Sung-Eun Chang et Al. A Case of incontinentia pigmenti associated with multiorgan abnormalities. *Ann Dermatol.* 2009; 21: 56–59. <https://doi.org/10.5021/ad.2009.21.1.56> PMID:20548858 PMCID:PMC2883371
2. Babu NA, Rajesh E, Krupaa J, Gnananandar G. Genodermatoses. *J Pharm Bioallied Sci.* 2015;7(Suppl 1): S203–S206. PMID:26015711 PMCID:PMC4439671
3. Hadj-Rabia S, Froidevaux D, Bodak N, Hamel-Teillac D, Smahi A, Touil Y, et al. Clinical study of 40 cases of incontinentia pigmenti. *Arch Dermatol.* 2003;139:1163–1170. <https://doi.org/10.1001/archderm.139.9.1163> PMID:12975158
4. Berlin AL, Paller AS, Chan LS. Incontinentia pigmenti: a review and update on the molecular basis of pathophysiology. *J Am Acad Dermatol.* 2002;47:169–187. <https://doi.org/10.1067/mjd.2002.125949> PMID:12140463
5. Shastry BS. Recent progress in the genetics of incontinentia pigmenti (Bloch-Sulzberger syndrome). *J Hum Genet.* 2000;45:323-326. <https://doi.org/10.1007/s100380070001> PMID:11185738
6. Jean-Baptiste S, O'Toole EA, Chen M et Al. Expression of eotaxin, an eosinophil-selective chemokine, parallels eosinophil accumulation in the vesiculobullous stage of incontinentia pigmenti. *Clin Exp Immunol.* 2002;127:470-478. <https://doi.org/10.1046/j.1365-2249.2002.01755.x> PMID:11966763 PMCID:PMC1906303
7. Buinauskiene J, Buinauskaite E, Valiukeviciene S. Incontinentia pigmenti (Bloch-Sulzberger syndrome) in neonates. *Medicina (Kaunas).* 2005;41:496–499.
8. Buinauskaite E, Buinauskiene J, Kucinskiene V, Strazdiene D, Valiukeviciene S. Incontinentia pigmenti in a male infant with Klinefelter syndrome: a case report and review of the literature. *Pediatr Dermatol.* 2010;27:492-495. <https://doi.org/10.1111/j.1525-1470.2010.01261.x> PMID:20807362
9. Song JY, Na CH, Chung BS, Choi KC, Shin BS. A case of a surviving male infant with incontinentia pigmenti. *Ann Dermatol.* 2008;20:134-137. <https://doi.org/10.5021/ad.2008.20.3.134> PMID:27303177 PMCID:PMC4903964
10. Kutkowska-Kaźmierczak A, Obersztyń E, Bonnefont JP, Rosińska-Borkowska D, Mazurczak T, Sobczyńska-Tomaszewska A, Mazurczak T. Variable clinical expression of familial incontinentia pigmenti syndrome - presentation of three cases. *Med Wieku Rozwoj.* 2008;12:748-753. PMID:19305025
11. Ehrenreich M, Tarlow MM, Godlewska-Janusz E, Schwartz RA. Incontinentia pigmenti (Bloch-Sulzberger syndrome): a systemic disorder. *Cutis.* 2007;79:355-362. PMID:17569396

12. Chung WK, Lee DW, Chang SE, Lee MW, Choi JH, Moon KC. A case of incontinentia pigmenti associated with multiorgan abnormalities. *Ann Dermatol*. 2009;21: 56–59. <https://doi.org/10.5021/ad.2009.21.1.56> PMID:20548858 PMCID:PMC2883371
13. Poziomczyk CS, Recuero JK, Bringham L, Maria FD, Campos CW, Travi GM, Freitas AM, Maahs MA, Zen PR, Fiegenbaum M, Almeida ST, Bonamigo RR, Bau AE. Incontinentia pigmenti. *An Bras Dermatol*. 2014;89:26-36. <https://doi.org/10.1590/abd1806-4841.20142584> PMID:24626645 PMCID:PMC3938351
14. Chun SR, Rashid RM. Delayed onychodystrophy of incontinentia pigmenti: an evidence- based review of epidemiology, diagnosis and management. *J Drugs Dermatol*. 2010;9:350-354. PMID:20514792
15. Chan YC, Happle R, Giam YC. Whorled scarring alopecia: a rare phenomenon in incontinentia pigmenti? *J Am Acad Dermatol*. 2003;49:929-931. [https://doi.org/10.1016/S0190-9622\(03\)00474-2](https://doi.org/10.1016/S0190-9622(03)00474-2)
16. Santa-Maria FD, Mariath LM, Poziomczyk CS, Maahs MA, Rosa RF, Zen PR, Schüller- Faccini L, Kiszewski AE. Dental anomalies in 14 patients with IP: clinical and radiological analysis and review. *Clin Oral Investig*. 2016 [Epub ahead]. PMID:27766487
17. Minić S, Trpinac D, Gabriel H, Gencik M, Obradović M. Dental and oral anomalies in incontinentia pigmenti: a systematic review. *Clin Oral Investig*. 2013;17:1-8. <https://doi.org/10.1007/s00784-012-0721-5> PMID:22453515
18. Minić S, Obradović M, Kovacević I, Trpinac D. Ocular anomalies in incontinentia pigmenti: literature review and meta-analysis. *Srp Arh Celok Lek*. 2010;138:408-413. <https://doi.org/10.2298/SARH1008408M> PMID:20842883
19. Minić S, Trpinac D, Obradović M. Systematic review of central nervous system anomalies in incontinentia pigmenti. *Orphanet J Rare Dis*. 2013;8:25. <https://doi.org/10.1186/1750-1172-8-25> PMID:23406512 PMCID:PMC3576363
20. Pörksen G, Pfeiffer C, Hahn G, Poppe M, Friebe D, Kreuz F, Gahr M. Neonatal seizures in two sisters with incontinentia pigmenti. *Neuropediatrics*. 2004;35:139-142. <https://doi.org/10.1055/s-2004-815837> PMID:15127315
21. Godambe S, McNamara P, Rajguru M, Hellmann J. Unusual neonatal presentation of incontinentia pigmenti with persistent pulmonary hypertension of the newborn: a case report. *J Perinatol*. 2005;25:289-292. <https://doi.org/10.1038/sj.jp.7211250> PMID:15789024
22. Moreira Neto CA, Moreira AT, Moreira Jr CA. Ophthalmic evaluation, treatment, and follow-up of two cases of incontinentia pigmenti. *Arq Bras Oftalmol*. 2014;77:47-49. <https://doi.org/10.5935/0004-2749.20140012> PMID:25076373
23. Tomotaki S, Shibasaki J, Yunoki Y, Kishigami M, Imagawa T, Aida N, Toyoshima K, Itani Y. Effectiveness of corticosteroid therapy for acute neurological symptoms in incontinentia pigmenti. *Pediatr Neurol*. 2016;56:55-58. <https://doi.org/10.1016/j.pediatrneurol.2015.12.002> PMID:26777982
24. Nagase T, Takanashi M, Takada H, Ohmori K. Extensive vesiculobullous eruption following limited ruby laser treatment for incontinentia pigmenti: a case report. *Australas J Dermatol*. 1997;38:155-157. <https://doi.org/10.1111/j.1440-0960.1997.tb01135.x> PMID:9293665