

## Verrucous-Keratotic Malignant Melanoma (VKMM)

Nikolay Damianov<sup>1</sup>, Michael Tronnier<sup>2</sup>, Nely Koleva<sup>3</sup>, Uwe Wollina<sup>4</sup>, Serena Gianfaldoni<sup>5</sup>, Torello Lotti<sup>6</sup>, Jacopo Lotti<sup>7</sup>, Katlein França<sup>8</sup>, Atanas Batashki<sup>9</sup>, Hristo Mangarov<sup>10</sup>, Georgi Tchernev<sup>11\*</sup>

<sup>1</sup>Medical Institute of Ministry of Interior, (MVR-Sofia), Department of General, Vascular and Abdominal Surgery, General Skobelev 79, 1606 Sofia, Bulgaria; <sup>2</sup>Department of Dermatology, Venereology and Allergology, Helios Klinikum GMBH Hildesheim Senator-Braun-Allee 33 – 31135 Hildesheim, Germany; <sup>3</sup>Department of Pathology, Medical Institute of Ministry of Interior (MVR), Department of Dermatology and Dermatologic Surgery, General Skobelev 79, 1606 Sofia, Bulgaria; <sup>4</sup>Department of Dermatology and Allergology, Academic Teaching Hospital Dresden-Friedrichstadt, Friedrichstrasse 41, 01067, Dresden, Germany; <sup>5</sup>University G. Marconi of Rome, Rome, Italy; <sup>6</sup>University of Rome "G. Marconi", Rome, Italy; <sup>7</sup>Department of Nuclear, Subnuclear and Radiation Physics, University of Rome "G. Marconi", Rome, Italy; <sup>8</sup>Institute for Bioethics & Health Policy; Department of Dermatology & Cutaneous Surgery; Department of Psychiatry & Behavioral Sciences, University of Miami Miller School of Medicine - Miami, FL, USA; <sup>9</sup>Abdominal and Thoracic Surgery, Department of Special Surgery, Medical University of Plovdiv, bul. "Peshtersko shose" Nr 66, 4000 Plovdiv, Bulgaria; <sup>10</sup>Medical Institute of Ministry of Interior (MVR), Department of Dermatology and Dermatologic Surgery, General Skobelev 79, 1606 Sofia, Bulgaria; <sup>11</sup>Medical Institute of Ministry of Interior (MVR), Department of Dermatology and Dermatologic Surgery, General Skobelev 79, 1606 Sofia, Bulgaria; Onkoderma"- Policlinic for Dermatology, Venereology and Dermatologic Surgery, 26 General Skobelev blvd., Sofia, Bulgaria

### Abstract

**Citation:** Damianov N, Tronnier M, Koleva N, Wollina U, Gianfaldoni U, Lotti T, Lotti J, França K, Batashki A, Mangarov H, Tchernev G. Verrucous-Keratotic Malignant Melanoma (VKMM). Open Access Maced J Med Sci. 2017 Jul 25; 5(4):547-548. <https://doi.org/10.3889/oamjms.2017.142>

**Keywords:** keratotic melanoma; verrucous melanoma; surgical approach; surgical safety; benign like lesions.

**\*Correspondence:** Professor Dr Georgi Tchernev PhD, Chief of 1) Department of Dermatology, Venereology and Dermatologic Surgery, Medical Institute of Ministry of Interior (MVR), General Skobelev 79, 1606 Sofia; 2) Onkoderma- Policlinic for Dermatology and Dermatologic Surgery, General Skobelev 26, Sofia, Bulgaria. GSM: 00359885588424. E-mail: georgi\_tchernev@yahoo.de

Received: 02-Apr-2017; Revised: 20-Apr-2017; Accepted: 24-Apr-2017; Online first: 24-Jul-2017

**Copyright:** © 2017 Nikolay Damianov, Michael Tronnier, Nely Koleva, Uwe Wollina, Serena Gianfaldoni, Torello Lotti, Jacopo Lotti, Katlein França, Atanas Batashki, Hristo Mangarov, Georgi Tchernev. This is an open-access article distributed under the terms of the Creative Commons Attribution-NonCommercial 4.0 International License (CC BY-NC 4.0).

**Funding:** This research did not receive any financial support.

**Competing Interests:** The authors have declared that no competing interests exist.

We report a patient with a verrucous keratotic variant of melanoma visiting the policlinic of Medical Institute of Ministry of Interior (MVR-Sofia), Department of Dermatology and Dermatologic surgery, with a keratotic verrucous lesion, located on the right thigh, partially deeply pigmented at upper right quadrant. The lesion had appeared three years ago before her presentation in the policlinic, and it had gradually enlarged and become darker in the last twelve months. The surface of the lesion was covered with thick hyperkeratotic lobules. The histologic evaluation revealed verrucous melanoma with a tumour thickness of 3 mm and Clark Level IV and focal ulceration. The tumour was staged as stage IIB (T3bN0M0). Sentinel lymph node biopsy was planned. Verrucous-keratotic forms of malignant melanoma occur more commonly in women and favour the extremities, but may be found on any anatomic site. Seventy-one percent of this melanoma type are situated on the upper and lower extremities. Although two-thirds of these neoplasms can be histologically graded according to the classification of Clark, one-third of these melanomas with marked verrucous hyperplasia and hyperkeratosis of the epidermis do not fit into his classification. Histological classification of patients with a verrucous keratotic type of melanoma may sometimes be extremely difficult. The marked papilliferous architecture of these lesions made an assessment of Breslow depth difficult. The presented case highlights the clinical existence and features of such benign-looking melanomas. It is therefore important for surgical pathologists to recognise this unusual variant of malignant melanoma, as it may be confused both clinically and pathologically with benign lesions.

The verrucous keratotic melanoma seems to be a rare variant of the cutaneous melanoma that can be often misdiagnosed with a benign lesion [1]. We report a patient with a verrucous keratotic variant of melanoma visiting the policlinic of Medical Institute of Ministry of Interior (MVR-Sofia), Department of Dermatology and Dermatologic surgery, with a keratotic verrucous lesion, located on the right thigh, partially deeply pigmented at upper right quadrant (Fig. 1a, 1b). The lesion had appeared three years ago before her presentation in the policlinic, and it had gradually enlarged and become darker in the last

twelve months (Fig. 1a, 1b). Physical examination revealed an oval shaped, partially black plaque, slightly elevated, 5.2 x 3.6 cm in size (Fig. 1a, 1b). The surface of the lesion was covered with thick hyperkeratotic lobules. The histologic evaluation (after the surgical removal with 2 cm surgical safety in all directions) revealed Verrucous melanoma with a tumour thickness of 3 mm and Clark Level IV and focal ulceration (Fig. 1c-1f). The tumour was staged as stage IIB (T3bN0M0). Sentinel lymph node biopsy was planned.

Verrucous malignant melanoma (VMM) is a rare variant of melanoma firstly described in 1967 [2]. Both clinically and histologically, it mimics SK [3, 4]. Some intradermal and compound nevi have been described as showing hyperkeratosis, papillomatosis, horn cysts, and lace-like downward growth of epidermal strands [5]. Though specific causative factors linking SK-like epidermal changes are still unknown, it is possible that both nevi and melanomas can release some epidermal cell growth factors, thereby inducing changes in the overlying epidermis [5].

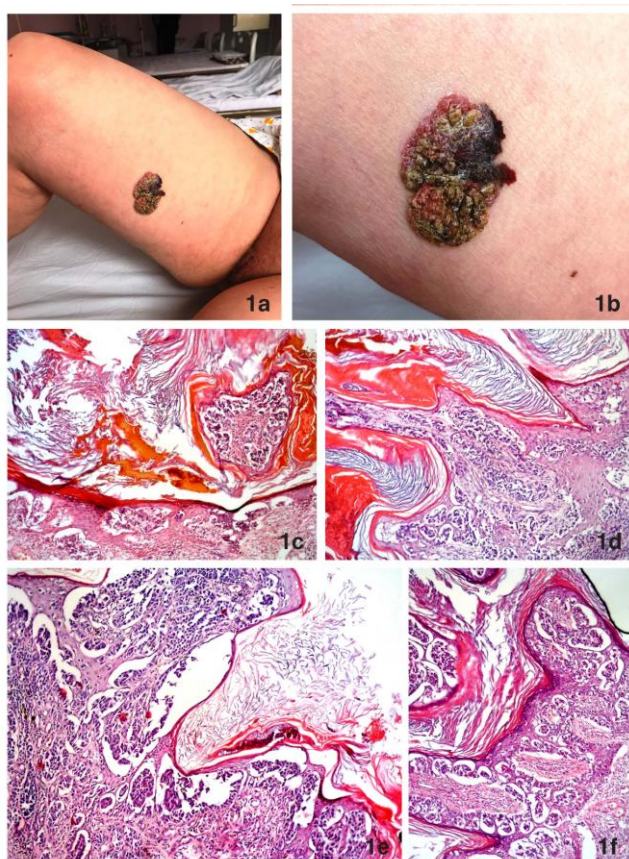


Figure 1: a), b) Large pigmented tumour on the medial aspect of the right thigh. b) Irregularly configured tumour with verruciform surface and a deeply pigmented macular component in the upper medial part; c), d) e), f) Various aspects of the tumour. Verruciform acanthosis of the epidermis with hyperkeratosis – namely orthohyperkeratosis and columns of parakeratosis. Atypical melanocytes mainly arranged in nests along the dermo-epidermal junction with marked confluence. Consumption of the epidermis in some parts. Some atypical melanocytes also located above the junction. Within the dermis nests and sheets of atypical melanocytes without maturation

Verrucous-keratotic forms of malignant melanoma occur more commonly in women and favour the extremities, but may be found on any anatomic site [3]. Seventy-one percent of this melanoma type are situated on the upper and lower extremities [3]. Although two-thirds of these neoplasms can be histologically graded according to the classification of Clark, one-third of these melanomas with marked verrucous hyperplasia and hyperkeratosis of the epidermis do not fit into his classification [3]. Histological classification of patients with a verrucous keratotic type of melanoma may sometimes be extremely difficult [3]. The marked papilliferous architecture of these lesions made an assessment of Breslow depth difficult [6]. The presented case highlights the clinical existence and features of such benign-looking melanomas. It is therefore important for surgical pathologists to recognise this unusual variant of malignant melanoma, as it may be confused both clinically and pathologically with benign lesions [3, 6].

## References

1. Matsumoto T, Yokota K, Sawada M, Hasegawa Y, Takeuchi A, Kono M, Akiyama M. Large epidermal cleft formation in verrucous-keratotic malignant melanoma of the heel. *J Am Acad Dermatol*. 2015;72(1):e37-8. <https://doi.org/10.1016/j.jaad.2014.09.044> PMID:25497951
2. Clark WH Jr. A classification of malignant melanoma in man correlated with histogenesis and biologic behaviour. In: Montagna W, ed. *Advances in Biology of the Skin, The Pigmentary System*, New York: Pergamon Press; 1967: p. 621-47.
3. Kuehnl-Petzoldt C, Berger H, Wiebelt H. Verrucous-keratotic variations of malignant melanoma: a clinicopathological study. *Am J Dermatopathol*. 1982;4(5):403-10. PMID:7149193
4. Suster S, Ronnen M, Bubis JJ. Verrucous pseudonevoid melanoma. *J Surg Oncol*. 1987;36:134-7. <https://doi.org/10.1002/jso.2930360213> PMID:3657177
5. Requena L, Sánchez M, Requena C. Simultaneous occurrence of junctional nevus and seborrheic keratosis. *Cutis*. 1989;44:465-6. PMID:2533059
6. Blessing K, Evans AT, al-Nafussi A. Verrucous naevoid and keratotic malignant melanoma: a clinico-pathological study of 20 cases. *Histopathology*. 1993;23(5):453-8. <https://doi.org/10.1111/j.1365-2559.1993.tb00494.x> PMID:8314219