

# The Necessity of Follow-Up Brain Computed-Tomography Scans: Is It the Pathology Itself Or Our Fear that We Should Overcome?

Ahmet Öğrenci<sup>1\*</sup>, Orkun Koban<sup>1</sup>, Murat Ekşi<sup>2</sup>, Onur Yaman<sup>3</sup>, Sedat Dalbayrak<sup>1</sup>

<sup>1</sup>Neurospinal Academy, Neurosurgery, Kurtköy mah, Ankara Cad. 390/3, Pendik, Istanbul 34955, Turkey; <sup>2</sup>Antalya Eğitim ve Araştırma Hastanesi, Neurosurgery, Antalya, Turkey; <sup>3</sup>Koc Üniversitesi Tıp Fakültesi, Neurosurgery, Istanbul, Turkey

## Abstract

**Citation:** Öğrenci A, Koban O, Ekşi M, Yaman O, Dalbayrak S. The Necessity of Follow-Up Brain Computed-Tomography Scans: Is It the Pathology Itself Or Our Fear that We Should Overcome? Open Access Maced J Med Sci. <https://doi.org/10.3889/oamjms.2017.157>

**Keywords:** epidural haematoma; follow-up tomography; CT scans; pediatric head trauma; fracture.

**\*Correspondence:** Ahmet Öğrenci, Neurospinal Academy, Neurosurgery, Kurtköy mah, Ankara Cad. 390/3, Pendik, Istanbul 34955, Turkey. E-mail: [drahmetogrenci@gmail.com](mailto:drahmetogrenci@gmail.com)

**Received:** 20-Jun-2017; **Revised:** 28-Jun-2017; **Accepted:** 30-Jun-2017; **Online first:** 05-Oct-2017

**Copyright:** © 2017 Ahmet Öğrenci, Orkun Koban, Murat Ekşi, Onur Yaman, Sedat Dalbayrak. This is an open-access article distributed under the terms of the Creative Commons Attribution-NonCommercial 4.0 International License (CC BY-NC 4.0).

**Funding:** This research did not receive any financial support.

**Competing Interests:** The authors have declared that no competing interests exist.

**AIM:** This study aimed to make a retrospective analysis of pediatric patients with head traumas that were admitted to one hospital setting and to make an analysis of the patients for whom follow-up CT scans were obtained.

**METHODS:** Pediatric head trauma cases were retrospectively retrieved from the hospital's electronic database. Patients' charts, CT scans and surgical notes were evaluated by one of the authors. Repeat CT scans for operated patients were excluded from the total number of repeat CT scans.

**RESULTS:** One thousand one hundred and thirty-eight pediatric patients were admitted to the clinic due to head traumas. Brain CT scan was requested in 863 patients (76%) in the cohort. Follow-up brain CT scans were obtained in 102 patients. Additional abnormal finding requiring surgical intervention was observed in only one patient (isolated 4th ventricle hematoma) on the control CTs (1% of repeat CT scans), who developed obstructive hydrocephalus. None of the patients with no more than 1 cm epidural hematoma in its widest dimension and repeat CT scans obtained 1.5 hours after the trauma necessitated surgery.

**CONCLUSION:** Follow-up CT scans changed clinical approach in only one patient in the present series. When ordering CT scan in the follow-up of pediatric traumas, benefits and harms should be weighted based upon time interval from trauma onset to initial CT scan and underlying pathology.

## Introduction

Patient admissions due to pediatric head traumas are 300.000 children/year, 350.000 children/year, and more than 400.000 children/year in Italy, UK and USA respectively [1-3]. Traumatic brain injury (TBI) is a leading cause of death and important morbidity cause in the pediatric population [1]. Early diagnosis of cranial and intracranial pathologies is vital to intervene them in a timely fashion; in which computed tomography (CT) scan is the most valuable diagnostic tool [1, 4-7].

However, follow-up CT scan protocols have not been well established opposite to it is in the initial screening of TBI [8-11].

This study aimed to make a retrospective analysis of pediatric patients with head traumas that

were admitted to one hospital setting and to analyse the patients for whom follow-up CT scans were obtained.

## Materials and Methods

Pediatric head trauma cases were retrospectively retrieved from the hospital's electronic database. The study was carried out in a single state hospital providing health care to a large region in the area where it was located. The study was conducted as a result of scanning frequent CT in follow-up period in the emergency clinic in pediatric patients with head trauma. The timeframe for the study was from November 2014 to May 2016.

Patients' charts, brain CT scans and surgical notes were evaluated by one of the authors. Repeat CT scans for operated patients were excluded from the total number of repeat CT scans. The study was conducted according to the principles of 1964 Declaration of Helsinki and all its amendments. Continuous variables were mentioned as means and ranges; whereas dichotomous variables were defined as percentages using chi-square test. An alpha value of 0.05 was accepted as the threshold for significance.

## Results

One thousand, one hundred and thirty-eight pediatric patients were admitted to the emergency clinic due to head traumas caused by traffic accidents, falls, and child abuse. There were 532 female (47%) and 606 male (53%) patients ( $p = 0.002$ ). Average age at admission was 6.8 years (range = 2 weeks-17 years). Meantime from trauma scene to hospital admission was 70 minutes (range = 5 minutes-3.5 days). Time of CT imaging was in the range of 25 minutes and 3.5 days (mean = 100 minutes).

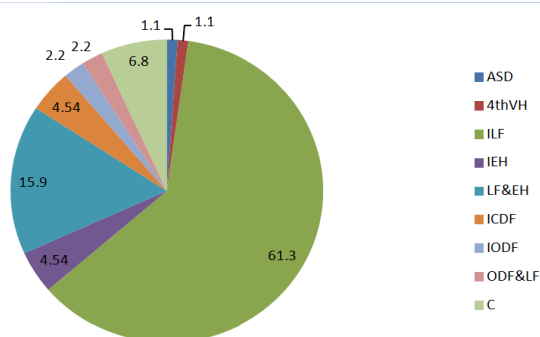


Figure 1: Pathological findings on initial CT scans. (Pathological findings were present in initial CT in 88 patients). Abbreviations: ASD: Acute subdural hematoma, 4thVH: 4th ventricle hematoma, ILF: Isolated linear skull fracture, LF & EH: Linear skull fracture with epidural hematoma, ICDF: Isolated closed depressed skull fracture, C: Contusion, IEH: Isolated epidural hematoma, IODF: Isolated open depressed skull fracture, LF & ODF: Linear skull fracture with open depressed skull fracture

Out of 1138 patients, 160 (14%) had multiple traumas. While brain CT was obtained in all of the patients with multiple traumas; it was obtained in 703 patients (72%) of the remaining patients with isolated brain trauma. The patients, in whom CT was not obtained, had minor head traumas with superficial lacerations or were newborns with high GCS scores (275 patients-24%). Initial brain CT was requested in 863 patients (75.8%-383 female and 480 male) in the cohort.

Main signs and symptoms of the patients, in whom brain CTs obtained, were scalp swellings and/or ecchymoses (430), headache (282), nausea

and vomiting (386), scalp laceration (214), depressed sensorium (342), (numbers in the parentheses do not depict exact patient numbers, some of the patients were counted more than once if they had more signs and symptoms).

There was one case of isolated 4th ventricle hematoma, one case of acute subdural hematoma (previously reported [12], 54 cases of isolated linear fracture, 4 cases with isolated epidural hematoma, 14 cases with linear fracture concomitant with epidural hematoma, 4 cases of isolated closed depressed skull fracture, 2 cases of isolated open depressed skull fracture, 2 cases of linear fracture with open depressed skull fracture, and 6 cases of contusion in different brain locations.

Table 1: Follow-up CT scans obtained in the series

	N	%
Isolated linear skull fracture	54	52.94
No prior finding	20	19.61
Epidural hematoma	16**	15.68
Isolated closed depressed skull fracture	4	3.92
Contusion	6	5.88
Isolated 4th ventricle hematoma*	1	0.98
Acute subdural hematoma	1	0.98
Total	102	100

Abbreviations: N: number of patients, \*: follow-up CT scan changed clinical approach, \*\*: 12 patients had a concomitant linear skull fracture.

All of the patients with isolated open depressed skull fracture with or without linear fracture were operated. Two of the patients harbouring temporal bone linear fracture concomitant with epidural hematoma had depressed sensorium at the time of admission. Both of them had multiple traumas. The patients could have their first brain CT scan at 1 and 1.5 hours after the first insult of trauma. The dimensions of the epidural hematomas at their largest with were 2 and 2.5 cm, respectively. Both of the patients were operated. Of the remaining 16 patients having an epidural hematoma, the linear fracture was present in 12 of them (75%). The largest width of the hematomas was 1 cm or lesser. None of them required surgical intervention. None of the patients with isolated linear fracture, acute subdural hematoma, and contusions needed further intervention during in-hospital follow-ups.

Follow-up brain CT scans were obtained in 102 patients (11.8% of the patients who had prior imaging) (Table 1): 54 patients with isolated linear skull fracture, 1 patient with isolated 4th ventricle hematoma, 1 patient with acute subdural hematoma, 16 patients with epidural hematoma, 4 patients with isolated closed depressed skull fracture, 6 patients with contusions in different brain locations, and 20 patients with no abnormal finding on prior CT, yet had ongoing symptoms such as vomiting, sleepiness, confusion. Abnormal finding necessitating surgical intervention was observed in only one patient (isolated 4th ventricle hematoma) on the control CT (1% of 2nd CT scans), who developed obstructive hydrocephalus.

There is no mortality in the present series. One of the patients with contusion had right hemiparesis at the time of admission. The hemiparesis persisted after the conservative therapy. Remaining patients recovered fully from their initial neurological findings.

## Discussion

Fall is the most common mechanism of brain injury, and road accident is the second one in the pediatric age group [9]. When the causes are categorised according to age subgroups: falls are common in infants, whereas road accidents are more common in older children, respectively [1]. Male predominance in pediatric age head traumas was reported in multiple series as same as the present study (males-53%,  $p = 0.002$ ) [1, 9, 13-16]. This finding could be explained by the risk-taking behaviour of boys [1].

There is consensus over CT use in the initial evaluation of the pediatric patients with moderate to severe head traumas, whereas the debate is still going for minor TBI category even though many studies have already been conducted [1, 17-19]. There is the scarce amount of studies to evaluate the necessity of repeat CT scan in TBI. There is a risk of exposure to high ionising radiation (median dose = 20 mGy, in some cases it may pass over 40 mGy) during brain CT scans [8-11, 20, 21].

Malignancies in the pediatric age group are seen in between 1/1000 and 1/5000 brain CT scans; hence this risk increases as the age of the patients decreases. It has been shown that thyroid malignancy is seen in 4-65/1.000.000 CT scans in children [22, 23]. Not only the radiation itself but also the need for sedation in uncooperative and lethargic pediatric patients yields additional risks [9]. Contrarily, there is a debate on if some deteriorating cases might be missed by denying repeat CT scan [24-26].

Some physical findings have been proposed as predictors of pathological CT findings: abnormal mental status, headache, vomiting, scalp swelling (hematoma), signs of skull fracture or contused lacerated injury [1, 13, 17-19, 27]. There is a disagreement over the role of loss of consciousness; some authors imply that loss of consciousness for a short-term (less than 5 minutes) is not significant since it is due to vagal response to pain, yet others insist on its importance as a predictor variable even it is short-lived (less than 1 minute) [1, 3].

What the rate of follow-up CT scans in our study was 11.8%, which is far behind the rates of similar studies (24-65%) [9, 24]. Repeat CT scan resulted in late surgical intervention in only one patient

(1%), which is comparable to other similar studies (1-24%) [8, 9, 11, 25, 26, 28]. Kim et al., found only the epidural hematoma other than another kind of intracranial pathologies being a predictor of late surgical intervention. Epidural hematoma of 10 mm or more was predictive of increment of the hematoma dimensions in follow-up CTs hence resulted in the surgical intervention [9]. No necessity for surgery developed in patients with epidural hematoma with a width of 1 cm or less, or in the same patients in whom initial CT scan could be obtained more than 1.5 hours after the trauma.

Limitations of the present study are its retrospective nature and the inclusion of patients admitted within a limited time frame, however many of the present studies are retrospective, and cohort number in this study is comparable to the number of similar studies from the literature [9, 24, 26]. To make more clear-cut conclusions, prospective multi-centre studies with large-cohorts should be designed.

In conclusion, follow-up CT scans changed clinical approach in only one patient in the present series. Ionizing radiation dose from CT scans is high for pediatric patients. When ordering CT scan in the follow-up of pediatric head traumas, benefits and harms should be weighted based upon time interval from trauma onset to initial CT scan and type of the underlying pathology.

## References

1. Fundaro C, Caldarelli M, Monaco S, et al. Brain CT scan for pediatric minor accidental head injury. An Italian experience and review of the literature. *Childs Nerv Syst.* 2012;28: 1063-68. <https://doi.org/10.1007/s00381-012-1717-9> PMID:22349902
2. Bishop NB. Traumatic brain injury: a primer for primary care physicians. *Curr Probl Pediatr Adolesc Health Care.* 2006;36: 318-331. <https://doi.org/10.1016/j.cppeds.2006.05.004> PMID:16996420
3. Da Dalt L, Marchi AG, Laudizi L, et al. Predictors of intracranial injuries in children after blunt head trauma. *Eur J Pediatr.* 2006;165: 142-148. <https://doi.org/10.1007/s00431-005-0019-6> PMID:16311740
4. Adelson PD, Bratton SL, Carney NA, et al. & American Association for Surgery of T, Child Neurology S, International Society for Pediatric N, International Trauma A, Critical Care S, Society of Critical Care M, World Federation of Pediatric I, Critical Care S. Guidelines for the acute medical management of severe traumatic brain injury in infants, children, and adolescents. Chapter
5. Indications for intracranial pressure monitoring in pediatric patients with severe traumatic brain injury. *Pediatr Crit Care Med.* 2003;4:19-24. <https://doi.org/10.1097/00130478-200307001-00006>
5. Shackford SR, Wald SL, Ross SE, et al. The clinical utility of computed tomographic scanning and neurologic examination in the management of patients with minor head injuries. *J Trauma.* 1992;33:385-394. <https://doi.org/10.1097/00005373-199209000-00009> PMID:1404507
6. Stein SC, Fabbri A, Servadei F. Routine serial computed tomographic scans in mild traumatic brain injury: when are they cost-effective? *J Trauma.* 2008;65:66-72. <https://doi.org/10.1097/TA.0b013e318068d75f> PMID:18580532
7. Vos PE, Battistin L, Birbamer G, et al. & European Federation of Neurological S. EFNS guideline on mild traumatic brain injury:

- report of an EFNS task force. *Eur J Neurol.* 2002;9:207-19. <https://doi.org/10.1046/j.1468-1331.2002.00407.x> PMID:11985628
8. Aziz H, Rhee P, Pandit V, et al. Mild and moderate pediatric traumatic brain injury: replace routine repeat head computed tomography with neurologic examination. *J Trauma Acute Care Surg.* 2013;75: 550-54. <https://doi.org/10.1097/TA.0b013e3182a53a77> PMID:24064865
9. Kim WH, Lim DJ, Kim SH, et al. Is Routine Repeated Head CT Necessary for All Pediatric Traumatic Brain Injury? *J Korean Neurosurg Soc.* 2015;58:125-30. <https://doi.org/10.3340/jkns.2015.58.2.125> PMID:26361528 PMCid:PMC4564744
10. Bata SC, Yung M. Role of routine repeat head imaging in paediatric traumatic brain injury. *ANZ J Surg.* 2014;84:438-441. <https://doi.org/10.1111/ans.12582> PMID:24697988
11. Durham SR, Liu KC, Selden NR. Utility of serial computed tomography imaging in pediatric patients with head trauma. *J Neurosurg.* 2006;105:365-69. <https://doi.org/10.3171/ped.2006.105.5.365>
12. Ogrenci A, Eksi MS, Koban O, Karakus M. Spontaneous rapid resolution of acute subdural hematoma in children. *Childs Nerv Syst.* 2015;31(12): 2239-43. <https://doi.org/10.1007/s00381-015-2910-4> PMID:26391785
13. Guzel A, Hicdonmez T, Temizoz O, et al. Indications for brain computed tomography and hospital admission in pediatric patients with minor head injury: how much can we rely upon clinical findings? *Pediatr Neurosurg.* 2009;45:262-70. <https://doi.org/10.1159/000228984> PMID:19609094
14. Berry JG, Jamieson LM, Harrison JE. Head and traumatic brain injuries among Australian children, July 2000-June 2006. *Inj Prev.* 2010;16:198-202. <https://doi.org/10.1136/ip.2009.022442> PMID:20423900
15. D'Ippolito A, Collins CL, Comstock RD. Epidemiology of pediatric holiday-related injuries presenting to US emergency departments. *Pediatrics.* 2010;125:931-37. <https://doi.org/10.1542/peds.2009-0307> PMID:20368316
16. Love PF, Tepas JJ, Wludyka PS, Masnita-Iusan C. Fall-related pediatric brain injuries: the role of race, age, and sex. *J Trauma.* 2009;67:12-15. <https://doi.org/10.1097/TA.0b013e3181ac7f22> PMID:19590346
17. Palchak MJ, Holmes JF, Vance CW, et al. A decision rule for identifying children at low risk for brain injuries after blunt head trauma. *Ann Emerg Med.* 2003;42:492-506. [https://doi.org/10.1067/S0196-0644\(03\)00425-6](https://doi.org/10.1067/S0196-0644(03)00425-6)
18. Maguire JL, Boutis K, Uleryk EM, Laupacis A, Parkin PC. Should a head-injured child receive a head CT scan? A systematic review of clinical prediction rules. *Pediatrics.* 2009;124:145-54. <https://doi.org/10.1542/peds.2009-0075> PMID:19564261
19. Homer CJ, Kleinman L. Technical report: minor head injury in children. *Pediatrics.* 1999;104: e78. <https://doi.org/10.1542/peds.104.6.e78> PMID:10586012
20. Bahadori A, Miglioretti D, Kruger R, et al. Calculation of Organ Doses for a Large Number of Patients Undergoing CT Examinations. *AJR Am J Roentgenol.* 2015;205:827-33. <https://doi.org/10.2214/AJR.14.14135> PMID:26397332 PMCid:PMC5384467
21. Frush DP, Donnelly LF, Rosen NS. Computed tomography and radiation risks: what pediatric health care providers should know. *Pediatrics.* 2003;112:951-57. <https://doi.org/10.1542/peds.112.4.951> PMID:14523191
22. Brenner DJ. Estimating cancer risks from pediatric CT: going from the qualitative to the quantitative. *Pediatr Radiol.* 2002;32:221-228. <https://doi.org/10.1007/s00247-002-0671-1> PMID:11956700
23. Mazonakis M, Tzedakis A, Damilakis J, Gourtsoyiannis N. Thyroid dose from common head and neck CT examinations in children: is there an excess risk for thyroid cancer induction? *Eur Radiol.* 2007;17:1352-57. <https://doi.org/10.1007/s00330-006-0417-9> PMID:17021703
24. Givner A, Gurney J, O'Connor D. Reimaging in pediatric neurotrauma: factors associated with progression of intracranial injury. *J Pediatr Surg.* 2002;37:381-85. <https://doi.org/10.1053/jpsu.2002.30825> PMID:11877652
25. Oertel M, Kelly DF, McArthur D, et al. Progressive hemorrhage after head trauma: predictors and consequences of the evolving injury. *J Neurosurg.* 2002;96:109-16. <https://doi.org/10.3171/jns.2002.96.1.0109> PMID:11794591
26. Smith JS, Chang EF, Rosenthal G, et al. The role of early follow-up computed tomography imaging in the management of traumatic brain injury patients with intracranial hemorrhage. *J Trauma.* 2007;63:75-82. <https://doi.org/10.1097/01.ta.0000245991.42871.87> PMID:17622872
27. Dunning J, Daly JP, Lomas JP, et al. Children's head injury algorithm for the prediction of important clinical events study g. Derivation of the children's head injury algorithm for the prediction of important clinical events decision rule for head injury in children. *Arch Dis Child.* 2006;91:885-891. <https://doi.org/10.1136/adc.2005.083980> PMID:17056862 PMCid:PMC2082967
28. Howe J, Fitzpatrick CM, Lakam DR, Gleisner A, Vane DW. Routine repeat brain computed tomography in all children with mild traumatic brain injury may result in unnecessary radiation exposure. *J Trauma Acute Care Surg.* 2014;76:292-95. Discussion, 295-96.