



Complete Dentures Fabricated with CAD/CAM Technology and a Traditional Clinical Recording Method

Nadica Janeva^{1*}, Gordana Kovacevska¹, Edvard Janev²

¹Department of Prosthodontics, Faculty of Dentistry, Ss. Cyril and Methodius University of Skopje, Skopje, Republic of Macedonia; ²Faculty of Dentistry, Oral Surgery, Ss. Cyril and Methodius University of Skopje, Skopje, Republic of Macedonia

Abstract

Citation: Janeva N, Kovacevska G, Janev E. Complete Dentures Fabricated with CAD/CAM Technology and a Traditional Clinical Recording Method. Open Access Maced J Med Sci. <https://doi.org/10.3889/oamjms.2017.169>

Keywords: complete denture; CAD/CAM; complete digital denture; traditional clinical recording method; digital dentistry.

***Correspondence:** Nadica Janeva. Department of Prosthodontics, Faculty of Dentistry, Ss. Cyril and Methodius University of Skopje, Skopje, Republic of Macedonia. E-mail: njaneva@stomfak.ukim.edu.mk

Received: 04-Jun-2017; **Revised:** 10-Jul-2017;
Accepted: 10-Aug-2017; **Online first:** 06-Oct-2017

Copyright: © 2017 Nadica Janeva, Gordana Kovacevska, Edvard Janev, This is an open-access article distributed under the terms of the Creative Commons Attribution-NonCommercial 4.0 International License (CC BY-NC 4.0).

Funding: This research did not receive any financial support.

Competing Interests: The authors have declared that no competing interests exist.

The introduction of computer-aided design/computer-aided manufacturing (CAD/CAM) technology into complete denture (CD) fabrication ushered in a new era in removable prosthodontics. Commercially available CAD/CAM denture systems are expected to improve upon the disadvantages associated with conventional fabrication. The purpose of this report is to present the workflow involved in fabricating a CD with a traditional clinical recording method and CAD/CAM technology and to summarize the advantages to the dental practitioner and the patient.

Introduction

After nearly 80 years of minimally changed methods and protocols to fabricate complete dentures (CDs), the first commercially available computer-aided design/computer-aided manufacturing (CAD/CAM) denture systems heralded a new era in removable prosthodontics. The complexity of CD fabrication procedures is the main reason digital technology has become available only recently for CD prosthodontics compared to other fixed prosthodontic restorations [1].

The first attempts at the development of a computer-aided system for designing and fabricating removable CDs were performed by Maeda et al. [2]. Since then, many developments have been made for improving the methods of collecting the data and

conversion to virtual impressions [3-6].

CAD/CAM technology has become commercially available for CD fabrication through the introduction of AvaDent digital dentures (Global Dental Science LLC [GDS]) and the Dentca CAD/CAM system (Dentca Inc). In 2013, Katadiyil et al. described the procedures associated with both systems [7]. Infante et al. presented a technique to fabricate a CD with CAD/CAM technology in two clinical appointments using the AvaDent system along with the clinical steps to obtain impressions, maxillomandibular relation records, and anterior tooth position with an anatomic measuring device (AMD) [8]. Modified and shortened clinical protocol, computer-aided design of the CDs, and 5-axis milling from prepolymerized poly(methylmethacrylate) PMMA pucks is believed to overcome most of the disadvantages of conventional CDs. In the last few years, since the first case reports have been

published on the implementation of digital technology in the field of CDs, many advancements have been made, and new CAD/CAM denture systems have been introduced [9-12].

Although dental companies have developed additional recording tools and tray systems for recording clinical information and introduced clinical protocols for them, the traditional recording protocol is acceptable. Currently, there are no published clinical reports that combine CAD/CAM technology and a traditional clinical recording method. The purpose of this clinical report is to present CDs fabricated with CAD/CAM technology using a traditional clinical recording method.

Clinical Report

A 63-year-old man presented without any significant medical problems to receive a new pair of CAD/CAM-fabricated CDs. The maxillary and mandibular arches were U-shaped, minimally resorbed, and firm with healthy mucosa.

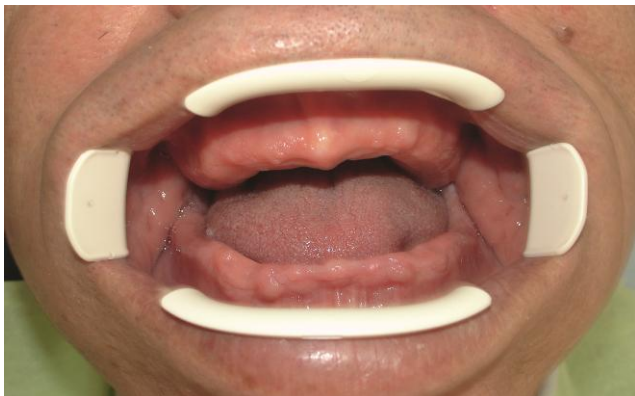

Figure 1: Clinical condition

After the initial examination, the first impressions were made with stock trays and irreversible hydrocolloid material (Alginoplast regular set, Heraeus Kulzer GmbH) and the impressions were sent to a dental laboratory for the fabrication of custom trays and occlusal rims. Occlusal rims and custom trays were made on the same stone casts.

The definitive impressions of the maxilla and mandible were made with thermoplastic border moulding material (impression compound green, Hoffman Dental Manufaktur GmbH) and wash impressions were made with low-viscosity wash material (Xantopren L blue, Heraeus Kulzer GmbH).

Following the basic protocol for CDs, the maxillomandibular relationship was recorded. The maxillary occlusal rim was contoured for proper lip

support and an incisal edge position of the maxillary teeth; then, the level of the occlusal plane was determined using a Fox occlusal plane plate (Trubyte, Dentsply).

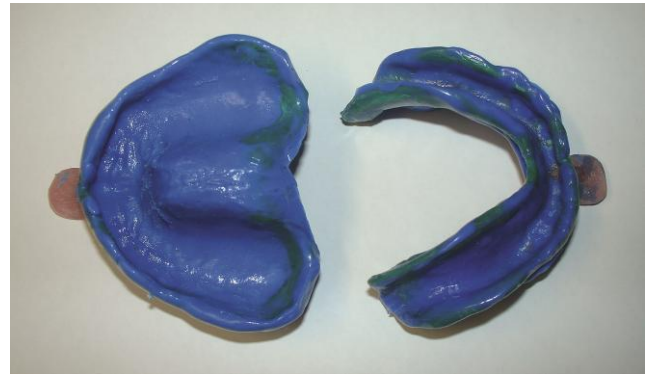

Figure 2: Maxillary and mandibular definitive impressions

Two measuring dots were marked on the most prominent points on the nose and the chin for measuring the resting vertical dimension (RVD), while patient was wearing the contoured maxillary rim; once the RVD was established, mandibular rim was adjusted to contact the maxillary occlusal rim evenly at a maxillomandibular vertical dimension, 3 mm less than the RVD. A thin wash was made in the occlusal rims to create enough detail to match to the definitive impressions when aligning the records in the design software. The maxillomandibular horizontal relation was registered in manually guided retruded contact position, and the occlusal rims were connected. The midline, smile line, and positions of the canines were marked. The tooth shape and tooth colour were selected, and the order form was completed.




Figure 3: Occlusal record with wash impression

In the dental laboratory, the maxillary and definitive mandibular impressions and the occlusal rims were prepared for scanning with scan spray.

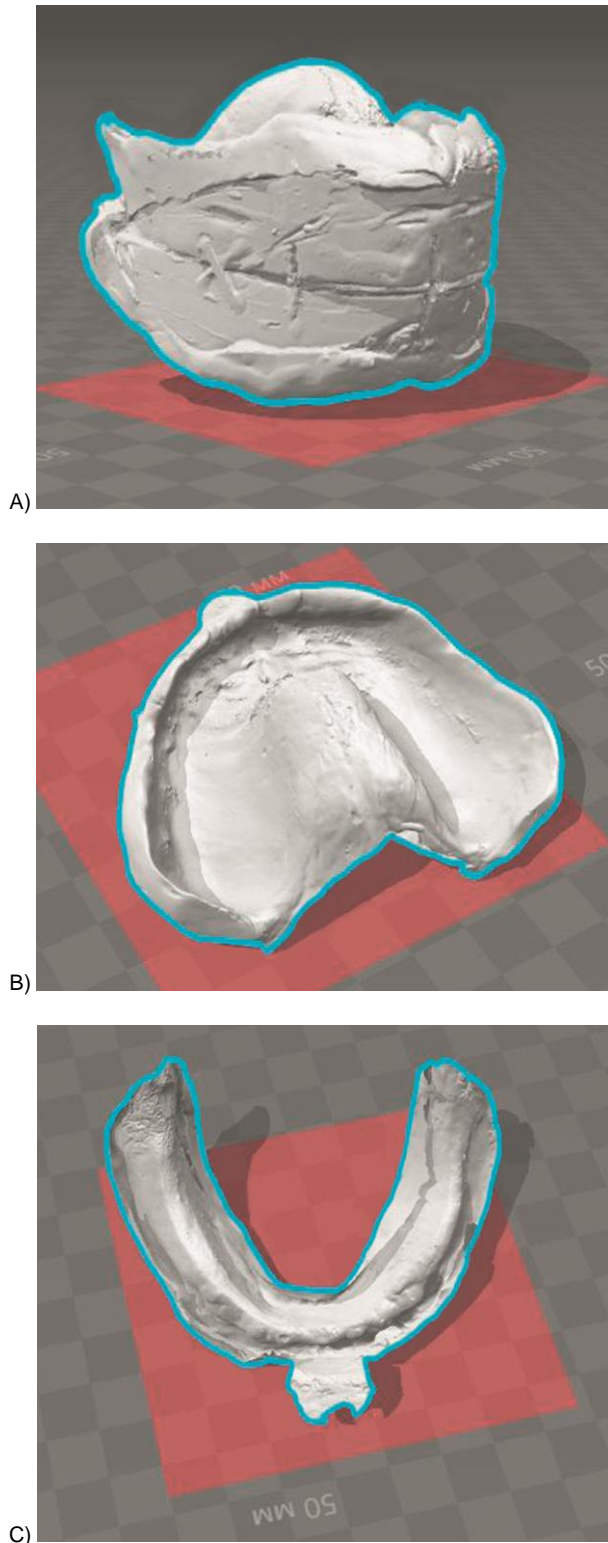


Figure 4: Screenshots of STL files; 4A. Occlusal_rims; 4B: Maxillary impression; 4C: Mandibular impression

Scanning was performed with an optical 3D scanner (Model Smart, Open Technologies Srl.). The files from the laser-scanned maxillary and definitive mandibular impressions and connected occlusal rims were translated into stereolithography (STL) files and

were sent to GDS, the Netherlands, along with the order form.

Once the CDs have been virtually designed in GDS software, a preview is sent for evaluation using 3D viewing software. After minor modifications in the positions of teeth were made, fabrication of the dentures was approved.

The digital dentures were fabricated from prepolymerized resin acrylic pucks (AvaDent PMMA Pucks, GDS) and were delivered with teeth (SR Vivodent DCL, Ivoclar Vivadent GmbH) bonded in the milled recesses.

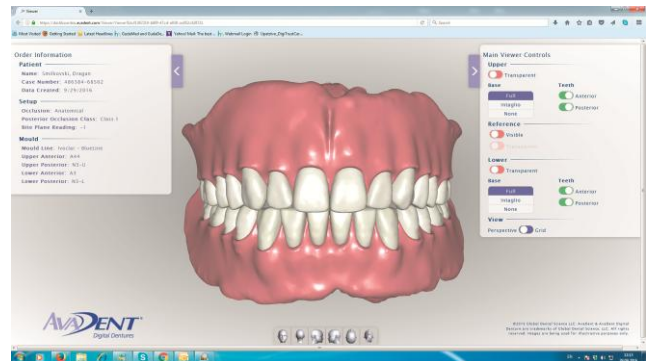


Figure 5: Preview of virtually designed dentures

After placement, clinical evaluations of the fit, retention, stability, occlusal relationship, esthetics, and phonetics were performed. Assessment of the occlusion was made with articulating paper, chairside adjustments were made and a few minor premature contacts were corrected. Adjustments were made only on overextended lingual flanges, which were shortened on both sides of the mandibular denture. The excellent fit was confirmed using pressure-indicating paste. The digital CDs met the clinical requirements.

Routine follow-up appointments were scheduled for two days and one week after placement. During the follow-up visits, the patient was satisfied with the esthetics, function and comfort of the dentures.

Discussion

Although the first clinical studies emphasised greater overall patient satisfaction and satisfactory clinical treatment outcomes, more research is needed to confirm the expectations from this technique [11-13].

Compared with the conventional technique for fabricating CDs, the digital workflow has several

advantages. Besides a reduction in the number of visits and reduced clinical chair time, the repository of digital data in the manufacturer (GDS) database allows for the rapid future fabrication of spare or replacement dentures.

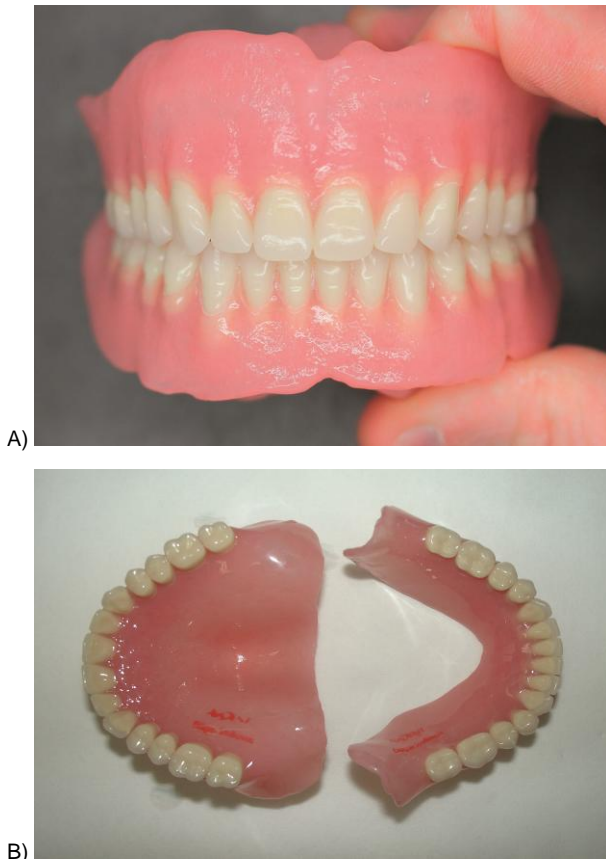


Figure 6: 6A: Completed digital dentures; 6B: Cameo surface view

Since the dentures are milled from a prepolymerized acrylic resin puck, which is produced under high pressure and heat, polymerisation shrinkage does not occur, porosity is decreased, and the adherence of *Candida albicans* to the denture base is decreased [8]. The lack of polymerisation shrinkage associated with milled dentures results in a highly accurate denture fit and improved retention [14, 15].

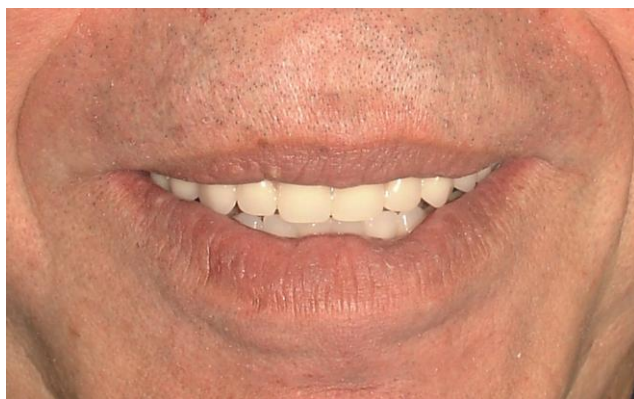

Figure 7: Patient with complete digital dentures

Indeed, the excellent retention and outstanding suction effect of the CDs in the present case could be explained by improved fit due to the lack of polymerisation shrinkage.

The virtual design process allows one to define the minimal thickness of the denture bases and to add a stippled structure and anatomic features on the polished surfaces of the dentures. In the present situation, the addition of palatal rugae to the maxillary denture greatly contributed to a positive first impression on the patient after placement of the dentures.

The lack of clinical trial placement procedures might be a disadvantage of using CAD/CAM dentures. To assess the fit, maxillomandibular relationship, occlusion, and esthetics of the future dentures, the denture system used in this case (AvaDent) offers a trial placement denture. To reduce costs, a trial placement denture was not requested.

The definitive impressions and the maxillomandibular relation can be obtained using different techniques. According to Schwindling et al., improvements leading to the recording of the maxillomandibular relation using manual methods might increase the attractiveness of digital CD systems [12]. The traditional recording method is acceptable because of the absence of stock thermoplastic trays and jaw relation recording tools and the insufficient experience of clinicians with Gothic arch tracing devices and inappropriate clinical situations for their use [7]. When sending data to the manufacturer for designing and milling, an accurate maxillomandibular record, acceptable definitive impressions, and satisfactory overall records result in an outcome with favourable properties. Further clinical research is needed to validate the traditional maxillomandibular relationship recording as an alternative method which can provide the clinicians with balanced dentures fabricated with CAD/CAM technology.

The present concept successfully combines the advantages of CAD/CAM technology and a traditional clinical recording method. The workflow is completely driven by CAD/CAM technology and eliminates many of the disadvantages of each laboratory step required by traditional denture fabrication and helps to simplify the work.

References

1. Bilgin MS, Erdem A, Aglarci OS, Dilber E. Fabricating complete dentures with CAD/CAM and RP technologies. *J Prosthodont.* 2015;24:576-9. <https://doi.org/10.1111/jopr.12302> PMID:26032438
2. Maeda Y, Minoura M, Tsutsumi S, Okada M, Nokubi T. A CAD/CAM system for removable denture. Part I: Fabrication of complete dentures. *Int J Prosthodont.* 1994;7:17-21. PMID:8179777

3. Kawahata N, Ono H, Nishi Y, Hamano T, Nagaoka E. Trial of duplication procedure for complete dentures by CAD/CAM. *J Oral Rehabil.* 1997;24:540-8. <https://doi.org/10.1046/j.1365-2842.1997.00522.x> PMID:9250843
4. Kanazawa M, Inokoshi M, Minakuchi S, Ohbayashi N. Trial of a CAD/CAM system for fabricating complete dentures. *Dent Mater J.* 2011;30:93-6. <https://doi.org/10.4012/dmj.2010-112> PMID:21282882
5. Inokoshi M, Kanazawa M, Minakuchi S. Evaluation of a complete denture trial method applying rapid prototyping. *Dent Mater J.* 2012;31:40-6. <https://doi.org/10.4012/dmj.2011-113> PMID:22277604
6. Goodacre CJ, Garbacea A, Naylor WP, Daher T, Marchack CB, Lowry J. CAD/CAM fabricated complete dentures: concepts and clinical methods of obtaining required morphological data. *J Prosthet Dent.* 2012;107:34-46. [https://doi.org/10.1016/S0022-3913\(12\)60015-8](https://doi.org/10.1016/S0022-3913(12)60015-8)
7. Kattadiyil MT, Goodacre CJ, Baba NZ. CAD/CAM complete dentures: a review of two commercial fabrication systems. *J Calif Dent Assoc.* 2013;41:407-16. PMID:23875432
8. Infante L, Yilmaz B, McGlumphy, Finger I. Fabricating complete dentures with CAD/CAM technology. *J Prosthet Dent.* 2014;111:351-5. <https://doi.org/10.1016/j.prosdent.2013.10.014> PMID:24461946
9. Baba NZ, AIRumaih HS, Goodacre BJ, Goodacre CJ. Current techniques in CAD/CAM denture fabrication. *Gen Dent.* 2016;64:23-28. PMID:27814252
10. Saponaro PC, Yilmaz B, Heshmati RH, McGlumphy EA. Clinical performance of CAD-CAM-fabricated complete dentures: a cross-sectional study. *J Prosthet Dent.* 2016;116:431-435. <https://doi.org/10.1016/j.prosdent.2016.03.017> PMID:27160780
11. Saponaro PC, Yilmaz B, Johnston W, Heshmati RH, McGlumphy EA. Evaluation of patient experience and satisfaction with CAD-CAM-fabricated complete denture: a retrospective survey study. *J Prosthet Dent.* 2016;116:524-528. 13
12. Schwindling FS, Stober T. A comparison of two digital techniques for the fabrication of complete removable dental prostheses: A pilot clinical study. *J Prosthet Dent.* 2016;116:756-763. <https://doi.org/10.1016/j.prosdent.2016.03.022> PMID:27236597
13. Kattadiyil MT, Jekki R, Goodacre CJ, Baba NZ. Comparison of treatment outcomes in digital and conventional complete removable dental prosthesis fabrications in a predoctoral setting. *J Prosthet Dent.* 2015;114:818-825. <https://doi.org/10.1016/j.prosdent.2015.08.001> PMID:26412000
14. Goodacre BJ, Goodacre CJ, Baba NZ, Kattadiyil MT. Comparison of denture base adaptation between CAD/CAM and conventional fabrication techniques. *J Prosthet Dent.* 2016;116:249-256. <https://doi.org/10.1016/j.prosdent.2016.02.017> PMID:27112416
15. Bidra AS, Taylor TD, Agar JR. Computer-aided technology for fabricating complete dentures: systematic review of historical background, current status, and future perspective. *J Prosthet Dent.* 2013;109:361-6. [https://doi.org/10.1016/S0022-3913\(13\)60318-2](https://doi.org/10.1016/S0022-3913(13)60318-2)