

Protective Effects of the Third Generation Vasodilatory Beta - Blocker Nebivolol against D-Galactosamine - Induced Hepatorenal Syndrome in Rats

Ahmed Atwa^{1*}, Rehab Hegazy², Rania Mohsen³, Neamat Yassin², Sanaa Kenawy³

¹Department of Pharmacology and Toxicology, Faculty of Pharmacy, Egyptian Russian University, Badr City, Egypt;

²Department of Pharmacology, Medical Division, National Institution Research, Giza, Egypt; ³Departement of Pharmacology and Toxicology, Faculty of Pharmacy, Cairo University, Cairo, Egypt

Abstract

Citation: Atwa A, Hegazy R, Mohsen R, Yassin N, Kenawy S. Protective Effects of the Third Generation Vasodilatory Beta - Blocker Nebivolol against D-Galactosamine - Induced Hepatorenal Syndrome in Rats. Open Access Maced J Med Sci. <https://doi.org/10.3889/oamjms.2017.173>

Keywords: Hepatorenal syndrome; Nebivolol; Nitric oxide; Sprague-Dawley rats; Galactosamine

***Correspondence:** Ahmed Atwa. Department of Pharmacology and Toxicology, Faculty of Pharmacy, Egyptian Russian University, Badr City, Egypt. E-mail: dr.atwa_911@hotmail.com

Received: 03-Aug-2017; **Revised:** 27-Aug-2017; **Accepted:** 25-Nov-2017; **Online first:** 13-Dec-2017

Copyright: © 2017 Ahmed Atwa, Rehab Hegazy, Rania Mohsen, Neamat Yassin, Sanaa Kenawy. This is an open-access article distributed under the terms of the Creative Commons Attribution-NonCommercial 4.0 International License (CC BY-NC 4.0).

Funding: This research did not receive any financial support.

Competing Interests: The authors have declared that no competing interests exist.

BACKGROUND: Renal dysfunction is very common in patients with advanced liver cirrhosis and portal hypertension. The development of renal failure in the absence of clinical, anatomical or pathological causes renal of failure is termed hepatorenal syndrome (HRS).

AIM: The present study was constructed to investigate the possible protective effects of nebivolol (Nebi) against D-galactosamine (Gal)-induced HRS in rats.

MATERIAL AND METHODS: Rats were treated with Nebi for ten successive days. On the 8th day of the experiment, they received a single dose of Gal. Serum levels of Cr, BUN, Na⁺ and K⁺ as well as AST, ALT, total bilirubin (TB), NH₃ and endothelin-1 (ET-1) were determined following Gal administration. Moreover, renal and liver contents of MDA, GSH, F₂-isoprostanes (F₂-IPs), tumor necrosis factor-alpha (TNF-α), nuclear factor kappa-B (NF-κB), total nitric oxide (NO), in addition to activities of caspase-3 (Cas-3), heme oxygenase-1 (HO-1), inducible and endothelial NO synthase (iNOS and eNOS) enzymes were also assessed. Finally, histopathological examination was performed.

RESULTS: Nebi attenuated Gal-induced renal and hepatic dysfunction. It also decreased the Gal-induced oxidative stress and inflammatory recruitment.

CONCLUSION: Results demonstrated both nephroprotective and hepatoprotective effects of Nebi against HRS and suggested a role of its antioxidant, anti-inflammatory, anti-apoptotic and NO-releasing properties.

Introduction

Renal failure occurs in 40-80% of patients with end-stage liver disease and is associated with an unfavourable prognosis. The development of renal failure in the absence of clinical, anatomical, or pathological causes of renal failure is termed the HRS [1].

Typical features of HRS include oliguria, hyponatremia, azotemia and hyponatremia. Although the pathophysiological mechanism underlying HRS is still incompletely understood, marked renal

vasoconstriction in the presence of splanchnic and systemic vasodilation may play an important role, and may thus reduce the renal arterial blood flow and the glomerular filtration rate, resulting in renal impairment [2-4]. One of the hallmarks of HRS is that there are relatively few histological changes in the kidneys, and that renal failure is secondary to haemodynamic and functional changes in the kidney. So far, no effective strategies are available for the treatment or prevention of HRS. Instead, patients are usually managed by maintaining their adequate hemodynamic status and intravascular volume. A better understanding of the pathophysiological mechanism underlying the transition from liver damage to renal failure helps to

guide its treatment [2, 4, 5].

Galactosamine is a potent hepatotoxic substance, which can cause hepatocyte death both by necrosis and apoptosis secondary to inhibition of hepatic RNA synthesis [6]. Studies also found that animals rapidly developed functional acute renal failure in addition to acute damage and liver failure, following intoxication with Gal [7]. Following a single injection of high dose Gal, rats develop acute liver failure with development of a hyperdynamic circulation. It was reported that Gal-induced liver injury is associated with the development of renal failure [8].

Many factors may contribute to Gal-induced HRS. Patients who develop HRS, particularly in the context of acute liver failure or alcoholic hepatitis, have increased circulating concentrations of the potent vasoconstrictor peptide endothelin-1 (ET-1) [9].

Additionally, NO is elevated in patients with cirrhosis; the imbalance between it and vasoconstrictors such as ET-1 in the renal microcirculation has been proposed to be responsible for the deterioration of kidney function in these patients. Moreover, a progressive rise in levels of NO had been proposed during progressive renal dysfunction in cirrhosis [10]. NO produced by iNOS is reported to have aggravated liver and kidney injury, while eNOS expression preserved physiological functions [11].

Moreover, oxidative stress is markedly elevated in chronic liver disease and has gained attention as a potentially important factor in altered hemodynamics and renal dysfunction in cirrhosis. It induces renal vasoconstriction not only by quenching NO, but also by increasing production of F₂-IPs (F₂-isoprostanes; formed as a result of free radical-mediated non-enzymatic peroxidation of membrane-bound arachidonic acid which can be used to evaluate local or systemic lipid peroxidation *in vivo*) and ET-1 in addition to damaging DNA and provoking apoptosis [12]. Markedly increased levels of both factors in patients with HRS in conjunction with increased systemic oxidative stress in cirrhosis raises the possibility of a pathogenetic role of oxidative stress in HRS [13]. Excessive oxidative stress has been suggested as a reason for HO-1 up-regulation, and this enzyme is known to play a role in the inflammatory process and oxidative tissue damage in Gal-induced acute liver injury. On the other hand, previous studies denoted that decreased renal HO-1 expression plays an important role in the pathogenesis of experimental HRS [14].

It has been well recognized that an unregulated inflammatory response is a key mechanism of Gal-induced acute hepatotoxicity. TNF- α is a pro-inflammatory cytokine secreted by liver Kupffer cells as an inflammatory response [15]. It modulates the necrotic, apoptotic and inflammatory

pathways in Gal-induced hepatotoxicity by activating transcription factors as NF- κ B. In respect of apoptosis, TNF- α combines with TNF- α receptor on the hepatocyte membrane activates caspase-3 and eventually induces apoptosis at an early stage through a series of signal transmission [16]. It has been reported that the transcription factor NF κ B plays an important role in the induction of iNOS because an NF κ B binding site has been identified in the promoter region of the iNOS gene. Inducible NOS-induced NO production is believed to play an important role in hepatocellular injury following endotoxemia and TNF- α stimulation [17].

Portal hypertension is an almost unavoidable complication of cirrhosis and provides the driving force for most of its complications, such as oesophageal and gastric varices, variceal bleeding, ascites, spontaneous bacterial peritonitis, hepatorenal syndrome, as well as portal-systemic encephalopathy. For medical treatment of portal hypertension, beta-blockers are used to decrease splanchnic inflow and may be combined with nitrates to reduce intrahepatic resistance [18].

Nebivolol is a third generation selective β ₁-adrenergic receptor blocker with vasodilator properties mediated by a direct stimulatory effect on the eNOS-L-arginine-NO pathway [19]. Treatment with Nebi has been shown to decrease renal fibrosis and glomerular injury as well as improving endothelial dysfunction. These effects have been attributed to vasodilatation, reduction in oxidative stress in addition to the enhancement of NO bioavailability [20]. Nebi may have beneficial effects on portal pressure, by decreasing splanchnic blood flow and decreasing intrahepatic resistance. Indeed, Nebi has been shown to be effective in a small case series of portal hypertensive patients with and without ascites [21].

Taken into consideration, these pharmacological properties of Nebi, with its renoprotective and hepatoprotective effects, could be of potential interest to patients with HRS. For that, the present study was performed to investigate the possible protective effects of Nebi against Gal-induced HRS in rats.

Material and Methods

Animals

Adult male Sprague Dawley rats, weighing 250-300 gram, were used in the present study. Standard food pellets and tap water were supplied *ad libitum*. Rats were kept under controlled conditions, with a 12 h light/dark cycles, at an ambient temperature of 22 \pm 2 $^{\circ}$ C and a humidity of 65–70%. This study was carried out in strict accordance with

the recommendations in the guide for the care and use of laboratory animals of the National Institutes of Health. The study protocol was approved by the guidelines of the Research Ethical Committee of the Faculty of Pharmacy, Cairo University, Cairo, Egypt (Permit Number: PT 734).

Drugs

Nebi was obtained from Sigma-Aldrich (USA). It was available as a powder and used in the current study at two dose levels of 10 and 20 mg/kg/day, p.o. [22]. Nebi was freshly prepared at the beginning of each experiment by being suspended in distilled water and volumes were adjusted so that each rat received 1 ml suspension/100 g body weight [23]. All other used chemicals were of the highest purity available.

Experimental Design

Hepatorenal syndrome was induced in rats using a single dose of Gal solution in sterile saline (1.1 g/kg, i.p.) [7]. Animals were randomly allocated into four groups; each group consisted of 12 rats. The first and second groups received saline and served as normal and control groups, respectively. Rats of all groups except the first received a single dose of Gal solution in sterile saline g/kg, i.p. on the 8th day of the experiment. Groups 3 & 4 received Nebi (10 & 20 mg/kg/day, respectively, p.o.). Administration of Nebi was carried out for ten successive days. Animals were allowed free access to food and tap water during the experiment.

Serum biochemical analysis

Blood samples were withdrawn via the retro-orbital plexus under ether anaesthesia from all rats on day 10, after two h of the last drug administration. Sera were separated for assessment of renal functions by measuring blood urea nitrogen (BUN), serum creatinine (SCr), potassium (K⁺) and sodium (Na⁺) levels, using specific commercial kits, (Stanbio, USA, catalogue No. 2050), (Quimica Clinica Aplicada S.A., Spain, catalogue No. 998891), (Quimica Clinica Aplicada S.A., Spain, catalogue No. 99111), and (Teco Diagnostics, USA, catalogue No. S600-50), respectively. Additionally, liver function tests were also assessed by measuring aspartate aminotransferase (AST), alanine aminotransferase (ALT), total bilirubin (TB) in addition to ammonia (NH₃) levels using specific commercial kits, (Quimica Clinica Aplicada S.A., Spain, catalogue No. 998720), (Quimica Clinica Aplicada S.A., Spain, catalogue No. 997610), (Quimica Clinica Aplicada S.A., Spain, catalogue No. 992714) and (MyBioSource Co., Inc., California, USA, catalogue No. MBS841579), respectively. Moreover, endothelin-1 (ET-1) level was estimated to judge the severity of vasoconstriction, using specific commercial ELISA kit (Immuno Biological Laboratories Co., Ltd,

Gunma, Japan, catalogue No. 27165).

Renal and liver tissue biochemical and histopathological analysis

Directly after collecting the blood samples, rats were sacrificed by cervical dislocation under ether anaesthesia, and both kidneys and liver tissues were isolated. The right kidneys and part of the liver tissues were rinsed in chilled 0.9 % NaCl (pH 7.4) then homogenised using a homogeniser (MPW- 120, Med instruments, Poland) to yield a 20% (w/v) tissue homogenate. The homogenates were used for estimation of kidney and liver contents of lipid peroxides in term of malondialdehyde (MDA) [24], reduced glutathione (GSH) [25], F₂-isoprostanes (F₂-IPs) using commercial ELISA kit (OXIS Health Products Co., Inc., Portland, catalogue No. 21049), tumor necrosis factor-alpha (TNF- α) using commercial ELISA kit (RayBiotech Co., Norcross GA, USA, catalogue No. ELR-TNF- α -001c), nuclear factor kappa-B (NF- κ B) using commercial reagent kit (Wuhan Eiaab Science Co., Wuhan, China, catalogue No. E1824r), nitric oxide (NO) measured as NO₃⁻/NO₂⁻ (nitrite and nitrate, stable metabolites of NO) using commercial reagent kit (Cayman chemical company, Germany, catalogue No. 780001). Moreover, kidney and liver activities of caspase-3 (Cas-3), inducible nitric oxide synthase (iNOS), endothelial nitric oxide synthase (eNOS) as well as heme-oxygenase-1 (HO-1) enzymes were also assessed, using specific commercial ELISA kits, (Uscn Life Science Co., Wuhan, China, catalogue No. E90626Mu), (Bioassay Technology Laboratory Co., Shanghai, China, catalogue No. E0704ra), (Wuhan Eiaab Science Co., Wuhan, China, catalogue No. E0868r) and (Uscn Life Science Co., Wuhan, China, catalogue No. E90584ra), respectively.

The left kidneys and the remaining parts of liver tissues from all groups were removed and fixed in 10% neutral buffered formal saline for at least 72 h. All the specimens were washed in tap water for half an hour and then dehydrated in ascending grades of alcohol, cleared in xylene and embedded in soft paraffin. Paraffin sections of 5 μ m thick were stained with haematoxylin and eosin (H&E) [26], for histopathological examination. Images were captured and processed using Adobe Photoshop version 8.0.

Statistical Analysis

All the values are presented as means \pm standard error of the means (SEM). Comparisons between different groups were carried out using one-way analysis of variance (ANOVA) followed by Tukey HSD test for multiple comparisons [27]. GraphPad Prism software, version 5 was used to carry out these statistical tests. The difference was considered significant when $p < 0.05$.

Results

Serum biochemical analysis

Induction of HRS in rats by a single dose of Gal markedly increased SCr and BUN levels on day ten by 217% and 372%, respectively. A marked decrease in Na⁺ level by 10% and increase in K⁺ by 54% level was also observed in Gal treated rats as compared with normal rats. Pretreatment of rats with Nebi (10 & 20 mg/kg) led to a significant reduction in SCr by 33% and 51% as well as BUN by 41% and 64%, respectively, compared to Gal group. Pretreatment of rats with Nebi (10 and 20 mg/kg) led to a significant elevation in Na⁺ by 8% and 10%, respectively, and to a significant reduction in K⁺ by 17% and 28%, respectively, compared to Gal group (Table 1).

Table 1: Effects of Nebi on serum levels of creatinine, blood urea nitrogen, sodium and potassium

Parameters	SCr (mg/dl)	BUN (mg/dl)	Na ⁺ (mEq/L)	K ⁺ (mmol/L)
Groups				
Normal (Saline)	b	b	b	b
Control Gal (1.1 g/kg)	0.64 ± 0.04	16.71 ± 0.57	137.86 ± 0.34	3.81 ± 0.09
Nebi (10 mg/kg) + Gal	2.03 ± 0.06	78.80 ± 0.59	123.57 ± 0.57	5.87 ± 0.07
Nebi (20 mg/kg) + Gal	1.36 ± 0.02	46.57 ± 0.65	132.86 ± 0.34	4.90 ± 0.03
	1.00 ± 0.03	28.29 ± 0.87	136.00 ± 0.31	4.20 ± 0.08

Saline, rats treated with saline and considered as normal rats; Gal, rats treated with galactosamine and served as control; Nebi + Gal, rats treated with galactosamine and nebiivolol; SCr, serum creatinine; BUN, blood urea nitrogen; Na⁺, serum sodium; K⁺, serum potassium. Data are presented as mean ± SE, n=12; a Significantly different from Saline; p < 0.05; b Significantly different from Gal; p < 0.05.

Saline, rats treated with saline and considered as normal rats; Gal, rats treated with galactosamine and served as control; Nebi + Gal, rats treated with galactosamine and nebiivolol; SCr, serum creatinine; BUN, blood urea nitrogen; Na⁺, serum sodium; K⁺, serum potassium. Induction of HRS in rats by a single dose of Gal markedly increased AST, ALT, NH₃ and TB levels on day ten by 339%, 432%, 1493% and 406%, respectively. Pretreatment of rats with Nebi (10 & 20 mg/kg) notably declined levels of AST by 50% and 71%, ALT by 51% and 73%, NH₃ by 68% and 84% and TB by 45% and 62%, respectively, compared to Gal group (Table 2).

Table 2: Effect of Nebi on serum levels of aspartate aminotransferase, alanine aminotransferase, ammonia and total bilirubin

Parameters	AST (U/ml)	ALT (U/ml)	NH ₃ (µg/ml)	TB (mg/dl)
Groups				
Normal (Saline)	b	b	b	b
Control Gal (1.1 g/kg)	23.00 ± 0.62	22.86 ± 0.55	0.58 ± 0.01	0.35 ± 0.01
Nebi (10 mg/kg) + Gal	100.86 ± 0.91	121.57 ± 0.95	9.24 ± 0.24	1.77 ± 0.04
Nebi (20 mg/kg) + Gal	50.14 ± 0.51	59.43 ± 0.20	2.99 ± 0.07	0.97 ± 0.01
	28.86 ± 0.34	33.29 ± 1.13	1.52 ± 0.04	0.67 ± 0.01

Saline, rats treated with saline and considered as normal rats; Gal, rats treated with galactosamine and served as control; Nebi + Gal, rats treated with galactosamine and nebiivolol; AST, serum aspartate aminotransferase; ALT, alanine aminotransferase; NH₃, serum ammonia; TB, total bilirubin. Data are presented as mean ± SE, n=12. A Significantly different from Saline; p < 0.05. B Significantly different from Gal; p < 0.05.

Induction of HRS in rats by a single dose of Gal markedly increased ET-1 levels on day ten by 759%. Pretreatment of rats with Nebi (10 and 20 mg/kg) resulted in a significant cutback in ET-1 levels by 57% and 73%, respectively, compared to Gal group (Table 3).

Table 3: Effect of Nebi on serum levels of endothelin-1

Parameters	ET-1 (pg/ml)
Groups	
Normal (Saline)	b
Control Gal (1.1 g/kg)	10.34 ± 0.33
Nebi (10 mg/kg) + Gal	88.87 ± 0.55
Nebi (20 mg/kg) + Gal	38.00 ± 0.82
	24.29 ± 0.53

Saline, rats treated with saline and considered as normal rats; Gal, rats treated with galactosamine and served as control; Nebi + Gal, rats treated with galactosamine and nebiivolol; ET-1, serum endothelin-1. Data are presented as mean ± SE, n=12. A Significantly different from Saline; p < 0.05. B Significantly different from Gal; p < 0.05.

Renal and liver tissue biochemical analysis

Induction of HRS in rats using Gal obviously augmented the normal renal and hepatic MDA contents by 493% and 508%, respectively and diminished GSH contents by 76% and 78%, respectively. Pretreatment of rats with Nebi (10 and 20 mg/kg) led to a significant dwindle in renal MDA contents by 59% and 76% and hepatic MDA contents by 57% and 72%, respectively, compared to Gal group (Fig. 1a). On the other hand, a recognisable rise in renal GSH contents by 71% and 123% and hepatic GSH contents by 87% and 136%, respectively, were seen as compared to Gal group (Fig. 1b).

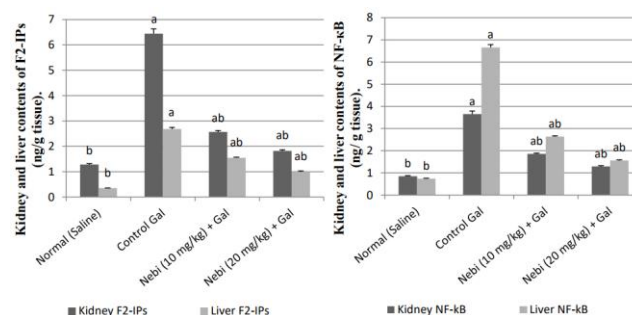


Figure 1: Effect of Nebi on Kidney and liver contents of MDA (left) and Kidney and liver contents of GSH (right). Saline, rats treated with saline and considered as normal rats; Gal, rats treated with galactosamine and served as control; Nebi + Gal, rats treated with galactosamine and nebiivolol; MDA, malondialdehyde; GSH, reduced glutathione. Data are presented as mean ± SE, n=12. A Significantly different from Saline; p < 0.05. b Significantly different from Gal; p < 0.05

Induction of HRS in rats using Gal strikingly increased the normal renal and hepatic F2-IPs contents by 403% and 666%, respectively and increased NF-κB contents by 329% and 799%, respectively. Pretreatment of rats with Nebi (10 and 20 mg/kg) led to a significant decline in renal F2-IPs

contents by 60% and 72% and hepatic F2-IPs contents by 42% and 63%, respectively, compared to Gal group (Fig. 2a). Moreover, Pretreatment of rats with Nebi (10 and 20 mg/kg) led to a significant drop in renal NF-κB contents by 49% and 65% as well as hepatic NF-κB contents by 60% and 77%, respectively, compared to Gal group (Fig. 2b).

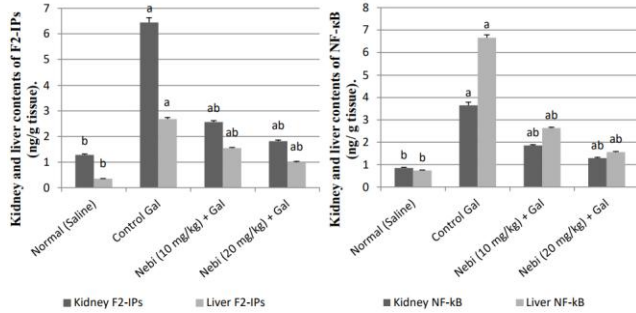


Figure 2: Effect of Nebi on Kidney and liver contents of F2-IPs (left) and Kidney and liver contents of NF-κB (right). Saline, rats treated with saline and considered as normal rats; Gal, rats treated with galactosamine and served as control; Nebi + Gal, rats treated with galactosamine and nebivolol; F2-IPs, F2-isoprostanes; NF-κB, nuclear factor-κB. Data are presented as mean ± SE, n=12. A Significantly different from Saline; p < 0.05. b Significantly different from Gal; p < 0.05

Induction of HRS in rats using Gal evidently amplified the normal renal and hepatic TNF-α content by 950% and 666%, respectively and augmented Cas-3 activity by 699% and 629%, respectively. Pretreatment of rats with Nebi (10 and 20 mg/kg) led to a significant reduction in renal TNF-α contents by 57% and 73% and hepatic TNF-α contents by 60% and 76%, respectively, compared to Gal group (Fig. 3a). Additionally, Nebi (10 & 20 mg/kg) achieved a marked fall in renal Cas-3 activity by 51% and 74% and hepatic Cas-3 activity by 57% and 76%, respectively, compared to Gal group (Fig. 3b).

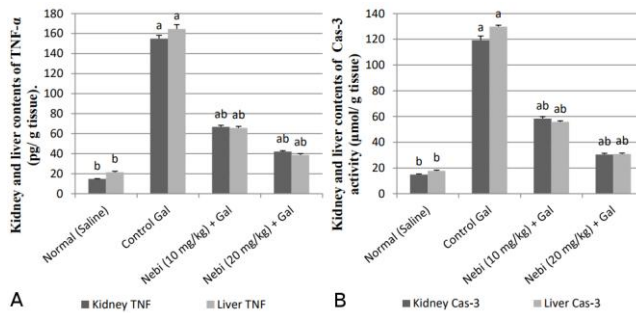


Figure 3: Effect of Nebi on (A) Kidney and liver contents of TNF-α and (B) Kidney and liver Cas-3 activity. Saline, rats treated with saline and considered as normal rats; Gal, rats treated with galactosamine and served as control; Nebi + Gal, rats treated with galactosamine and nebivolol; TNF-α, tumour necrosis factor-alpha; Cas-3, caspase-3. Data are presented as mean ± SE, n=12. a Significantly different from Saline; p < 0.05. b Significantly different from Gal; p < 0.05

Induction of HRS in rats using Gal markedly intensified the normal renal and hepatic NOx contents by 533% and 563%, respectively and raised renal &

hepatic iNOS activity by 592% and 311%, respectively. Pretreatment of rats with Nebi (10 and 20 mg/kg) led to a significant decline in renal NOx contents by 58% and 76% and hepatic NOx contents by 60% and 78%, respectively, compared to Gal group (Fig. 4a). In the same line, pretreatment of rats with Nebi (10 and 20 mg/kg) led to a significant regression in renal iNOS activity by 63% and 77% and hepatic iNOS activity by 56% and 68%, respectively, compared to Gal group (Fig. 4b).

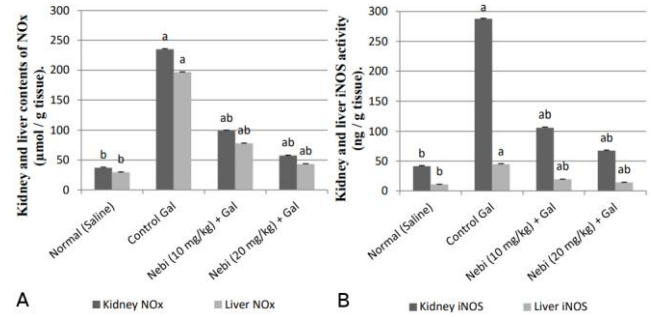


Figure 4: Effect of Nebi on (A) Kidney and liver contents of NOx and (B) Kidney and liver iNOS activity. Saline, rats treated with saline and considered as normal rats; Gal, rats treated with galactosamine and served as control; Nebi + Gal, rats treated with galactosamine and nebivolol; NOx, nitrite and nitrate, stable metabolites of NO; iNOS, inducible nitric oxide synthase. Data are presented as mean ± SE, n=12. a Significantly different from Saline; p < 0.05. b Significantly different from Gal; p < 0.05

Induction of HRS in rats using Gal prominently decreased the normal renal HO-1 activity by 76% and increased hepatic HO-1 activity by 717%. On the other hand, normal renal eNOS activity decreased by 52% and normal hepatic eNOS activity increased by 903%. Pretreatment of rats with Nebi (10 and 20 mg/kg) led to a significant surge in renal HO-1 activity by 86% and 210% and renal eNOS activity by 53% and 96%, respectively, compared to Gal group. On the contrary, pretreatment of rats with Nebi (10 and 20 mg/kg) led to a significant reduction in hepatic HO-1 activity by 56% and 69% in addition to hepatic eNOS activity by 67% and 84%, respectively, compared to Gal group (Fig. 5 a & b).

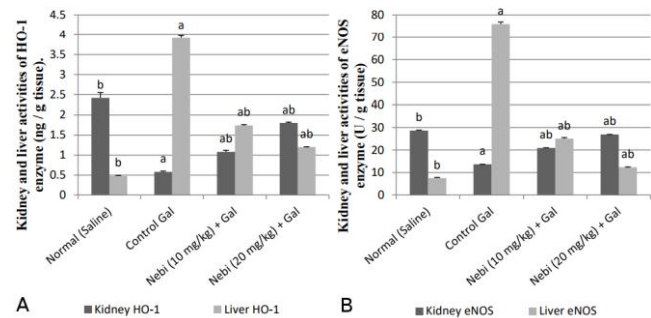


Figure 5: Effect of Nebi on (A) Kidney and liver HO-1 activity and (B) Kidney and liver eNOS activity. Saline, rats treated with saline and considered as normal rats; Gal, rats treated with galactosamine and served as control; Nebi + Gal, rats treated with galactosamine and nebivolol; HO-1, heme-oxygenase-1; eNOS, endothelial nitric oxide synthase. Data are presented as mean ± SE, n=12. a Significantly different from Saline; p < 0.05. b Significantly different from Gal; p < 0.05

Histopathological features of the renal and liver tissues

The renal tissue of the normal rats showed the normal histological structure of the glomeruli (g) and tubules (t) at the cortex besides the normal histological structure of the tubules at the corticomedullary portion (cm) (Fig. 6 A & B).

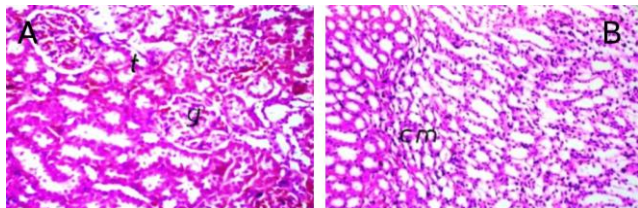


Figure 6: Photomicrographs of renal and liver sections from rats treated with the following: Saline (A) & (B) show normal histological structure of the glomeruli (g) and tubules (t) at the cortex besides the normal histological structure of the tubules at the corticomedullary portion (cm)

The liver tissue of the normal rats showed the normal histological structure of the portal area (Pa) and surrounding hepatocytes (h) besides the normal histological structure of the of the central vein (cv) (Fig. 7C & D).

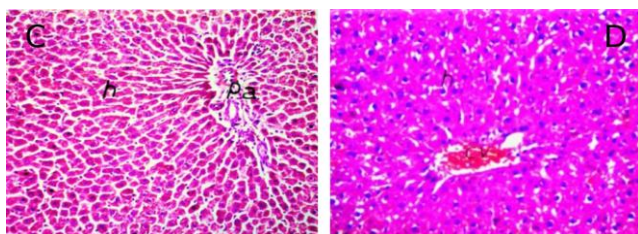


Figure 7: Photomicrographs of renal and liver sections from rats treated with the following: Saline (C) & (D) show the normal histological structure of the portal area (Pa) and surrounding hepatocytes (h) besides the normal histological structure of the of the central vein (cv)

In rats treated with Gal (1.1 g/kg) and sacrificed after 48 h from Gal administration, the renal tissues showed a marked congestion in the blood vessels (v) and glomeruli (g) associated with perivascular edema and inflammatory cells infiltration (m) and degeneration in the lining epithelium of the tubules (d) in addition to focal hemorrhage in the corticomedullary portion (h) (Fig. 8 E & F).

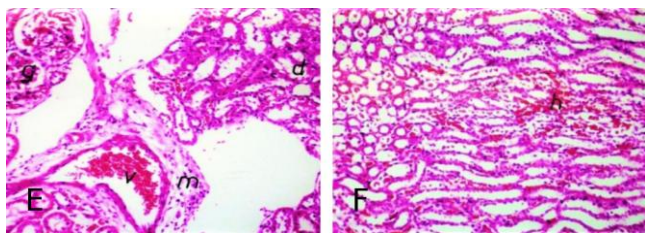


Figure 8: Photomicrographs of renal and liver sections from rats treated with the following: Gal (E & F) the renal tissues show a marked congestion in the blood vessels (v) and glomeruli (g) associated with perivascular edema and inflammatory cells infiltration (m) and degeneration in the lining epithelium of the tubules (d) in addition to focal hemorrhage in the corticomedullary portion (h) (H & E X 40)

In rats treated with Gal (1.1 g/kg) and sacrificed after 48 h from Gal administration, the liver tissues showed marked diffuse coagulative necrosis in the hepatocytes (hn) surrounding the central vein (cv) (Fig. 9 G).

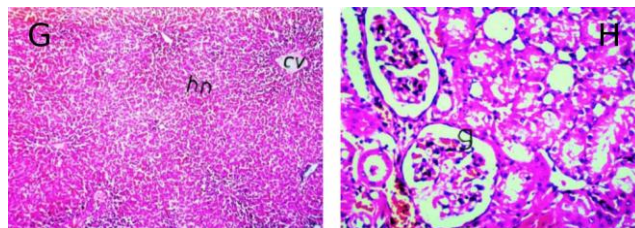


Figure 9: Photomicrographs of renal and liver sections from rats treated with the following: Gal (G) the renal tissues show a marked congestion in the blood vessels and glomeruli (g) associated with perivascular edema and inflammatory cells infiltration (m) and degeneration in the lining epithelium of the tubules (d) in addition to focal hemorrhage in the corticomedullary portion (h), while the liver tissues show marked diffuse coagulative necrosis in the hepatocytes (hn) surrounding the central vein (cv) (H & E X 16)

The renal tissues of rats with Gal-induced HRS that were pretreated with Nebi (10 mg/kg/day) showed glomerular congestion (g) in addition to tubular degeneration (d) with tubular cystic dilation (c) in corticomedullary portion (Fig. 9 H & Fig. 10 I). The liver tissues of rats with Gal-induced HRS that were pretreated with Nebi (10 mg/kg/day) showed inflammatory cells aggregation (m), congestion in portal vein as well bile duct hyperplasia (bd) in association with hepatocellular degeneration (arrow) (Fig. 10 J).

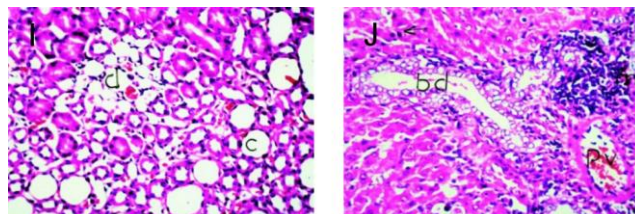


Figure 10: Photomicrographs of renal and liver sections from rats treated with the following: Nebi (10 mg) + Gal (I & J) the renal tissues show glomerular congestion (g) in addition to tubular degeneration (d) with tubular cystic dilation (c) in corticomedullary portion, while the liver tissues show inflammatory cells aggregation (m), congestion in portal vein as well bile duct hyperplasia (bd) in association with hepatocellular degeneration (arrow)

The renal tissues of rats with Gal-induced HRS that were pretreated with Nebi (20 mg/kg/day) showed inflammatory cells infiltration (m) in between the tubules of the cortex and congestion in blood vessels (v) with focal inflammatory cells infiltration in between the degenerated (d) and cystically dilated (c) tubules (Fig. 11 K & L).

The liver tissues of rats with Gal-induced HRS that were pretreated with Nebi (20 mg/kg/day) showed inflammatory cells infiltration (m) in between the degenerated hepatocytes (arrow) in addition to diffuse kupffer cells proliferation (arrow) in between the hepatocytes (Fig. 12 M & N).

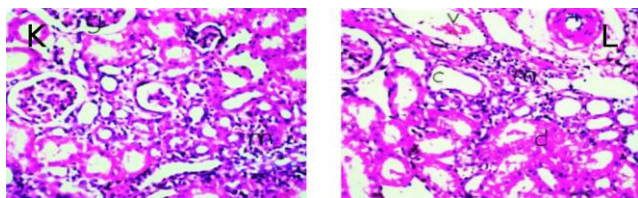


Figure 11: Photomicrographs of renal and liver sections from rats treated with the following: Nebi (20 mg) + Gal (K & L) the renal tissues show inflammatory cells infiltration (m) in between the tubules of the cortex and congestion in blood vessels (v) with focal inflammatory cells infiltration in between the degenerated (d) and cystically dilated (c) tubules. The liver tissues show inflammatory cells infiltration (m) in between the degenerated hepatocytes (arrow) (H & E X 40) in addition to diffuse kupffer cells proliferation (arrow) in between the hepatocytes (H & E X 80)

Discussion

A hepatorenal syndrome is a form of functional renal impairment due to debilitated renal blood flow, which happens typically in kidneys that are histologically normal, accompanied with severe complications of progressive liver disease and usually affects patients with cirrhosis and ascites [28].

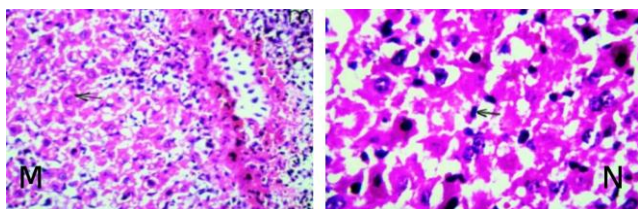


Figure 12: Photomicrographs of renal and liver sections from rats treated with the following: Nebi (20 mg) + Gal (M & N) the renal tissues show inflammatory cells infiltration (m) in between the tubules of the cortex and congestion in blood vessels (v) with focal inflammatory cells infiltration in between the degenerated (d) and cystically dilated (c) tubules. The liver tissues show inflammatory cells infiltration (m) in between the degenerated hepatocytes (arrow) (H & E X 40) in addition to diffuse kupffer cells proliferation (arrow) in between the hepatocytes (H & E X 80)

The current study revealed a significant increase in AST, ALT, NH₃ and TB serum levels in control positive HRS group compared with the normal one, an effect that was documented in earlier studies [7, 28, 29].

A significant increase in SCr, BUN and K⁺, as well as significant decrease in serum Na⁺ levels, were observed in control positive HRS group compared to the normal one. These findings are corroborated by previous studies [7, 28, 29]. The pathogenesis of the development of renal failure in this model corresponds with the mechanisms observed in typical HRS. It progresses from damage to the liver parenchyma to the development of portal hypertension, enlargement of the splanchnic vascular bed, reduction of the effective volume of fluid in the systemic circulation, and subsequent vascular baroreceptor stimulation, followed by activation of numerous vasoconstriction

factors, including the renin-angiotensin system, sympathetic nervous system, or arginine vasopressin system. These mechanisms lead to renal cortical vasoconstriction, renal hypoperfusion and renal failure [30].

In the present study, rats subjected to Gal provoked a significant elevation in serum ET-1 levels as compared with normal rats. This is by the outcomes of earlier studies [31-35]. Many factors may contribute to Gal-induced HRS. Patients who develop HRS, particularly in the context of acute liver failure or alcoholic hepatitis, have increased circulating concentrations of ET-1 [9].

In the present work, control positive HRS group depicted a significant increase in the renal and hepatic content of MDA, with a decrease in GSH contents. These results are in harmony with other studies [12, 36, 37]. Several mediators implicated in the pathogenesis of HRS are regulated through products of lipid peroxidation or redox changes in signalling pathways. Thus the development of oxidant stress may be important in the pathogenesis of HRS [38].

Moreover, Oxidative stress is markedly elevated in chronic liver disease and has gain attention as a potentially important factor in altered hemodynamics and renal dysfunction in cirrhosis. It induces renal vasoconstriction not only by quenching NO but also by increasing production of F₂-IPs and ET-1 in addition to damaging DNA and provoking apoptosis [12]. Markedly increased levels of both factors in patients with HRS in conjunction with increased systemic oxidative stress in cirrhosis raises the possibility of a pathogenetic role of oxidative stress in HRS [13].

In the current work, F₂-IPs contents in the liver and kidney were drastically boosted in the positive HRS group. This finding was by other studies [9, 39, 40]. The F₂-IPs are formed by lipid peroxidation. One of the major F₂-IPs formed in vivo, namely 8-iso-PGF₂. F₂-IPs synthesis is increased in patients with HRS and denotes increased lipid peroxidation [38]. Free-radical-generated F₂-IPs also stimulates DNA synthesis and the ET-1 expression on endothelial cells. F₂-IP is a highly potent renal vasoconstrictor that selectively increases pre-glomerular vascular resistance and leads to a reduction in the glomerular filtration rate [41].

Results of the current study illustrated that induction of HRS using Gal produced a substantial rise in the renal and hepatic contents of NF- κ B, TNF- α as well as Cas-3 activity as compared with normal animals. The present data are in agreement with previous studies [12, 15-17, 35, 42]. It has been well recognized that an up regulated inflammatory response is a key mechanism of Gal-induced acute hepatotoxicity. TNF- α is a pro-inflammatory cytokine secreted by liver kupffer cells as an inflammatory response [15]. TNF modulates the necrotic, apoptotic

and inflammatory pathways in Gal-induced hepatotoxicity by activating transcription factors as NF- κ B [43]. In respect of apoptosis, TNF- α combines with TNF- α receptor on the hepatocyte membrane activates caspase-3 and eventually induces apoptosis at an early stage through a series of signal transmission [16].

In the present study, rats subjected to Gal showed a significant elevation in the renal and hepatic contents of NO_x besides iNOS activity. These results are consistent with prior studies [29, 42, 44-46]. Previous findings have shown that NO, a potent vasodilator, plays an important role in the development of hyperdynamic syndrome and peripheral vasodilation during cirrhosis [3]. Increased NO level and synthetase activity in patients with liver cirrhosis have adverse effects on the functions of renal tubules and glomeruli whereas inhibition of NO synthetase prevents the development of renal failure in an animal model of HRS [47, 48]. NO produced by iNOS is reported to have aggravated liver and kidney injury, while eNOS expression preserved physiological functions [11].

Furthermore, in patients with cirrhosis; the imbalance between NO and vasoconstrictors such as ET-1 in the renal microcirculation has been proposed to be responsible for the deterioration of kidney function in these patients [10]. Additionally, endotoxemia up-regulates inducible forms of HO-1 and iNOS. Inducible NOS is primarily found in Kupffer cells and hepatocytes. Once activated, it can produce up to 1000 times more NO than eNOS. Inducible NOS-induced NO production is believed to play an important role in hepatocellular injury following endotoxemia and TNF- α stimulation [17].

Previous studies also revealed that the transcription factor NF κ B plays an important role in the induction of iNOS because an NF κ B binding site has been identified in the promoter region of the iNOS gene and that blocking NF κ B results in an attenuation of iNOS gene expression. Furthermore, ET-1 has been shown to activate NF κ B in human myofibroblastic hepatic stellate cells [17].

In the present investigation, hepatic HO-1 in addition to eNOS activities were elevated, nevertheless all at once renal HO-1 besides eNOS activities were declined in Gal treated rats as compared with the normal group. A similar pattern coincided with previous studies [14, 49-53].

Excessive oxidative stress has been suggested as a reason for hepatic HO-1 up-regulation, and this enzyme is known to be readily inducible by stressors [54]. On the other hand, previous studies denoted that decreased renal HO-1 expression plays an important role in the pathogenesis of experimental HRS [14].

HO-1 has constitutive and inducible isoforms [55, 56]. HO-1, a 32-kDa inducible protein [57],

catalyses the rate-limiting step in the oxidative degradation of heme to biliverdin, releasing equimolar amounts of CO and iron [55]. CO, a gaseous messenger similar to NO, mediates various physiological functions [58] including vasodilation [59]. HO-1 activity is the primary source of circulating CO [60], and HO-1 contributes to vasodilation mainly through HO-1-derived CO [61]. Thus, the declined HO-1 expression in the kidney may be responsible for a decrease in vasodilation. Also, oxidants can cause localised renal vasoconstriction [62]. Therefore, the antioxidant action of HO-1 and its products can preserve renal arterial blood flow. Decreased HO-1 expression in the kidney of Gal rats impairs their ability to buffer locally produced oxidants, thus leading to decreased renal arterial blood flow and deteriorated renal function. Additionally, eNOS expression follows a similar, tissue-specific pattern with HO-1 expression. Decreased eNOS and HO-1 expression in the kidneys, results in reduced amounts of NO and CO available resulting in renal vasoconstriction and reduced RBF occurring during cirrhosis [63]. Taken together, decreased HO-1 and eNOS expression in kidney plays an important role in the pathogenesis of experimental HRS [14].

Surprisingly, the HO-1 level was significantly higher in livers of Gal group, suggesting that there is more CO in the hepatic circulation [64]. It is possible that during cirrhosis the up-regulation of systemic CO resulting from increased HO-1 protein expression in the liver may also reduce HO-1 protein expression in the kidney due to a negative-feedback loop in an attempt to restore circulatory integrity [53].

Previous studies showed that over-expression of HO-1 could be harmful to the liver of rats with cirrhosis induced by bile duct ligation [14], which was also reported by [65]. In normal Sprague-Dawley (SD) rats, increased HO-1 activity as a pro-oxidant mechanism resulted in iron accumulation in the liver and increased portal pressure through hyperdynamic circulation and vasodilation; in contrast, decreased HO-1 activity reduced intracellular iron levels and oxidative stress besides reducing portal pressure and improving fibrosis [66].

HO-1 catalyses heme into iron and plays an important role in iron homeostasis. High levels of HO-1 could result in the accumulation of free divalent iron, thus increasing oxidative injury in fibroblast cell cultures [49]. Deposition of iron in the liver often triggers oxidative stress and inflammation and induces liver cell damage to membranes, proteins, and DNA [52].

Endothelial dysfunction is concomitant with changes in vascular structure associated with many forms of vascular diseases, such as portal hypertension, occurring in all forms of liver injury. This is associated with abnormal production of eNOS. eNOS is up regulated by various mechanisms; including phosphorylation, subcellular localisation, and

protein-protein interactions [67]. A large number of studies demonstrated that heat shock protein 90; a stress protein, interacting with eNOS plays a role in excessive NO production in the rat superior mesenteric artery [68].

Normal eNOS localisation is dramatically altered in endothelial cells of mesenteric arteries isolated from cirrhotic rats with portal hypertension. In those vessels, the Golgi localisation is lost, and eNOS diffuses within the cells and migrates more toward plasma membrane [69].

The severity of portal hypertension seems to be an important factor that influences eNOS activation in the splanchnic circulation. Initially, high portal pressure induces vasoconstriction in arterial splanchnic circulation due to a myogenic reflex caused by a sudden increase in portal pressure, which then causes phosphorylation and activation of eNOS through Akt/protein kinase B activation, ultimately leading to increase NO production and vasodilatation in the arteries of the splanchnic circulation [70].

In the current study, there was a significant histopathological alteration in the Gal- treated rats. The livers extensively displayed diffuse coagulative necrosis [35, 71]. In the same line, the kidneys revealed congestion in the blood vessels, glomeruli associated with perivascular oedema, inflammatory cells infiltration, degeneration in the lining epithelium of the tubules and focal haemorrhage in the corticomedullary portion due to the elevated level of ROS and the upshot of pro-inflammatory cytokines [42].

In the present study, animals treated with Nebi (10 & 20 mg/kg) exhibited a significant improvement in the liver above and renal function tests as compared with the diseased group. These findings are in agreement with previous studies using Nebi in different models of hepatotoxicity and nephrotoxicity [23, 72-74]. Nebi exerts NO-mediated vasodilation in the renal vasculature in addition to conventional beta-blocking effects. Published data indicate that higher doses of Nebi might increase β_2 receptor blocking activity which could be beneficial regarding decreasing splanchnic blood flow and portal hypertension [75] which was also proved by a previous study [76].

Current treatment with Nebi showed a remarkable drop in ET-1 levels as compared with Gal treated rats. Nebi reduced ET-1 levels in human pulmonary endothelial cells from pulmonary arterial hypertensive lungs [77] and during oxidative stress in human umbilical vein endothelial cells [20]. Moreover, Nebi can reduce ET-1 secretion in human coronary endothelial and smooth muscle cells [78]. Moreover, an in-vivo study demonstrated that Nebi suppresses ET-1-mediated vasoconstrictor tone in adults with elevated blood pressure [79].

Obtained data in the current study showed that animals treated with Nebi revealed an obvious enhancement in the oxidative stress markers in both kidney and liver. This is manifested by a significant decrease in renal and hepatic MDA, F₂-IPs contents in addition to a significant increase in the antioxidant pool of GSH contents. Recently, it was reported that Nebi showed marked amelioration of oxidative stress induced in different models of hepatic and renal injury [23, 72, 74, 80, 81]. Moreover, [82] et al. demonstrated that Nebi exerts systemic antioxidant effects through significantly decreasing the urinary excretion of the 8-iso-PGF₂ α (one of the major F₂-IPs). Nebi's antioxidant activity is due to a reduction of ROS produced by an NADPH oxidase system that makes an important contribution to oxidative stress by uncoupling eNOS [83]. Increased tissue levels of ROS diminish the bioactivity of NO by conversion of locally released NO to peroxynitrite (ONOO⁻), which itself contributes to tissue injury and oxidative stress [84]. Nebi reduces the NO-scavenging radical superoxide anion, by redirecting deranged NOS activity, from superoxide to NO production, thereby reducing lipid peroxidation and oxidative stress [85]. Also, increase in GSH may be ascribed to the observed increase in HO-1 expression as HO-1 mediates an increase in GSH levels [86] and modulates iNOS [87]. By decreasing oxidative stress, Nebi inhibits NF- κ B activation, which leads to the decrease of various pro-inflammatory cytokines [88].

In the present study, the effect of Nebi on renal and hepatic TNF- α contents is consistent with the results of [20] et al. who found that Nebi significantly reduced the oxidative stress-induced TNF- α gene expression in human umbilical vein endothelial cells. Furthermore, Nebi down-regulated TNF- α gene expression in human coronary artery smooth muscle cells [88]. On the other hand, Nebi decreased case-3 immuno-reactivity in cerebral ischemia/reperfusion in rats [89].

Surprisingly, the NO releaser, Nebi, in the present study reduced the hepatic and renal total NOx contents which increased with Gal administration. Likewise, hepatic and renal iNOS activities were significantly reduced in the presence of Nebi. This finding attracts attention that the source of such NOx increase occurred with Gal; it seems that the major spring of NOx is iNOS which was weakly expressed with Nebi treatment. Quantities of NO generated by eNOS is small while large amounts of NO are generated by iNOS [74]. It was reported that Nebi enhanced eNOS expression and reduced iNOS expression [90]. It is also known that sustained iNOS-mediated NO generation may mediate lipid peroxidation and pro-apoptotic effects [74].

Current treatment with Nebi markedly increased expression of renal eNOS and HO-1 activities as compared to HRS group which were weakly expressed with Gal toxicity. Decreased eNOS and HO-1 expression in the kidneys, resulted in

reduced amounts of NO and CO available resulting in renal vasoconstriction and reduced RBF occurring during HRS which was counteracted by Nebi. On the other hand, Nebi noticeably diminished hepatic eNOS and HO-1 activities which were strongly conveyed in Gal toxicity. Previous studies showed that over-expression of HO-1 could be harmful to the liver of rats with cirrhosis induced by bile duct ligation [14], which was also reported by [65]. In normal Sprague Dawley (SD) rats, increased HO-1 activity as a pro-oxidant mechanism resulted in iron accumulation in the liver and increased portal pressure through vasodilation; in contrast, decreased HO-1 activity reduced intracellular iron levels and oxidative stress besides reducing portal pressure and improving fibrosis [66]. Endothelial dysfunction is associated with many forms of vascular diseases, such as portal hypertension, occurring in all forms of liver injury. During endothelial dysfunction, hyperactive endothelial cells are observed in patients with portal hypertension. This is associated with abnormal production of an endothelial cell-derived eNOS [67]. All this consequence was reversed with Nebi treatment.

In this experiment, there was a significant histopathological improvement in the liver and kidney of the Nebi (both doses) treated HRS group showing little glomerular congestion and minute tubular degeneration with tubular cystic dilation in a corticomedullary portion in kidney and congestion in portal vein as well as bile duct hyperplasia in the liver due to the decreased level of ROS and the down-regulation of pro-inflammatory cytokines [91].

Finally, the present study has highlighted for the first time, the possible mechanisms responsible for Nebi mediated HRS improvement and its antioxidant action. These findings support its useful effect in the prevention of HRS in patients with advanced liver diseases or as an add-on medication with known anti-HRS therapy.

In conclusion, the present study revealed that treatment of rats with Nebi (10 or 20 mg/kg/day, p.o.) protected against renal and hepatic damage involved in Gal-induced HRS. The findings demonstrated the involvement of the anti-oxidant, anti-inflammatory, anti-apoptotic and NO-releasing properties of this drug and suggested its involvement in the renoprotective and hepatoprotective effect in Gal-induced HRS model?

References

1. Anand R, Harry D, Holt S, Milner P, Dashwood M, Goodier D et al. Endothelin is an important determinant of renal function in a rat model of acute liver and renal failure. *Gut*. 2002;50(1):111-17. <https://doi.org/10.1136/gut.50.1.111> PMID:11772977 PMCID:PMC1773076
2. Cardenas A. Hepatorenal syndrome: a dreaded complication of end-stage liver disease. *The American journal of gastroenterology*. 2005;100(2):460-7. <https://doi.org/10.1111/j.1572-0241.2005.40952.x> PMID:15667508
3. Martin P-Y, Ginès P, Schrier RW. Nitric oxide as a mediator of hemodynamic abnormalities and sodium and water retention in cirrhosis. *New England Journal of Medicine*. 1998;339(8):533-41. <https://doi.org/10.1056/NEJM199808203390807> PMID:9709047
4. Wadei HM, Mai ML, Ahsan N, Gonwa TA. Hepatorenal syndrome: pathophysiology and management. *Clinical journal of the American Society of Nephrology*. 2006;1(5):1066-79. <https://doi.org/10.2215/CJN.01340406> PMID:17699328
5. Moreau R, Lebrec D. Acute renal failure in patients with cirrhosis: perspectives in the age of MELD. *Hepatology*. 2003;37(2):233-43. <https://doi.org/10.1053/jhep.2003.50084> PMID:12540770
6. Keppler D, Lesch R, Reutter W, Decker K. Experimental hepatitis induced by D-galactosamine. *Experimental and molecular pathology*. 1968;9(2):279-90. [https://doi.org/10.1016/0014-4800\(68\)90042-7](https://doi.org/10.1016/0014-4800(68)90042-7)
7. Saracyn M, Patera J, Kocik J, Brytan M, Zdanowski R, Lubas A et al. Strain of experimental animals and modulation of nitric oxide pathway: their influence on development of renal failure in an experimental model of hepatorenal syndrome. *Arch Med Sci*. 2012;8(3):555-62. <https://doi.org/10.5114/aoms.2012.29281> PMID:22852015 PMCID:PMC3400905
8. Javle P, Yates J, Kynaston H, Parsons K, Jenkins S. Hepatosplanchnic haemodynamics and renal blood flow and function in rats with liver failure. *Gut*. 1998;43(2):272-79. <https://doi.org/10.1136/gut.43.2.272> PMID:10189857 PMCID:PMC1727229
9. Moore K, Wendon J, Frazer M, Karani J, Williams R, Badr K. Plasma endothelin immunoreactivity in liver disease and the hepatorenal syndrome. *New England Journal of Medicine*. 1992;327(25):1774-78. <https://doi.org/10.1056/NEJM199212173272502> PMID:1435931
10. Kayali Z, Herring J, Baron P, Franco E, Ojogho O, Smith J et al. Increased plasma nitric oxide, L- arginine, and arginase-1 in cirrhotic patients with progressive renal dysfunction. *J Gastroenterol Hepatol*. 2009;24(6):1030-7. <https://doi.org/10.1111/j.1440-1746.2008.05757.x> PMID:19226382
11. Alva N, Cruz D, Sanchez S, Valentin JM, Bermudez J, Carbonell T. Nitric oxide as a mediator of fructose 1,6-bisphosphate protection in galactosamine-induced hepatotoxicity in rats. *Nitric Oxide*. 2013;28:17-23. <https://doi.org/10.1016/j.niox.2012.09.004> PMID:23032643
12. Silveira KC, Viau CM, Colares JR, Saffi J, Marroni NP, Porawski M. Cirrhosis induces apoptosis in renal tissue through intracellular oxidative stress. *Arquivos de gastroenterologia*. 2015;52(1):65-71. <https://doi.org/10.1590/S0004-28032015000100014> PMID:26017086
13. Assimakopoulos SF, Gogos C, Labropoulou-Karatzas C. Could antioxidants be the "magic pill" for cirrhosis-related complications? A pathophysiological appraisal. *Med Hypotheses*. 2011;77(3):419-23. <https://doi.org/10.1016/j.mehy.2011.05.034> PMID:21703771
14. Guo SB, Duan ZJ, Li Q, Sun XY. Effect of heme oxygenase-1 on renal function in rats with liver cirrhosis. *World J Gastroenterol*. 2011;17(3):322-8. <https://doi.org/10.3748/wjg.v17.i3.322> PMID:21253390 PMCID:PMC3022291
15. Kang JW, Kim SJ, Kim HY, Cho SH, Kim KN, Lee SG et al. Protective effects of HV-P411 complex against D-galactosamine-induced hepatotoxicity in rats. *The American journal of Chinese medicine*. 2012;40(3):467-80. <https://doi.org/10.1142/S0192415X1250036X> PMID:22745064

16. Aristatile B, Al-Assaf AH, Pugalendi KV. Carvacrol suppresses the expression of inflammatory marker genes in D-galactosamine-hepatotoxic rats. *Asian Pac J Trop Med.* 2013;6(3):205-11. [https://doi.org/10.1016/S1995-7645\(13\)60024-3](https://doi.org/10.1016/S1995-7645(13)60024-3)
17. Keller S, Karaa A, Paxian M, Clemens MG, Zhang JX. Inhibition of endothelin-1-mediated up-regulation of iNOS by bosentan ameliorates endotoxin-induced liver injury in cirrhosis. *Shock.* 2006;25(3):306-13. <https://doi.org/10.1097/01.shk.0000196549.18258.6a> PMID:16552365
18. Bosch J, Berzigotti A, Garcia-Pagan JC, Abraldes JG. The management of portal hypertension: rational basis, available treatments and future options. *J Hepatol.* 2008;48 (Suppl 1):S68-92. <https://doi.org/10.1016/j.jhep.2008.01.021> PMID:18304681
19. Munzel T, Gori T. Nebivolol: the somewhat-different beta-adrenergic receptor blocker. *J Am Coll Cardiol.* 2009;54(16):1491-9. <https://doi.org/10.1016/j.jacc.2009.05.066> PMID:19815121
20. Garbin U, Fratta Pasini A, Stranieri C, Manfro S, Mozzini C, Boccioletti V et al. Effects of nebivolol on endothelial gene expression during oxidative stress in human umbilical vein endothelial cells. *Mediators of inflammation.* 2008;2008:367590. <https://doi.org/10.1155/2008/367590> PMID:18437228 PMID:PMC2323596
21. Fedulenkova LV. [Correction of portal hypertension and renal dysfunction with help of nebivolol and lizinopril in patients with hepatic cirrhosis]. *Eksp Klin Gastroenterol.* 2009; (5):130-7. PMID:20201315
22. Reiberger T, Payer BA, Schwabl P, Hayden H, Horvatis T, Jager B et al. Nebivolol treatment increases splanchnic blood flow and portal pressure in cirrhotic rats via modulation of nitric oxide signalling. *Liver Int.* 2013;33(4):561-8. <https://doi.org/10.1111/liv.12101> PMID:23331709
23. Atwa A, Hegazy R, Shaffie N, Yassin N, Kenawy S. Protective Effects of Vasodilatory Beta-blockers Carvedilol and Nebivolol against Glycerol Model of Rhabdomyolysis-Induced Acute Renal Failure in Rats. *Open Access Maced J Med Sci.* 2016;4(3):329-36. <https://doi.org/10.3889/oamjms.2016.082> PMID:27703551 PMID:PMC5042611
24. Ruiz-Larrea MB, Leal AM, Liza M, Lacort M, de Groot H. Antioxidant effects of estradiol and 2-hydroxyestradiol on iron-induced lipid peroxidation of rat liver microsomes. *Steroids.* 1994;59(6):383-8. [https://doi.org/10.1016/0039-128X\(94\)90006-X](https://doi.org/10.1016/0039-128X(94)90006-X)
25. Baud L, Ardaillou R. Involvement of reactive oxygen species in kidney damage. *Br Med Bull.* 1993;49(3):621-9. <https://doi.org/10.1093/oxfordjournals.bmb.a072635> PMID:8221027
26. Bancroft JD, Gamble M. Theory and practice of histological techniques: Elsevier Health Sciences, 2008.
27. Dunn OJ. Multiple Comparisons Using Rank Sums. *Technometrics.* 1964; 6(3):241-52. <https://doi.org/10.1080/00401706.1964.10490181>
28. Saracyn M, Zabkowski T, Zdanowski R, Brytan M, Patera J, Nowak Z et al. Effect of nitric oxide pathway regulation on water/sodium balance and renal function in a rodent model of acute liver and renal failure. *Med Sci Monit.* 2014;20:1735-44. <https://doi.org/10.12659/MSM.890757> PMID:25270512 PMID:PMC4186324
29. Saracyn M, Zdanowski R, Brytan M, Kade G, Nowak Z, Patera J et al. D-Galactosamine Intoxication in Experimental Animals: Is it Only an Experimental Model of Acute Liver Failure? *Med Sci Monit.* 2015;21:1469-77. <https://doi.org/10.12659/MSM.893291> PMID:26009004 PMID:PMC4451715
30. Javle P, Yates J, Kynaston HG, Parsons KF, Jenkins SA. Hepatosplanchnic haemodynamics and renal blood flow and function in rats with liver failure. *Gut.* 1998;43(2):272-9. <https://doi.org/10.1136/gut.43.2.272> PMID:10189857 PMID:PMC1727229
31. Anand R, Harry D, Holt S, Milner P, Dashwood M, Goodier D et al. Endothelin is an important determinant of renal function in a rat model of acute liver and renal failure. *Gut.* 2002;50(1):111-7. <https://doi.org/10.1136/gut.50.1.111> PMID:11772977 PMID:PMC1773076
32. Soper CP, Latif AB, Bending MR. Amelioration of hepatorenal syndrome with selective endothelin-A antagonist. *Lancet.* 1996; 347(9018):1842-3. [https://doi.org/10.1016/S0140-6736\(96\)91667-0](https://doi.org/10.1016/S0140-6736(96)91667-0)
33. Izzedine H, Kheder-Elfekih R, Deray G, Thabut D. Endothelin-receptor antagonist/N-acetylcysteine combination in type 1 hepatorenal syndrome. *J Hepatol.* 2009;50(5):1055-6. <https://doi.org/10.1016/j.jhep.2009.02.002> PMID:19328583
34. Moore K. Endothelin and vascular function in liver disease. *Gut.* 2004;53(2):159-61. <https://doi.org/10.1136/gut.2003.024703> PMID:14724140 PMID:PMC1774918
35. Wang JB, Wang HT, Li LP, Yan YC, Wang W, Liu JY et al. Development of a rat model of D-galactosamine/lipopolysaccharide induced hepatorenal syndrome. *World J Gastroenterol.* 2015; 21(34):9927-35. <https://doi.org/10.3748/wjg.v21.i34.9927> PMID:26379397 PMID:PMC4566385
36. Wang Y, Li Y, Xie J, Zhang Y, Wang J, Sun X et al. Protective effects of probiotic *Lactobacillus casei* Zhang against endotoxin- and d-galactosamine-induced liver injury in rats via anti-oxidative and anti-inflammatory capacities. *Int Immunopharmacol.* 2013; 15(1):30-7. <https://doi.org/10.1016/j.intimp.2012.10.026> PMID:23146349
37. Mahmoud MF, Zakaria S, Fahmy A. Can Chronic Nitric Oxide Inhibition Improve Liver and Renal Dysfunction in Bile Duct Ligated Rats? *Advances in pharmacological sciences.* 2015;2015:298792.
38. Morrow JD, Moore KP, Awad JA, Ravenscraft MD, Marini G, Badr KF et al. Marked overproduction of non-cyclooxygenase derived prostanoids (F2-isoprostanes) in the hepatorenal syndrome. *Journal of lipid mediators.* 1993;6(1-3):417-20. PMID:8358000
39. Moore K. Isoprostanes and the liver. *Chemistry and physics of lipids.* 2004;128(1-2):125-33. <https://doi.org/10.1016/j.chemphyslip.2003.10.003> PMID:15037158
40. Fukunaga M, Yura T, Badr KF. Stimulatory effect of 8-Epi-PGF2 alpha, an F2-isoprostane, on endothelin-1 release. *Journal of cardiovascular pharmacology.* 1994;26:S51-2.
41. Takahashi K, Nammour TM, Fukunaga M, Ebert J, Morrow JD, Roberts LJ, 2nd et al. Glomerular actions of a free radical-generated novel prostaglandin, 8-epi-prostaglandin F2 alpha, in the rat. Evidence for interaction with thromboxane A2 receptors. *J Clin Invest.* 1992;90(1):136-41. <https://doi.org/10.1172/JCI115826> PMID:1386085 PMID:PMC443072
42. Ghosh M, Das J, Sil PC. D(+) galactosamine induced oxidative and nitrosative stress-mediated renal damage in rats via NF-kappaB and inducible nitric oxide synthase (iNOS) pathways is ameliorated by a polyphenol xanthone, mangiferin. *Free Radic Res.* 2012;46(2):116-32. <https://doi.org/10.3109/10715762.2011.644240> PMID:22118634
43. Abe K, Ijiri M, Suzuki T, Taguchi K, Koyama Y, Isemura M. Green tea with a high catechin content suppresses inflammatory cytokine expression in the galactosamine-injured rat liver. *Biomedical research.* 2005;26(5):187-92. <https://doi.org/10.2220/biomedres.26.187> PMID:16295694
44. Mahmoud WA, Abdelkader NA, Mansour A. Could serum nitrate and nitrite levels possibly predict hepatorenal syndrome in hepatitis C virus-related liver cirrhosis? *Indian J Gastroenterol.* 2014;33(3):274-80. <https://doi.org/10.1007/s12664-013-0427-x>

PMid:24287875

45. Gomez-Hurtado I, Zapater P, Bellot P, Pascual S, Perez-Mateo M, Such J et al. Interleukin-10-mediated heme oxygenase 1-induced underlying mechanism in inflammatory down-regulation by norfloxacin in cirrhosis. *Hepatology*. 2011; 53(3):935-44. <https://doi.org/10.1002/hep.24102> PMID:21374664
46. Li TH, Lee PC, Lee KC, Hsieh YC, Tsai CY, Yang YY et al. Down-regulation of common NFkappaB- iNOS pathway by chronic Thalidomide treatment improves Hepatopulmonary Syndrome and Muscle Wasting in rats with Biliary Cirrhosis. *Sci Rep*. 2016; 6:39405.
47. Islas-Carbajal MC, Covarrubias A, Grijalva G, Alvarez-Rodriguez A, Armendariz-Borunda J, Rincon- Sanchez AR. Nitric oxide synthases inhibition results in renal failure improvement in cirrhotic rats. *Liver international: official journal of the International Association for the Study of the Liver*. 2005; 25(1):131-40. <https://doi.org/10.1111/j.1478-3231.2005.01018.x> PMID:15698410
48. Saracyn M, Wesolowski P, Nowak Z, Patera J, Kozlowski W, Wankowicz Z. [Role of nitric oxide system in pathogenesis of experimental model of hepatorenal syndrome]. *Polski merkuriusz lekarski: organ Polskiego Towarzystwa Lekarskiego*. 2008;24(142):293-7.
49. Wang QM, Du JL, Duan ZJ, Guo SB, Sun XY, Liu Z. Inhibiting heme oxygenase-1 attenuates rat liver fibrosis by removing iron accumulation. *World J Gastroenterol*. 2013;19(19):2921-34. <https://doi.org/10.3748/wjg.v19.i19.2921> PMID:23704825 PMCid:PMC3660817
50. Guo SB, Li Q, Duan ZJ, Wang QM, Zhou Q, Sun XY. Octreotide attenuates liver fibrosis by inhibiting hepatic heme oxygenase-1 expression. *Molecular medicine reports*. 2015;11(1):83-90. <https://doi.org/10.3892/mmr.2014.2735> PMID:25338529 PMCid:PMC4237075
51. Shafiei MS, Lui S, Rockey DC. Integrin-linked kinase regulates endothelial cell nitric oxide synthase expression in hepatic sinusoidal endothelial cells. *Liver Int*. 2015;35(4):1213-21. <https://doi.org/10.1111/liv.12606> PMID:24906011 PMCid:PMC4258191
52. Wang QM, Duan ZJ, Du JL, Guo SB, Sun XY, Liu Z. Heme oxygenase/carbon monoxide pathway inhibition plays a role in ameliorating fibrosis following splenectomy. *Int J Mol Med*. 2013;31(5):1186-94. <https://doi.org/10.3892/ijmm.2013.1309> PMID:23525258
53. Miyazono M, Garat C, Morris KG, Jr., Carter EP. Decreased renal heme oxygenase-1 expression contributes to decreased renal function during cirrhosis. *Am J Physiol Renal Physiol*. 2002;283(5):F1123-31. <https://doi.org/10.1152/ajprenal.00363.2001> PMID:12372789
54. Yun N, Eum HA, Lee SM. Protective role of heme oxygenase-1 against liver damage caused by hepatic ischemia and reperfusion in rats. *Antioxid Redox Signal*. 2010;13(10):1503-12. <https://doi.org/10.1089/ars.2009.2873> PMID:20446775
55. Christodoulides N, Durante W, Kroll MH, Schafer AI. Vascular smooth muscle cell heme oxygenases generate guanylyl cyclase-stimulatory carbon monoxide. *Circulation*. 1995;91(9):2306-09. <https://doi.org/10.1161/01.CIR.91.9.2306> PMID:7729015
56. Morita T, Perrella MA, Lee M-E, Kourembanas S. Smooth muscle cell-derived carbon monoxide is a regulator of vascular cGMP. *Proceedings of the National Academy of Sciences*. 1995;92(5):1475-79. <https://doi.org/10.1073/pnas.92.5.1475>
57. Verma A, Hirsch DJ, Glatt CE, Ronnett GV, Snyder SH. Carbon monoxide: a putative neural messenger. *Science-New York Then Washington*. 1993;259:381-81. <https://doi.org/10.1126/science.7678352>
58. Herve P, Lebre C, Brenot F, Simonneau G, Humbert M, Sitbon O et al. Pulmonary vascular disorders in portal hypertension. *European Respiratory Journal*. 1998;11(5):1153-66. <https://doi.org/10.1183/09031936.98.11051153> PMID:9648972
59. Chang S, Ohara N. Pulmonary circulatory dysfunction in rats with biliary cirrhosis. *Am Rev Respir Dis*. 1992;148:798-805. https://doi.org/10.1164/ajrccm/145.4_Pt_1.798 PMID:1554205
60. Naik JS, O'Donoghue TL, Walker BR. Endogenous carbon monoxide is an endothelial-derived vasodilator factor in the mesenteric circulation. *American Journal of Physiology-Heart and Circulatory Physiology*. 2003;284(3):H838-H45. <https://doi.org/10.1152/ajpheart.00747.2002> PMID:12446283
61. Carter EP, Hartsfield CL, Miyazono M, Jakkula M, Morris KG, McMurtry IF. Regulation of heme oxygenase-1 by nitric oxide during hepatopulmonary syndrome. *American Journal of Physiology-Lung Cellular and Molecular Physiology*. 2002;283(2):L346-L53. <https://doi.org/10.1152/ajplung.00385.2001> PMID:12114196
62. Bomzon A, Holt S, Moore K, editors. Bile acids, oxidative stress, and renal function in biliary obstruction. *Seminars in nephrology*, 1997.
63. Carter EP, Hartsfield CL, Miyazono M, Jakkula M, Morris KG, Jr., McMurtry IF. Regulation of heme oxygenase-1 by nitric oxide during hepatopulmonary syndrome. *Am J Physiol Lung Cell Mol Physiol*. 2002;283(2):L346-53. <https://doi.org/10.1152/ajplung.00385.2001> PMID:12114196
64. Rodriguez F, Kemp R, Balazy M, Nasjletti A. Effects of Exogenous Heme on Renal Function. *Hypertension*. 2003;42(4):680-84. <https://doi.org/10.1161/01.HYP.0000085785.40581.1A> PMID:12900432
65. Froh M, Conzelmann L, Walbrun P, Netter S, Wiest R, Wheeler MD et al. Heme oxygenase-1 overexpression increases liver injury after bile duct ligation in rats. *World J Gastroenterol*. 2007; 13(25):3478-86. <https://doi.org/10.3748/wjg.v13.i25.3478> PMID:17659695 PMCid:PMC4146784
66. Khan ZA, Barbin YP, Cukiernik M, Adams PC, Chakrabarti S. Heme-oxygenase-mediated iron accumulation in the liver. *Can J Physiol Pharmacol*. 2004;82(7):448-56. <https://doi.org/10.1139/y04-052> PMID:15389291
67. Sessa WC. eNOS at a glance. *J Cell Sci*. 2004;117(Pt 2):2427-9. <https://doi.org/10.1242/jcs.01165> PMID:15159447
68. Shah V, Wiest R, Garcia-Cardena G, Cadelina G, Groszmann RJ, Sessa WC. Hsp90 regulation of endothelial nitric oxide synthase contributes to vascular control in portal hypertension. *Am J Physiol*. 1999;277(2 Pt 1):G463-8. PMID:10444461
69. Sowa G, Liu J, Papapetropoulos A, Rex-Haffner M, Hughes TE, Sessa WC. Trafficking of endothelial nitric-oxide synthase in living cells. Quantitative evidence supporting the role of palmitoylation as a kinetic trapping mechanism limiting membrane diffusion. *J Biol Chem*. 1999;274(32):22524-31. <https://doi.org/10.1074/jbc.274.32.22524> PMID:10428829
70. Iwakiri Y, Tsai MH, McCabe TJ, Gratton JP, Fulton D, Groszmann RJ et al. Phosphorylation of eNOS initiates excessive NO production in early phases of portal hypertension. *Am J Physiol Heart Circ Physiol*. 2002;282(6):H2084-90. <https://doi.org/10.1152/ajpheart.00675.2001> PMID:12003815
71. Wang JB, Wang DL, Wang HT, Wang ZH, Wen Y, Sun CM et al. Tumor necrosis factor-alpha-induced reduction of glomerular filtration rate in rats with fulminant hepatic failure. *Lab Invest*. 2014;94(7):740-51. <https://doi.org/10.1038/labinvest.2014.71> PMID:24887412
72. Ulger BV, Erbis H, Turkcu G, Ekinci A, Turkoglu MA, Ekinci C et al. Nebivolol Ameliorates Hepatic Ischemia/Reperfusion Injury on Liver But Not on Distant Organs. *Journal of investigative surgery : the official journal of the Academy of Surgical Research*. 2015; 28(5):245-52.

- <https://doi.org/10.3109/08941939.2015.1031923> PMID:26305470
73. Teixeira C, Franco E, Oliveira PA, Colaco B, Gama A, Carrola J et al. Effects of nebivolol on liver fibrosis induced by bile duct ligation in Wistar rats. *In vivo*. 2013;27(5):635-40. PMID:23988899
74. Morsy MA, Heeba GH. Nebivolol Ameliorates Cisplatin-Induced Nephrotoxicity in Rats. *Basic & clinical pharmacology & toxicology*. 2016;118(6):449-55. <https://doi.org/10.1111/bcpt.12538> PMID:26617394
75. Bundkirchen A, Brixius K, Bolck B, Nguyen Q, Schwinger RH. Beta 1-adrenoceptor selectivity of nebivolol and bisoprolol. A comparison of [3H]CGP 12.177 and [125I]iodocyanopindolol binding studies. *Eur J Pharmacol*. 2003;460(1):19-26. [https://doi.org/10.1016/S0014-2999\(02\)02875-3](https://doi.org/10.1016/S0014-2999(02)02875-3)
76. Silkauskaitė V, Kupcinskas J, Pranculis A, Jonaitis L, Petrenkiene V, Kupcinskas L. Acute and 14-day hepatic venous pressure gradient response to carvedilol and nebivolol in patients with liver cirrhosis. *Medicina*. 2013; 49(11):467-73.
77. Perros F, Ranchoux B, Izikki M, Bentebbal S, Happe C, Antigny F et al. Nebivolol for improving endothelial dysfunction, pulmonary vascular remodeling, and right heart function in pulmonary hypertension. *J Am Coll Cardiol*. 2015;65(7):668-80. <https://doi.org/10.1016/j.jacc.2014.11.050> PMID:25677428
78. Brehm BR, Bertsch D, von Fallois J, Wolf SC. Beta-blockers of the third generation inhibit endothelin-1 liberation, mRNA production and proliferation of human coronary smooth muscle and endothelial cells. *J Cardiovasc Pharmacol*. 2000;36(5 Suppl 1):S401-3. <https://doi.org/10.1097/00005344-200036051-00117> PMID:11078433
79. Diehl KJ, Stauffer BL, Dow CA, Bammert TD, Brunjes DL, Greiner JJ et al. Chronic Nebivolol Treatment Suppresses Endothelin-1-Mediated Vasoconstrictor Tone in Adults With Elevated Blood Pressure. *Hypertension*. 2016;67(6):1196-204. <https://doi.org/10.1161/HYPERTENSIONAHA.115.06979> PMID:27113048 PMID:PMC4871319
80. Akgullu C, Huyut MA, Boyacioglu M, Gules O, Eryilmaz U, Hekim T et al. Nebivolol to attenuate the effects of hyperhomocysteinaemia in rats. *Atherosclerosis*. 2015 ;240(1):33-9. <https://doi.org/10.1016/j.atherosclerosis.2015.02.054> PMID:25746375
81. Rofaeil RR, Kamel MY, Abdelzاهر WY. Different effects of selective beta1-adrenoceptor antagonists, nebivolol or atenolol in acetaminophen-induced hepatotoxicity of rats. *Fundam Clin Pharmacol*. 2017; 31(2):165-73. <https://doi.org/10.1111/fcp.12253> PMID:27862262
82. Troost R, Schwedhelm E, Rojczyk S, Tsikas D, Frolich JC. Nebivolol decreases systemic oxidative stress in healthy volunteers. *British journal of clinical pharmacology*. 2000;50(4):377-9. <https://doi.org/10.1046/j.1365-2125.2000.00258.x> PMID:11012562 PMID:PMC2014994
83. Cominacini L, Fratta Pasini A, Garbin U, Nava C, Davoli A, Criscuoli M et al. Nebivolol and its 4-keto derivative increase nitric oxide in endothelial cells by reducing its oxidative inactivation. *J Am Coll Cardiol*. 2003;42(10):1838-44. <https://doi.org/10.1016/j.jacc.2003.06.011> PMID:14642697
84. Habibi J, Hayden MR, Sowers JR, Pulakat L, Tilmon RD, Manrique C et al. Nebivolol attenuates redox-sensitive glomerular and tubular mediated proteinuria in obese rats. *Endocrinology*. 2011;152(2):659-68. <https://doi.org/10.1210/en.2010-1038> PMID:21177830 PMID:PMC3037162
85. Ignarro LJ. Different pharmacological properties of two enantiomers in a unique beta-blocker, nebivolol. *Cardiovasc Ther*. 2008;26(2):115-34. <https://doi.org/10.1111/j.1527-3466.2008.00044.x> PMID:18485134
86. Li MH, Jang JH, Na HK, Cha YN, Surh YJ. Carbon monoxide produced by heme oxygenase-1 in response to nitrosative stress induces expression of glutamate-cysteine ligase in PC12 cells via activation of phosphatidylinositol 3-kinase and Nrf2 signaling. *J Biol Chem*. 2007;282(39):28577-86. <https://doi.org/10.1074/jbc.M701916200> PMID:17681938
87. Stevenson TH, Gutierrez AF, Alderton WK, Lian L, Scrutton NS. Kinetics of CO binding to the haem domain of murine inducible nitric oxide synthase: differential effects of haem domain ligands. *Biochem J*. 2001;358(Pt 1):201-8. <https://doi.org/10.1042/bj3580201> PMID:11485568 PMID:PMC1222048
88. Wolf SC, Sauter G, Jobst J, Kempf VA, Risler T, Brehm BR. Major differences in gene expression in human coronary smooth muscle cells after nebivolol or metoprolol treatment. *Int J Cardiol*. 2008;125(1):4-10. <https://doi.org/10.1016/j.ijcard.2007.02.045> PMID:17467819
89. Uzar E, Acar A, Evliyaoglu O, Firat U, Kamasak K, Gocmez C et al. The anti-oxidant and anti-apoptotic effects of nebivolol and zofenopril in a model of cerebral ischemia/reperfusion in rats. *Prog Neuropsychopharmacol Biol Psychiatry*. 2012;36(1):22-8. <https://doi.org/10.1016/j.pnpbp.2011.08.011> PMID:21888941
90. Heeba GH, El-Hanafy AA. Nebivolol regulates eNOS and iNOS expressions and alleviates oxidative stress in cerebral ischemia/reperfusion injury in rats. *Life Sci*. 2012;90(11-12):388-95. <https://doi.org/10.1016/j.lfs.2011.12.001> PMID:22226906
91. Moningka NC, Tsarova T, Sasser JM, Baylis C. Protective actions of nebivolol on chronic nitric oxide synthase inhibition-induced hypertension and chronic kidney disease in the rat: a comparison with angiotensin II receptor blockade. *Nephrol Dial Transplant*. 2012;27(3):913-20. <https://doi.org/10.1093/ndt/gfr449> PMID:21856762 PMID:PMC3289897