

Liposuction Assisted Lipoma Removal – Option or Alternative?

Igor Peev^{1*}, Lijana Spasevska², Elizabeta Mirchevska¹, Smilja Tudzarova-Gjorgova¹

¹University Clinic for Plastic and Reconstructive Surgery, Medical Faculty, Ss Cyril and Methodius University of Skopje, Skopje, Republic of Macedonia; ²Institute of Pathology, Medical Faculty, Ss Cyril and Methodius University of Skopje, Skopje, Republic of Macedonia

Abstract

Citation: Peev I, Spasevska L, Mirchevska E, Tudzarova-Gjorgova S. Liposuction Assisted Lipoma Removal – Option or Alternative? Open Access Maced J Med Sci. <https://doi.org/10.3889/oamjms.2017.186>

Keywords: Lipoma; Liposuction; Lipoma removal; Plastic surgery; Suction assisted lipectomy.

***Correspondence:** Igor Peev, Medical Faculty, University Clinic for Plastic and Reconstructive Surgery, Skopje, Republic of Macedonia. E-mail: peevigor@yahoo.com

Received: 07-Sep-2017; **Revised:** 20-Sep-2017; **Accepted:** 21-Sep-2017; **Online first:** 14-Oct-2017

Copyright: © 2017 Igor Peev, Lijana Spasevska, Elizabeta Mirchevska, Smilja Tudzarova-Gjorgova. This is an open-access article distributed under the terms of the Creative Commons Attribution-NonCommercial 4.0 International License (CC BY-NC 4.0).

Funding: This research did not receive any financial support.

Competing Interests: The authors have declared that no competing interests exist.

BACKGROUND: Lipomas are the most frequent soft -tissue tumors arising from adipose tissue. Traditionally, open surgery is a mainstay of their treatment. Recently, new treatment modalities emerge in order to decrease morbidity, to increase satisfaction rate in patients, but not to raise recurrence risk at the same time.

AIM: The aim of this article is to present our experience with liposuction assisted lipoma removal in terms of efficacy, complications, risk of recurrence and patient satisfaction.

METHODS: The study was prospective in which treated lipomas with vacuum suction were analyzed. Preoperative diagnosis comprised clinical exam and additional diagnostic tools as to rule out malignancy. Subcutaneous lipomas with diameter of at least 5 cm were taken into account. Tumescence liposuction technique with modification was used.

RESULTS: Lipoma's size, distribution and demographics are given. Total removal with affordable rate of complication was achieved in each case. No recurrences in 12 months follow-up period were seen. Satisfaction rate in patients was high.

CONCLUSION: Liposuction assisted lipoma removal is a good alternative to open approach lipectomy and we would recommend its use in selected cases where, it might be more advantageous. However, prospective randomized controlled studies are needed in order to estimate its accurate clinical value.

Introduction

Lipomas are well-defined encapsulated benign tumors arising from adipose tissue comprising the most common mesenchymal tumors in human body [1]. Fat cells are main constituents, but depending on other tissue specimens incorporated, different pathomorphology can be seen. However, the majority of all clinical lipomas are called simple (or conventional) lipomas consisted purely of adipocytes originating from white fatty tissue arranged within fibrovascular stroma [2]. Clinically they are soft circumscribed lesions, occurring everywhere in the body, but mainly subcutaneously on the trunk or extremities [3]. Due to aesthetic disfigurement, discomfort, nerve pressure or cancerophobia, patients seek their removal [4].

Historically, open surgical ablation was the

mainstay of their treatment, burdened with scarring and risk of complications. Striving for less scarring, based on accessibility of subcutaneously located simple lipomas, new methods of less invasive treatments have been innovated in last decades [5-9]. Among them, liposuction, as the only FDA approved alternative, receives greatest credits [10]. Soon after its introduction as a tool for aesthetic body contouring, it gained popularity for treatment of other non – cosmetic conditions [11, 12]. Rubenstein et al. were first that used liposuction in lipoma treatment in 1985. [9] The efficacy of liposuction in lipoma removal was arguable at the beginning, with some early reports being positive [12-14] and other not [15].

The aim of this article is to present our first experience with liposuction assisted lipoma removal in terms of efficacy, complications, risk of recurrence and satisfaction in patients with postoperative follow-up of at least 12 months.

Material and Methods

This is a prospective cohort study comprising the patients with lipomas treated with liposuction in the period from September 2013 to July 2016 operated by a same surgeon (the author). All cases were operated at the University Clinic for Plastic and Reconstructive surgery in Skopje where, so far, open extirpation is a standard care treatment for lipoma of any kind. The cohort includes all the patients operated by the author with a minimum follow up of 1 year. Inclusion criteria for utilizing the new method were patients with simple lipoma of the trunk and extremities located above the fascia with diameter at least 5cm in adult patients (18 + years old). Fine - needle aspiration biopsy (FNAB) and ultrasound image with linear probe was conducted in order to exclude any non-lipomatous formations. Occasionally, MRI was utilized in cases where ultrasound was not conclusive. Cases with results stating lipoma were taken into an account (1st classification group only and clear imaging for lipoma). The new technique was offered to patients with fulfilled aforementioned criteria. After discussing about the advantages and disadvantages of the two methods, the alternative was accepted in studied cases. Patients with positive inclusion criteria that rejected the proposed new method were operated traditionally (open approach) and are not part of this cohort. The same with cases with unclear imaging for lipoma and/or result of FNAB other than 1st classification group. Study has permission from Ethics' Committee from the Medical Faculty and consent form was signed by all participants. Descriptive statistics are used.

Operative technique: Surgery is conducted in local anesthesia solely or in combination with intravenous sedation by the same surgeon (the author). Around an hour before operation, broad spectrum antibiotic is given i.v. or i.m. as a single shot. Liposuction is done using manually created vacuum with 60ml Toomey syringe after infiltration with modified Klein solution (0.1% lidocaine + 1:1m adrenaline in 1000ml 0.9% NaCl solution) by means of tumescent "suprawet" technique. It follows classical recommendations for liposuction regarding infiltration, waiting period, suction and respective end points. A \emptyset 1mm blunt infiltration cannula and blunt Mercedes \emptyset 3mm/ \emptyset 5mm cannula (Byron®) are used in addition to standard operative tray. Lipoma margins are marked prior infiltration and an entry port as incision is chosen, usually at the most cosmetically acceptable place about 2-5 cm away from margin. Local anesthesia is given at the port (about 2 ml of 1% lidocaine + 0.01% adrenaline). After finishing liposuction, through the same port, all the remaining hard tissue from the cavity are pulled out employing long forceps or paeen. Two tissue samples are sent for pathohistological analysis: the solid tissue from the aspirate (after decantation and filtration on gauze) and

the residual tissue that is taken away with the forceps at the end. All samples are examined by the same senior pathologist at the Institute for Pathology in Skopje (co-author).

The incision is sutured and a compressive dressing follows. Few hours later, the patient is discharged with an advice for a moderate reduction in daily activities and using analgetics if needed. First check-up is on the third postoperative day. Next check-ups are scheduled depending on further requirements. Wearing a compressive garment or bandage for 3 weeks is advisable. In this period, up to one month, early postoperative complications are evaluated as well as the wound/scar. In the late follow-up period of up to one year and more, the quality of the scar and the liposuctioned surface is assessed. More after, in this period, special attention is paid to any eventual recurrences. If any, this should be further investigated and re-operated by means of traditional open excision. Finally, overall patient satisfaction of the treatment is questioned at the end of 12th month or later, using 1 to 5 rating semi quantitative scale questionnaires. The question is: How you will rate the overall satisfaction of the surgery? (Give marks from 1 to 5, 1 being the worst)

Results

In total, 23 lipomas were operated with this technique. In one patient (case Z.A), there were two lipomas that were treated in the same act. Out of 22 patients, 15 were females (68%), 7 males (32%), aged from 32 to 74 (average age 56). In all cases, lipomas were diagnosed according to proposed pathway: clinically, imaging techniques and FNAB. MRI was employed only in one case where ultrasound couldn't exclude intramuscular lipoma propagation. Sizes and localizations of lipomas are given in the Table 1. The largest lipoma had dimension 14x26cm. Average size is 9x12cm (first number reflects the smallest dimension and second the largest). The most common localization is back dorsal region (30%). Five lipomas were located on extremities (22%), 17 on trunk (74%) and 1 in posterior neck region.

In early postoperative period, edema and ecchymosis was usual finding that resolved by itself uneventfully. In two cases (8.7%, cases T.T, I.G), there was need of aspiration helping to resolve seroma formation. Obviously these were large lipomas. There was no hematomas, infections, nor problems with wound healing. Pain was light to moderate not affecting daily activities. Wearing the compressive dressing/garments for at least three weeks was unpleasant for some patients, especially when nuchal lipomas were treated. In all cases total lipoma removal was achieved.

Table 1: Demographics, sizes and locations of lipomas

Patient	Sex	Year of birth	Dimension	Localisation
M.M	F	1967	7x10 cm	omaris l. dex.
L.J.	M	1955	10x10 cm	nuchae
A.J.	F	1982	5x13 cm	thoracis lateralis sin.
C.K.	F	1972	7x9 cm	dorsi
I.G.	M	1973	13x20 cm	parietis abdominis ant.l.sin.
T.T.	M	1953	14x26 cm	thoracis lateralis dex.
S.Z.	F	1965	7x7 cm	omaris l. sin
Z.A.	M	1959	7x7 cm, 8x9 cm	parietis abdominis ant. et thoracis ant.
S.A.	M	1958	8x10 cm	femoris dex
V.V.	F	1980	8x10 cm	scapularis sin.
M.Z.	F	1945	10x14 cm	omaris l.sin
N.D.	F	1943	6x8 cm	scapularis dex.
S.J.	F	1949	9x11 cm	dorsi proximalis
J.N.	M	1947	10x13 cm	omaris l.dex.
V.M.	F	1962	6x9 cm	dorsi
Lj.D.	F	1955	10x10 cm	dorsi
B.N.	F	1962	8x12 cm	dorsi
F.B.	F	1952	9x12 cm	dorsi proximalis
M.S.	F	1942	13x17 cm	brachii l.dex.
M.A.	F	1954	14x20 cm	lumbalis l.sin.
O.S.	M	1963	9x10 cm	dorsi
C.S.	F	1955	5x7 cm	parietis abdominis anterior

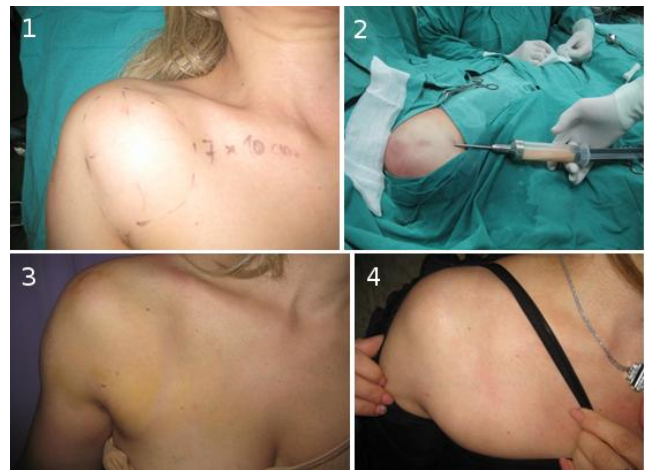


Figure 1: Preoperative photo documentation (1), intraoperative, liposuction of the lipoma (2), early postoperative finding (3) and late postoperative result in the same patient (4)

Ongoing follow up period is beyond 12 (from 12 to 46 months); 25 months being an average. All cases are still subject of further checkups. In this late postoperative period, there was 0 recurrences so far. Scar diminished by time and it was almost unnoticeable. In three cases, with large lipoma again, (13%, cases I.G., J.N, M.S) skin irregularities were present. Indentations were seen in two cases (8.7%, cases M.S., M.Z). None of that was a concern by a patient. Satisfaction rate at 12th month was high, with an average rate of 4.8. In all cases, the result of the patohistological analysis of the both specimens (aspirate and residual tissue) was an ordinary, conventional lipoma.

Results are summarized in Table 2.

Table 2: Summarized results

Patient	Follow up period (months)	Early complication	Late complication	Satisfaction mark
M.M	46	/	/	5
L.J.	44	/	/	5
A.J.	42	/	/	5
C.K.	40	/	/	5
I.G.	40	Seroma	skin irregularity	4
T.T.	37	Seroma	/	5
S.Z.	32	/	/	5
Z.A.	32	/	/	5
S.A.	27	/	/	5
V.V.	25	/	/	5
M.Z.	21	/	indentation	5
N.D.	20	/	/	4
S.J.	19	/	/	5
J.N.	18	/	skin irregularity	4
V.M.	18	/	/	5
Lj.D.	18	/	/	5
B.N.	16	/	/	5
F.B.	15	/	/	5
M.S.	15	/	skin irregularity indentation	3
M.A.	14	/	/	5
O.S.	13	/	/	5
C.S.	12	/	/	5

Zero recurrences

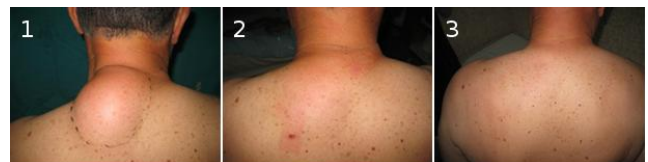

Figure 2: Preoperative (1), early postoperative (2) and late postoperative findings (3) at the same patient with lipoma on the upper dorsal region treated with liposuction

Photo documentation of two cases is shown in Figure 1 and 2.

On the other hand, it is highly safe procedure. [26] In our opinion, great indication for liposuction is suprafascial lipomatous masses, uni- or multilateral with moderate to large size where diagnosis is well established. However, there are reports for removing smaller lipomas in areas where scar is to be avoided [19]. Our cohort includes cases of subcutaneous lipoma with 5+ cm diameter where utilizing liposuction seems reasonable. Unless remote scar is wanted, we

think that smaller lipomas can be easily removed via small incisions and squeezing technique thus unnecessarily employing liposuction.

Several drawbacks have an impact on broader use of liposuction in lipoma treatment world widely. The need for special instrumentation is one of them. Others are tissue fragmentation and possible higher recurrence risk due to the closed approach [19]

The main concern with tissue fragmentation deals with accurate pathology analysis of the sample that has much with the fear of malignancies. Several studies have demonstrated that cell integrity in lipoaspirate is not damaged thus adequate pathohistology can be done accordingly [27, 28]. Moreover, in order to exclude malignancy, preoperative diagnosis of lipoma is mandatory and sufficient data must be collected prior any liposuction. One should always bear in mind that atypical lipomas or liposarcoma might have similar appearances [29]. Therefore, fine needle aspiration biopsy and ultrasound imaging should be the minimal supplement [18]. In doubtful cases, MRI should be added, especially when tumor growth is sudden or painful, size larger than 10 cm, localization atypical. It is a highly sensitive and specific imaging technique for soft tissue tumors [29, 30]. Furthermore it determines the localization and eventual intramuscular propagation. In highly suspicious cases, open biopsy should be done finally, in order to exclude liposarcoma of any type [29]. Liposarcoma treatment differs and its liposuction is extremely unpleasant scenario [31]. Having in mind the above, with accurate preoperative diagnosis and further validation with lipoaspirate pathohistology, misdiagnosis can be annulated. We have used ultrasound with linear probe in all cases as well as FNAB prior treatment. Only in one case, MRI had to be done in order to exclude intramuscular propagation. The pathologist had no difficulties with tissue samples and all results showed simple lipomas and their prospective capsule.

The higher possible recurrence risk in lipoma treated with liposuction compared to traditional removal is a conclusion deducted by observation or small studies. As a closed method of removal with limited visualization, this statement might be true for liposuction due to contingent incomplete removal of lipomatous or capsular/hard residual tissue [25]. However, it seems that the deduction is premature. Recurrence risk in open lipectomy is around 2% [29]. All studies published in the literature about suction assisted lipectomy have limited number of cases that can estimate that risk of 2% or less [25]. Up to date, there is only one small comparative study with 30 cases included, reporting unacceptable higher recurrence risk in liposuction treated cases [15]. Still, this study included giant lipomas only and is one of the oldest that might have implication on technical skills at that time. Apesos reported no recurrence in 4 patients with moderate and large lipoma treated with

suction within a follow up period of 3 years [20]. In the prospective study of Wilhelmi et al., no recurrence have been seen in a follow - up of 1-10 years in 5 cases [19]. Case reports for suction- treated giant lipomas showed no recurrence in a follow up of 2 years [22, 23]. Recent studies advocate the effectiveness. Al-Basty and El-Khatib [21], after the liposuction advice capsule extirpation with forceps through the same incision or through counter incision if lipoma is larger. Adding this modification, no recurrence has been seen in 16 patients in a long term follow- up of 6 years. Choi et al., used the same modification and had zero recurrence in 12 patients followed-up for a period of 2 years [18]. The largest and most recent published study has also applied the proposed modification and reports no recurrence in 44 treated lipomas (in 23 patients) for a period of mean follow up of 6 years [25]. Extraction of the capsule/hard residual tissue looks reasonable as it might have lipomatous precursors that can lead to future lipoma recurrence if untreated [32]. Adding the modification means radical ablation which decreases or annuls recurrence risk. We had used the modification in most of the cases. Our observations show that in some lipomas, especially ones with shorter history or location other than dorsal region, the hard residual tissue/capsule can be suctioned or mechanically destroyed.

There is no study in the literature about complication of suction treated lipoma, thus we cannot compare our results. If liposuction as a technique is taken into account, then we can say that the rates are acceptable [33]. All the complications are minor (local) and no major (systemic) complications were advocated. There was no need of further treatments. However, the study has limitations concerning small number of participants and its uncontrolled design.

In conclusion we can say that in properly selected cases of lipoma, that are sufficiently preoperatively examined with adequate operative technique used, liposuction - assisted lipectomy may have an advantage over the classical open technique, which vast majority, still, assumes it as golden standard. It counts especially in patients where larger scar is an issue. Nevertheless, larger randomized prospective studies are needed to evaluate precisely its clinical value.

References

1. Plötz S. et al. Häufige Hauttumoren in der Praxis. Berlin Heidelberg: Springer-Verlag, 2012:38. <https://doi.org/10.1007/978-3-642-24702-6>
2. Shiffman AM. Lipomatous Disorders: Classification and Review of the Literature. J Cosm Surg Med. 2005; 5(3) : 26-36.
3. Koh HK, Bhawan J. Tumors of the skin. In: Moschella SL, Hurley HJ, eds. Dermatology. 3d ed. Philadelphia: Saunders,1992:1721–1808.

4. Hodl S. Regionale und spezielle Erkrankungen des Fettgewebes. In: Braun-Falco O, Plewig G, Wolff HH, Burgdorf WHC, Landthaler M. *Dermatologie und Venerologie*. 2005;5:1021-23. PMID:PMC548971
5. Goldman A, Wollina U. Lipoma treatment with a subdermal Nd:YAG laser technique. *Int J Dermatol*. 2009; 48(11):1228-32. <https://doi.org/10.1111/j.1365-4632.2008.04007.x> PMID:20064183
6. Lee SH, Jung JY, Roh MR, Chung KY. Treatment of Lipomas using a Subdermal 1,444-nm Micropulsed Neodymiumdoped Yttrium Aluminum Garnet Laser. *Dermatolog Surg*. 2011; 37(9): 1375–1376. <https://doi.org/10.1111/j.1524-4725.2011.02084.x> PMID:22988996
7. Rotunda AM, Ablon G, Kolodney MS. Lipomas Treated with Subcutaneous Deoxycholate Injections. *J Am Acad Dermatol*. 2005;53: 973–978. <https://doi.org/10.1016/j.jaad.2005.07.068> PMID:16310057
8. Hallock GG. Endoscope-Assisted Suction Extraction of Lipomas. *Ann Plast Surg*. 1995; 34(1):32–34. <https://doi.org/10.1097/0000637-199501000-00007> PMID:7702298
9. Rubenstein R, Roenigk H, Garden JM, Goldberg NS, Pinski JB. Liposuction for lipomas. *J Dermatol Surg Oncol*. 1985; 11(11):1070–1074. <https://doi.org/10.1111/j.1524-4725.1985.tb01395.x> PMID:4056191
10. Boyer M. et al. A review of techniques and procedures for lipoma treatment. *Clinic Dermatol*. 2015; 3(4): 105–112. <https://doi.org/10.11138/cderm/2015.3.4.105>
11. El-Khatib HA. Liposuction for chronic medical diseases and noncosmetic conditions: review of the literature. *Plast Aesthet Res*. 2015;2:1-6. <https://doi.org/10.4103/2347-9264.149362>
12. Coleman WP3rd. Noncosmetic applications of liposuction. *J Dermatol Surg Oncol*. 1988;14(10):1085–1090. <https://doi.org/10.1111/j.1524-4725.1988.tb03465.x>
13. Spinowitz AL. Liposuction surgery: an effective alternative for treatment of lipomas. *Plast Reconstr Surg*. 1990; 86(3): 606 – 609. <https://doi.org/10.1097/00006534-199009000-00059> PMID:2385686
14. Pinski KS, Roenigk HH Jr. Liposuction of lipomas. *Dermatol Clin*. 1990; 8(3):483-92. PMID:2199109
15. Raemdonck D, De Mey A, Goldsemidt D. The treatment of giant lipomas. *Acta Chir Belg*. 1992; 92:213. PMID:1414141
16. Kryger ZB. Liposuction. In: Kryger ZB,Sisco M. *Practical Plastic Surgery*. Austin,TX Landes Bioscience, 2009:430.
17. Flynn TC. The history of liposuction. In:Shiffman MA, Di Giuseppe A. *Liposuction: Principles and Practice*. Springer-Verlag Berlin Heidelberg New York, 2006: 3-6. https://doi.org/10.1007/3-540-28043-X_1
18. Choi CW, Kim BJ, Moon SE et al. Treatment of lipomas assisted with tumescent liposuction. *J Eur Acad Dermatol Venerol*. 2007; 21: 243–246. <https://doi.org/10.1111/j.1468-3083.2006.02037.x> PMID:17243961
19. Wilhelmi BJ, Blackwell SJ, Mancoll JS, Phillips LG. Another indication for liposuction: small facial lipomas. *Plast Reconstr Surg*. 1999; 103(7):1864-7. <https://doi.org/10.1097/00006534-199906000-00008> PMID:10359246
20. Apesos J, Chami R. Functional applications of suction-assisted lipectomy: A new treatment for old disorders. *Aest Plast Surg*. 1991; 15(1): 73-79. <https://doi.org/10.1007/BF02273837>
21. Al-basti HA, El-Khatib HA. The use of suction-assisted surgical extraction of moderate and large lipomas: long-term follow-up. *Aest Plast Surg*. 2002; 26(2):114-7. <https://doi.org/10.1007/s00266-002-1492-1> PMID:12016495
22. Ilhan H, Tokar B. Liposuction of a pediatric giant superficial lipoma *J Pediatr Surg*. 2002.;37(5):796-8. <https://doi.org/10.1053/jpsu.2002.32291> PMID:11987105
23. Nichter LS, Gupta BR. Liposuction of giant lipoma. *Ann Plast Surg*. 1990; 24:362. <https://doi.org/10.1097/0000637-199004000-00011>
24. Calhoun KH, Bradfield JJ, Thompson C. Liposuction assisted excision of cervicofacial lipomas. *Otolaryngol Head Neck Surg*. 1995; 113(4): 401–403. [https://doi.org/10.1016/S0194-5998\(95\)70075-7](https://doi.org/10.1016/S0194-5998(95)70075-7)
25. Copeland-Halperin LR, Pimpinella V, Copeland M. Combined liposuction and excision of lipomas: long-term evaluation of a large sample of patients. *Plastic Surgery International*. 2015; 2015.
26. Housman TS, Lawrence N, Mellen BG et al.The safety of liposuction: results of a national survey. *Dermatol Surg*. 2002;28: 971–978. <https://doi.org/10.1097/00042728-200211000-00001>
27. Campbell GLM, Laudenslager N, Newman J. The effect of mechanical stress on adipocyte morphology and metabolism. *Am J Cosm Surg*. 1987; 4: 89–94. <https://doi.org/10.1177/074880688700400202>
28. Shiffman MA, Mirrafati S. Fat transfer techniques: the effect of harvest and transfer methods on adipocyte viability and review of the literature. *Dermatol Surg*. 2001; 27(9):819–826. <https://doi.org/10.1097/00042728-200109000-00008>
29. Dalal KM, Antonescu CR, Singer S. Diagnosis and management of lipomatous tumors. *J Surg Oncol*. 2008; 97:298-313. <https://doi.org/10.1002/jso.20975> PMID:18286473
30. Gaskin CM, Helms CA. Lipomas, Lipoma Variants, and Well-Differentiated Liposarcomas (Atypical Lipomas): Results of MRI Evaluations of 126 Consecutive Fatty Masses. *AJR*. 2004;182:733–739. <https://doi.org/10.2214/ajr.182.3.1820733> PMID:14975977
31. Voulliaume D, Vasseur C, Delaporte T, Delay E. An unusual risk of liposuction: liposuction of a malignant tumor. About 2 patients [Article in French] *Ann Chir Plast Esthet*. 2003;48(3):187-193. [https://doi.org/10.1016/S0294-1260\(03\)00043-8](https://doi.org/10.1016/S0294-1260(03)00043-8)
32. Suga H, Eto H, Inoue K, et al. Cellular and molecular features of lipoma tissue: comparison with normal adipose tissue. *Br J Dermatol*. 2009;161: 819–825. <https://doi.org/10.1111/j.1365-2133.2009.09272.x> PMID:19558598
33. Dixit VV, Wagh MS. Unfavorable outcomes of liposuction and their treatment. *Indian J Plast Surg*. 2013; 46(2): 377-792. <https://doi.org/10.4103/0970-0358.118617> PMID:24501474 PMID:PMC3901919