

Endoscopic Removal of a Giant Complicated Hyperplastic Gastric Polyp

Zaim Gashi¹, Aida Ferri Polloshka¹, Arber Veliu¹, Fisnik Kurshumliu², Elton Bahtiri^{3,4*}

¹Clinic of Gastroenterology, University Clinical Center of Kosovo, Prishtina, Kosovo; ²Institute of Pathology, University Clinical Center of Kosovo, Prishtina, Kosovo; ³Department of Pharmacology, Faculty of Medicine, University of Prishtina, Prishtina, Kosovo; ⁴Clinic of Endocrinology, University Clinical Center of Kosovo, Prishtina, Kosovo

Abstract

Citation: Gashi Z, Ferri Polloshka A, Veliu A, Kurshumliu F, Bahtiri E, Z. Endoscopic Removal of a Giant Complicated Hyperplastic Gastric Polyp. Open Access Maced J Med Sci. <https://doi.org/10.3889/oamjms.2017.188>

Keywords: Hyperplastic polyps; Endoscopic removal; Histological examination.

***Correspondence:** Elton Bahtiri, Department of Pharmacology, Faculty of Medicine, University of Prishtina, Republic of Kosovo. Telephone: +377 44 218 692; Email: elton.bahtiri@uni-pr.edu

Received: 17-Jun-2017; **Revised:** 20-Sep-2017; **Accepted:** 29-Sep-2017; **Online first:** 16-Oct-2017

Copyright: © 2017 Zaim Gashi, Aida Ferri Polloshka, Arber Veliu, Fisnik Kurshumliu, Elton Bahtiri. This is an open-access article distributed under the terms of the Creative Commons Attribution-NonCommercial 4.0 International License (CC BY-NC 4.0).

Funding: This research did not receive any financial support.

Competing Interests: The authors have declared that no competing interests exist.

The patient, a 40-year-old male, was referred to our clinic with intermittent nausea, vomiting and symptomatic anemia for 4 months. Notable hematological indices were low hemoglobin levels of 9.6 g/dl and hematocrit levels of 35.8%, while after receiving two units of concentrated red blood cells, at discharge; they achieved levels of 15.2 g/dl and 42.3%, respectively. Esophagogastroduodenoscopy revealed a 3 cm antral pedunculated polyp, prolapsing into pylorus thus causing intermittent pyloric obstruction and anemia. Histological examination revealed a hyperplastic polyp without evidences of malignancy. No atrophy, metaplasia, dysplastic changes or *Helicobacter pylori* infection were detected in samples taken from the antrum and the corpus; however, the examination provided evidence for gastritis. Follow-up endoscopy was provided after 12 weeks to see polypectomy site after a course of Pantoprazole administration, and to define symptom-free time after polypectomy. Endoscopic removal of complicated gastric polyps should be considered at the time of initial diagnostic endoscopy. Endoscopic resection of polyps enables to determine the exact histopathologic type as well as to effectively treat symptomatic gastric outlet obstruction and anemia.

Dear Sir,

Hyperplastic polyps represent the most common type of gastric polyps [1]. They are characterised by proliferation of foveolar cells with variable amounts of edematous stroma [1]. When hyperplastic gastric polyps occur in the antrum, they may prolapse into the pyloric channel, consequently causing gastric outlet obstruction and chronic blood loss leading to iron deficiency anaemia [2].

The patient, a 40-year-old male, was referred to our clinic with intermittent nausea, vomiting and symptomatic anaemia for four months. Notable haematological indices were low haemoglobin levels of 9.6 g/dl and hematocrit levels of 35.8%, while after receiving two units of concentrated red blood cells, at discharge; they achieved levels of 15.2 g/dl and

42.3%, respectively. Esophagogastroduodenoscopy revealed a 3 cm antral pedunculated polyp, prolapsing into pylorus thus causing intermittent pyloric obstruction and anaemia. Submucosal injection of the saline-epinephrine solution [3] in the basis of pedunculus and endo-loop placement was performed before the polyp was removed (Fig. 1). Rapid urease test for *Helicobacter pylori* performed on endoscopically taken tissue samples resulted negative. Histological examination revealed a hyperplastic polyp without evidence of malignancy. No atrophy, metaplasia, dysplastic changes or *Helicobacter pylori* infection were detected in samples taken from the antrum and the corpus; however, the examination provided evidence for gastritis. Histologically, hyperplastic polyp had corkscrew appearance characterised by marked elongation of the pits with branching and cystic dilatation of foveolae (Fig. 2A, 2B).

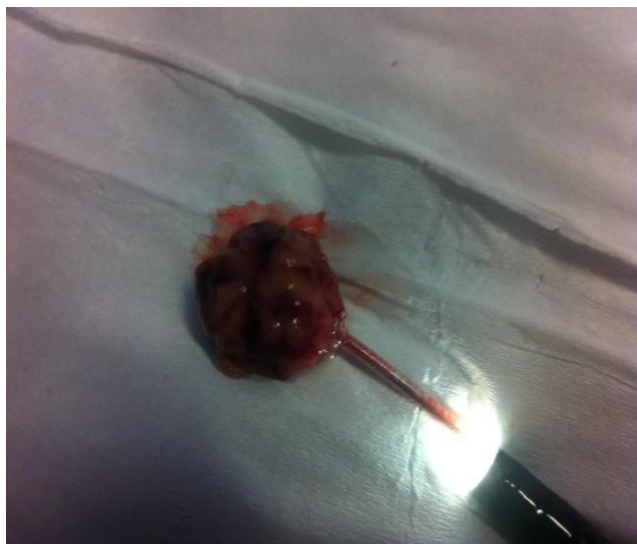


Figure 1: Gastric polyp after removal

Follow-up endoscopy was provided after 12 weeks to see polypectomy site after a course of Pantoprazole administration, and to define symptom-free time after polypectomy.

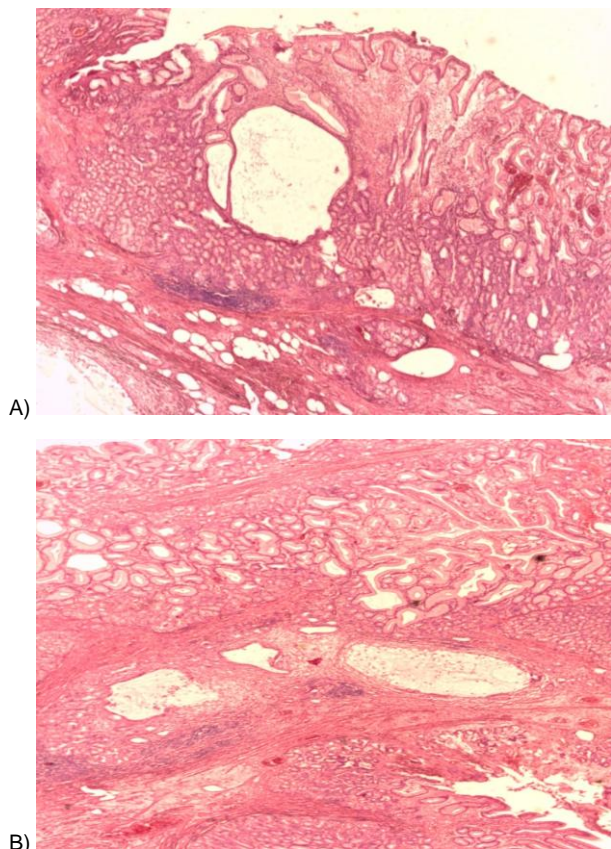


Figure 2: A) Irregular and dilated mucosal foveolae, lined by columnar epithelial cells are set in inflamed lamina propria (A), Hematoxylin and Eosin stain, 5x magnification). B) Smooth muscle fascicles traverse between the dilated glands, similar to what is observed in Peutz-Jeghers polyp (B), Hematoxylin and Eosin stain, 10x magnification)

Although most of these polyps are small (< 20 mm), large polyps may be encountered at endoscopy. The risk for complications is higher if the polyps exceed 20 mm in size [1]. Gencosmanoglu R. et al. [4] reported a similar case of a patient, in whom esophagogastroduodenoscopy revealed a prepyloric polyp causing intermittent gastric obstruction. Up to 80% of hyperplastic gastric polyps have been found to regress after eradication of *H. pylori* before endoscopic removal [5].

Endoscopic removal of complicated gastric polyps should be considered at the time of initial diagnostic endoscopy. Endoscopic resection of polyps enables to determine the exact histopathologic type as well as to effectively treat symptomatic gastric outlet obstruction and anaemia.

Ethics Committee Approval

The study protocol was approved by a local ethical committee of University Clinical Center of Kosovo.

Informed Consent

The participant gave written informed consent.

References

1. Jain R, Chetty R. Gastric hyperplastic polyps: a review. *Dig Dis Sci.* 2009; 54:1839-46. <https://doi.org/10.1007/s10620-008-0572-8> PMID:19037727
2. Gencosmanoglu R, Sen-Oran E, Kurtkaya-Yapicier O, Tozun N. Antral hyperplastic polyp causing intermittent gastric outlet obstruction: case report. *BMC Gastroenterol.* 2003; 3:16. <https://doi.org/10.1186/1471-230X-3-16> PMID:12831404 PMID:PMC166166
3. Kosai NR, Gendeh HS, Norfaezan AR, Razman J, Sutton PA, Das S. Prolapsing Gastric Polyp Causing Intermittent Gastric Outlet Obstruction. *Int Surg.* 2015; 100:1148-52. <https://doi.org/10.9738/INTSURG-D-14-00205.1> PMID:25578789 PMID:PMC4587521
4. Uraoka T, Saito Y, Yamamoto K, Fujii T. Submucosal injection solution for gastrointestinal tract endoscopic mucosal resection and endoscopic submucosal dissection. *Drug Des Devel Ther.* 2009; 2:131-8. PMID:19920900 PMID:PMC2761197
5. Ohkusa T, Takashimizu I, Fujiki K, et al. Disappearance of hyperplastic polyps in the stomach after eradication of *Helicobacter pylori*. A randomized, clinical trial. *Ann Intern Med.* 1998; 129:712-5. <https://doi.org/10.7326/0003-4819-129-9-199811010-00006> PMID:9841603