

# Histological Characteristics of Bruises with Different Age

Irena Kostadinova-Petrova<sup>1</sup>, Elida Mitevka<sup>1\*</sup>, Biljana Janeska<sup>2</sup>

<sup>1</sup>*Institute for Histology and Embryology, Faculty of Medicine, Ss Cyril and Methodius University of Skopje, Skopje, Republic of Macedonia*, <sup>2</sup>*Institute for Forensic Medicine and Criminalistics, Faculty of Medicine, Ss Cyril and Methodius University of Skopje, Skopje, Republic of Macedonia*

## Abstract

**Citation:** Kostadinova-Petrova I, Mitevka E, Janeska B. Histological Characteristics of Bruises with Different Age. Open Access Maced J Med Sci. 2017 Dec 15; 5(7):813-817. <https://doi.org/10.3889/oamjms.2017.207>

**Keywords:** bruises; histological analysis.

**\*Correspondence:** Elida Mitevka, Institute of Histology and Embryology, Faculty of Medicine, Ss Cyril and Methodius University of Skopje, Skopje. E-mail: [elida.mitevka@gmail.com](mailto:elida.mitevka@gmail.com)

**Received:** 20-Sep-2017; **Revised:** 15-Oct-2017; **Accepted:** 17-Oct-2017; **Online first:** 16-Oct-2017

**Copyright:** © 2017 Irena Kostadinova-Petrova, Elida Mitevka, Biljana Janeska. This is an open-access article distributed under the terms of the Creative Commons Attribution-NonCommercial 4.0 International License (CC BY-NC 4.0).

**Funding:** This research did not receive any financial support.

**Competing Interests:** The authors have declared that no competing interests exist.

**BACKGROUND:** In forensics bruises as injuries take an important part in the interpretation of the causes of death. Since activating the inflammatory response of the body in their formation, histological analysis of the bruised tissue can provide data on the determination of the time when the injury occurred.

**AIM:** The aim of this study is to compare the histological features of 1-day and 5-days old bruises.

**MATERIAL AND METHODS:** Bruised human skin samples, 1-day old in group A and 5-day-old in group B, obtained at autopsy from individuals who died from a violent death, were analyzed in this study. The qualitative microscopic analysis was performed on serial paraffin sections of tissues stained with Hematoxylin-eosin and Pearls Prussian Blue method, using a light microscope connected to a digital camera.

**RESULTS:** Qualitative histological analysis of the studied group A presented with fresh bruises, less than 24 hours old, showed ruptured smaller vessels and extravasated red blood cells in the connective tissue of the skin, with subsequent expansion and infiltration of fibrous septa of the skin. In the area of bleeding an initial infiltration by macrophages was observed. In the studied group B, presented with bruises 3-7 days old, histological analysis showed a marked presence of hemosiderin-laden macrophages and presence of hematoidin granules in the area of bleeding, as well as ruptured small blood vessels and red blood cells extravasation in the dilated fibrous septa.

**CONCLUSION:** A detailed analysis of tissue changes in bruises every day from the initiation until their recovery, a detailed description of the histological finding can be given, which will be supported in the precise determination of the age of the injuries themselves.

## Introduction

Bruises are skin injuries which present with extravasation of blood in the connective tissue of the skin or deeper in the underlying tissues [1]. At the time of the formation of bruises, due to the impact of the force, small blood vessels break in the skin and blood extravasates into the surrounding connective tissue, resulting in activation of the cellular response, followed by infiltration of the field of bleeding firstly with neutrophil granulocytes and then with macrophages. In addition to the initial signs of an injury, such as oedema near the haemorrhage resulting in enlargement of the fibrous septa, the erythrocytes outside blood vessels activate the inflammatory response of the body, hence

inflammation of the field of bleeding rapidly occurs [2]. Most commonly blood is extravasated between the dermis and hypodermis since there is a larger amount of loose connective tissue.

Three criteria must be met to create a bruise. The first criterion is the force acting on the skin; it should cause blood vessels to rupture in it, but not to disrupt the integrity of the skin. The pressure of force is usually transmitted by a blunt object. Otherwise the skin would be damaged. The second criterion is the blood pressure, which should be high enough to allow extravasation of the blood in the connective tissue of the skin. The third criterion is the location of the field of bleeding. The blood should be extravasated sufficiently close to the surface of the skin to be detected as a bruise [3]. Bruises formed during life

may not be visible due to opalescence of the skin [3, 4], but will be seen postmortem after the appearance of the skin reflection [5]. The early manifestation of blood drainage is dependent on two factors: the extravasation of blood from the blood vessels in the surrounding tissue and the depth of the skin where the blood is drained [6-8].

Bruises are not minor injuries because they can lead to death if they are extensive [9]. They are quite frequent injuries, and the determination of their age is one of the most sought data for forensic examinations, especially when it comes to cases of violent deaths and abuse in children [10] when the causes of death and the timing of the injuries are important to be known. Once the bruise is formed, the body reacts by activating the inflammatory response, and at the site of the bleeding, there is a migration of inflammatory cells, first neutrophilic granulocytes and later mononuclear macrophages. Their infiltration occurs at a certain time interval, which allows through the specific histological finding to interpret the age of the bruise [11].

In the routine examination procedures of injuries, when reviewing and interpreting bruises, the most commonly used method is observation as a method for rapid orientation for the age of the bruises. This approach as a standalone is commonly used in clinical assessment of these injuries, while in modern forensic medicine it is a baseline analysis complemented by microscopic and molecular analyses, to accurately determine the age of bruises.

Histological analysis through a detailed analysis of the cellular structure of affected tissue, as one of the additional methods for a detailed analysis of the age of bruises, provides an interpretation of the time when they occurred, as well as their age, data that can be further used in the investigation of cases of abuse in women and children, with possibility to be used as evidence in medico-legal cases.

The aim of this study was to make a comparison in the features of the bruised tissue by histological analysis with determination of the main histological findings in bruises 1-day and 5-day old, findings that further may be used as data for determining the age of bruises in addition to other methods.

## Material and Methods

The research was performed on human skin samples, obtained at autopsy from individuals who died from a violent death, at the Institute of Forensic Medicine in Skopje. All tissue samples were taken in depth across the entire skin together with the hypodermis, with dimensions of 4 cm<sup>2</sup>, and then fixed in a 40% formalin solution. Tissue samples contained

the entire bruise and its peripheral edges where the bruise passed into the healthy tissue. The qualitative histological analysis was performed on serial paraffin sections of skin tissues of 4 µm thickness, stained according to the standard Hematoxylin-eosin method. Additionally staining with the Pearls Prussian Blue method was applied for detection of macrophages. A light microscope, model Olympus CX21FS1 and lenses 40x, 20x and 10x were used for microscopic assessment of the tissue. Figures used in this study were made using micro camera Bresser, tv lens c-0.45x connected to Nikon Eclipse E400 microscope.

Samples were divided into three analysed groups, using the findings of a court expert, who classified the bruises by age, by using an observational method during the initial analysis of the bruised tissue during the autopsy. For this kind of classification, there are more published patterns (Table 1).

- Control group contained 12 samples of human skin with resectional edges that penetrated the surrounding healthy tissue of each autopsy material.
- Group A contained six tissue samples from human skin with fresh bruises, not older than 24 hours.
- Group B contained six tissue samples from human skin with bruises aged 3-7 days. The material in this group of orientational observation was classified into bruises with an approximate age of 3 days (two samples), four days (one sample), five days (two samples) and 5-6 days (sample of the decomposed body). Except for the last sample, the remaining samples were obtained from corpses shortly after death.

**Table 1: Classification of the age of bruises by colour, by five schemes published by different authors**

	Adelson	Rentable	Camps	Poison	Spitz
Initial colour	Red/blue	Violet	Red	Red, black	Blue/red
1-3 days	Blue/brown	Dark blue	Blue/brown	Purple, black	Purple, black
1 week	Yellow/green	Green	Green	Green	Green/yellow
8-10 days		Yellow	Yellow		Brown
2 weeks		Normal	Normal	Yellow	Normal

## Results

### Control group

The control group served us as a prototype for pattern construction and was used for comparison of the histological changes that occurred in bruised skin samples.

Histological analysis of all samples in the control group showed a normal skin structure, with an intact epidermis, dermis and hypodermis, and intact blood vessels. Red blood cells were observed only in

blood vessels. The cellular population of the connective tissue of the dermis was predominantly represented by fibrocytes and was less commonly present. Collagen fibres were a dominant component, with the irregular layout. The superficial tissue of the hypodermis consisted of clustered adipocytes in the form of lobes, wrapped with intact fibrous lobe-like septum with uniform obesity. The skin annexes had normal morphology (Figure 1).

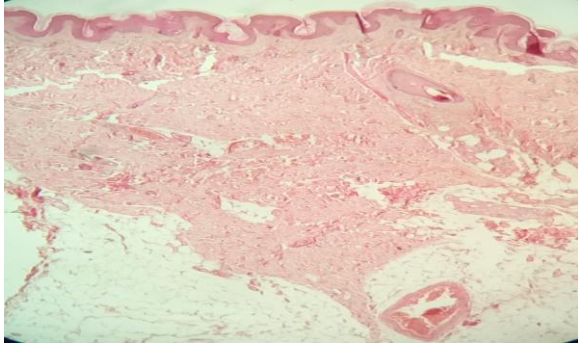


Figure 1: Normal human skin. The microphotography shows normal morphology of human skin, epidermis, dermis and part of the hypodermis (Haematoxylin-eosin, X10)

### Group A

Histological analysis of tissue sections with fresh bruises, not older than 24 hours, showed a change in the skin structure only in the hypodermis, while all other layers of the skin were unchanged in comparison to the control group. In the area of the fibrous septa of hypodermis, extravasated red blood cells were present from the ruptured vessels. The extravasated red blood cells penetrated the tissue of the fibrous septum, where only the peripheral contours of the septa and the collagen remained after the erythrocytes infiltration. The red blood cells retained their morphological form and appearance. Fibrous septa were damaged, corresponding to the initial oedema observed during the observation of injuries that resulted in a bruise. The bleeding area was located in the fibrous septa in the hypodermis, partly penetrating into the loose connective tissue between the adipocytes.

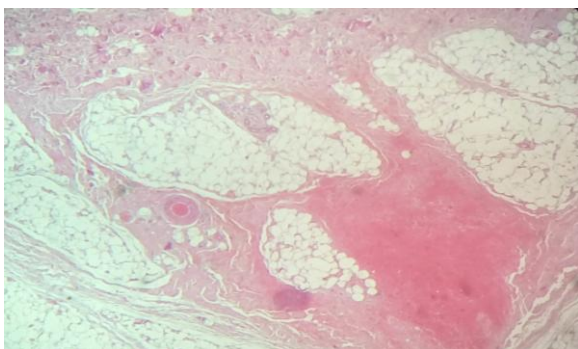


Figure 2: Fresh bruise, a few hours old. The microphotography shows the bleeding area filled with erythrocytes and the expansion of fibrous septae (Haematoxylin-eosin, X10)

Solid infiltration with polymorphonuclear cells

and initial infiltration with rare mononuclear cells were noticed. Infiltration was present throughout the bleeding area, with greater intensity in the peripheral parts (Figures 2 and 3). In 4 tissue samples in this group, the bleeding area entered the adipose tissue lobes, thus separating the adipocytes one from another, presenting with the microscopic impression as if adipocytes were found in the bleeding area.

The microscopic analysis of the peripheral parts in the bleeding area with surrounding healthy tissue showed a gradual transition from the bleeding area located in the fibrosis septa of the hypodermis, filled with red blood cells and inflammatory cells, into the normal structure of the skin in all its structural parts. There was a gradual narrowing of the fibrous septa in which the morphologic change was located, passing through to the healthy tissue where their structural features were noticed. Compared to the control group, their histological structure showed normal structure, with irregularly thick connective tissue woven with blood vessels and a normal structure of the border between the dermis and the hypodermis.

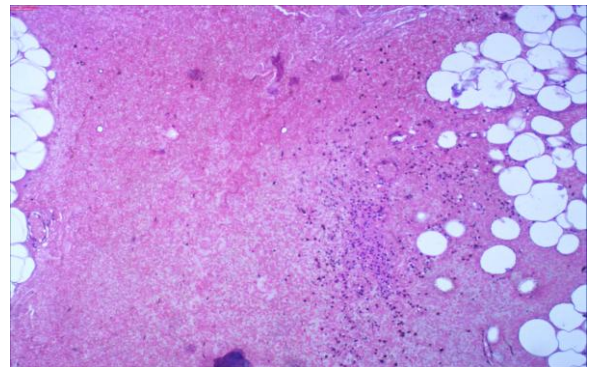


Figure 3: Fresh bruise, a few hours old. The microphotography shows the bleeding area (fibrous septum in the hypodermis) with initial infiltration with granulocytes (Haematoxylin-eosin, X20)

**Conclusion:** In the first 24 hours after the appearance of the bruise, the morphologic change was located in the fibrous septa of the hypodermis. Their collagen bundles were damaged due to the abundant extravasation. There was infiltration in the area of bleeding with granulocytes and rare macrophages. Infiltration was most pronounced in the peripheral zone of bleeding, with a wide belt. The bleeding area limits remained in the contours of the fibrous septa.

### Group B

Histological analysis of bruised tissue samples with 3 to 7 days old bruises showed extravasated erythrocytes from damaged blood vessels in the connective tissue of the hypodermis, located in the fibrous septa. Fibrous septa were dilated, their structural elements barely spun due to red blood cells infiltration. In the bleeding area, pronounced infiltration with mononuclear cells-

macrophages was noted. Residues from the erythrocytes phagocytosis in the form of hemosiderin were observed in them. Macrophage infiltration affected the entire bleeding area, both in its peripheral and in central parts. Among the erythrocytes, hematoidin particles were noticed, and they were diffusely spread through the bleeding area, seen brown-coloured. As in the analysed group A, in this group, there was also blood extravasation, located in the septa of connective tissue. The area of bleeding entered the delicate connective tissue between the adipocytes, isolating them; hence they were surrounded by densely hematoidin residues. In this examined group, bruises with different ages were analysed and there was a gradation of the presence of macrophages. The examined material consisted of 2 samples of bruises with an approximate age of 3 days, one sample of 4 days, two samples with an approximate age of 5 days and one sample of tissue originating from the decomposing body and its age corresponded approximately to 5-6 days.

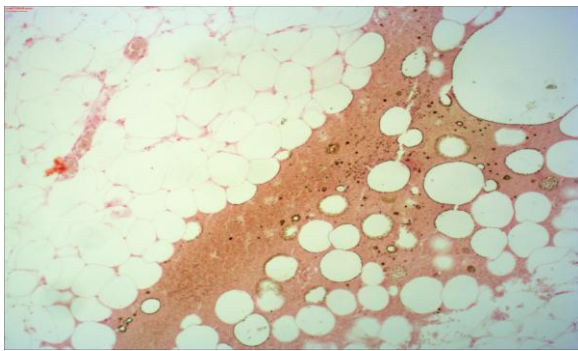


Figure 4: Five days old bruise. The microphotography shows the localisation of the bleeding area into the fibrous septa in the hypodermis (Pearls Prussian Blue, X 10)

The most pronounced presence of macrophages was observed in the bruises aged five days. The structure of the dermis was not altered; the analysed bruises were located in the adipose tissue of the hypodermis, within the contours of the fibrous septa.

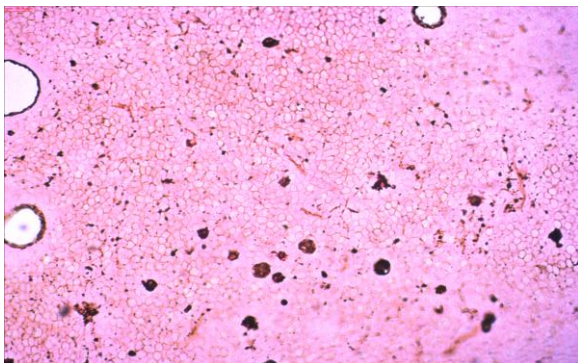


Figure 5: Five days old bruise. The microphotography shows macrophages filled with hemosiderin, as well as hematoidin granules between erythrocytes in the bleeding area (Pearls Prussian Blue, X 100)

The surrounding edges of the bruise showed

a gradual narrowing of the fibrous septae containing the bleeding area and passage to healthy tissue.

Due to the presence of a bleeding area in the hypodermis, a slight change in its thickness did not show a subsequent change in the appearance and thickness of the dermis. Since this study included tissue samples with small bruises, the question remains of further analysis of the changes that would cause oedema in the surrounding tissue in massive bruises (Figures 4 and 5).

**Conclusion:** The intensity of infiltration in the bleeding area with macrophages in our examined samples gradually increased until the fifth day after the appearance of the bruise. Infiltration affected the entire bleeding area. Hematoidin, among erythrocytes, was also extracellularly observed. The change was located and limited in the hypodermis fibrotic septa. Their collagen bundles were damaged due to abundant cell effusion.

## Discussion

In determining the age of bruises, the histological analysis in this study showed changes in the bruised tissue that occurred at a different time from the appearance of the bruise. In the first studied group, in bruises not more than 24 hours old, in addition to other tissue changes, the finding of infiltration of the bleeding area with polymorphonuclear leucocytes and rare mononuclear leukocytes indicating fresh bleeding. This finding is supported by literature data describing the course of the inflammatory response after the occurrence of the bleeding. In addition to the initial signs of injury, such as oedema in the area of bleeding, resulting in the enlargement of fibrous septa, the erythrocytes outside the blood vessels activate the inflammatory response of the body, which results in infusion of the connective tissue with inflammatory cells [2]. Approximately 4 hours after the initial bleeding, polymorphonuclear leukocytes-neutrophils migrated. These cells cannot phagocyte the red blood cells. Neutrophils are not present in normal skin, and therefore their presence is considered to be a significant finding [11]. Mononuclear leukocytes-macrophages are present in normal skin, and this makes their interpretation difficult when their infiltration begins in the bleeding area [11].

In the second examined group, with bruises aged 3-7 days, our analysis noted infiltration of the bruise with mononuclear cells-macrophages. These cells gradually infiltrated the bleeding area, which was also shown in the analysis of bruise samples with different ages within the second examined group. In the 5-day old bruises, the most intense infiltration with

macrophage in the bleeding area was observed. In addition to this finding, haematoidin granules extracellularly, as well as the presence of hemosiderin in macrophages, were noted in the bleeding area. The literature describes that approximately 9 hours after the initiation of the bruise, there is macrophages migration [12]. They can phagocyte extravasated erythrocytes. Phagocytosed erythrocytes in macrophages are observed after 15-17 hours after the appearance of the bruise [12]. Erythrophagocytosis occurs no later than three days [13]. In human skin lesions, macrophages are found at the earliest after 3 or 7 hours [13], with a peak of presence at 1-2 days after injury [14]. Macrophages filled with hemosiderin, as residues from phagocytosed red blood cells, detected by specific Pearls Prussian Blue method (Figure 3), can be seen at the earliest 24-48 hours after the appearance of the bruise, but are usually observed after 4-8 days. Hemosiderin is usually found in the tissue 90 hours after the inflammation, while the hematoidin is occasionally found 9 hours after the appearance of the bruise [12]. Hematoidin is a pigment that is chemically identical to bilirubin. It occurs in tissues as a result of the haemoglobin metabolism, especially in conditions of reduced oxygen concentration. Hematoidin does not contain iron; it is formed intracellularly, probably in reticuloendothelial cells, but is often located extracellularly, after 5-7 days, in the foci of previous bleeding. Our histological analysis showed refractory, yellow-brown or orange-red granules, but more typical were rhomboid plates arranged in a radial pattern, the so-called hematoidin burrs. The finding of hematoidin was a sign of bleeding which was in the direction of healing. The Pearls Prussian Blue staining method makes it easy to differentiate between hematoidin and hemosiderin. Hemosiderin produces blue coloured particles in the bleeding area, while hematoidin remains with light brown colouring [12].

In the further processing of this material, quantitative histological descriptions of cellular infiltration of bruises were made, as well as support for existing and new findings with additional molecular analyses. Quantification of macrophage infiltration in the bleeding area can be done with specific staining of macrophages with the Pearls Prussian Blue method that allows us to visualize hemosiderin in macrophages or this method can be supported by a molecular analysis of the gene expression for HO-1, an enzyme expressed in macrophages. In a more recent morphometric study, a significant amount of hemosiderin in the bleeding area has been described, about 20% and more of the field of vision, indicating the age of the bruise of about 1 week [15], which gives us the opportunity for a new field of research in interpretation of the histological finding in the bruises to determine their age.

The histological analysis gives a detailed insight into tissue structure. When using this method of analysis, the inflammatory response of the body to

the injury sustained can be monitored, with the possibility to note and process the stages in the repair of bruises on time. This method is used in the post-mortem analysis of bruises such as injuries in forensic medicine. A detailed analysis of tissue changes in bruises every day from the appearance until their recovery and a detailed description of the histological finding can be given, which will support the precise determination of the age of the injuries themselves.

## References

- Langlois NEI. The science behind the quest to determine the age of bruises—a review of the English language literature. *Forensic Science Medicine and Pathology*. 2007;3:241-251. <https://doi.org/10.1007/s12024-007-9019-3> PMID:25869263
- Vanezis P. Interpreting bruises at necropsy. *J Clin Pathol*. 2001;54:348-355. <https://doi.org/10.1136/jcp.54.5.348> PMID:11328832 PMCID:PMC1731416
- Cluroe AD. Superficial soft-tissue injury. *Am J Forensic Med Pathol*. 1995;16:142-146. <https://doi.org/10.1097/0000433-199506000-00013> PMID:7572870
- Camps F. Interpretation of wounds. *Br Med J*. 1952;2:770-772. <https://doi.org/10.1136/bmj.2.4787.770> PMID:12978325 PMCID:PMC2021602
- Hiss J, Kahana T. Medicolegal investigation of death in custody: a postmortem procedure for detection of blunt force injuries. *Am J Forensic Med Pathol*. 1996;17:312-314. <https://doi.org/10.1097/0000433-199612000-00007> PMID:8947356
- Edwards EA, Duntley SQ. The pigments and colour of living human skin. *Am J Anat*. 1939;65:1-33. <https://doi.org/10.1002/aja.1000650102>
- Hardy JD, Hammel HT, Murgatroyd D. Spectral transmittance and reflectance of excised human skin. *J Appl Physiol*. 1956;9:257-264. PMID:13376438
- Bonhert M, Baumgartner R, Pollak S. Spectrophotometric evaluation of the colour of intro- and subcutaneous bruises. *Int J Legal Med*. 2000;113:343-348. <https://doi.org/10.1007/s004149900107>
- Hiss J, Kahana T, Kugel C. Beaten to death: why do they die? *J Trauma*. 1996;40:27-30. <https://doi.org/10.1097/00005373-199601000-00006> PMID:8576994
- Gall J, Payne-James J. *Current practice in forensic medicine*. John Wiley & Sons, Ltd. Publication, 2011.
- Tarran S, Langlois NEI, Dziewulski P, Szynda T. Using the inflammatory cell infiltrate to estimate the age of human burn wounds: a review and immunohistochemical study. *Med Sci Law*. 2006;46:115-126. <https://doi.org/10.1258/rsmmsl.46.2.115> PMID:16683466
- Microscopy of bruises. Available from <http://www.forensicmed.co.uk/wounds/blunt-force-trauma/bruises/microscopy-of-bruises>. Accessed April 24th, 2014
- Betz P. Histological and enzyme histochemical parameters for the age estimation of human skin wounds. *Int J Legal Med*. 1994;107:60-68. <https://doi.org/10.1007/BF01225491> PMID:7529545
- Oenmichen M. Vitality and time course of wounds. *Forensic Sci Int*. 2004;144:221-231. <https://doi.org/10.1016/j.forsciint.2004.04.057> PMID:15364394
- Betz P, Eisenmenger W. Morphometrical analysis of hemosiderin deposits in relation to wound age. *Int J Leg Med*. 1996;108:262-264. <https://doi.org/10.1007/BF01369823>