



Cerebral Venous Thrombosis in a Patient with Iron Deficiency Anemia and Thrombocytopenia: A Case Report

Walaa A. Kamel^{1,2*}, Jasem Y. Al-Hashel^{1,3}, K. John Alexander¹, Fathi Massoud¹, Fatima Al Shawaf⁴, Ibtisam E. Al Huwaidi⁵

¹Neurology Department, Ibn Sina Hospital, Kuwait; ²Beni - Suef University, Egypt; ³Kuwait University, Kuwait; ⁴Mubarak Al-Kabeer Hospital, Kuwait; ⁵Geriatric Health Services, MOH, Kuwait

Abstract

AIM: To report a potential association of thrombosis, thrombocytopenia with iron deficiency anaemia.

CASE REPORT: A 43-year-old female experienced an episode of a headache, with bilateral papilledema by neurological examination, magnetic resonance venography (MRV) brain showed cerebrovenous thrombosis (CVT), iron deficiency anaemia and thrombocytopenia by blood investigations, that was treated with iron supplementations and anticoagulation.

CONCLUSION: In this patient, cerebrovenous thrombosis (CVT) was discovered in a patient with thrombocytopenia and iron deficiency anaemia and treated with iron supplements and anticoagulation, we concluded that thrombocytopenia is not a protective factor against thrombosis especially with iron deficiency anaemia.

Citation: Kamel WA, Al-Hashel JY, Alexander JK, Massoud F, Al Shawaf F, Al Huwaidi IE. Cerebral Venous Thrombosis in a Patient with Iron Deficiency Anemia and Thrombocytopenia: A Case Report. Open Access Maced J Med Sci. <https://doi.org/10.3889/oamjms.2017.216>

Keywords: Cvt; Anemia; Thrombocytopenia; Case; Report.

***Correspondence:** Walaa Kamel, Neurology Department, Ibn Sina Hospital, Kuwait. E-mail: Walaaneuro@yahoo.com

Received: 11-Sep-2017; **Revised:** 10-Oct-2017; **Accepted:** 12-Oct-2017; **Online first:** 28-Nov-2017

Copyright: © 2017 Walaa A. Kamel, Jasem Y. Al-Hashel, K. John Alexander, Fathi Massoud, Fatima Al Shawaf, Ibtisam E. Al Huwaidi. This is an open-access article distributed under the terms of the Creative Commons Attribution-NonCommercial 4.0 International License (CC BY-NC 4.0).

Funding: This research did not receive any financial support.

Competing Interests: The authors have declared that no competing interests exist.

Introduction

Cerebral venous thrombosis (CVT) presents acutely to the emergency department usually with signs and symptoms of raised intracranial tension, namely headache, vomiting and blurred vision, altered sensorium, seizures and focal deficits and if the patient is not treated in time can result in permanent deficits, coma and even death [1]. However sometimes cerebral venous thrombosis can manifest in an indolent fashion as seen in our patient whose only complaint was a persistent headache.

Case Report

A 43-year-old female presented with the intermittent bitemporal headache of a throbbing nature

mild to moderate in intensity associated with nausea, vomiting, and blurring of vision of 1-month duration, which was not responding to analgesics. She was diabetic, hypertensive dyslipidemic and obese. She also complained of menorrhagia of 3 years duration. On admission, she was afebrile, and her vitals were normal. Neurological examination revealed bilateral papilledema, no evidence of meningism or any focal neurological deficit. Routine blood investigation showed microcytic hypochromic anemia with hemoglobin value of 7.5 g/L (normal range: 12 - 16), RBC's value of 4.56 (normal range: 4.2 - 5.4), MCV is 55.6 (normal range: 82 - 97), low platelet count of 63,000/cumm (normal range 140,000-440,000), serum iron concentrate 3.3 mcml/L (normal range: 9 - 30), transferrin 3.2 g/L (normal range: 2 - 3.6), iron saturation 4% (normal range: 20 - 40%), heptaglobin is 2.26 g/L (normal range: 0.30 - 2). Coagulation profile was normal including antithrombin III, factor V (laden), and activated protein C resistance, antiphospholipid antibodies, fibrinogen, protein C, protein S, and homocysteine. Serum vitamin B12 and folate were normal. Screening for vasculitis including

rheumatoid factor, lupus anticoagulant, and Protein immunofixation electrophoresis was all normal. Upper gastrointestinal and lower digestive endoscopies, endovaginal sonography, thoracoabdominal and pelvic computed tomography were performed and did not detect any malignant disease or source of active bleeding. MRI brain and MR venography revealed right transverse and sigmoid sinus, Right internal jugular vein thrombosis (Fig. 1). A lumbar puncture study showed the high opening pressure of 34 cm H₂O with no cells, normal glucose and protein.

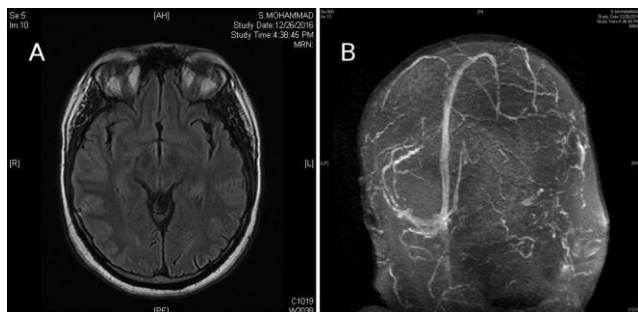


Figure 1: A) Normal MRI brain Axial FLAIR; B) MRV showing absent flow in the right transverse, sigmoid, and right internal jugular vein suggestive of cerebral venous thrombosis

The patient was treated as per protocol with low molecular weight (LMW) heparin, and this was later switched to Tablet Warfarin. Since she was found to be anaemic oral iron supplementation was also started. Daily haemogram was monitored, and it was observed that the platelet count rapidly increased and corrected to 200,000/cumm within one week. The patient's headache and blurring of vision gradually improved. The patient was discharged with gradual improvement of haemoglobin value of 8.2 g/dL, and the platelet count rose to 336,000/cumm. The cause of anaemia was presumed to be the prolonged history of menorrhagia this patient had after ruling out all other causes of the anaemia.

Discussion

Iron deficiency anaemia usually manifests as fatigue, exertional dyspnea and malaise. Neurological manifestations are not so common [2]. Our patient presented with symptoms of raised intracranial tension and who on the investigation was found to have CVT. Iron deficiency anaemia (IDA) is rarely recognized as a significant risk factor for stroke [3]. There are case reports of the association of iron deficiency and cerebral venous thrombosis with pseudotumor cerebri presentation which has been more often reported in children but only a few reports in the adult population [4 - 8]. Also, our patient had thrombocytopaenia which one would have expected to

cause a bleeding tendency but paradoxically could have contributed to the development of the venous thrombosis as explained below.

Some mechanisms have been proposed to explain the association between Iron deficiency anaemia and thrombosis. Firstly iron is considered to be a regulator of thrombopoiesis, and normal iron levels are required to prevent thrombocytosis by inhibiting thrombopoiesis and consequent hypercoagulable state [9]. It was postulated that iron either directly or indirectly inhibits the rise in platelets above steady state by inhibitory mechanisms; but also is required for the production or synthesis of one or more essential platelet components. By this, they postulated that when an iron deficiency occurs, it affects the inhibitory compartment first, and thrombopoiesis is stimulated leading to thrombocytosis; but if the iron depletion is more severe, the essential component is affected leading to thrombocytopenia. However, the level of iron deficiency at which the switch occurs is yet to be established [10].

Another mechanism by which iron deficiency may contribute to a hypercoagulable state is by affecting flow patterns within the vessels [11]. The microcytosis resulting from iron deficiency causes reduced red cell deformability and increased viscosity, which contributes to thrombosis in a negative-pressure environment, as is found in veins. Akin et al. have suggested that the decrease in antioxidant defence in iron deficiency anaemia may cause increased oxidative stress which in return may result in a tendency toward platelet aggregation [12]. Thus the abnormal platelet count and function observed in iron deficiency anaemia could act synergistically to promote thrombus formation especially in the setting of an underlying atherosclerotic disease, all these conditions lead to a turbulent blood flow, causing platelets to come more frequently in contact with endothelial lining [11].

Unlike children, in which the major cause of IDA is insufficient dietary iron intake, chronic blood loss is the most common cause of IDA in adults especially in women with menstrual irregularities as was seen in our patient who suffered from menorrhagia. The resolution of severe symptomatic anaemia along with thrombocytopenia following iron supplementation strengthens the hypothesis that iron therapy plays an important role in improving thrombocytopenia associated with IDA [13].

The association of menorrhagia, IDA, and thrombocytopenia that was noticed in our patient was also rarely reported in the literature, and the resolution of thrombocytopenia with iron supplements will occur provided other causes of thrombocytopenia are excluded such as acute hemorrhage, hemolysis, trauma, folate and vitamin B12 deficiency and idiopathic thrombocytopenic purpura [13]. Akoi et al. evaluated the effects of iron therapy on platelet

function among women with menorrhagia. They found iron deficiency anaemia in women caused arachidonic acid-induced platelet dysfunction causing increased menstrual blood loss which can be reversed through iron repletion [14]. In a study conducted by Jens et al. to identify venous thromboembolism risk factors in patients with thrombocytopenia, (platelet count $<100 \times 10^9/L$) it was concluded that the risk of venous thrombosis in patients with thrombocytopenia was the same as in patients with normal platelet counts [15]. Therefore it can be inferred that low platelet count does not give any protection against thromboembolism. Similarly, it has also been observed that certain subpopulations of patients with Idiopathic thrombocytopenic purpura (ITP) are at significantly higher risk of thrombotic complications [16-17].

In conclusion, this case report illustrates that CVT can occur in the setting of anaemia and thrombocytopenia. Correction of iron deficiency rapidly restored the platelet count and reversal of the hypercoagulable state which may have contributed to the rapid recovery of the patient albeit in the presence of adequate anticoagulation. Hence this case illustrates that iron deficiency anaemia and thrombocytopenia can be considered as independent risk factors for CVT. Whether the menorrhagia is an additional risk factor for a hypercoagulable state is open to debate and needs to be studied.

References

- Iurlaro S, Beghi E, Massetto N, Guccione A, Autunno M, Colombo B, Di Monda T, Gionco M, Cortelli P, Perini F, D'Onofrio F, Agostoni E. Does a headache represent a clinical marker in early diagnosis of cerebral venous thrombosis? A prospective multicentric study. *Neurol Sci*. 2004;25:S298-S2. <https://doi.org/10.1007/s10072-004-0317-1> PMID:15549568
- ai-Hao Huang, Je-Jen Su, Po-Hsien Lin. Iron deficiency anemia-A rare etiology of sinus thrombosis in adults. *Acta Neurologica Taiwanica*. 2010;19:2.
- Sébire G, Tabarki B, Saunders DE, Leroy I, Liesner R, Saint-Martin C, Husson B, Williams AN, Wade A, Kirkham FJ. Cerebral venous sinus thrombosis in children: risk factors, presentation, diagnosis and outcome. *Brain*. 2005;128,477-489. <https://doi.org/10.1093/brain/awh412> PMID:15699061
- Aoki N, Sakai T. Cerebral sinus thrombosis in patients with severe iron deficiency anaemia due to myoma uteri. *Acta Neurochir (Wien)*. 1989; 97: 131–134. <https://doi.org/10.1007/BF01772824>
- Ho BL, Huang P, Khor GT, Lin RT. Simultaneous thrombosis of cerebral artery and venous sinus. *Acta NeuroTaiwan*. 2008;17:112-116. PMID:18686652
- Kinoshita Y, Taniura S, Shishido H, Nojima T, Kamitani H, Watanebe T. Cerebral venous sinus thrombosis associated with iron deficiency: two case reports. *Neurol Med Chir (Tokyo)*. 2006; 46:589–593. <https://doi.org/10.2176/nmc.46.589>
- Balci K, Utku U, Asil T, Buyukkoyuncu N. Deep cerebral vein thrombosis associated with iron deficiency anaemia in adults, *Journal of Clinical Neuroscience*. 2006; 14(2):181–184. <https://doi.org/10.1016/j.jocn.2005.09.020> PMID:17161294
- Ogata T, Kamouchi M, Kitazono T et al., Cerebral venous thrombosis associated with iron deficiency anemia. *Journal of Stroke and Cerebrovascular Diseases*. 2008; 17(6):426–428. <https://doi.org/10.1016/j.jstrokecerebrovasdis.2008.04.008> PMID:18984440
- Beguín Y. Erythropoietin and platelet production. *Haematologica*. 1999; 84(6):541–547. PMID:10366799
- Gupta M, Joseph G. Severe thrombocytopenia associated with iron deficiency. *Hospital Physician*. 2001; 37: 49-54.
- Hartfield DS, Lowry NJ, Keene DJ, Yager JY. Iron deficiency: a cause of stroke in infants and children. *Pediatric Neurology*. 1997; 16(1):50–53. [https://doi.org/10.1016/S0887-8994\(96\)00290-1](https://doi.org/10.1016/S0887-8994(96)00290-1)
- Akins PT, Glenn S, Nemeth PM, Derdeyn CP. Carotid artery thrombus associated with severe iron deficiency anemia and thrombocytosis. *Stroke*. 1996;27:1002-1005. <https://doi.org/10.1161/01.STR.27.5.1002> PMID:8623090
- Ibrahim R, Khan A, Shahzad Raza MK, Dabas R, Haynes E, Gandhi A, Majumder OL, Zaman M. Triad of iron deficiency anemia, severe thrombocytopenia and menorrhagia—a case report and literature review. *Clinical medicine insights. Case reports*. 2012;5:23. <https://doi.org/10.4137/CCRRep.S9329> PMID:22493563 PMID:PMC3320130
- Akoi N, Sakai T. Cerebral sinus thrombosis in patients with severe iron deficiency anemia due to myoma uteri. *Acta Neurochir (Wien)*. 1989; 97:131-134. <https://doi.org/10.1007/BF01772824>
- Baelum JK, Moe EE, Nybo M, Vinholt PJ. Venous Thromboembolism in Patients With Thrombocytopenia: Risk Factors, Treatment, and Outcome. *Clinical and Applied Thrombosis/Hemostasis*. 2017;23(4):345-50. <https://doi.org/10.1177/1076029615613158> PMID:26512063
- Mc Crae K. Immune thrombocytopenia with pulmonary embolism and deep vein thrombosis. *The Haematologist*. 2011; 8-6.
- Ruggeri M, Tosetto A, Palandri F, et al. Thrombotic risk in patients with primary immune thrombocytopenia is only mildly increased and explained by personal and treatment-related risk factors. *J Thromb Haemost*. 2014;12:1266-1273. <https://doi.org/10.1111/jth.12636> PMID:24942752