

# A Patient with Multiple Keratinocytic Cancers (MKC): Uncommon Presentation in a Bulgarian Patient

Georgi Tchernev<sup>1,2\*</sup>, Stanislav Philipov<sup>3</sup>, Anastasiya Atanasova Chokoeva<sup>4</sup>, Uwe Wollina<sup>5</sup>, Torello Lotti<sup>6</sup>, Ilija Lozev<sup>7</sup>, Irina Yungareva<sup>1</sup>, Georgi Konstantinov Maximov<sup>2</sup>

<sup>1</sup>Medical Institute of the Ministry of Interior - Medical Institute of Ministry of Interior (MVR), Department of Dermatology, Venereology and Dermatologic Surgery, Sofia, Bulgaria; <sup>2</sup>"Onkoderma" - Polyclinic for Dermatology and Dermatologic Surgery, Sofia, Bulgaria; <sup>3</sup>Sofiiski Universitet Sveti Kliment Ohridski Meditsinski Fakultet - Department of General and Clinical Pathology, Sofia, Bulgaria; <sup>4</sup>Medical University Plovdiv - Dermatology and Venereology, Vasil Aprilov 15A, Plovdiv 4000, Bulgaria; <sup>5</sup>Städtisches Klinikum Dresden - Department of Dermatology and Allergology, Dresden, Sachsen, Germany; <sup>6</sup>University G. Marconi of Rome - Dermatology and Venereology, Rome, Italy; <sup>7</sup>Medical Institute of Ministry of Interior Department of General, Vascular and Abdominal Surgery, Sofia, Bulgaria

## Abstract

**Citation:** Tchernev G, Philipov S, Chokoeva AA, Wollina U, Lotti T, Lozev I, Yungareva I, Maximov GK. A Patient with Multiple Keratinocytic Cancers (MKC): Uncommon Presentation in a Bulgarian Patient. Open Access Maced J Med Sci. <https://doi.org/10.3889/oamjms.2018.010>

**Keywords:** skin cancer; surgery; island flap; basal cell carcinoma; squamous cell carcinoma

**\*Correspondence:** Georgi Tchernev, Department of Dermatology, Venereology and Dermatologic Surgery, Medical Institute of Ministry of Interior (MVR-Sofia), General Skobelev 79, 1606 Sofia, Bulgaria; Onkoderma - Polyclinic for Dermatology, Venereology and Dermatologic Surgery, General Skobelev 26, 1606, Sofia, Bulgaria. E-mail: [georgi\\_tchernev@yahoo.de](mailto:georgi_tchernev@yahoo.de)

**Received:** 26-Jul-2017; **Revised:** 20-Aug-2017; **Accepted:** 21-Aug-2017; **Online first:** 13-Jan-2018

**Copyright:** © 2018 Georgi Tchernev, Stanislav Philipov, Anastasiya Atanasova Chokoeva, Uwe Wollina, Torello Lotti, Ilija Lozev, Irina Yungareva, Georgi Konstantinov Maximov. This is an open-access article distributed under the terms of the Creative Commons Attribution-NonCommercial 4.0 International License (CC BY-NC 4.0)

**Funding:** This research did not receive any financial support

**Competing Interests:** The authors have declared that no competing interests exist

Keratinocyte skin cancers, including basal cell carcinoma (BCC) and squamous cell carcinoma (SCC), are the most common cancer occurring in people with fair skin, worldwide. Despite all known triggers, several suggested contributors are still investigated. We will focus our attention on the personal history of previous cancers and radiation exposure as occupational risk factors, as in the presented case. We report a patient, with multiple BCCs, and subsequent occurrence of a SCC on photo-exposed area of the face, as we want to emphasize the importance of strict following up of these patients, regarding the risk for developing new tumors in short periods of time, no matter if the triggering exposure factor is known from the history, or not. Although keratinocytes tumours are associated with the low mortality rate, we focus the attention on the fact, that the history of non-melanoma skin cancer is associated with increased mortality.

## Introduction

Keratinocyte skin cancers, including basal cell carcinoma (BCC) and squamous cell carcinoma (SCC), are the most common cancer occurring in people with fair skin, worldwide [1]. The highest incidence has been reported in Australia, because of the higher cumulative UV-exposure, with higher prevalence among man after 60 years of age, with the higher domination of BCC, than SCC [1][2]. Exposure to UV radiation is the primary triggering factor for malignant transformation in both-melanoma and non-

melanoma cancers, although the pattern of exposure that gives rise to different types of tumours appears to vary [2]. Other risk factors, playing role in the cancer genesis of these kinds of tumors include: patient's phenotype (light-coloured skin, eyes and hair), personal and family history of skin cancer, exposure to ionizing radiation, arsenic, and certain petroleum products, previous PUVA therapy, xeroderma pigmentosum, Basal cell nevus syndrome, immunosuppression and variety of precancerous skin conditions [3]. Most of the cases are the result of the simultaneous contribution of many risk factors [3]. While UV-exposure from the sun is the most important

risk factor for all skin cancer, the risk of basal cell and squamous cell skin cancers also increases with age [1]. Despite the morbidity, the gender distribution also depends on age. BCC develops in people under the age of 52, more commonly in women than men, while after 52, BCC is more common in men [2]. Squamous cell carcinoma is considered to occur equally in both men and women up to the age of 47, while after the age of 47, SCC becomes more common in men [1][2].

Despite all known triggers, several suggested contributors are still investigated. We will focus our attention on the personal history of previous cancers and radiation exposure as occupational risk factors, as in the presented case.

## Case report

An 83-year-old, fair-skinned, blue-eyed Caucasian male patient was admitted for a second time in the clinic for dermatologic surgery, with a medical history of multiple non-melanoma skin cancers in the past couple of years. The occasion of the certain hospitalisation was a recently occurred tumour formation, located on his left infratemporal area. Clinical examination revealed a nodular formation, with the ulcerated surface, covered with yellowish crusts and raised pearl-like edges, affecting the skin of the left preauricular, infratemporal area (Fig. 1a).

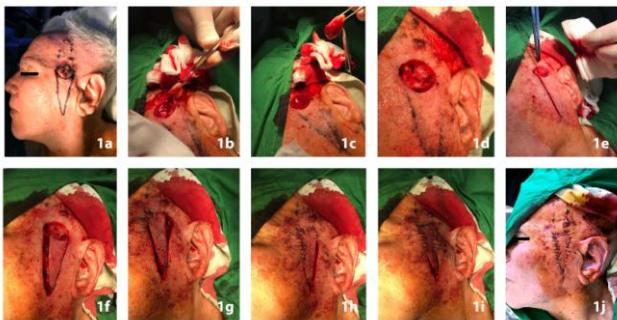

Figure 1: a - Clinical manifestation of a tumour, prior the surgical excision; b, c, d, e - Intraoperative finding. Oval shaped excision of a tumour with the preparation of the island flap; f - Postoperative findings. The surgical wound is closed with single stitches

Arterial hypertension, diabetes type II and prostate hyperplasia were reported as comorbidities, controlled with medications. Dermatologic history was positive for previous keratinocyte tumours, including eight basal cell carcinomas, excised within the first hospitalisation in the clinic, and four more BCCs, excised previously. Occupational history was positive for risk factors, as the patient had been working as a welder, in radiation conditions with X - rays. The conducted screening panel, including laboratory blood tests, lung X-ray and abdominal ultrasonography did

not reveal any significant abnormalities or organ involvement. The patient was referred for surgical treatment with island flap under local anaesthesia. The tissue, surrounding the tumour was resected by deep oval excision, toward the underlying muscle (Figs. 1 b, c, d). Two additional excisions were performed, forming a triangle (Fig. 1 e, f, g, h). The proximal and distal part of the flap was gently dissected in depth, for easier further transposition. The proximal part of the flap was slightly cut and transported proximally, with adaptation to the edges of the primary cutaneous defect (Fig. 1 e, f, g, h). Stepwise adjustment of the cutaneous island to the newly created bed was performed next, as the blood supply and innervation of the transported area were preserved (Fig. 1 e, f, g, h, i, j). The postsurgical period underwent without complications. Histopathological examination of the resected tumour verified the diagnosis of SCC (Fig. 2 a, b, c, d).

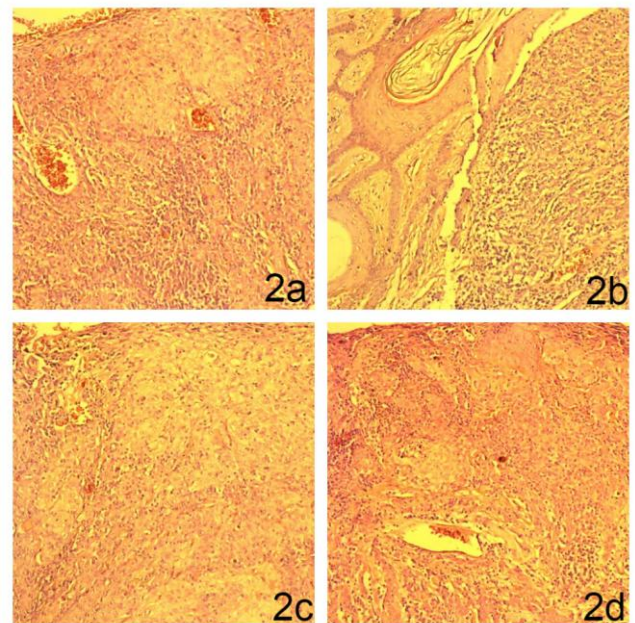


Figure 2: Histopathological findings, confirming the diagnosis of SCC (H&Ex100): a - Aggregates of atypical epithelial cells invading the dermis. The nonspecific inflammatory infiltrates with lymphocytes and plasma cells; b - Lobules and nests of atypical, acantholytic keratinocytes. Premature cornification with free-floating neoplastic keratinocytes. Cellular aggregates with vascular appearance; c, d - Aggregates of atypical epithelial cells invading the dermis. The nonspecific inflammatory infiltrates with lymphocytes and plasma cells. Erythrocytes contained in pseudovascular spaces. Moderate mitotic activity. Premature cornification

## Discussion

Multiple keratinocyte tumors may occur in the framework of inherited conditions, such as Gorlin-Goltz syndrome (caused by a mutation in a tumor-suppressor gene, known as the patched 1 gene (*PTCH1*) and xeroderma pigmentosum, as well as a result from several hereditary syndromes that are

associated with increased risk for development of BCCs, including Bazax - Dupre - Christol syndrome, Rombo syndrome, multiple hereditary infundibulocystic BCCs syndrome, basaloid hematoma etc. [4]. On the other hand, many immune-related conditions are also associated with increased keratinocyte carcinoma risk [5]. While usually most of the mentioned conditions are caused by certain mutations and have been associated with additional abnormalities, in the genesis of an-syndromic multiple keratinocyte tumours should be based on the environmental factors predominantly, mainly the UV exposure and personal history [6]. And if the cumulative dosage of UV radiation leads to DNA damage in all individuals, it is certainly unclear whether multiple keratinocyte tumours could appear in all individuals, exposed to same triggering factors, as radiation for example.

But it is well - known that the 3 - year cumulative risk for developing a BCC is 44% higher with at least a 10 - fold increase in the incidence compared with the rate in a comparable general population, while the cumulative risk of a subsequent SCC after a primary SCC is 18%, or at least a 10 - fold increase in incidence compared with the incidence of first tumors in a comparable general population [6]. Furthermore, the established risk of developing BCC in a patient with previous SCC is almost equal to the same in a patient with a primary BCC, for developing a new BCC, but it is lower for subsequent development of SCC in a patient with primary BCC [6].

Varies treatment options have been implicated in non-melanoma skin cancers, including surgical and non - surgical technique's [8]. The choice of treatment approach depends on several factors, including 1) the location of the lesion; 2) the type of a tumour; 3) the patient's age and comorbidities [8]. Surgical management may involve standard elliptic surgical excision of a primary tumour and Mohs micrographic surgery [8][9]. Although other possible modalities include locally destructive methods, such as cryotherapy, curettage, electro cautery and radiation, it is established that surgical management is the preferred one [9]. When dealing with face - located lesions, the defect closing and further reconstruction for the best aesthetic result could be challenging. Despite the primary closure, skin grafting, and local and free flaps are used in providing best cosmetic results and optimal defect closing [9]. Local flaps, including rotational techniques, Limberg flap, island flaps and V - Y advancement flaps, are usually performed in small and medium-size defects, depending on defects' shape and surgeon preferences, while skin grafting is recommended in larger surgical wounds [9].

In the presented case, we report a patient, with multiple BCCs in the past, and subsequent

occurrence of a SCC on photo-exposed area of the face, as we want to emphasize the importance of strict following up of these patients, regarding the risk for developing new tumors in short periods of time, no matter if the triggering exposure factor is known from the history, or not. Although keratinocytes tumours are associated with low fertility rate, we focus the attention on the fact, that the history of non-melanoma skin cancer is associated with increased mortality, as the high prevalence of these tumours elevates the importance of the possibility of associated subsequent mortality from other causes also [7]. Early detection is an essential part of the therapeutic process, while surgical excision is the most appropriate treatment choice.

## References

1. Perera E., Gnaneswaran N, Staines C, Win AK, Sinclair R. Incidence and prevalence of non-melanoma skin cancer in Australia: A systematic review. *Australas J Dermatol.* 2015; 56(4):258-67. <https://doi.org/10.1111/ajd.12282> PMID:25716064
2. Xiang F, Lucas R, Hales S, Neale R. Incidence of nonmelanoma skin cancer about ambient UV radiation in white populations, 1978-2012: empirical relationships. *JAMA Dermatol.* 2014; 150(10):1063-71. <https://doi.org/10.1001/jamadermatol.2014.762> PMID:25103031
3. Skin cancer (non-melanoma) - risks factors and prevention. American Society of Clinical Oncology (ASCO). (2013, December). Cancer.Net. Alexandria, VA.: American Society of Clinical Oncology (ASCO). <http://www.cancer.ca/en/cancer-information/cancer-type/skin-non-melanoma/risks/?region=sk#ixzz4qHlonl7C>
4. Burgdorf W., Plewig G., Wolf H., Landthaler M. et al. Braun Falco's Dermatology. 3rd edition. Other syndromes associated with increased risk for Basal cell carcinoma. Springer, 2009: Chapter 95, p 1355. <https://doi.org/10.1007/978-3-540-29316-3>
5. Yanik EL, Pfeiffer RM, Freedman DM, Weinstock MA, Cahoon EK, Arron ST, Chaloux M, Connolly MK, Nagarajan P, Engels EA. The spectrum of Immune-Related Conditions Associated with Risk of Keratinocyte Cancers among Elderly Adults in the United States. *Cancer Epidemiol Biomarkers Prev.* 2017; 26(7):998-1007. <https://doi.org/10.1158/1055-9965.EPI-17-0003> PMID:28377416
6. Marcil I, Stern RS. Risk of developing subsequent non-melanoma skin cancer in patients with a history of nonmelanoma skin cancer: a critical review of the literature and meta-analysis. *Arch Dermatol.* 2000; 136(12):1524-30. <https://doi.org/10.1001/archderm.136.12.1524> PMID:11115165
7. Barton V, Armeson K1,2, Hampras S3, Ferris LK4, Visvanathan K5, Rollison D3, Alberg AJ. Nonmelanoma skin cancer and risk of all-cause and cancer-related mortality: a systematic review. *Arch Dermatol Res.* 2017; 309(4):243-251. <https://doi.org/10.1007/s00403-017-1724-5> PMID:28285366
8. Smith V, Walton S. Treatment of facial Basal cell carcinoma: a review. *J Skin Cancer.* 2011; 2011:380371. <https://doi.org/10.1155/2011/380371> PMID:21773034 PMID:PMC3135095
9. Kwon KH, Lee DG, Koo SH, Jo MS, Shin H, Seul JH. Usefulness of v-y advancement flap for defects after skin tumor excision. *Arch Plast Surg.* 2012; 39(6):619-25. <https://doi.org/10.5999/aps.2012.39.6.619> PMID:23233887 PMID:PMC3518005