

Violet - Colored Inguinal Located Cutaneous Tumour?

Georgi Tchernev^{1,2*}, Anastasiya Atanasova Chokoeva³, Torello Lotti⁴, Uwe Wollina⁵, Irina Yungareva¹, Ilia Lozev⁶, Georgi Konstantinov Maximov²

¹Medical Institute of Ministry of Interior (MVR), Department of Dermatology, Venereology and Dermatologic Surgery, Sofia, Bulgaria; ²"Onkoderma" - Polyclinic for Dermatology and Dermatologic Surgery, Sofia, Bulgaria; ³Medical University Plovdiv, Dermatology and Venereology, Vasil Aprilov 15A, Plovdiv 4000, Bulgaria; ⁴University G. Marconi of Rome - Dermatology and Venereology, Rome, Italy; ⁵Städtisches Klinikum Dresden - Department of Dermatology and Allergology, Dresden, Sachsen, Germany; ⁶Medical Institute of Ministry of Interior Department of General, Vascular and Abdominal Surgery, Sofia, Bulgaria

Abstract

Citation: Tchernev G, Chokoeva AA, Lotti T, Wollina U, Yungareva I, Lozev I, Maximov GK. Violet - Colored Inguinal Located Cutaneous Tumour? Open Access Maced J Med Sci. 2018 Jan 25; 6(1):137-138. https://doi.org/10.3889/oamjms.2018.015

Keywords: B cell lymphoma; T cell lymphoma; anaplastic large; surgery; chemotherapy; systemic involvement

***Correspondence:** Georgi Tchernev. Department of Dermatology, Venereology and Dermatologic Surgery, Medical Institute of Ministry of Interior (MVR-Sofia), General Skobelev 79, 1606 Sofia, Bulgaria; Onkoderma - Polyclinic for Dermatology, Venereology and Dermatologic Surgery, General Skobelev 26, 1606, Sofia, Bulgaria. E-mail: georgi_tchernev@yahoo.de

Received: 31-Jul-2017; **Revised:** 01-Sep-2017; **Accepted:** 03-Sep-2017; **Online first:** 13-Jan-2018

Copyright: © 2018 Georgi Tchernev, Anastasiya Atanasova Chokoeva, Torello Lotti, Uwe Wollina, Irina Yungareva, Ilia Lozev, Georgi Konstantinov Maximov. This is an open-access article distributed under the terms of the Creative Commons Attribution-NonCommercial 4.0 International License (CC BY-NC 4.0)

Funding: This research did not receive any financial support

Competing Interests: The authors have declared that no competing interests exist

Anaplastic large cell lymphoma (ALCL) represents an aggressive CD30 – positive T cell lymphoma, as it is the second most common T cell lymphoma and 2% to 5% of all non - Hodgkin lymphomas. The cutaneous involvement can be primary or secondary within systemic ALCL, resembling inflammatory and other neoplastic lesions both clinically and cytologically. Various pigmented cutaneous tumours with a different origin, cutaneous metastasis and B-cell lymphoma must be carefully considered in the differential diagnostic plan. While simple surgical excision is usually curative, with good prognosis, systemic involvement must also be excluded. We present a case of a patient, with clinically unspecific single violet nodular lesion, as the only clinical manifestation of ALCL. The diagnosis was confirmed histologically, as the surgical excision was enough therapeutic management, regarding the early disease stage. Further following up with the patient is mandatory, because of the high recurrence rate. We want to emphasise the diversity of clinical manifestation of ALCL, regarding the importance of its early diagnosis and treatment.

Introduction

Anaplastic large cell lymphoma (ALCL) is the second most common T cell lymphoma and 2% to 5% of all non-Hodgkin lymphomas [1][2]. It represents an aggressive CD30 - positive T - cell lymphoma, with three subtypes, exhibiting a chromosomal translocation involving the ALK gene and the expression of ALK protein [3]. Although no current risk factors have been identified, some studies have shown an increased risk of incidence (up to 18 times) in association with breast implants for augmentation [3]. An increased risk of malignant T - cell lymphoma in patients with atopic dermatitis has also been reported [4]. The disease more often affects young and middle-aged adults, with mild male predominance

and with rapid progression and generalisation [4]. The cutaneous involvement can be primary or secondary within systemic ALCL [2], resembling inflammatory and other neoplastic lesions both clinically and cytologically [1]. Although fine needle biopsy aspiration cytology is usually useful for the correct diagnosis, most of the cases present in advanced stages and usually have been excited regarding the wide spectrum of differential diagnosis [2][3].

Case Report

A 63 – year - old male patient presented to the department of dermatologic surgery, because of

an elevated violet tumor-like formation on the inner side of his right hip. The lesion occurred approximately 20 days ago, accompanied by occasional spontaneous bleeding and mild discomfort. The patient had been treated with topical antibiotics for almost ten days, without any therapeutic result. Neither family history, nor comorbidities were reported.

Clinical examination revealed a nodular tumour-like formation with erythematous-violet discoloration, located on the medial side of the right hip (Fig. 1a). Enlarged lymph nodes were not detected on palpation. Laboratory blood tests were within the normal range. The patient was referred for surgical removal of the lesion. Elliptic surgical excision with 0.5 cm surgical margins was performed under local anaesthesia (Fig. 1 b, c, d).

The histopathological examination of a fragment of the excised lesion revealed diffuse dermal infiltrate of atypical cells. The atypical cells were with prominent, centrally located nuclei. Simultaneously a mixed inflammatory infiltrate was also detectable at the histology slides (Fig. 1 g, h, i). The findings were indicative of primary cutaneous anaplastic large T-cell lymphoma.

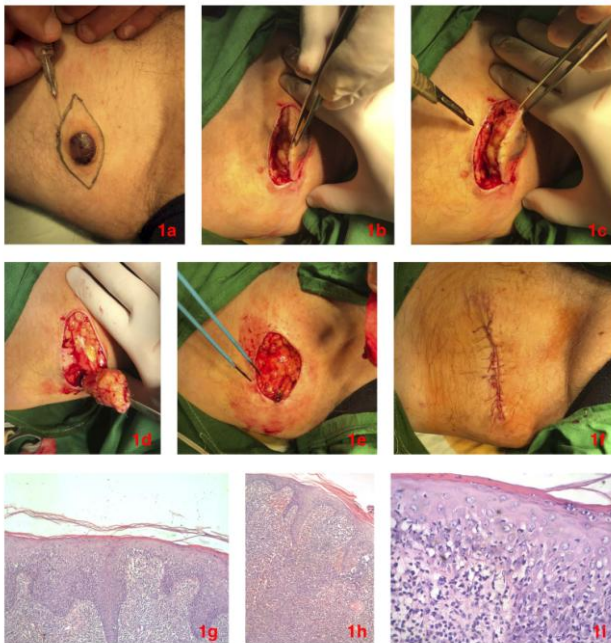


Figure 1: a – Clinical manifestation of a primary cutaneous anaplastic large cell lymphoma, presented as a single violet nodule in the medial aspect of the right hip; b, c, d, e, f – Intraoperative findings. Surgical excision of the lesion; g, h, i – Histological findings. Diffuse dermal infiltrate of atypical cells with prominent centrally located nuclei, with simultaneously presented mixed inflammatory infiltrate

The patient was referred for hospitalization in the haematology department for further screening for systemic involvement, which was not detected at this stage. Additional immunohistochemistry was planned

for confirmation of the diagnosis, as well as spinal puncture and serum flow cytometry.

Discussion

Primary cutaneous ALCL can be present clinically as single or multifocal nodules that ulcerate spontaneously, have autoregressive behavior and high rate of recurrence [5]. Regional lymph node invasion could be a sign for extracutaneous dissemination [5]. The diagnosis is confirmed by histological features such as diffuse, non-epidermotropic infiltrate, and anaplastic large lymphoid cells of immunohistochemistry CD30+, CD4+, EMA-/+ , ALK-, CD15- and TIA1-/+ . [5]. Surgical removal of the lesion, radiotherapy or low-dose methotrexate is reported treatment of choices [5].

In the presented case, a clinically unspecific single violet nodular lesion was the only clinical manifestation of ALCL. Diagnosis was confirmed histologically, and surgical excision was enough therapeutic management in regard to the early disease stage. Prognosis is good and does not depend on lymphatic invasion in general. Further following up of the patient is mandatory because of the high recurrence rate [1].

References

1. MA, Kothari KS, Naik LP, Patil S. Anaplastic large cell lymphoma: A great mimic on cytology. *J Cytol.* 2017; 34(3):165-167. <https://doi.org/10.4103/0970-9371.208101> PMID:28701833 PMID:PMC5492757
2. Athar S, Siddiqui N, Hameed A. Characteristics And Outcomes Of Anaplastic Large Cell Lymphoma Patients-A Single Centre Experience. *J Ayub Med Coll Abbottabad.* 2017; 29(1):37-41. PMID:28712170
3. Ferreri AJ, Govi S, Pileri SA, Savage KJ. Anaplastic large cell lymphoma, ALK-positive. *Crit Rev Oncol Hematol.* 2012; 83(2):293-302. <https://doi.org/10.1016/j.critrevonc.2012.02.005> PMID:22440390
4. Mitsuaki Ishida, Keiko Hodohara, Miyuki Yoshii, Hiroko Okuno, Akiko Horinouchi, Ayaka Shirakawa, Ayumi Harada, Muneo Iwai, Keiko Yoshida, Akiko Kagotani, Takashi Yoshida, Hidetoshi Okabe. Primary cutaneous anaplastic large cell lymphoma occurring in an atopic dermatitis patient: a case report with review of the literature with emphasis on their association. *Int J Clin Exp Pathol.* 2014; 7(4): 1735–1741. PMID:24817972 PMID:PMC4014256
5. Vinogradova luE, Lutsenko IN, Kaplanskaia IB, Vorob'ev IA, SamoiloVA RS, Gorgidze LA, Ryzhikova NA, Valiev TT, Giliazitdinova EA, Dzhulakian UL, Egorova EK, Zvonkov EE, Krasil'nikova BB, Magomedova AU, Margolin OV, Mar'in DS, Kremenetskaia AM, Kravchenko SK, Vorob'ev AI. Efficacy of therapy of different variants of anaplastic large T-cell lymphomas. *Ter Arkh.* 2008; 80(7):33-7. PMID:18763592