

The Role of Complex Treatment in Mixed Leg Ulcers – A Case Report of Vascular, Surgical and Physical Therapy

Uwe Wollina^{1*}, Birgit Heinig², Christian Stelzner³, Gesina Hansel¹, Jacqueline Schönlebe⁴, Georgi Tchernev^{5,6}, Torello Lotti⁷

¹Städtisches Klinikum Dresden, Department of Dermatology and Allergology, 01067 Dresden, Germany; ²Städtisches Klinikum Dresden - Center of Physical and Rehabilitative Medicine, Dresden, Germany; ³Städtisches Klinikum Dresden - Department of Internal Medicine II, Angiology Unit, Dresden, Sachsen, Germany; ⁴Städtisches Klinikum Dresden - Institute of Pathology "Georg Schmorl", Dresden, Germany; ⁵Department of Dermatology, Venereology and Dermatologic Surgery, Medical Institute of Ministry of Interior, and ⁶Onkoderma Policlinic for Dermatology and Dermatologic Surgery, Sofia, Bulgaria; ⁷Università Degli Studi "G. Marconi", Rome, Italy

Abstract

Citation: Wollina U, Heinig B, Stelzner C, Hansel G, Schönlebe J, Tchernev G, Lotti T. The Role of Complex Treatment in Mixed Leg Ulcers – A Case Report of Vascular, Surgical and Physical Therapy. Open Access Maced J Med Sci. 2018 Jan 25; 6(1):67-70. <https://doi.org/10.3889/oamjms.2018.023>

Keywords: Leg ulcer; Mixed vascular type; Sandwich transplantation; Percutaneous transluminal angioplasty; Transdermal CO₂; Surgery

***Correspondence:** Uwe Wollina, Städtisches Klinikum Dresden, Department of Dermatology and Allergology, 01067 Dresden, Germany. E-mail: wollina-uw@khdf.de

Received: 10-Aug-2017; **Revised:** 12-Nov-2017; **Accepted:** 29-Oct-2017; **Online first:** 01-Jan-2018

Copyright: © 2018 Uwe Wollina, Birgit Heinig, Christian Stelzner, Gesina Hansel, Jacqueline Schönlebe, Georgi Tchernev, Torello Lotti. This is an open-access article distributed under the terms of the Creative Commons Attribution-NonCommercial 4.0 International License (CC BY-NC 4.0)

Funding: This research did not receive any financial support

Competing Interests: The authors have declared that no competing interests exist

BACKGROUND: Leg ulcers are a burden to patients, their families and society. The second most common cause of chronic leg ulcers is the mixed arterio-venous type. An 80-year-old female patient presented to our department due to painful enlarging chronic leg ulcer of mixed arteriovenous origin on her left lower leg. She suffered from peripheral arterial occlusive disease stage I and chronic venous insufficiency Widmer grade IIIa, and a number of comorbidities.

AIM: The aim of our ulcer treatment was a complete and stable wound closure that was hampered by arterial occlusion, exposed tendon, and renal insufficiency.

CASE REPORT: To improve the prognosis for ulcer surgery, we performed percutaneous transluminal angioplasty, transcutaneous CO₂ and deep ulcer shaving. The wound was closed by sandwich transplantation using elastin-collagen dermal template and meshed split skin graft. She had a 100% graft take with rapid reduction of severe wound pain.

CONCLUSION: Complex approaches are necessary, to gain optimum results in leg ulcer therapy in mixed leg ulcers. Therapeutic nihilism should be abandoned.

Introduction

Leg ulcers are among the most common conditions seen in dermatologic department. Patients often present with chronic and disabling wounds. The spectrum of underlying disease causing leg ulcers is remarkably broad, although the most common cause in Western countries is chronic venous insufficiency (CVI). The second commons are mixed venous-arterial ulcers [1].

Leg ulcers are a symptom of an underlying chronic cause. In every case, a search for the underlying cause is necessary to provide the appropriate treatment for the patient. The pillars of

treatment are compression therapy, vascular surgery, leg ulcer shaving and transplantation. Smaller ulcers may heal by conservative treatment [2][3][4].

Leg ulcer surgery is based upon sufficient arterial blood supply, deep ulcer shaving to remove bacterial biofilm, avital tissue and necrosis, and fibrosis shifting a chronic non-healing wound into an acute wound with a better prognosis. Grafts to cover the wound can be made from the patient's own, uninjured skin (autografts), or applied as a sheet of bioengineered skin grown from donor cells (allograft). Preserved skin from other animals, such as pigs, has also been used (xenografts) [5].

The take rate after deep ulcer shaving and meshed grafts in venous and venous-arterial leg

ulcers was 91% in our own department but decreased down to 80% in case of dystrophic calcifications [3]. Other negative factors for graft take are insufficient shaving, extensive fibrosis, clotting disorders, immunosuppression, and predominant arterial ulcers [6] while the ulcer size is not predictive for graft failure [7].

But even in patients with arterial problems, successful leg ulcer shaving and grafting is possible with an interdisciplinary approach.

Case report

The 80-year-old female patient presented to our department due to painful enlarging chronic leg ulcer of mixed arteriovenous origin on her left lower leg. Leg ulcers were known for many years. Her medical history was remarkable for peripheral arterial occlusive disease stage I and chronic venous insufficiency Widmer grade IIIa [8]. In 2016, she underwent endovascular laser therapy of vena saphena magna and sclerotherapy of vena saphena parva.

Percutaneous transluminal angioplasty (PTA) was performed in March 2016 because of a relapsing stenosis of the distal arteria fibularis sinistra and the arteria poplitea sinistra. In July 2016, PTA was repeated and stent-assisted recanalization was realized.

She suffered from atrial fibrillation treated by phenprocoumon and beta-blocker. In 2016 she had a cardiac decompensation with pleural effusions due to a highly stenotic aortic valve. She got a synthetic aortic valve in November 2016 in combination with a bypass surgery for 2-vessel coronary stenosis.

She also suffered from chronic renal insufficiency stage III and coxarthrosis of right hip joint. Contact sensitization to para-phenylenediamine, lanoline, benzoyl peroxide, and chlorhexidine-digluconate had been confirmed by patch tests.

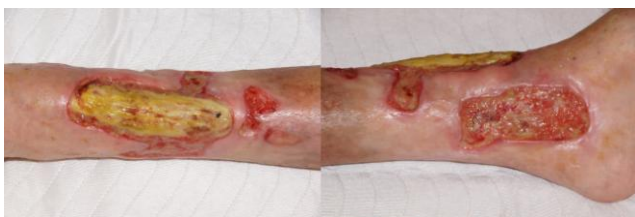

Figure 1: Clinical presentation of mixed arteriovenous leg ulcers of the left lower leg

On examination, we found a 14 x 7 cm large pretibial leg ulcer with exposed tendon. There was a second ulcers of 10 x 7 cm size above the left

malleolus medialis (Fig. 1 a & b). Both ulcers had a malodorous wound covering. Surrounding skin was erythematous, scaly and xerotic. Pain was 9 on the visual pain scale. We took a biopsy to exclude a malignant ulcer and other differential diagnoses such as calciphylaxis (Fig. 2). Histopathology revealed nonspecific changes.

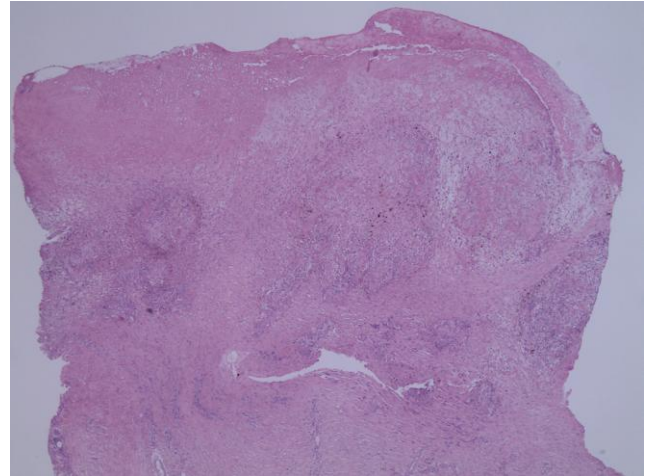


Figure 2: Histopathology of the biopsy from the leg ulcer showing nonspecific inflammation and ulceration (HE x 4)

Microbiological swabs from the wound revealed two strains of *Staphylococcus aureus* and *Corynebacterium striatum*.

An arterial vascular investigation showed a systemic blood pressure of 155/90 mmHg on the left side.

Closure pressure of the arteria tibialis posterior before treatment was 90 mmHg (right leg) and due to the ulceration it could not be assessed on the left leg, closure pressure of arteria dorsalis pedis was 95 mmHg (right leg) and 70 mmHg (left leg). The ankle-brachial pressure index (ABPI) was 0.86 on the right side and 0.64 on the left side.

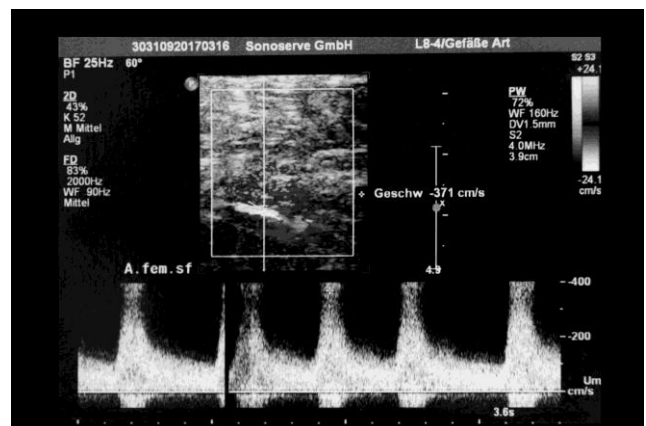


Figure 3: Duplex sonography of left A. femoralis superficialis

Using Duplex sonography, a high-grade stenosis of the left distal in distal arteria femoralis superficialis (V_{max} 350 cm/s) was observed. Another

stenosis was found in arteria poplitea at the transition P2/P3 (Fig. 3).

PTA was successfully performed before leg ulcer surgery.

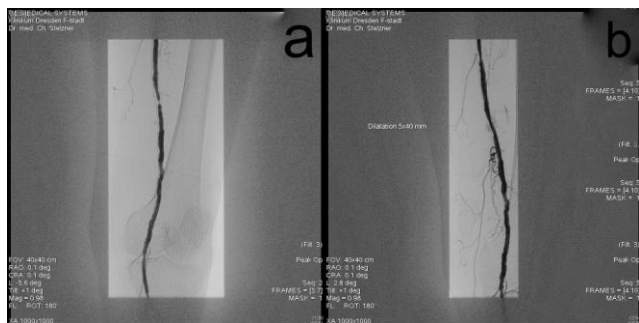

Figure 4: Angiography of A. femoralis superficial of the left leg before and after PTA

After PTA, closure pressure of the arteria tibialis posterior was 140 mmHg (right leg) and 160 mmHg (left leg), closure pressure of arteria dorsalis pedis was 140 mmHg on both sides. The ankle-brachial pressure index (ABPI) was 0.9 on the right side and 1.03 on the left side.

Acral light plethysmogram demonstrated on both legs powerful post stenotic curves. It also excluded a relapse after endovascular laser therapy.

We decided to perform deep ulcer shaving in combination with sandwich meshed graft transplantation in general anesthesia. The ulcers were conditioned with anti-septic wound covers (Cutimed sorbact gauze, Cutimed sorbact hydroactive dressing), multiple necrosectomies, and daily transcutaneous application of CO₂ for 30 min [9].

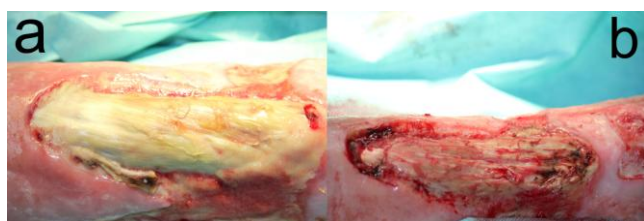


Figure 5: Aggressive surgical debridement of the leg ulcer: (a) before and (b) after the procedure

Ulcer surgery was realized in May 2017 with antibiotic prophylaxis (Unacid 3 g i.v./day for one week followed by Unacid PD oral tablets 2 x 2/day for 10 days). Using an electrodermatome, all necrotic and avital tissue was removed. Exposed tendon was completely covered by dermal template (Matriderm®, Dr. Suwelack Skin and Healthcare Ltd., Billerbeck, Germany). Eventually, the meshed graft was fixed by tissue tacker. We used silicone Adaptic touch above the grafts and sterile gauze compresses before compression bandages were applied.

Five days after surgery the transplant was stable but the wound ground was wet. To stabilize the

graft topical treatment with Betaisodona solution, Cutimed sorbact gauze, and Adaptic touch silicone gauze was performed on a daily basis. Surrounding skin was treated initially with a combination of betamethasone and fusidinic acid (Fucicort ointment) and later on by moisturizer (Dermatop basic cream). The leg ulcers healed completely (Fig. 6). The pain was rated 2 on the visual pain scale.

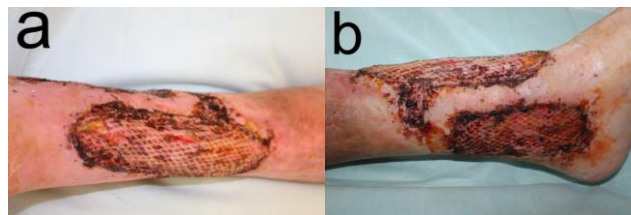


Figure 6: Stable and complete meshed-graft take on day 11 after surgery

We recommended a lower leg flat knitted compression stocking, compression class I.

Discussion

Chronic leg ulcers are a great burden for the individual patient and society. Pain reduction and infection control are major targets in leg ulcer treatment [10]. Despite the fact that most patients are treated conservative by various dressings, ointments, physical therapies, and compression the outcome of patients who underwent surgery is the most favorable regarding the need for additional treatment and evidence of post-intervention claims for symptomatic varicose veins [11].

In contrast to patients with venous leg ulcers, patients with mixed leg ulcers are significantly older, have lower body mass index, a history of smoking, and more comorbid conditions. Ulcer pain is highly prevalent. Mixed arteriovenous leg ulcers were associated with lower health related quality of life, greater mobility impairments, and more deficits in self-care and usual activities [12].

In the present case a symptomatic stenosis of infrapopliteal arteries was evident. We performed a PTA in our Department of Angiology. Meta-analyses of infra-popliteal PTA show technical success rates of up to 90% [13][14]. Leg ulcer healing rates, however, are not improved by primary stent implantation [15][6].

In case of exposed tendons, however, the take rate of skin grafts is low. We developed a sandwich technique to overcome this problem. A dermal template consisting of non-crosslinked collagen and elastin (Matriderm) is used to cover the tendon. After reconstitution of the template by Ringer's solution, a meshed skin graft is placed

above. The dermal template supports a rapid neoangiogenesis and pretends the adhesion of the graft to the tendon itself [17][18].

Using PTA at first place allows leg ulcer surgery in mixed arteriovenous leg ulcers with arterial stenosis. Sandwich transplantation is capable to cover wound with exposed tendons. After PTA, mild compression ensures an optimal healing.

References

- Jockenhöfer F, Gollnick H, Herberger K, Isbary G, Renner R, Stücker M, Valesky E, Wollina U, Weichenthal M, Karrer S, Kuepper B, Roesch A, Dissemond J. Aetiology, comorbidities and cofactors of chronic leg ulcers: retrospective evaluation of 1 000 patients from 10 specialised dermatological wound care centers in Germany. *Int Wound J*. 2016; 13:821-8. <https://doi.org/10.1111/iwj.12387> PMID:25483380
- O'Meara S, Cullum N, Nelson EA, Dumville JC. Compression for venous leg ulcers. *Cochrane Database Syst Rev*. 2012; 11:CD000265. <https://doi.org/10.1002/14651858.CD000265.pub3>
- Wollina U, Hasenöhr K, Köstler E, Schönlebe J, Heinig B, Haroske G, Kittner T. Dystrophic calcification in chronic leg ulcers--a clinicopathologic study. *Dermatol Surg*. 2009; 35:457-61. <https://doi.org/10.1111/j.1524-4725.2009.01064.x> PMID:19243405
- Wollina U, Unger L, Stelzner C, Machetanz J, Schellong S. Ulcus cruris. *Internist (Berl)*. 2013; 54:1323-9. <https://doi.org/10.1007/s00108-013-3342-4> PMID:24005788
- Jones JE, Nelson EA, Al-Hity A. Skin grafting for venous leg ulcers. *Cochrane Database Syst Rev*. 2013; (1):CD001737. <https://doi.org/10.1002/14651858.CD001737.pub4>
- Reich-Schupke S, Schmeil I, Kreuter A, Bechara F, Hoffmann K, Altmeyer P, Stücker M. Insufficient and incomplete shaving in chronic venous leg ulcers leads to a poor prognosis of the skin graft: a histomorphological analysis. *Dermatology*. 2011;223:87-92.
- Abisi S, Tan J, Burnand KG. Excision and meshed skin grafting for leg ulcers resistant to compression therapy. *Br J Surg*. 2007; 94:194-7. <https://doi.org/10.1002/bjs.5619> PMID:17152081
- Widmer LK, Stähelin HB, Nissen C, Da Silva A (eds) *Venen-, Arterien-Krankheiten, koronare Herzkrankheit bei Berufstätigen. Prospektiv-epidemiologische Untersuchung. Basler Studien I-III*, 1995–1978. Bern: Huber, 1981.
- Wollina U, Heinig B, Uhlemann C. Transdermal CO2 application in chronic wounds. *Int J Low Extrem Wounds*. 2004; 3:103-6. <https://doi.org/10.1177/1534734604265142> PMID:15866797
- Catanzano O, Docking R, Schofield P, Boateng J. Advanced multi-targeted composite biomaterial dressing for pain and infection control in chronic leg ulcers. *Carbohydr Polym*. 2017; 172:40-8. <https://doi.org/10.1016/j.carbpol.2017.05.040> PMID:28606546
- Mallick R, Raju A, Campbell C, Carlton R, Wright D, Boswell K, Eaddy M. Treatment patterns and outcomes in patients with varicose veins. *Am Health Drug Benefits*. 2016; 9:455-65. PMID:28465773 PMID:PMC5394556
- Marin JA, Woo KY. Clinical characteristics of mixed arteriovenous leg ulcers: A descriptive study. *J Wound Ostomy Continence Nurs*. 2017; 44:41-7. <https://doi.org/10.1097/WON.0000000000000294> PMID:28060003
- Romiti M, Albers M, Brochado-Neto FC, Durazzo AE, Pereira CA, De Luccia N. Meta-analysis of infrapopliteal angioplasty for chronic critical limb ischemia. *J Vasc Surg*. 2008; 47:975-81. <https://doi.org/10.1016/j.jvs.2008.01.005> PMID:18372148
- Morris-Stiff G, Moawad M, Appleton N, Davies G, Hicks E, Davies C, Lewis MH. Long-term clinical outcome following lower limb arterial angioplasty. *Ann R Coll Surg Engl*. 2011; 93:250-4. <https://doi.org/10.1308/147870811X566394> PMID:21477442 PMID:PMC3291146
- Brodmann M, Froehlich H, Dorr A, Gary T, Portugaller RH, Deutschmann H, Pilger E. Percutaneous transluminal angioplasty versus primary stenting in infrapopliteal arteries in critical limb ischemia. *Vasa*. 2011; 40:482-90. <https://doi.org/10.1024/0301-1526/a000152> PMID:22090182
- Randon C, Jacobs B, De Ryck F, Vermassen F. Angioplasty or primary stenting for infrapopliteal lesions: results of a prospective randomized trial. *Cardiovasc Intervent Radiol*. 2010; 33:260-9. <https://doi.org/10.1007/s00270-009-9765-6> PMID:19957178
- Wollina U. One-stage reconstruction of soft tissue defects with the sandwich technique: Collagen-elastin dermal template and skin grafts. *J Cutan Aesthet Surg*. 2011; 4:176-82. <https://doi.org/10.4103/0974-2077.91248> PMID:22279382 PMID:PMC3263127
- Wollina U, Meseg A, Weber A. Use of a collagen-elastin matrix for hard to treat soft tissue defects. *Int Wound J*. 2011; 8:291–6. <https://doi.org/10.1111/j.1742-481X.2011.00785.x> PMID:21449935