

Sarcoidosis in A. C. Milan (1899)?

Georgi Tchernev^{1,2*}, Torello Lotti³, Uwe Wollina⁴, José Carlos Cardoso⁵, Lyubomira Viktor Popova⁶, Georgi Konstantinov Maximov¹, Ilia Lozev⁷, Ivan Terziev⁸

¹Medical Institute of Ministry of Interior (MVR), Department of Dermatology, Venereology and Dermatologic Surgery, Sofia, Bulgaria; ²"Onkoderma" - Polyclinic for Dermatology and Dermatologic Surgery, Sofia, Bulgaria; ³University G. Marconi of Rome - Dermatology and Venereology, Rome, Italy; ⁴Städtisches Klinikum Dresden - Department of Dermatology and Allergology, Dresden, Sachsen, Germany; ⁵Dermatology Department, Coimbra Hospital and University Center, Praceta Mota Pinto, Coimbra, Portugal; ⁶Saint Kliment Ohridski University, Sofia, Bulgaria; ⁷Medical Institute of Ministry of Interior, Department of General, Vascular and Abdominal Surgery, General Skobelev 79, 1606 Sofia, Bulgaria; ⁸Medical Institute of Ministry of Interior, Department of General, Vascular and Abdominal Surgery, General Skobelev 79, 1606 Sofia, Bulgaria

Abstract

Citation: Tchernev G, Lotti T, Wollina U, Cardoso JC, Popova LV, Maximov GK, Lozev I, Terziev I. Sarcoidosis in A. C. Milan (1899)? Open Access Maced J Med Sci. <https://doi.org/10.3889/oamjms.2018.049>

Keywords: Sarcoidosis; Sarcoid - type reaction; Cutaneous granuloma; Molecular mimicry; Tattoo; Exogenous pigment

***Correspondence:** Georgi Tchernev. Department of Dermatology, Venereology and Dermatologic Surgery, Medical Institute of Ministry of Interior (MVR-Sofia), General Skobelev 79, 1606 Sofia, Bulgaria; Onkoderma - Polyclinic for Dermatology, Venereology and Dermatologic Surgery, General Skobelev 26, 1606, Sofia, Bulgaria. E-mail: georgi_tchernev@yahoo.de

Received: 02-Nov-2017; **Revised:** 17-Nov-2017; **Accepted:** 20-Oct-2017; **Online first:** 13-Jan-2018

Copyright: © 2018 Georgi Tchernev, Torello Lotti, Uwe Wollina, José Carlos Cardoso, Lyubomira Viktor Popova, Georgi Konstantinov Maximov, Ilia Lozev, Ivan Terziev. This is an open-access article distributed under the terms of the Creative Commons Attribution-NonCommercial 4.0 International License (CC BY-NC 4.0)

Funding: This research did not receive any financial support

Competing Interests: The authors have declared that no competing interests exist

The pathogenesis, diagnosis and therapy of sarcoidosis as an autonomous disease are subjects of spirited discussions, which haven't found definitive conclusion yet. Distinguishing between sarcoidosis and sarcoid-like reactions (sarcoid - type granulomas) is not currently a medical "gold standard" and is not implemented in clinical practice. This leads to 1) misinterpretation of numerous available data; 2) difficulty in the interpretation of other unverified data, which is often followed by 3) inappropriate or inadequate therapeutic approach. Similarly to many other diseases, in sarcoidosis and sarcoid - types of reactions the concept of personalised approach and therapy should also be introduced. This methodology of clinical guidance is difficult, complex and not always achievable in the current medical status and relations (doctor-patient relationship; financial factor; time factor). It is appropriate to note that in some cases the guidelines or the so-called standards are neglected or not possible to put into practice with the aim of better therapeutic practices and strategies, as well as the achievement of optimal final clinical results (especially in patients with sarcoid granulomas). The sarcoid granuloma, even when it is sterile, should not be considered as the equivalent of sarcoidosis, i.e., sarcoidosis as an autonomous disease. Sure enough, exactly because of this fact, the personalised approach should not be an exception, but it has to gradually become a rule in medical practice. When clinical decisions are conformed to some of the latest modern concepts, officialised in the international databases, often the achieved results can be much better.

We present a patient with a tattoo of AC Milan (1899) on his right arm, who subsequently developed localised sterile sarcoid granulomas in the area of the tattoo. Later the process became generalised on his whole body's skin, lungs and lymph nodes. It is unclear for the moment whether this condition should be interpreted as sarcoidosis as an autonomous disease or, instead, as a sarcoidal type of reaction with subsequent generalisation due to cross-reactivity against antigens present in other tissues with similarities to the exogenous pigments. Following the modern concepts regarding the pathogenesis of these two conditions, we introduced, in this case, an innovative, non-standard approach: 1) systemic and local immunosuppressive therapy, combined with 2) recommendation for immediate surgical excision of the tattoo to remove the possible trigger of molecular and antigen mimicry.

Introduction

At the current stage of knowledge the definition of sarcoidosis as an autonomous disease, as well as the differentiation between sarcoidosis and sarcoid - type reactions, remain unclear and a serious clinical and diagnostic challenge [1].

An accurate distinction between these two concepts is crucial because it presumes completely

different clinical behaviour and therapeutic strategies [2]. On the other hand, it is a very serious question whether the term sarcoidosis has to be reconsidered as a non-autonomous disease but rather as a reaction pattern [3].

We present an interesting patient with histopathologically - proven sarcoid granulomas and discuss the possible pathogenetic relationship between the disturbance of tissue homeostasis and granuloma formation.

Case report section

Anamnesis

A 42 – year - old male patient presented to the department of dermatologic surgery due to a rash on his right thigh. Pruritus leading to scratching and bleeding was reported as a subjective complaint. The symptoms occurred one year and a half after performing a tattoo with the logo of the football team AC Milan (1899). The patient noticed thickening of the skin under the blazon, exactly in the area of the red pigment, which had started to disappear (Fig.1 a).

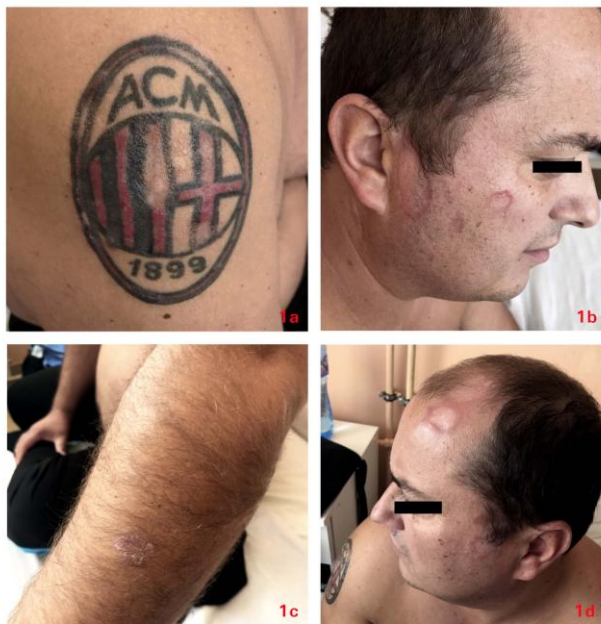

Figure 1: a – Thickening of the skin under the blazon, coinciding with the area of the red pigment, which has started to disappear

The patient had histologically proven cutaneous sarcoidosis from 03/2014. Therapy with methylprednisolone 60mg/day, with gradual tapering of the dose, was started. In 02/2015 systemic sarcoidosis was additionally proved histologically after a biopsy of endobronchial granulations. Throughout several months, dermatologic and pulmonary consultations were performed as well as control CT and chest radiography. Meanwhile, the dosage of methylprednisolone was slowly reduced or increased according to disease fluctuations. According to the more recent data, methylprednisolone was prescribed in the following doses: 01-03/2017 x 15 mg/d; 04-06/2017 x 10 mg/d; 06-09/2017 x 5 mg/d.

In 09/2016, treatment with methotrexate at a dose of 20 mg weekly was prescribed for six months, followed by reduction of the dose to 10 mg weekly until 09/2017 when the treatment was suspended. By the regular follow-up tests, the treatment mentioned above was considered inefficient.

QuantiFERON test and serological tests (anti-

HCV and HBsAg) were negative.

Physical examination

Disseminated annular lesions with the atrophic centre and raised edges, well demarcated from the surrounded skin were observed on the scalp, face, trunk and upper limbs (Fig.1 b, c, d). Enlarged inguinal lymph nodes were identified by palpation.

Ancillary tests

Laboratory tests revealed elevated ESR – 18 mm/h (< 11 mm/h); WBC - 31.0/l (3.5 - 10.5/l); Crystal - 9.0/l (-); Plasma uric acid - 526.0 mol/l (< 410 mol/l). Microbiological analysis of a skin swab identified *S. aureus*, sensitive to amoxicillin, cefuroxime, ciprofloxacin and clindamycin.

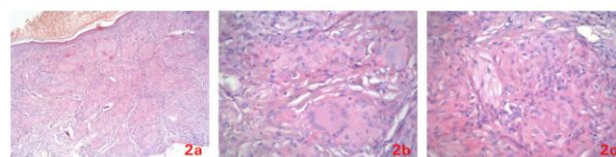


Figure 2: Radiographic images taken in the last 15 months show relatively stable pulmonary findings, which persist in spite of the systemic treatment

Chest radiography detected bilateral hilar enlargement with irregular borders, consistent with hilar lymphadenopathy (Fig. 2). An infiltrate with perihilar paracardial localisation could not be excluded. Horizontal linear opacities between the medium and lower lobes of the right lung were also reported (Fig. 3).

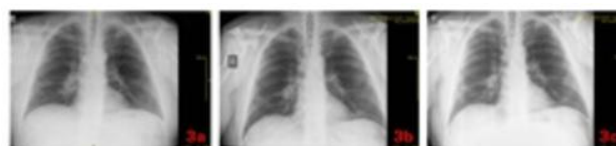

Figure 3: a, b, c - Chest radiography detected bilateral hilar enlargement with irregular borders, which can be associated with hilar lymphadenopathy. An infiltrate with perihilar paracardial localisation cannot be excluded. Horizontal linear opacities between the medium and the lower lobes of the right lung were also observed

Ultrasound examination revealed splenomegaly and enlarged bilateral inguinal lymph nodes as well as enlarged cervical lymph nodes on the right side of the neck, dorsal to the sternocleidomastoid muscle. Echocardiography detected upper-bound volume on the left ventricle, right ventricle dilatation and elevated pulmonary artery pressure in the right atrium. Biopsy from 10/2017 revealed sarcoid granulomas. After endocrinology consultation, the patient was diagnosed with hyperuricemia and started therapy with allopurinol.

Treatment and outcome

To eradicate the infectious process he underwent treatment with ciprofloxacin 100mg 2 x 2/d i.v. and local dressings with Jodasept® unguent, resulting in successful results.

The patient was diagnosed with skin and systemic sarcoidosis. According to the clinical consultations he performed, treatment was inefficient and did not lead to any significant improvement of the pulmonary changes. Furthermore, the progression of the cutaneous lesions of sarcoidosis was observed. Therefore, a therapy with methylprednisolone 60 mg/d i.v. and azathioprine 2 x 50 mg/d for three days was prescribed. The ambulatory treatment proceeded with methylprednisolone 40 mg/d with a dose reduction of 4 mg per week; azathioprine 50 mg 2 x 1/d; esomeprazole 40 mg/d and local application of pimecrolimus 1%/15 g cream 2 x /d. Also, the patient was referred to a plastic and reconstructive surgery department for surgical excision of his tattoo to permanently remove the exogenous pigment.

Discussion

Once more, we focus the attention of our colleagues and the dermatologic community on the pathogenesis of sarcoidosis, still defined as an “autonomous disease”, a concept that, in our opinion, should be reconsidered. A sarcoid granuloma is not equivalent to the disease sarcoidosis because it is observed as a result of 1) possible paraneoplastic manifestation, resulting from cross-reaction between antigens of the self and cancer antigens; 2) reaction pattern (cross-mediated or direct immunity) against several microbiological agents [1]. Is sarcoidosis such a wide-spectrum disease?

One of the difficulties in distinguishing sarcoidosis as an autonomous disease from sarcoidal-type reactions comes from their main common feature, which is the presence of epithelioid cell granulomas [3]. However, there is no “gold standard” for systematic diagnostic approach and prediction of clinical behaviour in cases of histologically proven epithelioid cell granulomas [4]. The definition of sarcoidosis states that it is a disease characterised by the presence of non - caseating epithelioid cell granulomas in several organs and tissues [5]. By definition, granulomas in sarcoidosis are sterile, so the presence of any identifiable immunogenic triggering agents makes it more accurate to refer to this reaction as a sarcoidal type of reaction pattern [6][7]. In our opinion, sterile sarcoid granuloma should not equate to sarcoidosis disease. The triggering mechanisms that induce sarcoid-like reactions may be categorized as following: 1) local reaction to infectious agents (leprosy, atypical

mycobacterial infections, deep fungal reactions, etc.) [8][9][10]; 2) noninfectious but immunogenic antigens (inorganic compounds) [11][12]; 3) tumors (paraneoplastic sarcoid type of reaction) [13][14]. Our concepts of sarcoid - type reaction are based on the assumption that it may be provoked, in predisposed patients, by cross-reaction to immunogens or tumour antigens, so its pathogenesis is closely related to the generation of cross - mediated immunity presenting as molecular (antigen) mimicry. This phenomenon occurs by the similarity between certain amino acid sequences in the triggering antigens and molecular structures in the body [15]. The precise distinction between these two terms is extremely important because misdiagnosis may lead to the introduction of inappropriate treatment. Immunosuppressive therapy, which is recommended as first-line treatment for sarcoidosis, can enhance a tumour or infectious progression in patients afflicted by those conditions, with all its deleterious consequences for the patient [16][17][18].

Blau syndrome (BS), for example, is a rare autosomal dominant autoinflammatory disease characterised by the clinical triad of dermatitis, arthritis, and uveitis. It is caused by mutations in nucleotide-binding oligomerisation domain-containing protein - 2 (NOD2) gene [19]. It is unclear whether and to what extent this autoinflammatory syndrome overlaps with congenital or early-onset sarcoidosis, which is most probably genetically determined [20]. It is a somewhat disturbing fact that the mechanism of granuloma formation in these patients is completely different from the one that originates similar types of granulomas in patients with certain forms of cancer or deep mycosis. Sarcoid granulomas are obviously the final result of diverse pathogenic mechanisms, which are, in turn, activated by different specific diseases [1][21].

Would it be accurate to define existing sarcoidosis as a disease occurring by 1) congenital genetic defect; 2) paraneoplastic reaction; 3) parainfectious or infectious disease, as well as the incorporation of inorganic material via inhalation or skin contact?

According to our observations, sarcoid-like reactions could be determined by the capability of the organism (or a genetically determined predisposition) for reacting against different kinds of antigens. These antigens could be either exogenously incorporated into the body or generated by the tissue homeostasis (de novo) as seen in the process of carcinogenesis. This abnormality of tissue homeostasis is the main trigger of sarcoid-like reactions [22]. Thus, clinicians should be cautious in the approach to this kind of reactions. In case of a histological diagnosis of sarcoid granulomas, it is of great importance to exclude: 1) different forms of tumours; 2) infectious diseases with diverse origin. Following the standard definition of sarcoidosis and starting immunosuppressive therapy may lead to a significant

risk of potentiating cancer progression or worsening of an underlying infection, which may have fatal consequences, as we already unravelled.

In conclusion, we consider the present case of a patient with a sarcoid-like reaction secondary to a tattoo, as an illustrative example of our theory of antigen mimicry as the mechanism leading to granuloma formation in genetically predisposed individuals. The persistence of symptoms in spite of treatment with corticosteroids followed by methotrexate in combination with corticosteroids is not unique in the setting of sarcoidosis or sarcoid type reactions. In such patients, we hypothesise that it is of vital importance to eliminate the trigger of molecular mimicry, which may potentially lead to normalization of the tissue homeostasis and the immune response. It remains an open question: Sarcoidosis – does it exist?

References

- James DG. A clinicopathological classification of granulomatous disorders. *Postgraduate Medical Journal*. 2000; 76:457-465. <https://doi.org/10.1136/pmj.76.898.457> PMID:10908370 PMCid:PMC1741697
- Tchernev G, Chokoeva AA, Schiavone C, D Erme AM, Tana C, Darling M, Kaley J, Gianfaldoni S, Wollina U, Lotti T, Patterson JW. Sarcoidosis exclusion criteria: the "simple truth" for a "complicated diagnosis". *J Biol Regul Homeost Agents*. 2015; 29(1 Suppl):5-9. PMID:26016958
- Tchernev G, Tana C, Schiavone C, Cardoso JC, Ananiev J, Wollina U. Sarcoidosis vs. Sarcoid-like reactions: The Two Sides of the same Coin? *Wien Med Wochenschr*. 2014; 164(13-14):247-59. <https://doi.org/10.1007/s10354-014-0269-x> PMID:24664574
- Mukhopadhyay S, Gal AA. Granulomatous Lung Disease: An Approach to the Differential Diagnosis. *Archives of Pathology & Laboratory Medicine*. 2010; 134(5): 667-690. PMID:20441499
- Mitchell DN, Scadding JG, Heard BE, Hinson KF. Sarcoidosis: histopathological definition and clinical diagnosis. *Journal of Clinical Pathology*. 1977; 30(5):395-408. <https://doi.org/10.1136/jcp.30.5.395> PMID:325017 PMCid:PMC476430
- Bonham CA, Streck ME, Patterson KC. From granuloma to fibrosis: sarcoidosis associated pulmonary fibrosis. *Current opinion in pulmonary medicine*. 2016; 22(5):484-491. <https://doi.org/10.1097/MCP.0000000000000301> PMID:27379967 PMCid:PMC5532138
- Tchernev G, Cardoso JC, Chokoeva AA, Verma SB, Tana C, Ananiev J, Gulubova M, Philipov S, Kanazawa N, Nenoff P, Lotti T, Wollina U. The "mystery" of cutaneous sarcoidosis: facts and controversies. *Int J Immunopathol Pharmacol*. 2014; 27(3):321-30. <https://doi.org/10.1177/039463201402700302> PMID:25280023
- Brownell I, Ramírez-Valle F, Sanchez M, Prystowsky S. Evidence for Mycobacteria in Sarcoidosis. *American Journal of Respiratory Cell and Molecular Biology*. 2011; 45(5):899-905. <https://doi.org/10.1165/rcmb.2010-0433TR> PMID:21659662
- PMCid:PMC3361363
- Moravvej H, Vesal P, Abolhasani E, Nahidi S, Mahboudi F. Comorbidity of Leishmania Major with Cutaneous Sarcoidosis. *Indian Journal of Dermatology*. 2014; 59(3):316. <https://doi.org/10.4103/0019-5154.131453> PMID:24891680 PMCid:PMC4037970
- Pierce TB, Margolis M, Razzuk MA. Sarcoidosis: still a mystery? *Proceedings (Baylor University Medical Center)*. 2001; 14(1):8-12. <https://doi.org/10.1080/08998280.2001.11927724>
- Newman KL, Newman LS. Occupational Causes of Sarcoidosis. *Current opinion in allergy and clinical immunology*. 2012; 12(2):145-150. <https://doi.org/10.1097/ACI.0b013e3283515173> PMID:22314258 PMCid:PMC4196683
- Williams WJ, Williams D. "Residual bodies" in sarcoid and sarcoid-like granulomas. *J Clin Pathol*. 1967; 20(4):574-7. <https://doi.org/10.1136/jcp.20.4.574>
- Balasubramaniam SC, Salomão DR, Davies JB, Ramsay RC, Habermann TM, Chow GK, Boorjian SA, Pulido JS. Paraneoplastic sarcoid-like reactions and the eye. *Retina*. 2015; 35(4):789-97. <https://doi.org/10.1097/IAE.0000000000000429> PMID:25526097
- Cohen PR, Kurzrock R. Sarcoidosis and malignancy. *Clin Dermatol*. 2007; 25(3):326-33. <https://doi.org/10.1016/j.clindermatol.2007.03.010> PMID:17560310
- Oldstone MB. Molecular mimicry, microbial infection, and autoimmune disease: evolution of the concept. *Curr Top Microbiol Immunol*. 2005; 296:1-17. https://doi.org/10.1007/3-540-30791-5_1
- Beegle SH, Barba K, Gobunsuy R, Judson MA. Current and emerging pharmacological treatments for sarcoidosis: a review. *Drug Design, Development and Therapy*. 2013; 7:325-338. PMID:23596348 PMCid:PMC3627473
- Penn I, Starzl TE. The Effect of Immunosuppression on Cancer. *Proceedings National Cancer Conference*. 1972; 7:425-436. PMID:4587653 PMCid:PMC3079479
- Orlicka K, Barnes E, Culver EL. Prevention of infection caused by immunosuppressive drugs in gastroenterology. *Therapeutic Advances in Chronic Disease*. 2013; 4(4):167-185. <https://doi.org/10.1177/2040622313485275> PMID:23819020 PMCid:PMC3697844
- Wouters CH, Maes A, Foley KP, Bertin J, Rose CD. Blau Syndrome, the prototypic auto-inflammatory granulomatous disease. *Pediatric Rheumatology Online Journal*. 2014; 12:33. <https://doi.org/10.1186/1546-0096-12-33> PMID:25136265 PMCid:PMC4136643
- Okafuji I, Nishikomori R, Kanazawa N, Kambe N, Fujisawa A, Yamazaki S, Saito M, Yoshioka T, Kawai T, Sakai H, Tanizaki H, Heike T, Miyachi Y, Nakahata T. Role of the NOD2 genotype in the clinical phenotype of Blau syndrome and early-onset sarcoidosis. *Arthritis Rheum*. 2009; 60(1):242-50. <https://doi.org/10.1002/art.24134> PMID:19116920
- Celada LJ, Hawkins C, Drake WP. The etiologic role of infectious antigens in sarcoidosis pathogenesis. *Clinics in chest medicine*. 2015; 36(4):561-568. <https://doi.org/10.1016/j.ccm.2015.08.001> PMID:26593133 PMCid:PMC4660257
- Robinson LA, Smith P, SenGupta DJ, Prentice JL, Sandin RL. Molecular analysis of sarcoidosis lymph nodes for microorganisms: a case-control study with clinical correlates. *BMJ Open*. 2013; 3(12):e004065. <https://doi.org/10.1136/bmjopen-2013-004065> PMID:24366580 PMCid:PMC3884606