

# Chronic Encapsulated Seroma Persisting for Three Years after Abdominoplasty and a Successful Surgical Solution

Alberto Goldman<sup>1</sup>, Uwe Wollina<sup>2\*</sup>, Katlein França<sup>3</sup>, Georgi Tchernev<sup>4,5</sup>, Torello Lotti<sup>6</sup>

<sup>1</sup>*Clinica Goldman - Plastic Surgery Av. Augusto Meyer 163 conj.1203, Porto Alegre/RS, Brazil;* <sup>2</sup>*Städtisches Klinikum Dresden - Department of Dermatology and Allergology, Dresden, Sachsen, Germany;* <sup>3</sup>*University of Miami School of Medicine 1400 NW 10th Avenue, Miami, Florida 33136-1015, United States;* <sup>4</sup>*Department of Dermatology, Venereology and Dermatologic Surgery, Medical Institute of Ministry of Interior, Sofia, Bulgaria;* <sup>5</sup>*Onkoderma, Policlinic for Dermatology and Dermatologic Surgery, Sofia, Bulgaria;* <sup>6</sup>*University G. Marconi of Rome - Dermatology and Venereology, Rome, Italy*

## Abstract

**Citation:** Goldman A, Wollina U, França K, Tchernev G, Lotti T. Chronic Encapsulated Seroma Persisting for Three Years after Abdominoplasty and a Successful Surgical Solution. Open Access Maced J Med Sci. 2018 Jan 25; 6(1):82-84. <https://doi.org/10.3889/oamjms.2018.051>

**Keywords:** Pseudocapsule; Chronic seroma; Abdominoplasty; Capsulectomy; Surgery; Scarpa's fascia

**\*Correspondence:** Uwe Wollina. Städtisches Klinikum Dresden - Department of Dermatology and Allergology, Dresden, Sachsen, Germany. E-mail: [wollina-uw@khdf.de](mailto:wollina-uw@khdf.de)

**Received:** 02-Sep-2017; **Revised:** 29-Nov-2017; **Accepted:** 30-Nov-2017; **Online first:** 09-Jan-2018

**Copyright:** © 2018 Alberto Goldman, Uwe Wollina, Katlein França, Georgi Tchernev, Torello Lotti. This is an open-access article distributed under the terms of the Creative Commons Attribution-NonCommercial 4.0 International License (CC BY-NC 4.0)

**Funding:** This research did not receive any financial support

**Competing Interests:** The authors have declared that no competing interests exist

Abdominoplasty is listed among five most common esthetic surgical procedures in the Western World. Despite all efforts, abdominoplasty bears a high risk of complications. We observed a 39-year-old-woman with previous classical abdominoplasty performed elsewhere three years ago. Clinical examination demonstrated a swollen and tense abdominal mass. Laboratory findings were normal. Clinical examination was completed by abdominal ultrasonography which demonstrated both, a significant fluid volume in this area and a dense fibrous "capsule". The diagnosis was a late or chronic encapsulated seroma with a thick pseudocapsule or "bursa". We performed a revision abdominoplasty with a standard supra-fascial dissection. Surgical resection of infra-umbilical flap containing skin, subcutaneous tissue and capsulectomy were performed under general anaesthesia. A new umbilicus was created attaching small skin flaps in the muscular fascia. No drains were used. We observed no seroma formation. Follow up after six and ten months was unremarkable. The fibrous pseudocapsule of chronic seroma results in different degrees of deformities, abdominal scar deviation and asymmetry. Surgical capsulectomy combined with revision abdominoplasty with preservation of Scarpa's fascia and placement of progressive tension sutures resulted in being effective and leads an esthetic outcome without seroma recurrence.

## Introduction

Abdominoplasty is listed among is one the five most common esthetic surgical procedures in the Western World. Techniques, patients care and settings have been improved and modified in the last decades. Abdominoplasty is a measure of primary body shaping and has been additionally fueled by bariatric surgery [1].

Despite all efforts, abdominoplasty bears a higher risk of complications compared to other esthetic procedures. Scar problems, cutaneous flap necrosis, hematoma formation, infections, thrombo-

embolic events, and seroma formation are described in the surgical literature [2][3][4][5].

Seroma formation is among the most common complications and has been reported in about five to 50 % of cases [5]. A chronic seroma may develop later a fibrous encapsulation.

The reason for this is largely unknown. Interruption of lymphatic flow and shear forces between tissue layers were discussed as contributing factors. Nevertheless, encapsulation represents a severe complication after abdominoplasty [6]. In such a case, repeated aspiration does not achieve a complete remission. Instead of this, complete surgical removal is necessary.

## Case Report

A 39-year-old-woman with previous classical abdominoplasty performed elsewhere three years ago was referred to our surgical department with an enlargement of her abdominal region (Fig. 1a-c). According to the patient, three weeks after the surgery she experienced a palpable swelling in the surgical region. The clinical diagnosis was a seroma which was drained by aspiration by her surgeon. Five days after this initial aspiration a new seroma was drained. In the last three years, there was a continuous recurrence of seromas. She has undergone aspiration with the evacuation of the serous fluid numerous times.

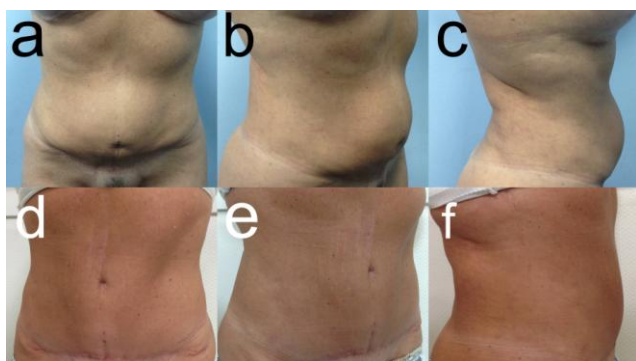


Figure 1: (a-c) A 39-year-old woman presenting for treatment of her abdominal projected region. Treatment results ten months later (d-f)

The patient arrived at our consultation with a projected aspect of her abdomen and with some flotation and aesthetic deformity. The enlargement of the region was evident upon clinical inspection without other signs or symptoms of inflammation or infection. The umbilicus was abnormally located (too low), and the entire aspect of the region was compromised. Clinical examination also demonstrated a swollen and tense abdominal region. Laboratory findings were normal. Abdominal ultrasonography demonstrated both, a significant fluid volume in this area and a dense fibrous “capsule”. The diagnosis was a chronic encapsulated seroma with a thick pseudocapsule or “bursa”. We performed an aspiration of approximately 540 mL of viscose serous and sanguine fluid. The liquid was sent to microbial examination, which revealed no contamination.

A revision abdominoplasty was performed with a standard supra-fascial dissection. Surgical resection of infra-umbilical flap containing skin, subcutaneous tissue and the entire capsule of the affected area was performed (capsulectomy under general anaesthesia) (Fig. 2). No muscular plication was done. Progressive tension sutures using Monocryl 4-0 suture were placed to avoid dead space [7].

A new umbilicus was created attaching small skin flaps in the muscular fascia. No drains were

used. Smooth dressings were applied during the next three weeks without compression.

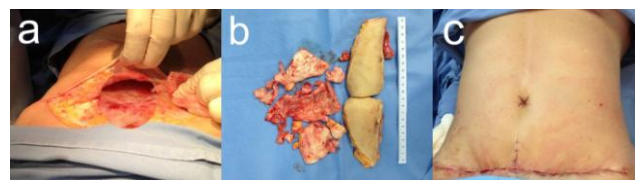


Figure 2: Surgical resection of an encapsulated late seroma of the abdomen. (a) Operation situs. (b) Infra-umbilical flap is containing skin, subcutaneous tissue and the entire capsule of the chronic seroma. (c) Final aspect with umbilicus reconstruction

We observed no complications such as wound hematoma, infection, dehiscence, or recurrence of seroma after revision surgery. Follow up after six and ten months was unremarkable (Fig. 1 d-f).

## Discussion

Postoperative seroma formation remains the most frequent complication following abdominoplasty. Usually seroma appears shortly after the abdominoplasty with a peak incidence eleven days after surgery [8].

If not detected or adequately treated, a fibrous pseudocapsule can develop that transforms the seroma into a chronic encapsulated condition. The seroma pseudocapsule is composed of fibrous tissue with eosinophilic hyaline degeneration of collagen and a mild inflammatory, predominantly lymphocytic, infiltration. It lacks an epithelium on its inner surface.

Differential diagnoses include hernias, chronic expanding organized hematoma, cystic lesions of epithelial, mesothelial, and other origin (germ cell tumors, sex cord gonadal stromal tumors, cystic mesenchymal tumors, fibrous wall tumors, and infectious cystic peritoneal lesions), lymphangiomas and posttraumatic oily pseudocysts [9][10][11]. The fibrous pseudocapsule of chronic seroma results in different degrees of deformities, abdominal scar deviation and asymmetry. Surgical capsulectomy was followed by revision abdominoplasty with preservation of Scarpa's fascia and placement of progressive tension sutures [7][12]. Thereafter special garments were used leading to an esthetic outcome without seroma recurrence.

Damage of lymphatic vessels of the abdominal wall muscular fascia probably affects lymphatic drainage in the undermined surface after a classical abdominoplasty [6]. The most frequently used method for decreasing early seroma frequency has probably been the use of closed suction drains. Several studies disclosed, however, that drains do not

result in a decreased seroma incidence [12]. In contrast, progressive tension sutures decreased the rate of seroma from 26% to 4% [13] and from 9% to 2% [14], respectively.

Other methods for reducing complications are described in the literature for seroma. Those recommendations include quilted sutures to reduce dead space and fibrin glue. In a meta-analysis covering 15 studies with > 1,800 patients, only the abdominoplasty with preservation of Scarpa's fascia or placement of progressive tension sutures was associated with a significantly reduced incidence of seroma compared with standard abdominoplasty. Abdominoplasty with the application of fibrin glue was similar to standard abdominoplasty regarding seroma development [15][16].

Although seromas usually resolve with multiple aspirations, some can often become chronic and lead to the development of a pseudocapsule or pseudobursa clinically apparent by (scar) asymmetry. This condition requires reoperation with complete resection of the entire compromised tissue [17][18]. As shown in our patient, the outcome after well-performed procedure is esthetically and functionally excellent.

## References

- Matarasso A, Matarasso DM, Matarasso EJ. Abdominoplasty: classic principles and technique. *Clin Plast Surg*. 2014; 41(4):655-72. <https://doi.org/10.1016/j.cps.2014.07.005> PMID:25283453
- Molitor M, Měšťák O, Popelka P, Vítová L, Hromádková V, Měšťák J. Pulmonary embolism after abdominoplasty – are we really able to avoid complications? Case report and literature review. *Acta Chir Plast*. Fall. 2016; 58(1):35-38.
- Winocour J, Gupta V, Ramirez JR, Shack RB, Grotting JC, Higdon KK. Abdominoplasty: risk factors, complication rates, and safety of combined procedures. *Plast Reconstr Surg*. 2015; 136(5):597e-606e. <https://doi.org/10.1097/PRS.0000000000001700> PMID:26505716
- Massenburg BB, Sanati-Mehrziy P, Jablonka EM, Taub PJ. Risk factors for readmission and adverse outcomes in abdominoplasty. *Plast Reconstr Surg*. 2015; 136(5):968-77. <https://doi.org/10.1097/PRS.0000000000001680> PMID:26505701
- Baroudi R, Ferreira A. Seroma: how to avoid it and how to treat it. *Aesthetic Surg J*. 1998; 18:439. [https://doi.org/10.1016/S1090-820X\(98\)70073-1](https://doi.org/10.1016/S1090-820X(98)70073-1)
- Roje Z, Roje Z, Karanović N, Utrobčić I. Abdominoplasty complications: a comprehensive approach for the treatment of chronic seroma with pseudobursa. *Aesthetic Plast Surg*. 2006; 30(5):611-5. <https://doi.org/10.1007/s00266-004-0142-1> PMID:16977373
- Ardehali B, Fiorentino F. A meta-analysis of the effects of abdominoplasty modifications on the incidence of postoperative seroma. *Aesthet Surg J*. 2017; 37(10):1136-43. <https://doi.org/10.1093/asi/sjx051> PMID:28482000
- Pollock H, Pollock T. Progressive tension sutures: a technique to reduce local complications in abdominoplasty. *Plast Reconstr Surg*. 2000 Jun;105(7):2583-6; discussion 2587-8. <https://doi.org/10.1097/00006534-200006000-00047> PMID:10845315
- Arraiza M, Metser U, Vajpeyi R, Khalili K, Hanbidge A, Kennedy E, Ghai S. Primary cystic peritoneal masses and mimickers: spectrum of diseases with pathologic correlation. *Abdom Imaging*. 2015; 40(4):875-906. <https://doi.org/10.1007/s00261-014-0250-6> PMID:25269999
- Wollina U. Posttraumatic painful subcutaneous oily cysts. *Cosmetic Medicine (International Issue)*. 2017; 3(1):25-6.
- Wollina U, Heinig B, Langner D. Chronic expanding organized hematoma of the lower leg: a rare cause for nonhealing Leg ulcers. *Int J Low Extrem Wounds*. 2015; 14(3):295-8. <https://doi.org/10.1177/1534734615571129> PMID:25691320
- Pollock TA, Pollock H. Progressive tension sutures in abdominoplasty: a review of 597 consecutive cases. *Aesthet Surg J*. 2012; 32(6):729-42. <https://doi.org/10.1177/1090820X12452294> PMID:22751080
- Macias LH, Kwon E, Gould DJ, Spring MA, Stevens WG. Decrease in seroma rate after adopting progressive tension sutures without drains: A single surgery center experience of 451 abdominoplasties over 7 years. *Aesthet Surg J*. 2016; 36(9):1029-35. <https://doi.org/10.1093/asi/sjw040> PMID:26977072
- Khan UD. Risk of seroma with simultaneous liposuction and abdominoplasty and the role of progressive tension sutures. *Aesthetic Plast Surg*. 2008;32(1):93-9; discussion 100. <https://doi.org/10.1007/s00266-007-9004-y> PMID:17849158
- Nasr MW, Jabbour SF, Mhaweji RI, Elkhoury JS, Sleilati FH. Effect of tissue adhesives on seroma incidence after abdominoplasty: A systematic review and meta-analysis. *Aesthet Surg J*. 2016; 36(4):450-8. <https://doi.org/10.1093/asi/sjv276> PMID:26821643
- Di Martino M, Nahas FX, Kimura AK, Sallum N, Ferreira LM. Natural evolution of seroma in abdominoplasty. *Plast Reconstr Surg*. 2015; 135(4):691e-8e. <https://doi.org/10.1097/PRS.0000000000001122> PMID:25811581
- Caulfield RH, Maleki-Tabrizi A, Khan F, Ramakrishnan V. A large encapsulated seroma presenting as a mass 5 years post paraumbilical hernia repair. *J Plast Reconstr Aesthet Surg*. 2009; 62(1):105-7. <https://doi.org/10.1016/j.bjps.2007.08.009> PMID:17933597
- di Summa PG, Wettstein R, Erba P, Raffoul W, Kalbermatten DF. Scar asymmetry after abdominoplasty: the unexpected role of seroma. *Ann Plast Surg*. 2013; 71(5):461-3. <https://doi.org/10.1097/SAP.0b013e3182503ad9> PMID:23143814