

Dynamic MRI Evaluation of the Gastric Fundus and Splenic Circulation to Assess the Gastric Breves Dissection during Laparoscopic Nissen Fundoplication

Gökhan Akkurt^{1*}, Önder Sürgit¹, Hakan Ataş¹, Mustafa Alimoğullari²

¹Keçiören Training Hospital Ankara, Ankara, Turkey; ²General Surgery Ankara, Ankara, Turkey

Abstract

Citation: Akkurt G, Sürgit Ö, Ataş H, Alimoğullari M. Dynamic MRI Evaluation of the Gastric Fundus and Splenic Circulation to Assess the Gastric Breves Dissection during Laparoscopic Nissen Fundoplication. Open Access Maced J Med Sci. <https://doi.org/10.3889/oamjms.2018.078>

Keywords: Magnetic resonance; Necrosis; Laparoscopic Nissen Fundoplication; Arteria Gastrica breves; Splenic perfusion

***Correspondence:** Gökhan Akkurt, Keçiören Training Hospital Ankara, Ankara, Turkey. E-mail: drakkurt06@gmail.com

Received: 17-Oct-2017; **Revised:** 11-Dec-2017; **Accepted:** 12-Dec-2017; **Online first:** 10-Feb-2018

Copyright: © 2018 Gökhan Akkurt, Önder Sürgit, Hakan Ataş, Mustafa Alimoğullari. This is an open-access article distributed under the terms of the Creative Commons Attribution-NonCommercial 4.0 International License (CC BY-NC 4.0)

Funding: This research did not receive any financial support

Competing Interests: The authors have declared that no competing interests exist

AIM: We aimed to evaluate the possible effects of dissecting gastric breves (GB) during the Laparoscopic Nissen Fundoplication (LNF) on the gastric fundus and splenic circulation using dynamic Magnetic Resonance Imaging (MRI).

METHODS: In total 14 patients with gastroesophageal reflux disease (GERD) that was diagnosed with esophagogastroduodenoscopy and 24 - hour PH monitorization and undergoing LNF surgery were included. All patients underwent LNF surgery between October 2006 and March 2010. All patients were evaluated regarding gastric fundus and splenic circulation one week before and 15 days after the surgery with dynamic MRI. Alteration of the signal intensity before and after surgery was used to assess gastric fundus and splenic circulation.

RESULTS: We detected a significant decrease in DeMeester score before and after surgery ($p < 0.001$). There were no statistical differences between preoperative and postoperative dynamic MRI measurements of the spleen, anterior wall measurements, posterior wall measurements in different MRI phases (Bonferroni corrected $p > 0.01$). Postoperative measurements of anterior and posterior gastric wall measurements were comparable (Bonferroni corrected $p > 0.0033$).

CONCLUSIONS: We did not detect any significant differences in the abovementioned tissues regarding perfusion.

Introduction

Gastroesophageal reflux (GER) is a condition that is characterised by a retrograde movement of the gastric content into the oesophagus. Retrosternal burn at least two days of the week affecting life quality or mucosal loss (erosion or ulcer) in endoscopy is considered as "Gastroesophageal Reflux Disease" (GERD). Defective lower oesophageal sphincter (LES), transient lower oesophageal sphincter relaxations (TLESR), delayed oesophageal clearance, acid hypersecretion are implicated in the etiopathogenesis of the GERD [1][2]. GERD may cause clinical findings including pyrosis, acid

regurgitation, chest pain, dysphagia, and odynophagia [3][4]. In some of the GERD cases, columnar epithelium with intestinal metaplasia may develop in the oesophageal mucosa, which is called as Barrett's oesophagus [5]. It is known that this condition is a risk factor for oesophageal adenocarcinoma [4][6].

Even though acid might be controlled with medical treatment, non - acid reflux persists because defective LES remains untreated [7]. Contemporarily, surgical treatments are commonly used, as they are cheaper and more effective than medical treatment [8]. Among those surgical methods, Laparoscopic Nissen Fundoplication (LNF) is a standard gold treatment with less than 1% mortality and complication risk [9].

We aimed to evaluate the effects of transaction gastric breves (GB) during the LNF on the gastric fundus and splenic circulation. Our hypothesis in the current study is to explore whether gastric breves in LNF is effective on gastric fundus and splenic circulation using dynamic magnetic resonance imaging (MRI).

Material and Methods

We included 14 patients with symptoms of gastroesophageal reflux disease (GERD), endoscopically identified hiatal hernia, esophagitis and Demeester score above 14.72 in 24 - hour Ph monitoring were included in the study. Esophagitis is evaluated using Los Angeles classification [10]. A 24 - hour pH monitorization was used. Flexible pH catheters had their reference pH levels, and the distance between two sensors of the catheters was 15 cm. These catheters were calibrated in solutions with a pH of 1 and seven before usage. The data were assessed with a pH analysis program (MMS, the Netherlands) and Johnson and DeMeester scores were obtained. Patients with DM, HT, a history of pulmonary embolism, DVT or coronary artery disease and who had previously undergone gastrointestinal system or cardiac operation or received chemotherapy & radiotherapy were not included in the study. All patients underwent LNF surgery by the same operator (Surgit) using the standard technique between October 2006 - March 2010. All patients were evaluated regarding gastric fundus and splenic circulation one week before and 15 days after the surgery with dynamic MRI. Alteration of the signal intensity before and after surgery was used to assess gastric fundus and splenic circulation.

MR Imaging

A dynamic upper abdominal MRI was performed on a 1.5 T MR system (Intera Achieva 1.5 T; Philips Medical Systems, Best, The Netherlands) using a four channel SENSE body coil. A 15 - mL bolus of contrast material (gadodiamid [Omniscan, GE Healthcare Ireland]) and 20 mL of saline were delivered at 2 mL/second into an antecubital vein using an infusion pump injector (Medrad, Spectris Solaris; Indianola, Pa) and 5 sequential axial three - dimensional image datasets were acquired at precontrast, postcontrast 30 (Phase 1), 60 (Phase 2), 100 (Phase 3), and 130 (Phase 4) seconds using a T1 High Resolution Interpolated Volume Examination (THRIVE) perfusion sequence. (TR 4 msec, TE 1.9 msec, flip angle 10°, slice thickness 4 mm, field of view 320 - 380 mm). After transferring the images to Philips Extended Workspace, regions of

interest were located over anterior, posterior gastric fundus wall and spleen parenchyma to generate signal intensity - time curves. One measurement was performed from spleen parenchyma in each pre - and postoperative stages (Figure 1, 3).

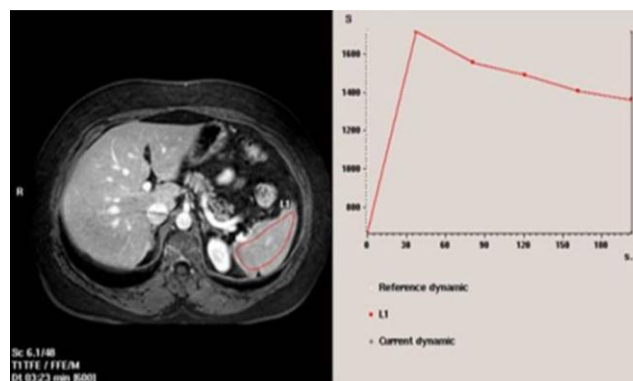


Figure 1: Preoperative measurements of the spleen with Dynamic MRG

A single measurement was performed from gastric fundus wall in preoperative stage (Figure 2), and two measurements were done from the anterior and posterior wall in postoperative stage (Figure 4). The signal intensities were calculated as arbitrary units (a).

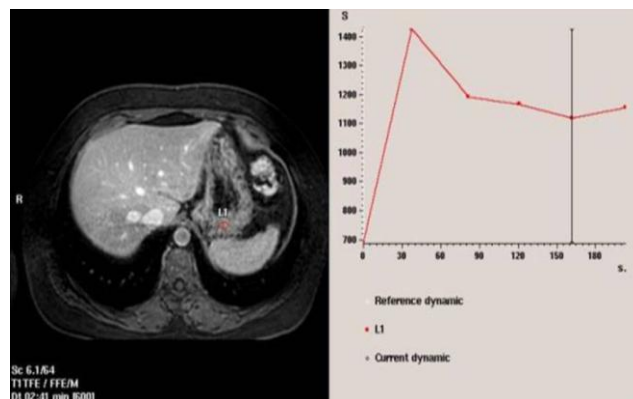


Figure 2: Preoperative measurements of the stomach with Dynamic MRG Image

Surgical Technique

Patients were placed in a Trendelenburg position following general anaesthesia. The operating surgeon stood between the patients' legs while the assistant operating the camera was on the patient's right and the second assistant holding the liver refractor was on the left side of the patient.

Following the positioning of the patient in 20 degrees reverse - Trendelenburg position, a 10mm incision was made approximately 3 cm above the umbilicus, and CO₂ insufflation into the abdomen was performed with a Veress needle. A 10 mm - port was introduced through the incision when the abdominal pressure reaches 14 mgHg. Then, two 5 mm trocars from both subcostal regions (ports that surgeon worked), a 10 mm trocar from the right side of the

abdomen for the liver refractor and another 10mm trocar from the left side of the abdomen were placed.

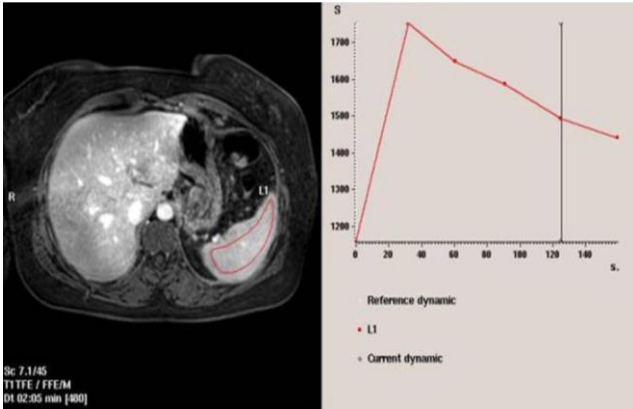


Figure 3: Postoperative measurements of the spleen with Dynamic MRG

First, the gastrohepatic ligament was opened, and the hiatus was dissected. External margins of the oesophagus, interior margins of both crura and nervus vagus were identified. Both oesophagus and nervus vagus were taken into the Goldfinger. Then, a blunt dissection in an avascular area was performed to identify crura completely. A window in which the fundus can easily pass through is opened.

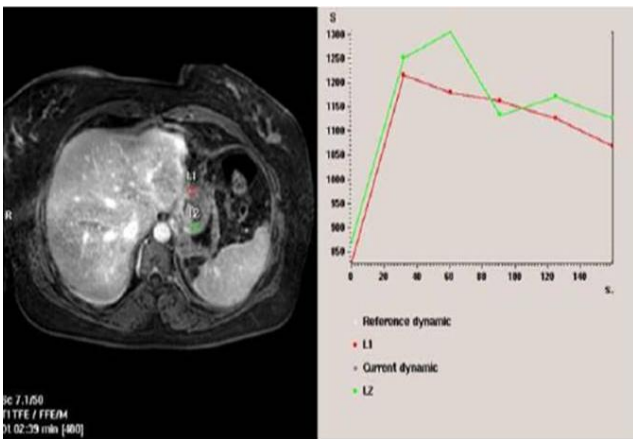


Figure 4: Postoperative measurements of anterior and posterior walls of the stomach with Dynamic MRG

The oesophagus was taken into the abdomen approximately 3 – 4 cm. After finalising hiatal dissection, Goldfinger was taken out, and GBs were transected using 5 mm - LigaSure®. The fundus is released including the left crus. Then the Goldfinger is inserted through the window that was previously opened. Crura were brought closer to each other using a 2 - 3 non - absorbable sutures and a 3 x 2 cm sized polypropylene graft (GalliniS.r.l, Mirandola, Italy) were laid out on it. The crura are fixed with a tacker. A suspending suture is placed on the fundus, and the suture is fixed to the Goldfinger. Then, it is moved through from the posterior to the anterior of the window. Thus, a 360 - degree wrap is completed. This position is fixed with three sutures with the first one passing through the oesophageal

wall. This way, a 2 – 3 cm “floppy” loose fundoplication was completed. The fundal part was fixed to the graft with one suture.

The Patients started began oral nutritional intake the next day. They were advised to be on a pureed food diet for one month. On post - operation day 15, a dynamic MRI was performed to evaluate gastric fundal and splenic circulation. On post - operation month 3, they were evaluated with an upper GIS endoscopy and a 24 - hour pH monitorization.

Table 1: Demographic characteristics

Variables	n=14
Age	48.9±8.6
Sex	
Men	8 (%57.1)
Women	6 (%42.9)
Comorbid disorders	2 (%14.3)

Statistical analyses

We used the SPSS for Windows®version 11.5 to analyse the data. A Shapiro Wilk test was used to check the normality of the continuous variables. Descriptive statistics were presented as median (minimum-maximum). We used Wilcoxon Sign test with a Bonferroni correction to test the differences between pre - and post - operation phase 1, 2, 3, four dynamic MRI measurements. For the splenic measurements, $p < 0.010$ and for gastric measurements, $p < 0.0033$ were considered statistically significant according to the Bonferroni correction.

Results

Preoperative median DeMeester score was 75.8 (minimum: 19.2 - maximum: 211.4) and it receded to 3.6 after surgery (minimum: 0.4 - maximum: 6.6). This decrease was statistically significant ($p < 0.001$) (Table 2).

Table 2: Pre - and post - operative DeMeester Scores

Time	DeMeester Score
Pre-operative	75.8 (19.2-211.4)
Post-operative	3.6 (0.4-6.6)
p-value	< 0.001

Median pre - and postoperative splenic measurements in phase 1, 2, 3, and 4 were statistically not different (Table 3).

Table 3: Pre - and postoperative Dynamic MRI measurements in each phase of the spleen

Phases	Pre-op (a)	Post-op (a)	the
Phase I	1962,5 (1174-2697)	2273 (1172-2874)	0.245
Phase II	2098 (1279-2836)	2105 (1153-3117)	0.975
Phase III	2032 (1241-2912)	2013 (1131-2894)	0.975
Phase IV	1957 (1196-2753)	1954,5 (1076-2594)	0.975

a Results were considered significant according to the Bonferroni corrected $p < 0.01$.

Median pre - and postoperative gastric measurements in phase 1, 2, 3, and 4 were statistically not different (Table 4).

Table 4: Pre - and postoperative Dynamic MRI measurements in each phase of the stomach

Phases	Pre-op (a)	Post - op On (a)	the
Phase I	1582 (1126-2486)	1558.5 (663-2085)	0.363
Phase II	1791 (964-2545)	1756 (876-2351)	0.530
Phase III	1744,5 (888-2719)	1612 (996-2704)	0.272
Phase IV	1649 (794-2273)	1530 (942-2346)	0.300

Median preoperative gastric and postoperative gastric posterior wall measurements in phase 1, 2, 3, and 4 were statistically not different (Table 5).

Table 5: Preoperative gastric and postoperative posterior gastric wall Dynamic MRI measurements in each phase

Phases	Pre-op (a)	Post - op Arka (a)	the
Phase I	1582 (1126-2486)	1927.5 (1129-2529)	0.363
Phase II	1791 (964-2545)	1966.5 (1312-2903)	0.875
Phase III	1744,5 (888-2719)	1831 (1161-2286)	0.826
Phase IV	1649 (794-2273)	1761 (1094-2357)	0.975

^a Results were considered significant according to the Bonferroni corrected $p < 0.0033$.

Postoperative anterior and posterior gastric wall measurements in phase 1, 2, 3, and four were significantly not different in Bonferroni corrected analysis (Table 6).

Table 6: Postoperative anterior and posterior gastric wall Dynamic MRI measurements in each phase

Phases	Post - op Anterior (a)	Post - op Posterior (a)	the
Phase I	1558.5 (663-2085)	1927.5 (1129-2529)	0.019
Phase II	1756 (876-2351)	1966.5 (1312-2903)	0.026
Phase III	1612 (996-2704)	1831 (1161-2286)	0.055
Phase IV	1530 (942-2346)	1761 (1094-2357)	0.008

^a Results were considered significant according to the Bonferroni corrected $p < 0.0033$.

Discussion

Many studies have shown that ischemia and necrosis in the gastric fundus, splenic ischemia and infarcts may occur following LNF. The prevalence of these complications is reported in several studies [11][12]. In the current study, we measured gastric fundus ischemia and spleen circulation with dynamic MRI before and after LNF and evaluated the effects of these measures on postoperative complications and the choice of laparoscopic antireflux technique. It is important to consider that in our study all patients were operated by the same surgeon with the same technique and evaluated by the same observer. Unlike previous studies, Dynamic MRI was used for the first time to evaluate gastric fundus and splenic circulation in patients who underwent LNF, which was performed dissecting the GB. The development of novel MRI may provide a new opportunity for evaluating abdominal pathologies [13].

Laparoscopic Nissen fundoplication was performed by the same surgeon without any

complications. In our study, preoperative median DeMeester score was 75.8 (minimum: 19.2 - maximum: 211.4), and postoperative median DeMeester score was 3.6 (minimum: 0.4 - maximum: 6.6), and there was a significant difference between pre - and postoperative DeMeester score ($p < 0.001$). Gastric necrosis following Nissen Fundoplication was first described in an 11 year - old girl who presented with gastric dilatation and was operated at the emergency room two years after Nissen Fundoplication surgery. Gastric necrosis was related to delayed gastric emptying after removing gastronomy tube and compartment syndrome [14]. Gastric necrosis and perforation after Nissen Fundoplication were described first by Patuto N. in adults. Obstruction related to small intestine adhesion 14 years after the surgery and gastric dilatation related with tight fundus wrap were thought to be responsible [15]. Experimental studies have shown that tight fundoplication wraps may cause gastric dilatation and infarcts due to the vomiting difficulties. The most dramatic outcome of the gastric dilatation is gastric necrosis, which is a life-threatening condition with 73% mortality [16][17]. Animal studies reported that the ligation of the four main arteries and 80% ligation of the small arteries do not result in gastric necrosis [15]. Disturbed intramural venous circulation due to increased intragastric pressure (over 20 to 30 mmHg) may cause gastric ischemia and rupture [16].

Kenedy T. et al. performed Nissen fundoplication and proximal gastric vagotomy to 33 patients with chronic duodenal ulcer and hiatal hernia. They detected necrosis of the lesser gastric curvature in three patients within the first week after the operation. This was related to gastric dilatation, which occurred due to swallowed air a couple of days after the operation, and subsequently distension and pressure on the lesser curvature vessels [11].

Rudolf Nissen in 1956 suggested forming a less tight gastric fundus wrap during the operation dissecting the GB to prevent extreme narrowing at the bottom of the oesophagus and postoperative dysphagia. However, dissection of GB during fundal mobilisation is still being debated. Some believe that it is necessary to dissect these vessels to have a less tight wrap and to prevent postoperative dysphagia [18]. Others, on the other hand, do not find it necessary to have a loose wrap. Moreover, they suggested that a larger dissection might increase the risk of bleeding during the operation, gastric fundus and splenic infarcts and abscess formation [19].

In a study, 99 patients with chronic GER who had an antireflux procedure with or without preserving the GB were followed for ten years. There was no statistical difference between the groups regarding heartburn, gas - bloating syndrome and burping. Life quality was evaluated with Psychological General Well - Being (PGWB) index and both groups revealed similar results [20]. The

surgeon should decide to dissect the GBs during the operation. In some publications, it was shown that dissecting the GBs result in similar postoperative outcomes as in LNF without GB dissection and it was concluded that dissecting the GBs is a safe procedure [12].

A hiatal hernia and bloating related to gas is seen more commonly in patients that underwent LNF with GB dissection. Surgeons developed the Nissen - Rosetti technique in which these vessels were preserved. Even though postoperative dysphagia was reported less in LNF with dissection of GBs when compared to the LNF without GB dissection, randomised, controlled studies are needed to confirm these findings [21].

Luostarinen ME, et al. suggested that GB dissection during LNF increases the risk of a hiatal hernia [22]. It was thought that dissecting GBs might cause loosening of the gastric fundus. Thus, the hernia may occur more easily, and hernia recurrence is increased [21]. In the last five prospective randomised studies, the beneficial effect of dissecting GB was not proven. However, many surgeons dissect GB during LNF in their clinical practice [23].

LNF with or without GB dissection, however, has been shown to be beneficial in relieving GER symptoms [24]. Wyman et al. proposed that dissecting GBs during LNF might damage the afferent vagal nerves that stimulate gastric tension receptor in the fundus responsible for burping reflex [25].

Markar S.R. et al. reviewed literatures between January 1950 - October 2009 for patients that LARP with and without GB dissections and compared them in terms of primary outcomes including need of reoperation, postoperative dysphagia, and postoperative GER secondary outcomes including duration of operation, duration of hospitalization, presence of postoperative complications, postoperative gas - bloating syndrome, postoperative resting state lower esophageal sphincter pressure, and postoperative DeMeester scores that is calculated using 24 - hour pH monitoring. There were no significant differences and heterogeneity between groups for the need of reoperation, postoperative GER, duration of hospitalisation; postoperative DeMeester score and postoperative resting state lower oesophageal sphincter pressure. However, duration of operation was significantly longer in patients who received LNF with GB dissection. There were no significant differences and heterogeneity for postoperative complications between the groups. They did not detect any significant differences in gas - bloating syndrome, but a difference in heterogeneity was detected [12].

In our study, we showed that dissecting GBs during LNF does not affect gastric fundal circulation as evaluated with dynamic MRI.

Splenic bleeding and infarcts were also described in previous publications [18]. Splenic infarctions have been reported commonly in the laparoscopic surgery and prevalence was generally < 1% [18][26].

An occlusion or injury in the peripheral splenic artery that has limited collateral circulation may generate ischemia or infarct areas in the splenic parenchyma [19]. Cardiac emboli or hypercoagulability are considered to be an underlying factor for occlusion [27].

In total, 30% of the patients with splenic infarcts are asymptomatic, and they may develop splenic rupture or abscess. Rarely, the whole spleen may have infarct [28]. In the short term, haemorrhage can be seen, but in the long term, it is healed by fibrosis [27]. In our patient group, none of the patients had postoperative splenic ischemia or infarct.

Damaging or ligating risk of the splenic vessels is high in LNF and laparoscopic sleeve gastrectomy (LSG) with GB dissection as they are located in the posterior field of the surgical area. In that case, splenic ischemia or infarct might occur. Splenic infarct has been reported in some case reports [18][25], and in a study of 1600 patients, it was seen in < 1% of the patients [26]. Stamou KM et al. reported splenic infarcts as 4.1% in 287 patients who had laparoscopic sleeve gastrectomy. Splenic infarcts are recognised by observing the colour alterations in the spleen during the operation or with USG and BT postoperatively [19][29].

Similarly, we believe that ischemia and infarcts following LNF occur due to the dissection or ligation of the splenic artery and its branches after dissection of the GB. In the current study, no statistical differences between pre - and postoperative measurements of gastric fundus and splenic circulation with dynamic MRI were detected.

To the best of our knowledge, effects of the dissection of GBs during LNF on gastric and splenic perfusion have not been tested with dynamic MRI. We did not find any significant difference regarding perfusion between pre - and post - operative measurements. However, small sample size is a limitation in the current study. More studies with bigger sample sizes are needed. In the light of our current findings, we believe that LNF with GB dissection has no effect on the gastric and splenic perfusion and it is a relatively safe technique for GERD.

References

1. Peters JH, DeMeester TR. Esophagus and Diaphragmatic Hernia: Gastroesophageal Reflux Disease. Schwartz's Principle of Surgery, 8th edition. Birmingham: McGraw- Hill Professional, 2004; 573-649.
2. Bor S, Mandiracioglu A, Kitapcioglu G, Caymaz-Bor C, Gilbert RJ. Gastroesophageal reflux disease in a low-income region in Turkey. *Am J Gastroenterol*. 2005; 100:759-65. <https://doi.org/10.1111/j.1572-0241.2005.41065.x> PMID:15784016
3. Moss SF, Armstrong D, Arnold R et al. GERD 2003- a consensus on the way ahead. *Digestion*. 2003; 67:111-7. <https://doi.org/10.1159/000071290> PMID:12853722
4. Malfertheiner P, Hallerback B. Clinical manifestations and complications of gastroesophageal reflux disease (GERD). *Int J Clin Pract*. 2005; 59:346-55. <https://doi.org/10.1111/j.1742-1241.2005.00370.x> PMID:15857335
5. Adachi K, Fujishiro H, Katsube T et al. Predominant nocturnal acid reflux in patients with Los Angeles grade C and D reflux esophagitis. *J Gastroenterol Hepatol*. 2001; 16:1191- 6. <https://doi.org/10.1046/j.1440-1746.2001.02617.x> PMID:11903734
6. Lagergren J, Bergstrom R, Lindgren A, Nyren O. Symptomatic gastroesophageal reflux as a risk factor for esophageal adenocarcinoma. *N Engl J Med*. 1999; 18:825-31. <https://doi.org/10.1056/NEJM199903183401101> PMID:10080844
7. S Demester. Gastroesophageal reflux disease. *Cur Prob Surg* 2001; 38:558-40.
8. Heading RC. Long-term management of gastroesophageal reflux disease. *Scand J Gastroenterol Suppl*. 1995; 213:25-30. PMID:8578240
9. Rantanen TK, Oksala NK, Oksala AK, Salo JA, Sihvo EI. Complications in antireflux surgery: national-based analysis of laparoscopic and open funduplications. *Arch Surg*. 2008; 143:359-65. <https://doi.org/10.1001/archsurg.143.4.359> PMID:18427023
10. Kennedy T, Magill P, Johnston GW, Parks TG. Proximal gastric vagotomy, fundoplication, and lesser-curve necrosis. *Br Med J*. 1979; 1:1455-6. <https://doi.org/10.1136/bmj.1.6176.1455> PMID:466056 PMID:PMC1599048
11. Markar SR, Karthikesalingam AP, Wagner OJ et al. Systematic review and meta- analysis of laparoscopic Nissen fundoplication with or without division of the short gastric vessels. *Br J Surg*. 2011; 98:1056-62. <https://doi.org/10.1002/bjs.7519> PMID:21560121
12. Bass KD, David P. Meagher J, Haase GM. Gastric Necrosis After Fundoplication: A Novel Approach for Esophageal Preservation. *J Pediatr Surg*. 1998; 33:1720-2. [https://doi.org/10.1016/S0022-3468\(98\)90618-2](https://doi.org/10.1016/S0022-3468(98)90618-2)
13. Patuto N, Ackjin Y, Oertli D, Langer I. Gastric necrosis complicating lately a Nissen fundoplication. *Langenbecks Arch Surg*. 2008; 393:45-7. <https://doi.org/10.1007/s00423-007-0216-z> PMID:17690904
14. Todd SR, Marshall GT, Tyroch AH. Acute gastric dilatation revisited. *Am Surg*. 2000; 66:709-10. PMID:10966022
15. Hunter JG, Trus TL, Branum GD, Waring JP. Laparoscopic Heller myotomy and fundoplication for achalasia. *Ann Surg*. 1997; 225:655-64. <https://doi.org/10.1097/0000658-199706000-00003> PMID:9230806 PMID:PMC1190864
16. Martínez DG, Sánchez AW, García AP. Splenic abscess after laparoscopic Nissen fundoplication: a consequence of short gastric vessel division. *Surg Laparosc Endosc Percutan Tech*. 2008; 18:82-5. <https://doi.org/10.1097/SLE.0b013e318159e837> PMID:18287992
17. Mardani J, Lundell L, Lönroth H, Dalenback J, Engström C. Ten-year results of a randomized clinical trial of laparoscopic total fundoplication with or without division of the short gastric vessels. *Br J Surg*. 2009; 96:61-5. <https://doi.org/10.1002/bjs.6393> PMID:19016274
18. Watson DI, Pike GK, Baigrie RJ et al. Prospective double-blind randomized trial of laparoscopic Nissen fundoplication with division and without division of short gastric vessels. *Ann Surg*. 1997; 226:642-652. <https://doi.org/10.1097/0000658-199711000-00009> PMID:9389398 PMID:PMC1191126
19. Luostarinen ME, Isolauri JO. Randomized trial to study the effect of fundic mobilization on long-term results of Nissen fundoplication. *Br J Surg*. 1999; 86:614-8. <https://doi.org/10.1046/j.1365-2168.1999.01111.x> PMID:10361180
20. Kösek V, Wykypiel H, Weiss H et al. Division of the short gastric vessels during laparoscopic Nissen fundoplication: clinical and functional outcome during long-term follow up in a prospectively randomized trial. *Surg Endosc*. 2009; 23:2208-13. <https://doi.org/10.1007/s00464-008-0267-4> PMID:19082662
21. Anvari M, Allen C, Marshall J et al. Randomized controlled trial of laparoscopic Nissen fundoplication versus proton pump inhibitors for treatment of patients with chronic gastroesophageal reflux disease: one-year follow-up. *Surg Endosc*. 2011; 25:2547-54. <https://doi.org/10.1007/s00464-011-1585-5> PMID:21512887
22. Ciovica R, Riedl O, Neumayer C, Lechner W, Schwab GP, Gadenstätter M. The use of medication after laparoscopic antireflux surgery. *Surg Endosc*. 2009; 23:1938-46. <https://doi.org/10.1007/s00464-008-0271-8> PMID:19169748
23. Ipek T, Eyuboglu E, Ozben V. Partial splenic infarction as a complication of laparoscopic floppy nissen fundoplication. *J Laparoendosc Adv Surg Tech A*. 2010; 20:333- 7. <https://doi.org/10.1089/lap.2009.0409> PMID:20438311
24. Rabushka LS, Kawashima A, Fishman EK. Imaging of the spleen: CT with supplemental MR examination. *Radiographics*. 1994; 14:307-32. <https://doi.org/10.1148/radiographics.14.2.8190956> PMID:8190956
25. Nores M, Phillips EH, Morgenstern L, Hiatt JR. The clinical spectrum of splenic infarction. *Am Surg*. 1998; 64:182-8. PMID:9486895