

# The Kapandji Technique of Closed Reduction Using Sommer - Pins in the Treatment of Completely Dislocated Fractures of the Distal Radius in Children

Marjan Kamiloski<sup>\*</sup>, Lazar Todorovik, Shaban Memeti, Lazo Jovcevski, Slavica Shuperliska, Zlatko Aleksovski

*University Clinic of Paediatric Surgery, Faculty of Medicine, Ss Cyril and Methodius University of Skopje, Skopje, Republic of Macedonia*

## Abstract

**Citation:** Kamiloski M, Todorovik L, Memeti S, Jovcevski L, Shuperliska S, Aleksovski Z. The Kapandji Technique of Closed Reduction Using Sommer - Pins in the Treatment of Completely Dislocated Fractures of the Distal Radius in Children. *Open Access Maced J Med Sci.* 2018 Feb 15; 6(2):330-335. <https://doi.org/10.3889/oamjms.2018.073>

**Keywords:** Kapandji; Fractures of the distal radius; Pediatric; Fractures; Surgical treatment

**\*Correspondence:** Marjan Kamiloski, University Clinic of Paediatric Surgery, Faculty of Medicine, Ss Cyril and Methodius University of Skopje, Skopje, Republic of Macedonia. E-mail: [mkamiloski@yahoo.com](mailto:mkamiloski@yahoo.com)

**Received:** 19-Nov-2017; **Revised:** 06-Dec-2017; **Accepted:** 07-Dec-2017; **Online first:** 11-Feb-2018

**Copyright:** © 2018 Marjan Kamiloski, Lazar Todorovik, Shaban Memeti, Lazo Jovcevski, Slavica Shuperliska, Zlatko Aleksovski. This is an open-access article distributed under the terms of the Creative Commons Attribution-NonCommercial 4.0 International License (CC BY-NC 4.0)

**Funding:** This research did not receive any financial support

**Competing Interests:** The authors have declared that no competing interests exist

**BACKGROUND:** The fractures of the distal radius are one of the most frequent cases in the pediatric population. The primary way of treating these fractures is conservative, with manual reduction and cast immobilisation. In patients where reduction and retention of the fracture cannot be achieved, a surgical approach is the treatment of choice.

**AIM:** To evaluate the benefits of using the minimally invasive surgical treatment of closed reduction using Sommer - pins in the treatment of the fractures of the distal radius in the pediatric population with the method of the Kapandji technique.

**MATERIAL AND METHODS:** In this study, we used cases treated from 2012 to 2017, of 48 completely dislocated fractures of the distal radius in patients ages 6 -14 yrs., where the use of non-surgical treatment proved ineffective. In the surgical treatment, we used one or two Sommer - pins to achieve a correct reduction and fixation.

**RESULTS:** The post-op immobilisation lasted 4 - 7 weeks with an underarm cast. The patients were closely followed in the period of 6 months following the intervention. The anatomic reduction was easily achieved with this type of technique in every case. In the post-op period, there was no significant loss of reduction and another surgical procedure was not needed in any of the cases.

**CONCLUSION:** With the use of the closed reduction Kapandji technique, an easy and good anatomical reduction is achieved with good post-op results in the treatment of completely dislocated fractures in the distal radius in children.

## Introduction

The distal radius is the most frequent location of fractures in the pediatric population - about 20 - 30% of all fractures belong to this group [1]. The main principle in the treatment of fractures in the pediatric population is to use a non - invasive, conservative approach to the treatment of the fractures of the distal radius. In the cases where we have a non - optimal reposition of the fragments of the fracture, surgical or semi-conservative techniques are used to treat these fractures.

The achievement of a good reposition of the fracture can prove difficult in the completely dislocated pediatric fractures of the distal radius (PDR) using a closed reduction technique which consists of

manually manipulating the fracture. It has been shown that the traction is especially non - efficient [2], when there is an intact ulna or a "greenstick" ulnar fracture [3], because of which completion of the periosteal "greenstick" ulnar fracture is suggested [4]. Several authors have identified the factors of risk for dislocation of the fractures of the distal radius which can be categorised in two categories: primary and secondary causes[5][6][7][8]. The **primary cause** includes: ages of more than 9 yrs., a complete dislocation to begin with, a translation of the fracture of more than 50%, an angulation of more than 20<sup>0</sup>, an oblique fracture line, comminuting, a bayonet fracture with dorsal positioning accompanied with ipsilateral distal ulnar fractures. The **secondary causes** include the inability to achieve a primary perfect reduction, a suboptimal technique of cast immobilization with a cast index larger than 0.8,

additional reduction maneuvers and reduction in sedation or using a hematoma block, instead of full anaesthesia.

The intrafocal technique of Kapandji is a well - established method of reduction and fixation of the distal radial fractures in the adult population, and the authors of this study have used it during their practice in this institution for many years. Because of its simplicity, and effectiveness, the authors of this study have used the same technique for the treatment of the completely dislocated fractures of the distal radius in the pediatric population [9].

Our study aims to evaluate the benefits of using the minimally invasive surgical treatment of closed reduction using Sommer - pins in the treatment of the fractures of the distal radius in the pediatric population with the method of the Kapandji technique.

## Material and Methods

This is a prospective study of the treatment of 48 pediatric patients, presented with a completely dislocated, closed fracture of the distal radius with or without an accompanying ulnar fracture, after a non - optimal repositioning of the fragments at the University Clinic of pediatric surgery in Skopje, in the period from 2012 - 2017. All of the 48 patients included in the study were treated surgically. The surgical method used was the Kapandji technique of closed reduction using Sommer - pins. In every patient, a pre-op and post-op AP and lateral X - rays were made. An informed agreement for the surgical procedure (The Kapandji technique) was given by the parents/guardians in every case included in the study.

### Surgical technique

After adequate anaesthesia, the arm was positioned on the radio - translucent table (Figure 1, 2).

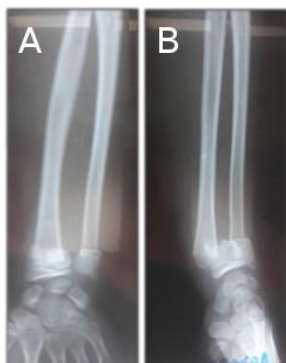

Figure 1: The preoperative anteroposterior (A) and lateral X-rays of a completely dislocated fracture of the distal radius in a child (B)

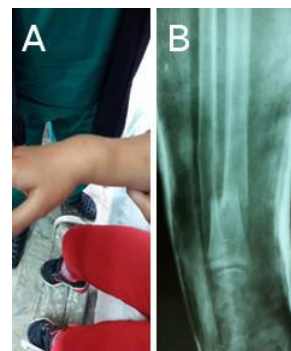

Figure 2: Photo of the presentation of the fracture (A) and an initial X-ray of the fracture (B)

To achieve a full radial length, gentle traction and contra-traction were used. In all of the cases, the distal fragment was posteriorly moved. The Sommer pin was manually introduced at the site of the fractured form the posterior aspect (Figure 3). A 2.2 mm Sommer pin was used in the smaller children, while a 2.8 mm Sommer pin was used in the larger patients.

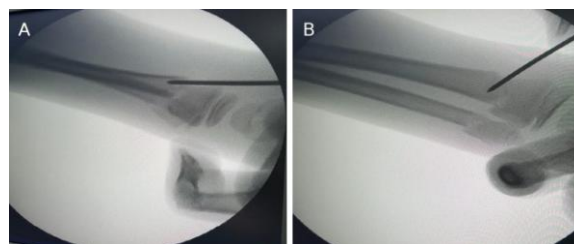


Figure 3: (A) Lateral and (B) AP presentation after the introduction of the Sommer - pin

The preoperative anteroposterior (A) and lateral X - rays of a completely dislocated fracture of the distal radius in a child (B).

The Sommer-pin was introduced trough the distal fragment in the site of the fracture towards the proximal fragment. The posterior cortex of the proximal fragment was elevated posteriorly with a manual borer for pinning reducing the posterior cortex of the distal fragment (Figure 4).

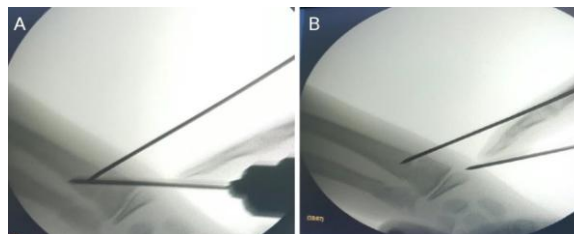


Figure 4: An x-ray in which the reduction of the proximal (A) and distal fragment (B) of the fracture was made using Sommer - pins

An x-ray in which the reduction of the proximal (A) and distal fragment (B) of the fracture was made using Sommer - pins.

After the posterior cortexes of the fragments have been aligned, the Sommer - pin was forced obliquely across the fracture so it could reach the anterior cortex of the proximal fragment. After this, a drill was placed on the Sommer - pin which later is introduced across the anterior cortex, stabilising the fracture. The underarm was in full pronation and then checked on an AP and lateral x-ray (Figure 5). If the fracture was reduced, as was in most of the cases, the extra - focal Sommer - pin has passed through the lateral side or from the distal lateral to the proximal medial side of the radial styloid processes, or has passed above the physical line, or from proximal lateral position to distal medial.

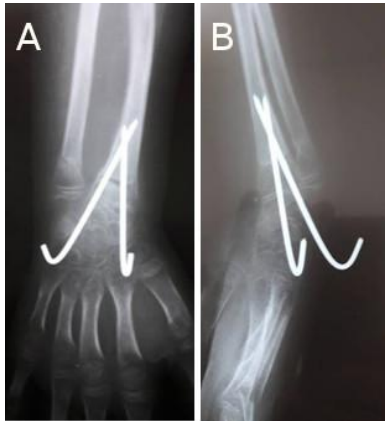

Figure 5: An X-ray of the anteroposterior (A) and lateral (B) presentation after the fixation with the Sommer - pins

An X-ray of the anteroposterior (A) and lateral (B) presentation after the fixation with the Sommer - pins.

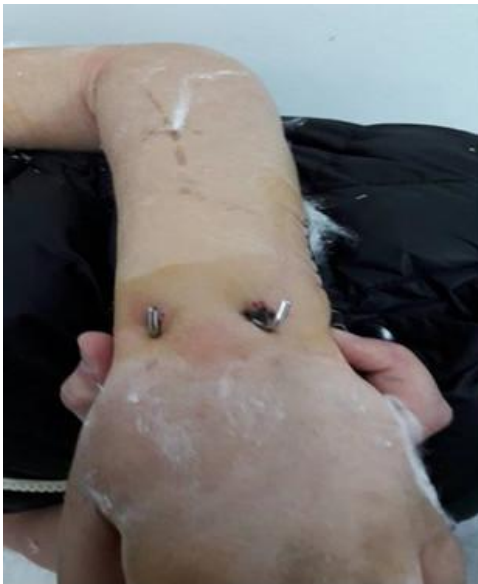

Figure 6: A clinical presentation of the introduction site of the Sommer - pins through the skin

If there was a residual lateral translation/dislocation of the distal fragment in the AP presentation, another intra - focal Sommer - pin

was introduced through the lateral site of the fracture (Figure 6). If the child was admitted during the night shift, it was released from the hospital the next day. A control x-ray in lateral and AP presentation were obtained before releasing the child. The first control X-ray was done on the first post-op day, then control X - rays were obtained according to the age of the child.

After 3 to 6 weeks, control X-rays were obtained. After the results were optimal, the extraction of the Sommer pins was done as an outpatient procedure. We used a compressive bandage, and the mobilisation of the wrist began after the extraction of the Sommer pins. The patients were followed at least three months post-op.

## Results

In this study are presented our starting results of 48 patients with completely dislocated fractures of the distal radius treated with the minimally invasive surgical approach of the Kapandji technique.

The age of the patients was 6 - 14 yrs., out of which 26 were male, 22 female. According to the mechanism of injury – 14 patients were injured after falling from a height, while most were sports injuries, or injury during play – 34 patients (Table 1). The average age was 9.8 yrs. The average time of the procedure of reduction and fixation with the Sommer - pins was 19 minutes. The combination of intra and extra - focal Sommer - pins were used and adjoined ulnar fractures were observed in 21 patient. The results were based on the function of the wrist (Figure 7). The normal pronation/supination was defined as 90/0/90 degrees (A), the normal flexion/extension as 30/0/30 degrees (B), while the normal radial flexion as 20/0 degrees and the normal ulnar flexion as 0/30 degrees (C). The control group consisted of children with a healthy non - injured wrist.

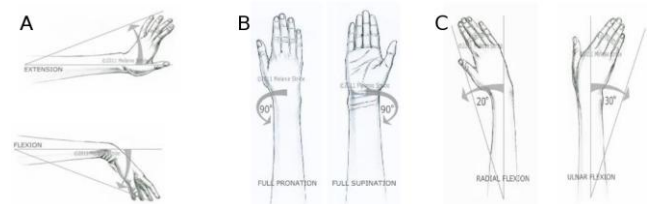


Figure 7: Function of the wrist

The evaluation of the results was done six months after the intervention, and in our study, we used the “Mayo wrist score” system for evaluation of the function of the wrist with analysis of several parameters: mobility, the strength of grip, level of satisfaction and pain (Figure 8).

Category	Score	Findings	
Pain (25 points)	25	No pain	
	20	Mild pain with vigorous activities	
	20	Pain only with weather changes	
	15	Moderate pain with vigorous activities	
	10	Mild pain with activities of daily living	
	5	Moderate pain with activities of daily living	
Satisfaction (25 points)	0	Pain at rest	
	25	Very satisfied	
	20	Moderately satisfied	
	10	No satisfied, but working	
	0	No satisfied, unable to work	
Range of motion (25 points)	25	100% percentage of normal	Final result (total points)
	20	75~99% percentage of normal	90~100 Excellent
	10	50~74% percentage of normal	80~89 Good
	5	25~49% percentage of normal	65~79 Fair
	0	0~24% percentage of normal	<65 Poor
Grip strength (25 points)	25	100% percentage of normal	
	15	75~99% percentage of normal	
	10	50~74% percentage of normal	
	5	25~49% percentage of normal	
	0	0~24% percentage of normal	

Figure 8: "Mayo wrist score."

With the method of lifting by Kapandji, an anatomical or almost anatomical reduction of the fracture was achieved in every case. Open reduction was not used in any of the cases. The post-op period in each of the 48 patients, went without any complication.

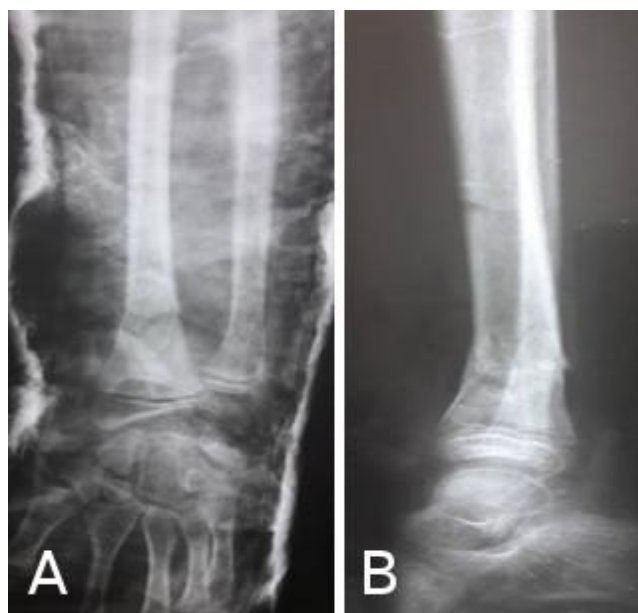

Figure 9: A postoperative anteroposterior (A) and lateral X-ray (B), showing the healed fracture of the distal radius

The X-ray signs of consolidation were seen after four weeks, and the treatment of the fractures was fully completed three months after the injury, with the extraction of the pins after 8 - 18 weeks. In each patient, a full clinical and radiologic healing was obtained with a normal range of motion of the wrist. On the final X-ray, just before the extraction of the Sommer pin, there has been no recorded angular translation or angulations.

All the fractures have healed fully (Figure 9). The cosmetic effect was excellent after the cast was removed in all the cases. All of the patients achieved full flexion and extension of the wrist (Figure 11).

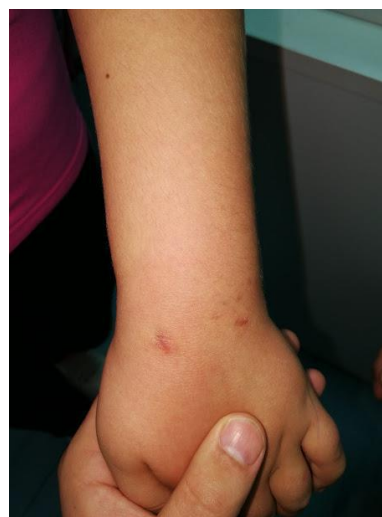

Figure 10: A good cosmetic effect

The average length of time needed to achieve a full range of motion after the initial immobilisation was four weeks (range 2 - 5 weeks). There was no loss of reduction or re-manipulation. No complications with the pins or the cast were noted.

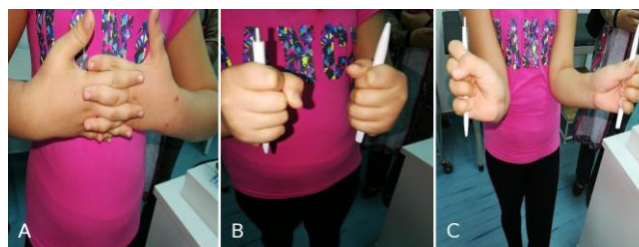


Figure 11: Good flexion and extension of the wrist

## Discussion

There are three methods for the treatment of the completely dislocated fractures of the distal radius in children: a careful manual repositions without optimal reduction of the fracture and cast immobilisation without the use of anaesthesia, a closed reduction and cast immobilisation with the use of anaesthesia, and closed reduction and pinning with the use of anaesthesia.

The closed reduction is usually reserved for cases of late treatment or loss of initial reduction with complete angulation. The completely dislocated fractures of the distal radius are with the risk of new reposition and reduction after the initially closed manipulation and cast immobilisation. Despite the overall good functional and radiological results, on the long run, in most of the non - reduced fractures of the distal radius, the loss of reduction is considered a real problem.



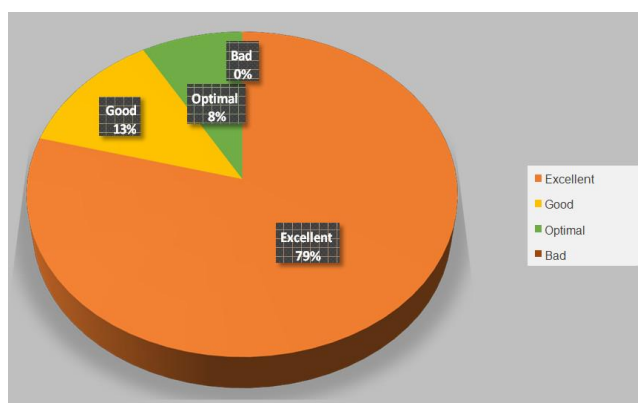


Figure 12: Display results according to the "Mayo wrist score" scoring system for evaluation

Some factors that have to be considered before electing the optimal method of treatment are the age of the child, the seriousness of the initial angulation or an angulation after a secondary displacement which might be accepted for a given patient, the length of time needed for the remodeling and another intervention if needed, and whether the second intervention can give the same result as the primary intervention, as well as the full length of treatment.

Table 1: Statistical analysis of clinical data

Age	Sex	Associated fractures	Mechanism of injury	Pin extraction in weeks	Functional results according to the Mayo wrist score
10	M	Ulna	Fall from bike	10	Excellent
10	F		Fall from rollers	11	Excellent
11	F	Ulna	Fall from sling	15	Excellent
9	F		Fall from sling	14	Excellent
12	M		Fall during football	15	Excellent
10	M		Fall from bike	13	Excellent
9	F		Fall from bike	9	Excellent
10	M	Ulna	Fall from trampoline	10	Good
10	M	Ulna	Fall from ladder	13	Excellent
7	F		Fall while skating	12	Excellent
8	F		Fall from bike	18	Optimal
10	M		Fall from trampoline	14	Good
12	M	Ulna	Fall from ladder	9	Excellent
11	F		Fall while skating	16	Excellent
13	F		Fall during football	11	Excellent
8	F		Fall from bike	17	Excellent
11	M	Ulna	Fall from trampoline	11	Optimal
9	M	Ulna	Fall from ladder	13	Excellent
12	M	Ulna	Fall while skating	8	Good
10	F	Ulna	Fall from trampoline	10	Excellent
11	F		Fall from ladder	15	Excellent
13	F		Fall while skating	14	Excellent
9	M		Fall from trampoline	9	Excellent
12	F	Ulna	Fall from trampoline	18	Excellent
11	M	Ulna	Fall from ladder	14	Excellent
10	F		Fall while skating	13	Excellent
9	M		Fall during football	10	Good
11	F		Fall from bike	15	Excellent
14	F	Ulna	Fall from ladder	18	Excellent
8	M	Ulna	Fall from trampoline	14	Excellent
10	M		Fall from ladder	12	Excellent
6	F	Ulna	Fall while skating	15	Excellent
8	M	Ulna	Fall during football	18	Good
9	M		Fall during football	17	Excellent
13	F		Fall during football	12	Optimal
7	F	Ulna	Fall from bike	11	Excellent
9	M		Fall while skating	18	Excellent
9	M		Fall during football	16	Excellent
9	F		Fall from ladder	16	Excellent
10	M	Ulna	Fall from sling	12	Excellent
11	M		Fall from rollers	10	Excellent
6	M		Fall from ladder	13	Optimal
7	F		Fall from trampoline	18	Excellent
14	F	Ulna	Fall while skating	18	Excellent
12	M	Ulna	Fall from bike	16	Good
9	M	Ulna	Fall from trampoline	15	Excellent
9	M		Fall while skating	14	Excellent
7	M	Ulna	Fall from ladder	14	Excellent

Even though the achievement of an optimal closed reduction with any used technique is the unified first step in the treatment, the other thing that must be highlighted is the use of the technique which allows the best post-op reduction that will last during the period of healing. Well-Placed cast immobilisation on three points and the percutaneous application of the Sommer pins are two options that are proven to keep a good stable reduction of the fracture while healing. Although a perfectly modelled cast is required, that might not be possible because of inappropriate and sufficient application of gauze, a too quick or maybe even a prolonged manipulation of the cast itself, swelling of the soft tissues, or the use of suboptimal anaesthesia. An above average swelling can be present in the initial exam of the fracture, because of trauma under high velocity, an accompanying ulnar fracture primary immobilisation that was never achieved right after the injury. The swelling can increase after later forced manipulations with the fracture, especially in cases of prolonged presentation. The reduction of the swelling several days after the initial cast immobilisation is placed can result in a concomitant dislocation of the initially achieved reduction.

In one prospective randomised trial of over 100 fractures of the distal radius in adults treated with the application of Sommer pins, Sthorm et al., [10] have found the functional and radiographic results of the Kapandji method used and proved that they are much better than the conventional (Willenegger) technique. The conventional extra-focal Sommer-pins in completely dislocated distal radial fractures can be introduced only after achievement of a satisfying reduction.

The authors of this study had done only two post-op X-ray exams, one right after surgery, the other when the Sommer pins were extracted. After extraction, they have conducted only two controls, the first after 2 - 3 weeks, the second after 4 - 6 weeks after extraction. During the first control exam, the authors were satisfied with the cosmetic effect. On the second exam, the majority of patients had already achieved full range of motion of the wrist, which was an indicator of full recovery. Using the Kapandji technique which is a method of closed fracture reduction, the force used is applied in full effect without traumatising the soft tissues surrounding the fracture. Many orthopaedic surgeons agree that the majority of distal radius fractures could be treated with minimal or no cosmetic and functional abnormalities, especially in the pediatric population.

According to our results, in the treatment of the dislocated fractures of the distal radius which are by the results by other relevant authors, we can safely recommend the minimally invasive Kapandji technique as a method of choice when treating this type of fractures.

## References

1. Randsborg PH, Gulbrandsen P, Saltyte Benth J, et al. Fractures in children: epidemiology and activity-specific fracture rates. *J Bone Joint Surg Am.* 2013; 95(7):e421–e427. <https://doi.org/10.2106/JBJS.L.00369> PMID:23553305
2. Fernandez DL. Conservative treatment of forearm fractures in children. In: Chapchal G, ed. *Fractures in Children.* New York, NY: Thieme-Stratton, 1981.
3. Woodbury DF, Fischer B. An overriding radius fracture in a child with intact ulna: management considerations. *Orthopaedics.* 1985; 8:763–765.
4. Compere CL, Carr CR, Tracy HW. Management of fractures of the distal forearm in children. *South. Med J.* 1965; 57:540–550.
5. Zamzam MM, Khoshhal KI. Displaced fracture of the distal radius in children: factors responsible for redisplacement after closed reduction. *J Bone Joint Surg Br.* 2005; 87:841–843. <https://doi.org/10.1302/0301-620X.87B6.15648> PMID:15911670
6. Kamat AS, Pierse N, Devane P, Mutimer J, Horne G. Redefining the cast index: the optimum technique to reduce redisplacement in pediatric distal forearm fractures. *J Pediatr Orthop.* 2012; 32(8):787–791. <https://doi.org/10.1097/BPO.0b013e318272474d> PMID:23147621
7. Mostafa MF, El-Adl G, Enan A. Percutaneous Kirschner-wire fixation for displaced distal forearm fractures in children. *Acta Orthop Belg.* 2009; 75:459–466. PMID:19774811
8. McQuinn AG, Jaarsma RL. Risk factors for redisplacement of pediatric distal forearm and distal radius fractures. *J Pediatr Orthop.* 2012; 32(7):687–692. <https://doi.org/10.1097/BPO.0b013e31824b7525> PMID:22955532
9. Parikh SN, Jain VV, Youngquist J. Intrafocal pinning for distal radius metaphyseal fractures in children. *Orthopedics.* 2013; 36(6):783–788. <https://doi.org/10.3928/01477447-20130523-25> PMID:23746016
10. Strohm PC, Müller CA, Boll T, Pfister U. Two procedures for Kirschner wire osteosynthesis of distal radial fractures: a randomized trial. *J Bone Joint Surg Am.* 2004; 86(12):2621–2628. <https://doi.org/10.2106/00004623-200412000-00006> PMID:15590845