

Prognostic Significance of Vascular Endothelial Growth Factor (VEGF) and Her-2 Protein in the Genesis of Cervical Carcinoma

Arshad H. Rahmani¹, Ali Yousif Babiker^{1,2*}, Mohammed A. Alsahli¹, Saleh A. Almatroodi¹, Nazik Elmalaika O. S. Husain³

¹Department of Medical Laboratories, College of Applied Medical Sciences, Qassim University, Buraidah, Saudi Arabia;
²Department of Histopathology and Cytology, College of Medical Laboratories Science, University of Sciences and Technology, Omdurman, Sudan; ³Department of Pathology, Faculty of Medicine, Omdurman Islamic University, Omdurman, Sudan

Abstract

Citation: Rahmani AH, Babiker AY, Alsahli MA, Almatroodi SA, Husain NEOS. Prognostic Significance of Vascular Endothelial Growth Factor (VEGF) and Her-2 Protein in the Genesis of Cervical Carcinoma. Open Access Maced J Med Sci. <https://doi.org/10.3889/oamjms.2018.089>

Keywords: Cervical carcinoma; Vascular endothelial growth factor; Her-2; Grade and stage

***Correspondence:** Ali Yousif Babiker. Department of Medical Laboratories, College of Applied Medical Sciences, Qassim University, Buraidah, Saudi Arabia. E-mail: alibabkr99@gmail.com

Received: 13-Dec-2017; **Revised:** 22-Dec-2017; **Accepted:** 23-Dec-2017; **Online first:** 10-Feb-2018

Copyright: © 2018 Arshad H. Rahmani, Ali Yousif Babiker, Mohammed A. Alsahli, Saleh A. Almatroodi, Nazik Elmalaika O.S. Husain. This is an open-access article distributed under the terms of the Creative Commons Attribution-NonCommercial 4.0 International License (CC BY-NC 4.0)

Funding: This research did not receive any financial support

Competing Interests: The authors have declared that no competing interests exist

BACKGROUND: Angiogenesis plays a pivotal role in the progression of tumours through the formation of new blood vessels. Vascular endothelial growth factor (VEGF) is a chief factor responsible for inducing and regulating angiogenesis. Additionally, the human epidermal growth factor receptor family of receptors also plays an important role in the pathogenesis of tumours.

AIM: This study aimed to examine the association between VEGF and Her-2 protein expression and its correlation with clinic-pathological characteristics; in particular, prognosis.

METHODS: A total of 65 cases of cervical carcinoma and 10 samples of inflammatory lesions were evaluated for VEGF and Her-2 protein expression.

RESULTS: Expression of VEGF and Her-2 was detected in 63.07% and 43.07% in cervical carcinoma cases respectively whereas control cases did not show any expression. The difference in the expression pattern of both markers comparing cancer and control cases was statistically significant ($p < 0.05$). However, no significant difference in the expression pattern of VEGF protein was observed among the different grades and stages of tumours ($p > 0.05$). Comparing different grades of a tumour, expression of Her-2 was detected in 31.8% of well-differentiated tumours, 36.0 % in moderately differentiated tumours and 66.66 % in poorly differentiated cancers. The expression of Her-2 was increased in high-grade tumours, and the difference of expression level between tumour grades was statistically significant ($p < 0.05$). The expression level of Her-2 protein was not correlated with the stage of a tumour ($p > 0.05$).

CONCLUSION: The present study supports earlier findings that over-expression / up-regulation of VEGF and Her-2 is linked with poor prognosis and may play a vital role in the development and progression of cervical cancer.

Introduction

Cervical cancer is the most common form of female genital malignancy and is a principal cause of cancer-associated mortality. Despite numerous studies, the exact carcinogenetic events in the development and progression of cervical cancer are not entirely understood. In this regard, hormonal imbalance, smoking and obesity are suggested to be the chief causative agents in the development and progression of cervical cancer. Additionally, Human Papillomavirus (HPV) has been recognised as an etiological agent in the pathogenesis of uterine cervix cancer [1][2] and epidemiological studies have shown

that HPV infection is commonly identified in invasive cervical cancer [3].

Angiogenesis has also been shown to play a vital role in tumour development and progression through the formation of new blood vessels. Vascular endothelial growth factor (VEGF) acts as the chief mediator of tumour angiogenesis and stimulates the growth of new blood vessels [4]. It has been shown that VEGF plays an important role in inducing angiogenesis in some physiological and pathological processes [5]. Moreover, VEGF expression may be induced by various factors such as altered expression of tumour suppressor genes [6], oncogenes [7][8], insulin-like growth factor – 1 [9] and altered VEGF expression has been associated with

both the advanced pathological stage of cancer and lymph node metastasis [10].

The human epidermal growth factor receptor 2 (Her2) is a transmembrane receptor tyrosine kinase [11][12] and has been shown to play a significant role in the pathogenesis of tumours. Her2-gene amplification appears to be an early event in the development of cancer [13]. Up-regulation of Her-2 has been noticed in the genesis of numerous cancers including cervical cancer.

The current study aimed to examine the expression patterns of VEGF and Her-2 proteins in cervical cancer and correlate the expression pattern of both markers with clinic-pathological features observed in patients.

Materials and Methods

Patients and tissues

Tissue from a total of 65 patients (mean age 65 ± 14 years, range 26 – 98 years) diagnosed with cervical carcinoma was collected from the Histopathology Department at the National Health Laboratory (and other histopathology laboratories) in Sudan. A total of 10 cases of inflammatory lesions of the cervix were included in the study as a control group. The study was approved by the institutional Research Ethics Committee, and written consent was obtained from each patient. Hematoxylin and Eosin (H&E) staining were performed on each case to evaluate the histopathology of tissue samples, including grade and stage of a tumour (Figure 1). The detailed clinic-pathological feature of the patients is presented in Table 1. A series of 5 – μm -thick sections were prepared from each formalin-fixed, paraffin-embedded block and immunohistochemical staining was performed to evaluate the expression pattern of VEGF and Her-2 protein to allow its interpretation and correlation with clinical outcome.

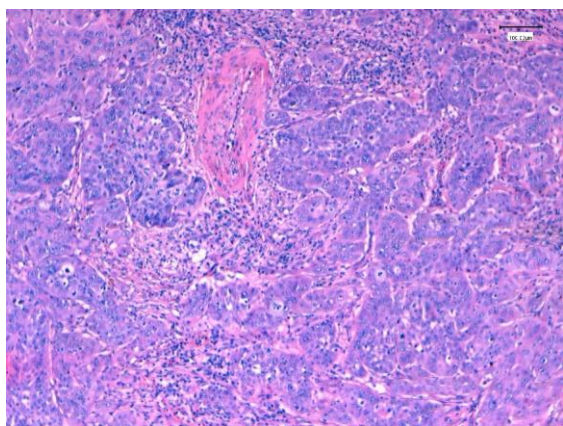


Figure 1: Section from cervical carcinoma grade II(H & E X40)

Table 1: Correlation between VEGF and clinicopathological features in cervical carcinoma

Variables	Total cases	VEGF positive	VEGF negative	the
Cervical carcinoma	65	41 (63.07%)	24 (36.92%)	< 0.05
Inflammatory lesion	10	0 (0%)	10 (100%)	
Age (In years)				
≤ 55 years	28	16 (57.14%)	12 (42.85%)	> 0.05
> 55 years	37	25 (67.56%)	12 (32.43%)	
Histological grades				
Well differentiated	22	12 (54.54%)	10 (45.45%)	
Moderately differentiated	25	17 (68.00%)	14 (32.55%)	
Poorly differentiated	18	12 (66.66%)		> 0.05
Histologic type				
Squamous Cell Carcinoma	59	38 (64.4%)	21 (35.59%)	
Adenocarcinoma	6	3 (50.0%)	3 (50.0 %)	> 0.05
Clinical stage				
I	14	7 (50.0%)	7 (50.0%)	> 0.05
II	17	11 (64.7%)	6 (35.29%)	
III and IV	34	23 (67.64%)	11 (32.35%)	

Immunohistochemical staining

Five μm sections from each paraffin-embedded tissue block were prepared from cervical cancer and inflammatory lesions. Immunohistochemical staining was performed on paraffin-embedded tissue sections as described by Rahmani et al., 2015 [14]. In brief, deparaffinization of all sections was made through a series of xylene solutions, and rehydration was performed through graded ethanols. Also, endogenous peroxidase activity was blocked by pre-treatment of sections with 0.3% hydrogen peroxide for 20 minutes. Antigen retrieval was performed using a sodium-citrate buffer (pH 6.0), in a microwave oven for 30 minutes. Additionally, protein blocking agent (Abcam, USA) was applied for 10 minutes to reduce nonspecific binding. VEGF and Her-2 antihuman monoclonal antibodies (Abcam, Cambridge, MA, USA) were used as primary antibodies followed by the secondary biotinylated antibody (Abcam, USA). Detection of immunostaining for VEGF and Her-2 protein was performed using the streptavidin-biotin method. Diaminobenzidine (DAB) chromogen (Abcam, USA) was applied then sections were counterstained and mounted with DPX. Negative controls (omission of primary antibody) and positive controls were used to verify the quality of staining.

Staining Interpretation

Expression of VEGF and Her-2 protein was evaluated, and the mean percentage positivity was calculated. Five fields from each section were selected, and positive cells for each marker (lowest to the highest number of positive cells) were counted at 40 X magnification. Specimens were considered as positively stained when more than 10% of the tumour cells showed cytoplasmic expression for VEGF and membranous or cytoplasmic stain for Her2 protein. If 10% or less than 10 % of cells showed cytoplasmic expression, they were classified as negative cases.

Statistical analysis

Expression of markers was correlated with clinicopathological features of the patients. Chi-square (χ^2) test was used to make the correlation of marker with grade, age and stage of the tumour. Statistical significance was defined as $p < 0.05$.

Results

Association of VEGF protein expression with clinicopathological characteristics

The expression pattern of VEGF was examined in uterine cervix cancer including squamous cell carcinoma (SCC), adenocarcinoma and inflammatory lesions of the cervix. The expression of VEGF was detected only in the cytoplasm of cancer cells (Figure 2, a-c) whereas control cases did not show any expression. VEGF protein showed expression in fewer than 10% of cells or no expression in all ten inflammatory lesions and these were thus considered as negative for VEGF expression.

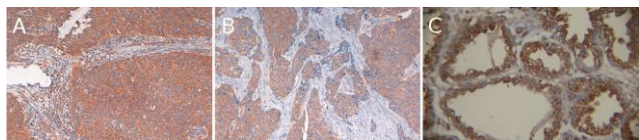


Figure 2: a) Immunohistochemical staining of VEGF protein demonstrating strong cytoplasmic expression in a cervical carcinoma (Orig mag. 40X); b) Immunohistochemical staining of VEGF protein showing moderate cytoplasmic expression in a cervical carcinoma (Orig mag. 40X); c) Expression of VEGF protein in section from carcinoma of cervix (Orig mag. 40X)

Conversely, greater than 10% positivity for VEGF staining was observed in 41/65 (63.07%) cases of cervical cancer patients, and these were considered VEGF positive. The difference in VEGF expression between cancer cases and control cases was statically significant ($p \leq 0.05$). Moreover, the expression level for VEGF was correlated with tumour grade was found to be positive in 12/22 (54.54%) well-differentiated tumours, 17/25 (68.00%) samples of moderately and 12/18 (66.66%) poorly differentiated carcinoma. The difference in VEGF expression between different grades of a tumour did not reach statistical significance ($p > 0.05$) (Table 1), and intensity of expression was high in poorly differentiated carcinoma as compared to well and moderately differentiated carcinoma.

Additionally, the expression of VEGF was evaluated according to the stage of cancer, and it was found that VEGF expression was positive in 7/14 (50%) Stage I samples, 11/17 (64.7%) stage II samples and 23/43 (67.64%) stage III and IV samples (Table 1). The difference of VEGF expression observed in the different tumour stages was also

found to be statically insignificant ($p > 0.05$). The expression of VEGF was also correlated with the age of the patients (younger than 55 years and equal or older than 55 years). Again, no significant difference was observed between samples from different age groups.

Expression pattern of Her-2 protein in cervical cancer and inflammatory lesions

Her-2 protein was not detected in inflammatory lesions of the cervix while there were strong expression observed in 28/65 (43.07%) carcinoma cases (Figure 3) ($p < 0.05$). Expression analysis of Her-2 protein in different tumour grades showed that Her-2 expression was increased with a grade of a tumour. Her-2 expression was detected in 7/22 (31.8%) well-differentiated tumours, 9/25 (36.0%) moderately differentiated tumours and 12/18 (66.66%) poorly differentiated cancers (Table 2). Her-2 expression showed a significant difference in expression between different grades of cancer ($p < 0.05$).

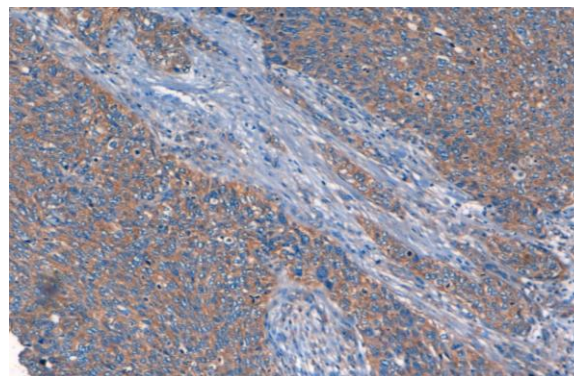


Figure 2: Immunohistochemical expression of Her-2 protein in poorly differentiated cervical carcinoma (Orig Mag. 40X)

The immunoreactivity of Her-2 was not found to be correlated with stage of a tumour, Her-2 expression observed in 6/14 (42.85%) Stage I, 11/17 (64.7%) Stage II and 17/34 (50.0%) Stage III/IV tumours (Table 2). Moreover, the expression profile of Her-2 protein also showed no significant difference between different age groups of patients (≤ 55 years and > 55 years).

Table 2: Correlation between Her-2 protein and clinicopathological features of cervical carcinoma

Variables	Total cases	Her-2 positive	Her-2 negative	p - value
Cervical carcinoma	65	28 (43.07%)	37 (56.92%)	< 0.05
Inflammatory lesion	10	0 (0%)	10 (100%)	
Age (In years)				> 0.05
≤ 55 years	28	11 (39.28%)	17 (60.71%)	
> 55 years	37	17 (45.94%)	20 (54.05%)	
Histological grades				< 0.05
Well differentiated	22	7 (31.8%)	15 (68.18%)	
Moderately differentiated	25	9 (36.0%)	16 (64%)	
Poorly differentiated	18	12 (66.66%)	6 (33.33%)	
Histologic type				> 0.05
Squamous Cell Carcinoma	59	25 (42.37%)	34 (57.62%)	
Adenocarcinoma	06	3 (50.0%)	3 (50%)	
Clinical stage				> 0.05
I	14	6 (42.85%)	8 (57.14%)	
II	17	11 (64.7%)	6 (35.29%)	
III and IV	34	17 (50.0%)	17 (50.0%)	

Relationship between VEGF protein expression, and Her 0-2 expression with clinicopathologic features

Both proteins VEGF and Her-2 showed high levels of expression in cancer cases while none of the control lesions that were studied showed positive expression. The difference in expression for both markers comparing cancer cases and control cases were thus statically significant. Furthermore, the immunoreactivity of Her-2 marker increased according to grades of a tumour whereas VEGF did not show a significant difference in expression when comparing tumour grade. Both markers did not show any significant difference in the level of expression when comparing different age groups of patients.

Discussion

Angiogenesis is the process of formation of new blood vessels from sprouting of existing vessels. Extensive laboratory data suggests that new vessel formation is an important step in driving tumour growth and progression [15][16][17]. Vascular Endothelial Growth Factor (VEGF) is one of the chief angiogenic factors that stimulate the formation of new blood vessels and thus can influence tumour growth [18]. Previous studies have confirmed that over-expression of VEGF can be correlated with tumour growth, metastasis and patient survival [19][20][21]. Altered expression of VEGF has been observed in cancers and strongly suggesting that angiogenesis participates in tumour development and progression. In the current study, it was found that VEGF expression was high in 41 (63.07%) in cervical carcinoma cases while inflammatory lesions did not show detectable expression. The difference in expression of VEGF in cancer cases and control cases was found to be statistically significant ($p < 0.05$). These findings are consistent with an earlier study on cervical cancer, which reported that VEGF was not expressed in control tissue samples whereas VEGF expression was high in patients with high-grade squamous intraepithelial (HSIL) lesions (33.33%) and patients with cervical cancer (60.87%) [22], showing a statistically significant difference between tumour samples and control [22].

Another study also reported that VEGF expression progressively increased along a continuum from normal epithelium to invasive SCC [23]. Our findings showed that immunostaining was high in high-grade tumours and slightly increased according to the grade of a tumour, this difference was not statistically significant ($p > 0.05$). A study examining transitional cell carcinoma of the urinary bladder reported that VEGF immunostaining was positively

correlated with grade, stage, and recurrence of transitional cell carcinoma but the findings were not statistically significant [24] while another study on urinary bladder carcinoma showed that the rate of VEGF expression increased significantly with the progression of tumour grade [25]. An earlier report looking at cervical cancer stated that high VEGF immunostaining was observed in grade III cervical intraepithelial neoplasia whereas expression was found to be low in grade I cervical intraepithelial neoplasia and in control group samples [26]. Lastly, an earlier study also found that there was no significant difference between VEGF expressions in tumours of various grades of differentiation [27].

In the current study, the expression of VEGF protein was analysed in different age groups of the patients (≤ 55 years and > 55 years), and it was found that there was no significant difference between age groups ($p > 0.05$). A previous study also reported no correlation between age and VEGF positive tumours, with the number of VEGF positive tumours in patients < 50 years 58.0 %, while 50-55 years showed 63.75%, and > 55 years was 52.9%, all of these differences showing no statistical significance [27].

Her-2 belongs to the family of *HER* genes that control cell growth, survival, differentiation and migration [28][29]. Her-2 over-expression has been noticed in invasive breast cancers [30], gastric cancer [31] and previous studies examining cervical cancer reported that 29.7% tumours expressed the c-erbB-2 (Her-2) protein [32]. The present study was also aimed to measure the expression of Her-2 in cervical cancer, and positive immunostaining was observed in 28 (43.07%) cases while the control group did not show any expression. This is similar to a previous study examining lesions of the uterine cervix, which reported that higher expression of Her-2/neu was noticed in malignant lesions as compared to benign lesions [33]. Moreover, expression of the Her-2 protein was found to be higher in high-grade tumours when compared to low-grade tumours. The difference of Her-2 expression between the tumour grades was found to be statistically significant ($p < 0.05$) in this study. Furthermore, an earlier study reported that malignancies exhibited a variable degree of Her-2 expression with significantly higher expression observed in high-grade squamous cell carcinomas [33]. Lastly, another study reported similar findings where benign, premalignant and malignant cervical tissues showed a highly significant correlation between the expression of the epidermal growth factor receptor (EGF-R), the oncogene product of c-erbB-2 and the histological grade of the lesion [34]. In the current study, immunoreactivity of Her-2 was not correlated with stage of a tumour. This differs from two previous reports that showed Her-2 positivity was higher in Stage III (87.50%) and stage IV (100%) tumors as compared to stage I (48.28%) and Stage II

(72.22%) [33]; and that stronger Her-2/neu expression were observed in higher stage tumors [35].

The present study supports earlier findings that overexpression/up-regulation of VEGF and Her-2 protein in cervical cancer are linked to poor prognosis and that expression of these proteins may play vital roles in the development and progression of cervical cancer.

References

- Villa LL. Papillomaviruses and cervical cancer. *Adv Cancer Res.* 1997; 71:321-341. [https://doi.org/10.1016/S0065-230X\(08\)60102-5](https://doi.org/10.1016/S0065-230X(08)60102-5)
- ZurHausen H. Papillomavirus infections - a major cause of human cancers. *Biochim Biophys Acta.* 1996; 1288:F55-F78.
- Walboomers JM, Jacobs MV, Manos MM, et al. Human papillomavirus is a necessary cause of invasive cervical cancer worldwide. *J Pathol.* 1999; 189:12-19. [https://doi.org/10.1002/\(SICI\)1096-9896\(199909\)189:1<12::AID-PATH431>3.0.CO;2-F](https://doi.org/10.1002/(SICI)1096-9896(199909)189:1<12::AID-PATH431>3.0.CO;2-F)
- Kajdaniuk D, Marek B, Borgiel-Marek H, Kos-Kudła B. Vascular endothelial growth factor (VEGF) - part 1: in physiology and pathophysiology. *Endokrynol Pol.* 2011; 62(5):444-55. PMID:22069106
- Bergers G, Benjamin LE. Tumorigenesis and the angiogenic switch. *Nat Rev Cancer.* 2003; 3:401-410. <https://doi.org/10.1038/nrc1093> PMID:12778130
- Kieser A, Weich HA, Brandner G et al. Mutant p53 potentiates protein kinase C induction of vascular endothelial growth factor expression. *Oncogene.* 1994; 9:963-969. PMID:8108142
- Grugel S, Finkenzeller G, Weindel K et al. Both v-Ha-Ras and v-Raf stimulate expression of the vascular endothelial growth factor in NIH 3T3 cells. *J Biol Chem.* 1995; 270:25915-25919. <https://doi.org/10.1074/jbc.270.43.25915>
- Mukhopadhyay D, Tsiokas L, Sukhatme VP. Wild-type p53 and v-Src exert opposing influences on human vascular endothelial growth factor gene expression. *Cancer Res.* 1995; 55:6161-6165. PMID:8521408
- Warren RS, Yuan H, Matli MR et al. Induction of vascular endothelial growth factor by insulin-like growth factor 1 in colorectal carcinoma. *J Biol Chem.* 1996; 271:29483-29488. <https://doi.org/10.1074/jbc.271.46.29483> PMID:8910616
- Shariat SF, Youssef RF, Gupta A, Chade DC, Karakiewicz PI, Isbarn H, Jeldres C, Sagalowsky AI, Ashfaq R, Lotan Y. Association of angiogenesis related markers with bladder cancer outcomes and other molecular markers. *J Urol.* 2010; 183(5):1744-50. <https://doi.org/10.1016/j.juro.2010.01.018> PMID:20299037
- Yarden Y, Sliwkowski MX. Untangling the ErbB signalling network. *Nat Rev Mol Cell Biol.* 2001; 2:127-137. <https://doi.org/10.1038/35052073> PMID:11252954
- Gschwind A, Fischer OM, Ullrich A. The discovery of receptor tyrosine kinases: targets for cancer therapy. *Nat Rev Cancer.* 2004; 4:361-370. <https://doi.org/10.1038/nrc1360> PMID:15122207
- Chong D, Cooke TG, Reeves JR et al. Quantitation of EGFR and c-erbB-2 expression in preinvasive compared to invasive breast cancers. *ECCO 10 Conference, 12-16 September, 1999 (Abstr 792A)* [https://doi.org/10.1016/S0959-8049\(99\)81219-2](https://doi.org/10.1016/S0959-8049(99)81219-2)
- Rahmani AH, Babiker AY, Al Wanian WM, Elsiddig SA, Faragalla HE, Aly SM. Association of cytokeratin and vimentin protein in the genesis of transitional cell carcinoma of urinary bladder patients. *Dis Markers.* 2015; 2015:204759. <https://doi.org/10.1155/2015/204759> PMID:26640315
- PMCid:PMC4660019
- Folkman J. What is the evidence that tumors are angiogenesis dependent? *J Natl Cancer Inst.* 1990; 82:4-6. <https://doi.org/10.1093/jnci/82.1.4> PMID:1688381
- Folkman J. The vascularization of tumors. *Sci Am.* 1976; 234:58-73. <https://doi.org/10.1038/scientificamerican0576-58> PMID:1273568
- Folkman J. Tumor angiogenesis. In: Wells SA Jr, Sharp PA, editors. *Accomplishments in Cancer Research.* Pennsylvania: JB Lippincott Williams and Wilkins, 1998:32-44.
- Donmez G, Sullu Y, Baris S, Yildiz L, Aydin O, Karagoz F, Kandemir B. Vascular endothelial growth factor (VEGF), matrix metalloproteinase-9 (MMP-9), and thrombospondin-1 (TSP-1) expression in urothelial carcinomas. *Pathol Res Pract.* 2009; 205(12):854-7. <https://doi.org/10.1016/j.prp.2009.07.015> PMID:19762163
- Zetter BR. Angiogenesis and tumor metastasis. *Annu Rev Med.* 1998; 49:407-24. <https://doi.org/10.1146/annurev.med.49.1.407> PMID:9509272
- Carmeliet P. Angiogenesis in health and disease. *Nat Med.* 2003; 6:653-660. <https://doi.org/10.1038/nm0603-653> PMID:12778163
- Risau W. Mechanisms of angiogenesis. *Nature.* 1997; 386:671-674. <https://doi.org/10.1038/386671a0> PMID:9109485
- Mandic A, Usajknezevic S, Kapicllvkovic T. Tissue expression of VEGF in cervical intraepithelial neoplasia and cervical cancer. *J BUON.* 2014; 19(4):958-64. PMID:25536602
- Fujiwaki R, Hata K, Iida K, Maede Y, Miyazaki K. Vascular endothelial growth factor expression in progression of cervical cancer: correlation with thymidine phosphorylase expression, angiogenesis, tumor cell proliferation, and apoptosis. *Anticancer Res.* 2000; 20(2B):1317-22. PMID:10810442
- Al-Abbasi DS, Al-Janabi AA, Al-Torhi KM, Jabor TA, Yasseen AA. Expression of VEGF in urinary bladder transitional cell carcinoma in an Iraqi population subjected to depleted uranium: an immunohistochemical study. *Appl Immunohistochem Mol Morphol.* 2009; 17(4):307-11. <https://doi.org/10.1097/PAI.0b013e3181941794> PMID:19151604
- Rahmani A, Alzohairy M, Khadri H, Mandal AK, Rizvi MA. Expressional evaluation of vascular endothelial growth factor (VEGF) protein in urinary bladder carcinoma patients exposed to cigarette smoke. *Int J Clin Exp Pathol.* 2012; 5:195-202. PMID:22558473 PMCid:PMC3341674
- Belfort-Mattos PN, Focchi GR, Speck NM, Taha NS, Carvalho CR, Ribalta JC. Immunohistochemical expression of granzyme B and vascular endothelial growth factor (VEGF) in normal uterine cervixes and low and high grade squamous intraepithelial lesions. *Eur J Gynaecol Oncol.* 2010; 31:459-461. PMID:20882896
- Goncharuk IV, Vorobjova LI, Lukyanova NY, Chekhun VF: Vascular endothelial growth factor expression in uterine cervical cancer: correlation with clinicopathologic characteristics and survival. *Exp Oncol.* 2009; 31(3):179-181. PMID:19783962
- Schechter AL, Stern DF, Vaidyanathan L, et al. The neu oncogene: an erb-B-related gene encoding a 185,000-Mr tumour antigen. *Nature.* 1984; 312:513-516. <https://doi.org/10.1038/312513a0> PMID:6095109
- Rubin I, Yarden Y. The basic biology of HER2. *Ann Oncol.* 2001; 12(Suppl 1):S3-S8. https://doi.org/10.1093/annonc/12.suppl_1.S3 PMID:11521719
- Kaplan S, Tan LK, Chen B. Her2 and breast cancer. *Diagn Mol Path.* 2001; 10:139-152. <https://doi.org/10.1097/00019606-200109000-00001>
- Gravalos C, Jimeno A. Her2 in gastric cancer, a new prognostic factor and a novel therapeutic target. *Ann Oncol.* 2008; 19:1093-1100. <https://doi.org/10.1093/annonc/mdn169>
- Lee JS, Kim HS, Jung JJ, Lee MC, Park CS: Expression of vascular endothelial growth factor in adenocarcinomas of the uterine cervix and its relation to angiogenesis and p53 and c-erbB-

2 protein expression. *Gynecol Oncol.* 2002; 85:469-475.
<https://doi.org/10.1006/gyno.2002.6648>

33. Gupta N, Singh S, Marwah N, Kumar S, Chabra S, Sen R. HER-2/neu expression in lesions of uterine cervix: is it reliable and consistent? *Indian J Pathol Microbiol.* 2009; 52(4):482-5.
<https://doi.org/10.4103/0377-4929.56127> PMID:19805951

34. Lakshmi S, Nair MB, Jayaprakash PG, Rajalekshmy TN, Nair MK, Pillai MR. c-erbB-2 oncoprotein and epidermal growth factor

receptor in cervical lesions. *Pathobiology.* 1997; 65:163–168.
<https://doi.org/10.1159/000164118> PMID:9309783

35. Sarwade P, Patil S, Bindu R. Immunohistochemistry study for Her-2/neu expression in lesions of uterine cervix. *Int J Cur Res Rev.* 2016; 8:5-57.