

# Treatment of a Patient with Merkel Cell Skin Carcinoma Using Radiation Therapy - A Case Report

Andrej Petrov<sup>1,2\*</sup>, Slavica Krалеva<sup>1</sup>, Katerina Kubelka-Sabit<sup>1</sup>, Deva Petrova<sup>1</sup>

<sup>1</sup>Acibadem Sistina Hospital, Skopje, Republic of Macedonia; <sup>2</sup>Faculty of Medical Sciences, University Goce Delchev, Shtip, Republic of Macedonia

## Abstract

**Citation:** Petrov A, Krалеva S, Kubelka-Sabit K, Petrova D. Treatment of a Patient with Merkel Cell Skin Carcinoma Using Radiation Therapy - A Case Report. Open Access Maced J Med Sci. <https://doi.org/10.3889/oamjms.2018.120>

**Keywords:** Carcinoma; Merkel cell; Radiotherapy

\***Correspondence:** Andrej Petrov. Acibadem Sistina Hospital, Skopje, Republic of Macedonia. E-mail: [petrovandrej555@gmail.com](mailto:petrovandrej555@gmail.com)

**Received:** 01-Feb-2018; **Revised:** 30-Mar-2018; **Accepted:** 04-Apr-2018; **Online first:** 14-Apr-2018

**Copyright:** © 2018 Andrej Petrov, Slavica Krалеva, Katerina Kubelka-Sabit, Deva Petrova. This is an open-access article distributed under the terms of the Creative Commons Attribution-NonCommercial 4.0 International License (CC BY-NC 4.0)

**Funding:** This research did not receive any financial support

**Competing Interests:** The authors have declared that no competing interests exist

**BACKGROUND:** Merkel cell carcinoma (MCC) is a rare, very aggressive tumour. The pathogenesis remains unclear, but UV radiation, immunosuppression, and the presence of Merkel cell polyomavirus in the tumour genome appear to have a key role. Merkel cell carcinoma is a highly aggressive tumour that often has a lethal end.

**CAS REPORT:** A patient at 93 years of age comes for an examination by a dermatologist due to a rapidly growing nodular tumour growth in the forehead area. A tumour was about 3 cm in size. It had no signs of basal-cell carcinoma, no arborising vascularisation, no pigmentations on dermoscopy. Clinically, an eventual Merkel cell carcinoma was considered for the patient, but other primary skin tumours had to be excluded, as well as the possibility that regarding the patient's age, it may be a metastatic deposit. A skin biopsy was performed, as well as H-E examination and immunohistochemical analyses (positive CD56, positivity of neuroendocrine markers synaptophysin, chromogranin) which were in favour of Merkel cell carcinoma of the skin. After setting the diagnosis, our patient was treated with therapy which led to a complete withdrawal of a tumour. However, after 3 months the patient had repeated relapse of a tumour at the same site on the forehead and metastases in the retroauricular lymph nodes bilaterally. It shows that the radiotherapy as monotherapy has a great effect on the removal of the tumour formation, but unfortunately, it has no impact on lesion recurrence. It is also compatible with the literature data.

**CONCLUSION:** In many adult patients, as our case suggests, radiotherapy could be a good palliative treatment opportunity that should be considered, as well as a combination of radiation therapy with other oncologic therapeutic options.

## Introduction

Merkel cell carcinoma (MCC) is a rare, very aggressive tumour, with quite common local or regional recurrences and with high metastatic potential. MCC usually develops in areas of the skin exposed to sunlight, in patients of advanced age. Its incidence has grown four times over the past decades due to the ageing of the population and immunohistochemical techniques leading to the diagnosis. The pathogenesis remains unclear, but UV radiation, immunosuppression, and the presence of Merkel cell polyomavirus in the tumour genome appear to have a key role. Toker was the author who first described a tumour in 1972. He used the term trabecular carcinoma of the skin, suggesting a possibility of glandular origin. Ultrastructural studies made 6 years later by Tang and Toker indicated a presence of electron-dense granules in the cytoplasm of the tumour cells. They suggested a neuroendocrine

origin, similar to Merkel cells in the epidermis. The term cutaneous neuroendocrine carcinoma may be the one that best describes the immunohistochemical and ultrastructural phenomena of these tumours, but the most widely used and ultrastructurally accepted name in the literature is MCC [1].

Merkel cell carcinoma (MCC) is typically presented as a painless, rapidly growing, cubist red or purple nodule of sun-exposed areas of the skin, such as the head and the neck, or the upper limbs. Aetiology is multifactorial, with immunosuppression, UV-induced skin damage and viral factors [2].

According to the NCCN, resection of a tumour in healthy tissue is the basic therapy. Patients at high risk may also undergo adjuvant radiotherapy. The role of chemotherapy is unclear. The incidence of Merkel cell carcinoma in the United States is estimated to be 0.32/100.000 [3].

Merkel cell polyomavirus (MCPyV) was discovered in 2008 and still is the only human

polyomavirus that can be causally associated with human malignancy, i.e. Merkel cell carcinoma [4].

Merkel cell carcinoma is a highly aggressive tumour that often has a lethal end. Clonal colonisation with Merkel cell polyomavirus in the host genome may have a role in the carcinogenesis or the UV-induced carcinogenesis. Viral-encoded oncoproteins and UV-induced mutations affect the related signalling pathway such as RB restriction of cell cycle progression or p53 inactivation. Although its relatively low incidence Merkel cell carcinoma has drawn much attention recently due to immunogenetics and immunomodulatory treatments [5].

MCC is characterised by the acronym (from English words) AEIOU.

Most cases of MCC occur in a population at obvious high risk of developing this tumour. AEIOU features can be useful in identifying a suspected lesion [6] [7].

"A" is for asymptomatic. MCC is typically asymptomatic compared to an inflamed cyst, which it may sometimes resemble.

"E" is for expanding rapidly; a node that increases in 1-2 months.

"I" is for immunocompromised. 92% of patients with MCC are not immunocompromised, but those with long-standing T cell dysfunction (HIV, leukaemia, chronic immunosuppression) are at a much greater risk to develop MCC although they represent less than 10% of the cases.

"O" is for patients older than 50 years. The risk of MCC increases with age due to the immunosenescence (the immune system is less capable of detecting immunogenic cancer).

"U" is for the ultraviolet radiation-exposed fair skin.

Ninety of the patients have 3 or more of the AEIOU features. But this is not specific since some lipomas or cysts can meet 2 or 3 criteria.

Treatment is based on multidisciplinary management, although the optimal therapy is still controversial due to lack of data. Aggressive surgery, which is often associated with adjuvant radiotherapy, improves the locoregional recurrence and overall survival [8]. According to some authors, surgery and radiotherapy achieve excellent locoregional control. However, a certain percentage of patients develop a disseminated disease that is incurable. Chemotherapy has a great response in metastatic disease, but the response is short-lived, and the survival impact has not been established [9].

There are rare cases of metastatic disease. The disease usually metastasises in the local lymph nodes, but there are also cases of pleural metastases. [10] Immunohistochemical analysis of a section stained with hematoxylin and eosin indicates tumour

cells with infiltrative growth and hyperchromatic nuclei that have been positive for CK20, CD56, chromogranin and synaptophysin [11]. Survival at 5 years is 51% for local disease and is low as 14% for distant disease, which underscores the aggressive nature of this tumour and challenges in management [12].

## Case Report

The clinical examination is the first step in MCC diagnosis. The nonspecific and varied clinical features of this tumour pose certain diagnostic challenges even for an experienced dermatologist. Unlike basal cell carcinoma or melanoma, which may be clinically or dermatoscopically apparent, the "classic" MCC lesion does not exist [12].

A patient at 93 years of age comes for an examination by a dermatologist due to a rapidly growing erythematous nodule growth in the forehead area. A tumour was about 3 cm in size. It had no signs of basal-cell carcinoma, no arborising vascularisation, no pigmentations on dermatoscopy. The polymorphous vascular pattern has been observed.

Clinically, an eventual Merkel cell carcinoma was considered for the patient, but other primary skin tumours had to be excluded, as well as the possibility that regarding the patient's age, it may be a metastatic deposit [13].

A skin biopsy was performed, as well as H-E examination and immunohistochemical analyses (positive CD56, positivity of neuroendocrine markers synaptophysin, chromogranin) which were in favour of Merkel cell carcinoma of the skin.

The biopsy specimen was formalin fixed and paraffin moulded. Besides the routine hematoxylin and eosin stained tissue sections, additional immunohistochemical analyses were performed on DAKO Autostainer link 48, an automatic immunohistochemical stainer, using monoclonal ready to use antibodies from Agilent Technologies.

Histopathological analysis of the biopsy specimen detected a presence of neoplastic cells in the dermis, arranged in solid sheets with areas of "crush effect", composed of relatively uniform cells. The neoplastic cells had small basophilic nuclei and very scant cytoplasm consistent with the histopathological finding of small cell variant of MCC (Figure 1A). Numerous mitotic figures were evident. To confirm the neuroendocrine nature of the tumour cell, additional immunohistochemical analyses were performed. The immunohistochemical analysis indicated that tumour cells were positive for neuroendocrine markers chromogranin (Figure 1B) and synaptophysin (Figure 1C), whereas they were

negative for cytokeratins 5/6 (Figure 1D), cytokeratin 7, CD45, TTF1, as well as for cytokeratin 20 (Figure 1E). Ki-67 proliferative index was more than 90% (Figure 1F).

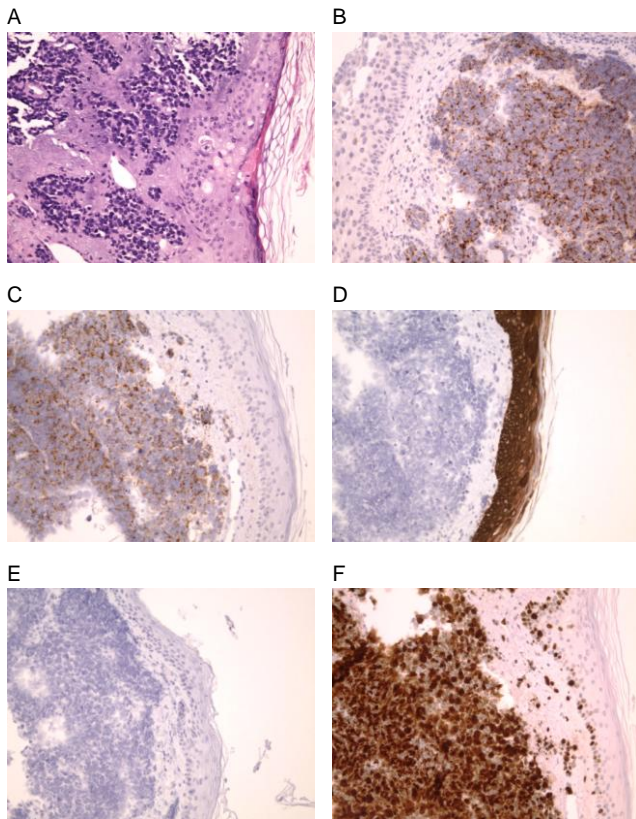


Figure 1: A) Histological appearance of the tumor (hematoxylin and eosin, x200); B) Neoplastic cells show positivity for Chromogranin (x200); C) Neoplastic cells show positivity for Synaptophysin (x200); D) Neoplastic cells are negative for cytokeratins 5/6 (x200); E) Neoplastic cells are negative for cytokeratin 20 (x200); F) Ki-67 proliferative index is >90% (x200)

The performed CT examination indicated no presence of other tumour formations in the deep tissues of the head and the neck. The finding was normal.

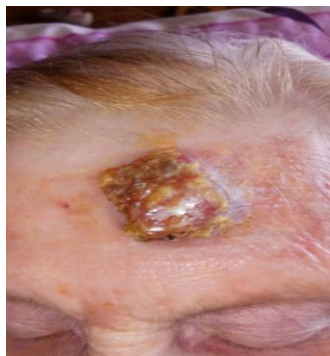

Figure 2: Patient before treatment

After CT simulation in the patient, a plan for radiation of the skin efflorescence in the frontal area was made. The treatment used X-rays with an energy

of 6MV and a total dose of 40 Gy during 10 fractions. The patient achieved a full-scale remission of the lesions. There was no tumour recurrence in the monitoring period of 3 months.

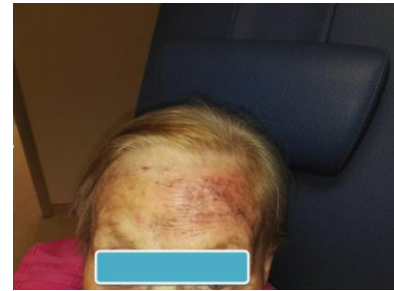

Figure 3: Patient after radiation treatment

## Discussion

Merkel cell carcinoma (MCC) usually has a clinical presentation in the form of a solitary, solid, well-defined nodule which is erythematous or purple, and mobile about the subcutaneous tissue.

Staging classification of the disease is done according to the American Joint Committee on Cancer.

Table 1: TNM Classification of MCC according to the American Joint Committee on Cancer

Tumour	Node	Metastasis
Tx, the tumour cannot be assessed	Nx, lymph node involvement cannot be assessed	Mx, metastasis cannot be assessed
T0, no evidence of a primary tumour	N0, no lymph node involvement	M0, no metastasis
This, primary tumour in situ	-cN0, no clinical signs of lymph node involvement (on inspection, palpation, and radiograph)	M1, distant metastasis
T1, primary tumour ≤ 2 cm	-pN0, no lymph node involvement detected by a pathologist	-M1a, metastasis to the skin, subcutaneous cellular tissue, or distant lymph nodes
T2, primary tumour >2 cm and ≤ 5 cm	-pNx, no histology of lymph nodes	-M1b, metastasis to the lung
T3, primary tumour >5 cm	N1a, micrometastasis <sup>b</sup>	-M1c, metastasis to other visceral organs
T4, a primary tumour affecting bone, muscle, fascia, or cartilage	N1b, macrometastasis <sup>c</sup>	
	N2, in-transit metastasis <sup>d</sup>	

Abbreviations: MCC, Merkel cell carcinoma; a - Adapted by [1]; b - Micrometastases refer to clinically undetectable lymph nodes that are affected by the disease found in a sentinel lymph node or by elective dissection; c - Macrometastases refer to clinically evident and pathologically proven regional lymph nodes that are affected by the disease, using dissection or punch biopsy; d - In-transit metastases refer to metastases that are found between the primary tumor and the regional lymph nodes or distally of the primary tumor.

After setting the diagnosis, our patient was treated with therapy which led to a complete withdrawal of a tumour.

However, after 3 months the patient had repeated relapse of a tumour at the same site on the forehead and metastases in the retroauricular lymph nodes bilaterally. It shows that the radiotherapy as monotherapy has a great effect on the removal of the

tumour formation, but unfortunately, it has no impact on lesion recurrence.

**Table 2: Staging of MCC according to the American Joint Committee on Cancer**

Stage	Tumour	Lymph Nodes	Metastasis	5-Year Survival, % <sup>a</sup>
0	This	N0	M0	100
IA	T1	pN0	M0	79
IB	T1	cN0	M0	60
IIA	T2/T3	pN0	M0	58
IIB	T2/T3	cN0	M0	49
IIC	T4	N0	M0	47
IIIA	Any T	N1a	M0	42
IIIB	Any T	N1b/N2	M0	26
IV	Any T	Any N	M1	18

Abbreviations: MCC, Merkel cell carcinoma.

It is also compatible with the literature data. A study of 1.227 patients has proven that survival of 5 years is greater in patients with performed resection of the tumour formation in healthy tissue, compared to the definite radiotherapy of the disease [11].

In conclusion, an increase of MCC incidence in recent years has drawn attention to this malignant disease that attacks older people. [14] This is especially relevant to the increase in patient's lifespan. Treatment of Merkel cell carcinoma on the head and the neck requires an early and adequate diagnosis so that proper treatment can start. AEIOU (acronym) rule can be of great help in raising suspicion to this tumour. It includes surgery, radiotherapy and/or combined chemotherapy. An adequate stage assessment of the cervical lymph node is of supreme importance prior starting the definitive plan for treatment of the disease [15].

Partial or complete regression of the tumour is also observed but is a rare phenomenon. Regression is accompanied by dense lymphocytic infiltrate predominantly from CD8 phenotype and apoptosis [16].

Definitive radiation monotherapy is an alternative to surgery, for patients who are poor surgical candidates, or those in whom surgery would result in significant functional compromise. The outcomes of radiation monotherapy may be inferior compared to complete surgical resection. Overall survival is decreased (37-39%, 5 years survival with radiation monotherapy) compared to complete surgical resection [17]. In many adult patients, as our case suggests (93 years old patient, 3 cm tumour size), radiotherapy could be considered as treatment opportunity, but is not preferable, since tumour relapse is seen soon afterwards. However, only if we can - not perform a wide surgical resection, because of functional disability and/or other co-morbidities, we could consider it as the first option, because Merkel cell carcinoma is a radiosensitive tumour.

## References

- Llombart B, Requena C, Cruz J. Update on Merkel Cell Carcinoma: Epidemiology, Etiopathogenesis, Clinical Features, Diagnosis, and Staging. *Actas Dermosifiliogr*. 2017; 108:108-19. <https://doi.org/10.1016/j.ad.2016.07.022> PMID:27770997
- Saini AT, Miles BA. Merkel cell carcinoma of the head and neck: pathogenesis, current and emerging treatment options. *Onco Targets Ther*. 2015; 8:2157-67. PMID:26316785 PMCid:PMC4548751
- Miles BA, Goldenberg D. Education Committee of the American Head and Neck Society (AHNS). Merkel cell carcinoma: Do you know your guidelines? *Rev Endocr Metab Disord*. 2017; 2017.
- Zur Hausen A. Book of abstracts. 47.VI Congress of dermatovenerologists of Macedonia with international participation. ISBN 978-9989-37-031-1
- Becker JC, Stang A, Hausen AZ, Fischer N, DeCaprio JA, Tothill RW, Lyngaa R, Hansen UK, Ritter C, Nghiem P, Bichakjian CK, Ugurel S, Schrama D. Epidemiology, biology and therapy of Merkel cell carcinoma: conclusions from the EU project IMMOMECC. *Cancer Immunol Immunother*. 2017. PMID:29188306
- Heath M, James N, Lemos B, et al. Clinical characteristics of Merkel cell carcinoma at diagnosis in 195 patients: the AEIOU features. *J Am Acad Dermatol*. 2008; 58:375-381. <https://doi.org/10.1016/j.jaad.2007.11.020> PMID:18280333 PMCid:PMC2335370
- Heath M, Jaimes N, Lemos B, et al. Clinical characteristics of Merkel cell carcinoma at diagnosis in 195 patients: the AEIOU features. *J Am Acad Dermatol*. 2008; 58:375-381. <https://doi.org/10.1016/j.jaad.2007.11.020> PMID:18280333 PMCid:PMC2335370
- Verzi AE, Amin SM, Guitart J, Micali G. Merkel cell carcinoma: a review. *G Ital Dermatol Venereol*. 2015; 150(4):419-28. PMID:26224231
- Banks PD, Sandhu S Gyorki DE, Johnston ML, Rischin D. Recent Insights and Advances in the Management of Merkel Cell Carcinoma. *J Oncol Pract*. 2016; 12(7):637-46. <https://doi.org/10.1200/JOP.2016.013367> PMID:27407160
- Ye-Young Rhee, Soo Hee Kim, Eun Kyung Kim, Se Hoon Kim. Merkel Cell Carcinoma Metastatic to Pleural Fluid: A Case Report. *J Pathol Transl Med*. 2017. <https://doi.org/10.4132/jptm.2017.11.10>
- Wick MR. Primary lesions that may imitate metastatic tumors histologically: A selective review. *Semin Diagn Pathol*. 2017. pii: S0740-2570(17)30137-5.
- Coggsall K, et al. Merkel cell carcinoma: An update and review. Pathogenesis, diagnosis, and staging. *J Am Acad Dermatol*. 2018; 78(3):433-442. <https://doi.org/10.1016/j.jaad.2017.12.001> PMID:29229574
- Wright GP, Holtzman MP. Surgical resection improves median overall survival with marginal improvement in long-term survival when compared with definitive radiotherapy in Merkel cell carcinoma: A propensity score matched analysis of the National Cancer Database. *Am J Surg*. 2017. pii: S0002-9610(17)31072-3.
- Fitzgerald TL, Dennis S, Kachare SD, Vohra NA, Wong JH, Zervos EE. Dramatic increase in the incidence and mortality from Merkel cell carcinoma in the United States. *Am Surg*. 2015; 81:802-806. PMID:26215243
- Papadopoulos I, Patrikidou A, Patsatsi A, Mangoudi D, Thuau H, Vahtsevanos K. Head and neck Merkel cell carcinoma: a retrospective case series and critical literature review with emphasis on treatment and prognosis. *Oral Surg Oral Med Oral Pathol Oral Radiol*. 2017. pii: S2212-4403(17)31105-7.
- Takenaka H, Kishimoto S, Shibaki R, Nagata M, Yasuho H. Merkel cell carcinoma with partial spontaneous regression: an immunohistochemical, ultrastructural, and TUNEL labeling study. *Am J Dermatopathol*. 1997; 19(6): 614-8. <https://doi.org/10.1097/00003372-199712000-00012> PMID:9415621
- Tello et al. Merkel cell carcinoma: An update and review. Current and future therapy. *J Am Acad Dermatol*. 2018; 78(3):445:454.