

# Microperforated Hymen Presenting Spontaneous Pregnancy with Cesarean Delivery and Hymenotomy Surgery: A Case Report

Brikene Elshani<sup>1</sup>, Heroid Arifi<sup>1</sup>, Armond Daci<sup>2\*</sup>

<sup>1</sup>Department of Obstetrics and Gynecology, Faculty of Medicine, University of Prishtina, Prishtina, Kosovo; <sup>2</sup>Department of Pharmacy, Faculty of Medicine, University of Prishtina, Prishtina, Kosovo

## Abstract

**Citation:** Elshani B, Arifi H, Daci A. Microperforated Hymen Presenting Spontaneous Pregnancy with Cesarean Delivery and Hymenotomy Surgery: A Case Report. Open Access Maced J Med Sci. 2018 Mar 15; 6(3):528-530. <https://doi.org/10.3889/oamjms.2018.123>

**Keywords:** Cesarean Delivery; Imperforate Hymen; Hymen Incision Surgery

**\*Correspondence:** Armond Daci, Department of Pharmacy, Faculty of Medicine, University of Prishtina, Prishtina, Kosovo. E-mail: [armond.daci@uni-pr.edu](mailto:armond.daci@uni-pr.edu)

**Received:** 23-Oct-2017; **Revised:** 08-Feb-2018; **Accepted:** 20-Feb-2018; **Online first:** 07-Mar-2018

**Copyright:** © 2018 Brikene Elshani, Heroid Arifi, Armond Daci. This is an open-access article distributed under the terms of the Creative Commons Attribution-NonCommercial 4.0 International License (CC BY-NC 4.0)

**Funding:** This research did not receive any financial support

**Competing Interests:** The authors have declared that no competing interests exist

**BACKGROUND:** Female genital tract anomalies including imperforate hymen affect sexual life and fertility.

**CASE PRESENTATION:** In the present case, we describe a pregnant woman diagnosed with imperforate hymen which never had penetrative vaginal sex. A 27-year-old married patient with 2 months of amenorrhea presented in a clinic without any other complications. Her history of difficult intercourse and prolonged menstrual flow were reported, and subsequent vaginal examination confirmed the diagnosis of imperforate hymen even though she claims to have had pinhole surgery in hymen during puberty. Her urine pregnancy test was positive, and an ultrasound examination revealed 8.3 weeks pregnant. The pregnancy was followed up to 39.5 weeks when she entered in cesarean delivery in urgency. Due to perioperative complications in our study, a concomitant hymenotomy was successfully performed. The patient was discharged with the baby, and vaginal anatomy was restored.

**CONCLUSIONS:** This case study suggests that even though as microperforated hymen surgery in puberty can permit pregnancy and intervention with cesarean section and hymenotomy is a good option to reduce the resulting perioperative complications which indirectly affect the increase of the fertilisation and improvement of later sexual life.

## Introduction

Female genital tract anomalies have an important impact on the sexual activity and fertility. Imperforate hymen is a congenital disorder of hymenal configuration which does not permit normal menstrual flow [1]. Minor surgery can fix an imperforate hymen in puberty age, even though there are reports that virginity sparing (pinhole) surgery is a solution when the hymen is a social problem in unmarried girls, and this can still lead to infertility [2]. In the present case, we describe a pregnant woman diagnosed with imperforate hymen which never had penetrative vaginal sex.

## Case report

A 27 – year - old woman complained of amenorrhea for 2 months. She had been married for 1 year and claims problems with sexual intercourse. Her menstruation periods were turned to be regular after performing virginity sparing surgery in childhood period. After clinical examination, she was conscious, oriented and normotensive. On inspection of the external genitalia, a membranous structure covering the vagina was detected, without visualisation of the cervix and taught right membrane which was associated with imperforate hymen (Figure 1a).

Her urine pregnancy test was positive, and abdominal ultrasound resulted in 8.3 weeks pregnancy (Figure 1b). Based on the clinical outcomes of the patient we did not find it applicable to make an additional surgery of hymenal ring even though the risk of its healing process during pregnancy is reported in the literature as well. The pregnancy was followed up to 39.5 weeks without any previously diagnosed and observed complications. Patient has come into the clinic with pain and uterine contractions and based on the imperforate hymen diagnosis the cesarean delivery was performed under brief general anaesthesia which resulted with successful birth (male; 3700 gram; 53 cm and Apgar score 7/8).

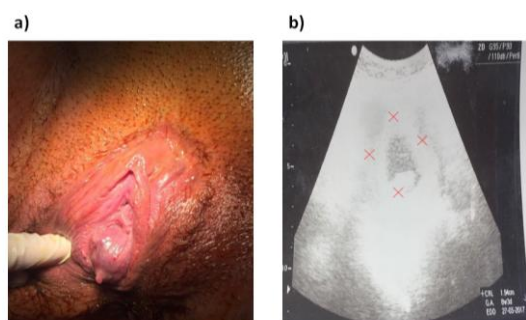


Figure 1: a) Imperforate hymen with a hymenal membrane covering the vagina b) Transabdominal ultrasound showing gestational sac and embryo

However during the following intervention when the morbidly adherent placenta (placenta accreta) was removed, an active bleeding was observed and after unsuccessful attempting in the revision of uterus cavity and placing of two sutures in the front wall of the inner part of the uterus for hemostasis induction, we have proceed further for hemostasis induction with the incision of hymen was done (Figure 2a) in order to make full passability and the uterine cavity tamponade which later resulted with successful hemostasis and operation.

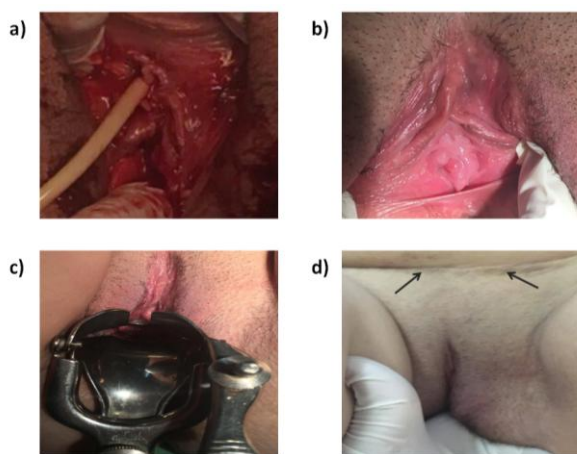


Figure 2: a) Hymenotomy surgery during cesarean delivery; b) Hymen view after surgery; c) Restoration of normal vaginal anatomy posthymenotomy d) Normal penetration and wound healing

The patient was discharged after all the treatment procedures with her baby for outpatient follow - up. At the 4 - week follow up after hymenotomy the vaginal anatomy including also normal penetration was restored (Figure 2b and c), and the cesarean wound was healed effectively (Figure 2d). Later on, the patient reported being well and had normal sexual intercourse.

## Discussion

Imperforate and microperforated hymen tissue occurs during the embryologic development and is congenital anomalies. There are many symptoms which characterise this malformation including primary amenorrhea, pelvic pain, vaginal bleeding, vaginal discharge, dysuria, infertility etc. Usually, the symptoms tend to persist without an early intervention in early childhood [3]. Due to this a simple microsurgery procedure including incision of the hymen is recommended in early childhood to relieve the symptoms [4]. However, there are different cultural and religious importance to keep the intact hymen, which makes surgeon decide to keep the natural intact hymen under those circumstances [5]. Providing intact hymen by making a pinhole opening may permit passage of menstruation blood flow or semen, but still, the difficulty in having sexual intercourse or penis penetration exists, which may lead to infertility, even though consequently spontaneous pregnancy could rarely occur [6] [7]. There are rare minor reports that spontaneous closure of the hymen was done during pregnancy due to the healing process [8]. Also, an incomplete abortion is reported in microperforated hymen which shows that surgical correction is essential for long-term treatment and also sexual and psychological health [9]. In the present case, it has been shown that spontaneous pregnancy may happen without normal sexual intercourse. The closure of hymen in pregnancy was observed. There are no reports regarding the cesarean section associated with complicated bleeding and the necessity for intervention with hymenotomy. This rare case represents a successful cesarean delivery performed in concomitant with hymenotomy surgery.

In conclusion, keeping intact hymen in imperforate hymen extends the problems in sexual intercourse; this may rarely lead to spontaneous pregnancy without fetus complications. Cesarean delivery is the preferred choice in the patients with imperforated hymen patients, even though in our case the active bleeding from morbidly adherent placenta was urgency procedure and the main indicators to proceed further with hymenotomy in order to make the uterine tamponade which indirectly affects the reduction of operative possible complications of

cesarean delivery which indirectly affect the increase of the fertilization and improvement of later sexual

## Acknowledgements

We would like to thank, J.I., F.K and J.K. for assisting and contribution in the operating procedures and D.V. for revising this manuscript.

## References

1. MacDaugall J. Management of imperforate hymen, transverse and other vaginal septa. *Gynecol Obstet Surg Challenges Manag Options*. 2016; 525–7.
2. Temizkan O. Virginity sparing surgery for imperforate hymen: report of two cases and review of literature. *J Turkish-German Gynecol Assoc*. 2012; 13(4):278–80. <https://doi.org/10.5152/jtqga.2012.46> PMID:24592057 PMCid:PMC3881718
3. Domany E, Gilad O, Shwarz M, Vulfsons S, Garty BZ, Letts M, et al. Imperforate hymen presenting as chronic low back pain. *Pediatrics*. 2013; 132(3):e768-70. <https://doi.org/10.1542/peds.2012-1040> PMID:23958769
4. Nazir Z, Rizvi RM, Qureshi RN, Khan ZS, Khan Z. Congenital vaginal obstructions: Varied presentation and outcome. *Pediatr Surg Int*. 2006; 22(9):749–53. <https://doi.org/10.1007/s00383-006-1730-8> PMID:16871398
5. Cetin C, Soysal C, Khatib G, Urunsak IF, Cetin T. Annular hymenotomy for imperforate hymen. *J Obstet Gynaecol Res*. 2016; 42(8):1013–5. <https://doi.org/10.1111/jog.13010> PMID:27094100
6. Güven D. Microperforate (pinhole) hymen and infertility: A rare case report. *Open J Obstet Gynecol*. 2012; 2:287–8. <https://doi.org/10.4236/ojog.2012.23060>
7. KR B. An interesting rare case of spontaneous pregnancy with imperforate hymen and high transverse vaginal septum with bicornuate uterus. *Int J Reprod Contraception, Obstet Gynecol*. 2017; 6(1):341–3. <https://doi.org/10.18203/2320-1770.ijrcog20164692>
8. Onan MA, Turp AB, Taskiran C, Ozogul C, Himmetoglu O. Spontaneous closure of the hymen during pregnancy. *Am J Obstet Gynecol*. 2005; 193(3):889–91. <https://doi.org/10.1016/j.ajog.2005.03.025> PMID:16150298
9. Padhi M, Tripathy P, Sahu A. Microperforate hymen presenting with incomplete abortion: A case report. *J Obstet Gynaecol Res*. 2017; 43(8):1353–5. <https://doi.org/10.1111/jog.13347> PMID:28636237