

# Therapeutic Challenge in a Severely Atrophic Mandible

Edvard Janev<sup>1\*</sup>, Nadica Janeva<sup>2</sup>, Marija Peeva–Petreska<sup>3</sup>, Kristina Mitic<sup>4</sup>

<sup>1</sup>Faculty of Dentistry, Ss Cyril and Methodius University of Skopje, Skopje, Republic of Macedonia; <sup>2</sup>Department of Prosthodontics, Faculty of Dental Medicine, Ss. Cyril and Methodius University of Skopje, Skopje, Republic of Macedonia; <sup>3</sup>Department of Oral Surgery, Faculty of Dental Medicine, Ss. Cyril and Methodius University of Skopje, Skopje, Republic of Macedonia; <sup>4</sup>Department of Periodontology, Faculty of Dental Medicine, Ss. Cyril and Methodius University of Skopje, Skopje, Republic of Macedonia

## Abstract

**Citation:** Janev E, Janeva N, Peeva–Petreska M, Mitic K. Therapeutic Challenge in a Severely Atrophic Mandible. Open Access Maced J Med Sci. 2018 Mar 15; 6(3):564-567. <https://doi.org/10.3889/oamjms.2018.130>

**Keywords:** Mini implants; Edentulous mandible; Total prosthesis; Augmentation

**\*Correspondence:** Edvard Janev, Faculty of Dentistry, Ss Cyril and Methodius University of Skopje, Skopje, Republic of Macedonia. E-mail: edijanev@hotmail.com

**Received:** 06-Dec-2017; **Revised:** 21-Dec-2017; **Accepted:** 08-Feb-2018; **Online first:** 10-Mar-2018

**Copyright:** © 2018 Edvard Janev, Nadica Janeva, Marija Peeva–Petreska, Kristina Mitic. This is an open-access article distributed under the terms of the Creative Commons Attribution-NonCommercial 4.0 International License (CC BY-NC 4.0)

**Funding:** This research did not receive any financial support

**Competing Interests:** The authors have declared that no competing interests exist

**BACKGROUND:** After tooth loss, however, severely atrophic residual alveolar ridges are fairly common, especially in patients who have been edentulous for a long period. Anterior area of the mandible is areas where clinicians have greater anatomical limitations. Reduced alveolar bone height very often represents a contraindication to implant therapy, unless a procedure such as a ridge augmentation is performed.

**CASE REPORT:** This study aims to present two separate cases in highly selected edentulous anterior mandibular sites, where one stage, mini implants were used to support total prostheses. Small diameter implants have been used for retention of complete removable mandibular overdentures. This is an excellent option for those who suffer from the inconvenience and embarrassment of loose lower dentures and are tired of having to use sticky pastes and creams to make their dentures stay in place.

**CONCLUSION:** Small diameter implants, when used multiples may offer adequate support for a removable prosthesis and overcome this problem.

## Introduction

The management of the atrophic mandibular ridge has always been a challenge for the clinicians because of inadequate retention and support that the ridge offers to the complete denture prosthesis. When the complete denture patient is unable to tolerate the prosthesis in spite of all efforts from the clinician, the surgical approaches must be resorted to; these include the vestibuloplasties and the bone grafts [1].

The conventional removable total prosthesis has a frequent motion during the act of eating, chewing, swallowing and even talking. According to some statistic data, 50% of patient report those problems and 40% of them are located in the mandible, due to progressive bone resorption (Figure 1).

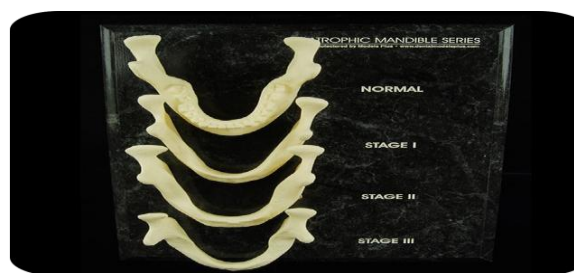


Figure 1: Resorption process in the mandible

The new method of treatment and its purposes include the following parameters: Mini Dental Implants (MDI) anchor the existing upper or lower dentures and provide stability. They are suitable to replace single or multiple missing teeth, and the patient can be prepared for fixed porcelain crowns after eliminating dentures entirely. The final goal is to eliminate the partial metal denture.

MDI is characterized by small diameter- for minimally invasive insertion (2 mm – D1 and D2/over 2.4 mm - D3 and D4); high purity, blasted and etched surface - for safe osseointegration; self - tapping thread - for quick and easy application, and two different connectors (ball top and cone top) - for large range of indications.

### **Mini Dental Implants vs Regular Dental Implants**

MDI has many advantages over regular dental implants. They are much smaller than conventional implants (2 mm as against 4 mm - 5.75 mm for conventional implants), so it takes less drilling of the jaw bones. MDI surgery is minimally invasive. The surgery does not usually need cutting of gums and removal of stitches afterwards. Trauma to the jaw bone, bleeding, chances of injury, post-surgical discomfort are all minimised. Due to their smaller size, mini dental implants can also be used when the site for implantation is too narrow for a regular implant. Quite often, only local sedation of the implant site is needed in the case of MDIs.

The MDI procedure is quick and can be completed in one sitting as opposed to conventional implants which require several visits to the dentist [2] [3].

MDIs cost less than conventional dental implants, but offer advanced prosthesis stability and retention. The easy approach allows improved implant's hygiene. MDIs can improve facial structure restoration, prevent further bone resorption and provide immediate function.

### **Who is a Candidate for Mini Dental Implants?**

Almost anyone with weak gums and in need of dental implants can go for mini dental implants. On the other hand, mini dental implants are not advised in the following situations: Uncontrolled diabetes, history of radiation treatment for cancer (this does not include X - rays for diagnostics), substance abuse, immune - suppression. Patients with the following conditions may suffer complications or failure with MDIs: heavy smoking/drinking habits, Sjorgren's syndrome, Alzheimer's disease, people who clench/grind their teeth, young persons in their growing years.

### **Preoperative Planning**

General anamnesis, systemic disease evaluation, RTG imaging, CT - scan, 3D - implant planning are critical in preoperative planning procedure. Following these protocols, a measurement of the crest between the mental foramen of edentulous mandible should be performed, and attention should be paid to the following parameters: -

processes alveolaris volume, thickness and inclination; - bone density; and - implant marking (6mm space between implants).

MDIs can be successfully used in highly selected sites where there is adequate bone density and bone volume for immediate implant stability [5] [6]. Atrophic residual alveolar crest cannot be an option for standard two-stage implants with diameter from 3.75 – 4.2 mm. A series of mini implants (4 - 6) are placed along the gum line, and they serve as the base of the denture. At least 2 implants may be successfully used to support fixed partial and total dentures in edentulous sites of compromised bone width or length. The small size of mini implants often means that no incision is needed to place the implants. They can usually be inserted right through the gum into the bone. This eliminates the need for a recovery period, and the restoration can usually be placed right away or only a short time after.

### **One Stage Dental Implants**

In the one-stage dental implants surgery, the second stage is altogether avoided, and during a single surgery, the implant is placed in the jaw bone in such a way that the top of the implant is higher than the surface of the bone, at the height of the soft tissue. When the soft tissue is stitched at the end of the surgery, the dental implant's head is exposed. There is, therefore, no need for a second surgery as the implant is already exposed and takes its place naturally [7].

Features of the One Stage Dental Implants are: osseointegration begins immediately; a short period of bone healing before placing the implant; there are no missing teeth in the mouth, and the tooth looks natural while the implant is healing.

## **Case reports**

### **Case report 1**

Fifty-nine years old female patient referred to our clinic with only one periodontally affected teeth remained in the mandible (Figure 2a). Three weeks after teeth extractions (Figure 2b), two cone top one - stage dental implants were inserted intraoperatively, with raising a mucoperiosteal flap (Figure 2c). One week later, implant supported total prosthesis was adapted after cementing Dodler bar attachment construction (Figure 2d and 2e). The retention and stabilisation were satisfying for the patient, resulting in optimal aesthetics and function (Figure 2f).

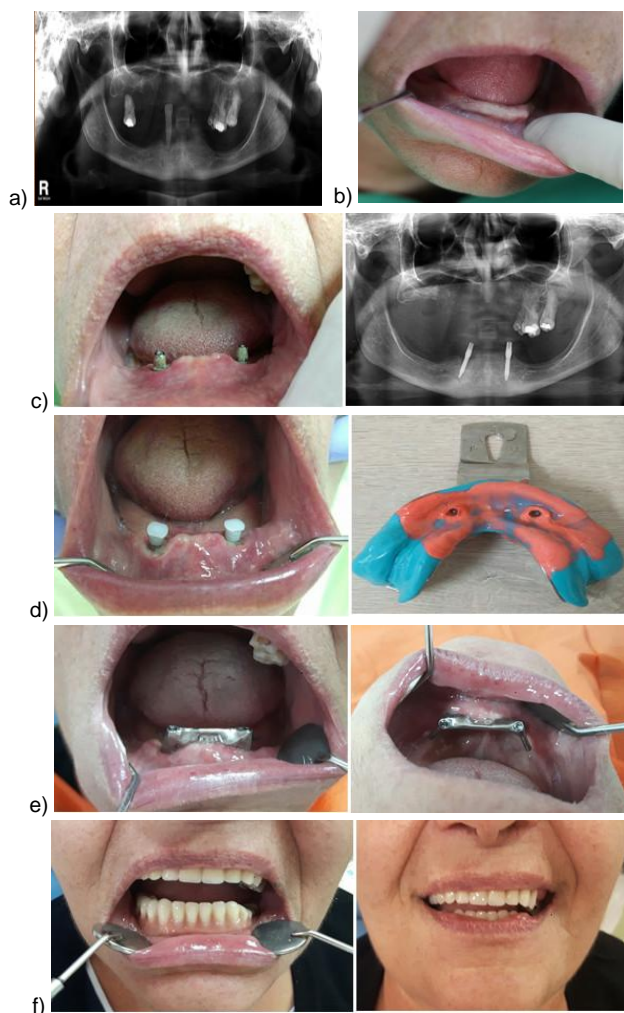


Figure 2: a) RTG view before extraction; b) Clinical situation after healing; c) Inserted two cone top dental implants, clinical and RTG view; d) Positioning the transfers for impression; e) Fixing total prosthesis on Dodler bar construction; f) Final position on the total prosthesis

### Case report 2

Sixty-two years old female patient was unsatisfied with an existed total prosthesis, due to uncontrolled motion and difficult function during the act of eating and even talking. The RTG status of both jaws is presented in Figure 3a. Two MDIs dental implants were placed in the frontal mandible (Figure 3b) and then connected with a bar attachment. A new prosthesis was adapted to a new cemented implant supported construction (Figure 3c). Improved stabilisation and prosthesis retention were achieved after the implant and prosthetic treatment (Figure 3d).

### Discussion

A small diameter implant presents less of an obstacle for angiogenesis, and there are less percutaneous exposure and bone displacement as

compared with standard sized implants [8]. Multiple splinted implants may be necessary to minimise metal fatigue from cyclic loading. Anterior restorations supported by mini implants may need occlusal relief to minimise the effects of cyclic loading [7] [9]. Because MDIs are one - piece fixtures and are immediately loaded, it is important to avoid lateral loads on the fixtures that may lead to failure of the implant to integrate and loss of the fixture. The teeth in the posterior region must be with an oval and narrow shape to minimise the axial and nonaxial forces [10] [11].

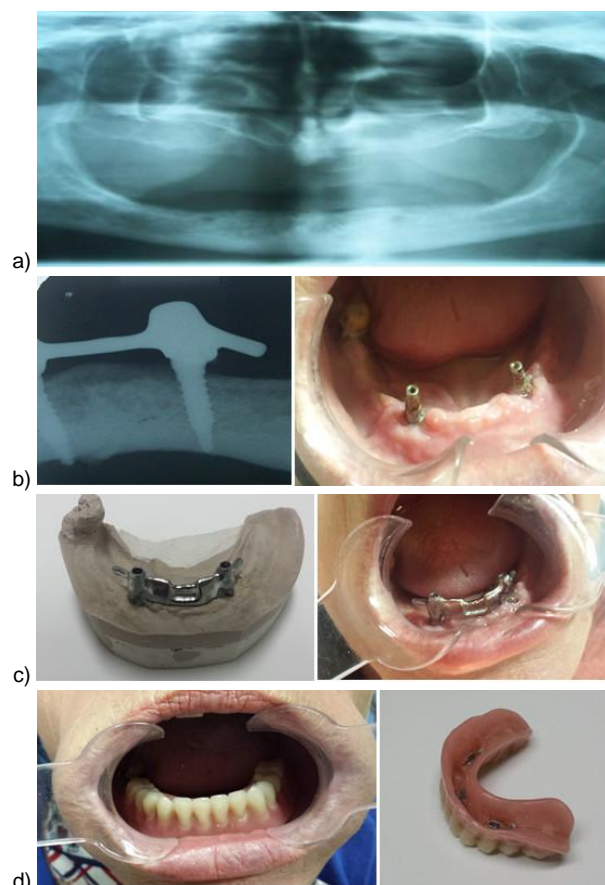


Figure 3: a) Radiological view of the residual alveolar crest in the mandible; b) Inserted two MDIs in the anterior mandible (RTG and clinical image); c) Adapting total prosthesis on implant-supported bar construction; d) Advanced retention and stabilisation of the prosthesis

The resultant stress distribution was evaluated by Flanagan in patients with total prosthesis supported by 2 implant bar-retained [12] [13]. Overlay denture was simulated with 0-, 1-, 2-, and 3-mm bar heights. A vertical force was applied to the left first molar and gradually increased from 0 to 50 N. The amount of stress transferred by 3-mm heights of the bar connection was greater than that of 1- and 2-mm bar connections [14].

In conclusion, this kind of method by using one stage dental implants provides satisfying retention and stabilisation of the removable overdentures, to achieve better comfort and quality during mastication

and other functions. The preferred technique for the practitioners is with transmucosal drilling and implants positioning. The major indications for MDIs usage are due to their affordable dimensions which offer some prosthetic options.

Because an increased number of implants are recommended when mini implants are planned as an anchorage device, a proper stress distribution on dental implants is necessary for the bar - retained implant overlay dentures. Dolder bar attachment with 1- and 2-mm heights could be associated with appropriate stress distribution for the implant-retained prosthesis.

## References

- Esposito M, Grusovin MG, Coulthard P et al. The efficacy of various bone augmentation procedures for dental implants: A Cochrane systematic review of randomized controlled clinical trials. *Int J Oral Maxillofac Implants*. 2006; 21:696–710. PMID:17066630
- Davarpanah M, Martinez H, Tecucianu JF et al. Small-diameter implants: Indications and contraindications. *J Esthet Dent*. 2000; 12:186–194. <https://doi.org/10.1111/j.1708-8240.2000.tb00221.x> PMID:11323862
- Tarnow D, Elian N, Fletcher P et al. Vertical distance from the crest of bone to the height of the interproximal papilla between adjacent implants. *J Periodontol*. 2003; 74:1785–1788. <https://doi.org/10.1902/jop.2003.74.12.1785> PMID:14974820
- Comfort MB, Chu FC, Chai J et al. A 5-year prospective study on small diameter screw-shaped oral implants. *J Oral Rehabil*. 2005; 32:341–345. <https://doi.org/10.1111/j.1365-2842.2004.01441.x> PMID:15842242
- Flanagan D. Implant-supported fixed prosthetic treatment using very small diameter implants: A case report. *J Oral Implantol*. 2006; 32:34–37. <https://doi.org/10.1563/778.1> PMID:16526580
- Mazor Z, Steigmann M, Leshem R et al. Mini-implants to reconstruct missing teeth in severe ridge deficiency and small interdental space: A 5 year case series. *Implant Dent*. 2004; 13:336–341. <https://doi.org/10.1097/01.id.0000148554.83439.00> PMID:15591995
- Fritz U, Diedrich P, Kinzinger G et al. The anchorage quality of mini-implants towards translatory and extrusive forces. *J Orofac Orthop*. 2003;64:293–304. <https://doi.org/10.1007/s00056-003-0304-9> PMID:12937865
- Ahn MR, Choi JH, Sohn DS. Immediate loading with mini dental implants in the fully edentulous mandible. *Implant Dent*. 2004; 13:367–372. <https://doi.org/10.1097/01.id.0000148560.65514.3d> PMID:15591999
- Kanie T, Nagata M, BanS. Comparison of the mechanical properties of 2 prosthetic mini-implants. *Implant Dent*. 2004; 13:251–256. <https://doi.org/10.1097/01.id.0000136912.98138.c3> PMID:15359162
- Romeo E, Lops D, Amorfini L et al. Clinical and radiographic evaluation of small-diameter (3.3-mm) implants followed for 1–7 years: A longitudinal study. *Clin Oral Implants Res*. 2006; 17:139–148. <https://doi.org/10.1111/j.1600-0501.2005.01191.x> PMID:16584409
- Cosme DC, Baldisserotto SM, CanabarroSA et al. Bruxism and voluntary bite force in young dentate adults. *Int J Prosthodont*. 2005; 18:328–332. PMID:16052788
- Vigolo P, Givani A, Majzoub Z et al. Clinical evaluation of small-diameter implants in single-tooth and multiple-implant restorations: A 7-year retrospective study. *Int J Oral Maxillofac Implants*. 2004; 19: 703–709. PMID:15508986
- Vigolo P, Givani A. Clinical evaluation of single-tooth mini-implant restorations: A five-year retrospective study. *J Prosthet Dent*. 2000; 84:50–54. <https://doi.org/10.1067/mpr.2000.107674> PMID:10898842
- Kim Y, Oh TJ, Misch CE et al. Occlusal considerations in implant therapy: Clinical guidelines with biomechanical rationale. *ClinOralImplRes*.2005; 16:26–35. <https://doi.org/10.1111/j.1600-0501.2004.01067.x>