

## Ovarian Strumal Carcinoid Tumour: Case Report

Vesna S. Antovska<sup>1</sup>, Milka Trajanova<sup>1</sup>, Iskra Krstevska<sup>1</sup>, Irena Gosheva<sup>1\*</sup>, Jasmina Chelebieva<sup>1</sup>, Irina Prodanova<sup>2</sup>

<sup>1</sup>Department for Urogynaecology and Pelvic Floor Disorders, University Clinic for Gynecology and Obstetrics, Skopje, Republic of Macedonia; <sup>2</sup>PHI Histolab, Diagnostic Laboratory for Cytology and Histopathology, Skopje, Republic of Macedonia

### Abstract

**Citation:** Antovska VS, Trajanova M, Krstevska I, Gosheva I, Chelebieva J, Prodanova I. Ovarian Strumal Carcinoid Tumour: Case Report. Open Access Maced J Med Sci. <https://doi.org/10.3889/oamjms.2018.138>

**Keywords:** Ovarian teratoma; Strumal carcinoid; Carcinoid syndrome

**\*Correspondence:** Irena Gosheva, Department of Urogynaecology and Pelvic Floor Disorders, University Clinic for Gynecology and Obstetrics, Skopje Republic of Macedonia. E-mail: irena\_karamanolevska@yahoo.com

**Received:** 25-Oct-2017; **Revised:** 01-Nov-2017; **Accepted:** 20-Feb-2018; **Online first:** 12-Mar-2018

**Copyright:** © 2018 Vesna S. Antovska, Milka Trajanova, Iskra Krstevska, Irena Gosheva, Jasmina Chelebieva, Irina Prodanova. This is an open-access article distributed under the terms of the Creative Commons Attribution-NonCommercial 4.0 International License (CC BY-NC 4.0)

**Funding:** This research did not receive any financial support

**Competing Interests:** The authors have declared that no competing interests exist

**BACKGROUND:** Ovarian strumal carcinoid is a germ cell tumour characterised by a mixture of thyroid tissue and carcinoid. Ovarian struma is a very rare occurrence with 0.3-1% incidence of all ovarian tumours and 3% of mature teratomas. Primary carcinoid ovarian tumours are still uncommon as a part of mature teratoma or mucinous cystadenoma. There are four major variants of a carcinoid tumour: insular, trabecular, strumal and mucinous. A strumal carcinoid is an unusual form of ovarian teratoma composed of an intimate admixture of thyroid/carcinoid tissues.

**CASE REPORT:** This is a case report of a 59-year old woman with a 5-year clinical history of perimenopausal uterine bleeding and three explorative curettages. Gynaecological and ultrasound examinations revealed ovarian enlargement with a diameter of 50 mm with hypochoic zones suspected of benign teratoma. The diagnostic test such as Ca-125, AFP, free-T4 and TSH was in normal range. A smooth, solid right ovarian 50 mm-size tumour, as well as small amount of fluid in the Douglas pouch, was found during the total abdominal hysterectomy, bilateral salpingo-oophorectomy and staging biopsy. The histopathology revealed teratoma with strumal carcinoid tumour IA stage according to AJCC 2010 of the right ovary and negative cytopathology of the fluid from the Douglas pouch. On the postoperative 2-year control, the patient was tumour free, and Ca-125, free-T4 and TSH were in normal range.

**CONCLUSION:** We would like to point out those specific diagnostic tools, such as ultrasound and Ca-125 have low specificity and sensitivity in detection of this rare ovarian malignancy.

### Introduction

Ovarian strumal carcinoid belongs to the germ cell family of ovarian malignancy, which is an intimate admixture of normal thyroid tissue and carcinoid. Ovarian struma has a very rare occurrence with 0.3 - 1% incidence of all ovarian tumours and 3% of mature teratomas. Primary carcinoid tumours of the ovary are uncommon, rarer than struma ovarii and account only for 5% of ovarian teratomas. Three - fifths of the strumal carcinoids arise in dermoid cysts or mature, solid teratomas. They are frequently composed of mature cystic teratomas or, less commonly, mucinous cystadenomas. Most patients with strumal carcinoid have no symptoms of carcinoid syndrome like flushing and diarrhoea, but only symptoms of enlarging mass. They can also be just incidental findings. According to histopathology, there is four major variants of

carcinoids: insular, trabecular, strumal and mucinous. Treatment with a simple oophorectomy or salpingo-oophorectomy is effective. Ovarian strumal carcinoid metastasises occasionally, and such a type of neoplasm should be treated as an ovarian tumour with low malignancy potential.

We present a patient with ovarian teratoma and strumal carcinoid tumour.

### Case Report

A 59 - year old postmenopausal woman was referred to our hospital without any symptoms at the regular gynaecological checkup, which revealed an enlarged cystic right adnexal tumour with mixed

echogenicity and increased blood flow. In the perimenopausal period, she had 3 consecutive explorative curettages for excessive bleeding, and the histopathological analysis revealed normal, benign findings. Her menopause occurred at the age of 54, and after that, she never had any vaginal bleeding.

She was admitted to our gynaecological department for accurate diagnosis and adequate treatment. Pelvic examinations revealed an enlarged right ovary whose dimensions were inappropriate for the woman's age, with a diameter of 43 mm with both hypoechoic and hyperechoic zones. There was no amount of fluid in the Douglas pouch. The uterus was in AVFL and had a thin endometrial lining with no other notable features observed. The risk of ovarian malignancy index (ROMI) = 9, i.e. there is a low risk for malignancy: cystic structure with < 1/4 solid parts (1 point) + senium (1 point) + multilocularity (2 points) + opalescent intralocular liquid (2 points) + intralocular papillary vegetation of 3 - 5mm thickness (1 point) + thickness of the capsule of 3 - 5mm (1 point) + clear rugged margin (1 point) [1].

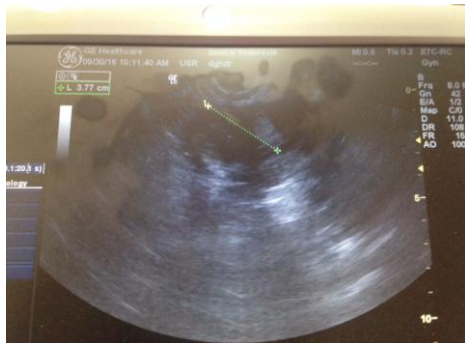

Figure 1: Ultrasound examination which revealed a cystic structure with < 1/4 solid parts, opalescent intralocular liquid, intralocular papillary vegetation of 3 - 5 mm thickness, the thickness of the capsule of 3 - 5 mm and a clear, rugged margin

The results of urinalysis and blood chemistry tests were within normal ranges and Ca125 - 11.4 U/mL. Routine investigations including serum electrolytes and thyroid function test were all within normal limits. Serum tumour markers, such as Ca125, carcinoembryonic antigen and Alpha-fetoprotein (AFP) were within normal limits. According to the clinical and imaging information and postmenopausal status of the patient, the possibility of a cystic ovarian teratoma was considered and, after discussion with the patient and her family, exploratory laparotomy was planned.

The patient underwent surgical treatment, total abdominal hysterectomy with bilateral salpingo-oophorectomy, along with omentectomy, peritoneal washing and peritoneal sampling biopsy. During the procedure, a cystic tumour with a diameter of 5 cm - size arising from the right ovary with the intact capsule, mobile and well circumscribed was visualised. The uterus left ovary, and both tubes were normal. At the same time, a peritoneal washing was

performed for cytological examination. The postoperative period was uneventful, and the patient was discharged on the 7th postoperative day.

According to the pathology report, the tumour of the right ovary measured 6 x 4.5 x 4.5 cm, and it was lobulated, with the smooth outer surface. The cut surface revealed a cystic formation filled with sebaceous material and a tuft of hair. In the wall of the cyst, there was solid, homogenous, tan - brown to yellow, circumscribed nodule measured 3.5 cm.

Microscopic examination revealed a cyst lined by stratified squamous epithelium with skin appendages, together with mature neuronal elements and fat tissue (Figure 2A). The solid nodule was composed partly of thyroid tissue with thyroid follicles filled with colloid and partly of tumour cell clusters composed of monomorphic cells with abundant granular cytoplasm. The nuclear chromatin was finely granular and "salt and pepper" in appearance. The tumour cells were arranged in trabecular structures, or in solid nests and small acini (Figure 2B, and 3).

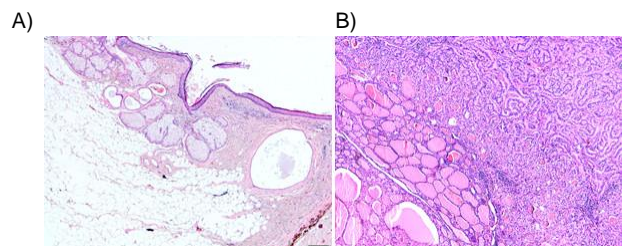


Figure 2: A - Mature cystic teratoma: stratified squamous epithelium with skin appendages, mature neuronal elements and fat tissue, H&E x10; B - Hematoxylin-eosin staining of the strumal carcinoid tumour; Thyroid tissue (bottom left) and carcinoid tumour (upper right), H&E x10

Immunohistochemically, tumour cells were diffusely positive for synaptophysin, neuron-specific enolase (NSE) and CD56 and focally positive for chromogranin A. Mitotic activity of tumour cells was 3 mitoses/10HPF and proliferative index measured with Ki - 67 was 10% (Figure 4).

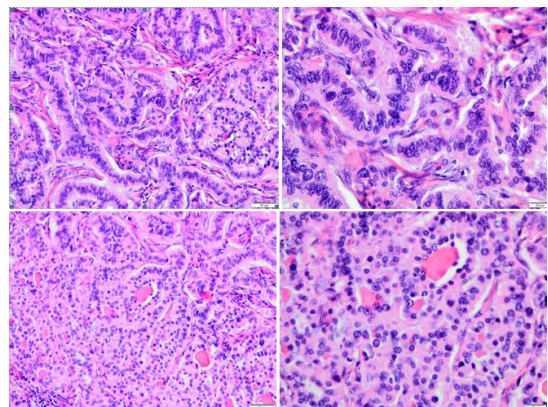


Figure 3: Trabecular carcinoid tumour composed of solid parts and showing a trabecular growth pattern (H&E x 20) (left up). Carcinoid cells with oblong nuclei and columnar cytoplasm presented with long, wavy, parallel ribbon-like arrangement (H&E x 40) (right up). Insular carcinoid tumour composed of solid nests and small acini (H&E x 20) (left down); H&E x 40 (right down)

This part of the tumor was diagnosed as trabecular and insular carcinoid. Because of the presence of mature cystic teratoma and thyroid components, the definitive diagnosis was mature cystic teratoma with strumal carcinoid. Cytological examination of the fluid from the Douglas pouch was negative for tumour cells.

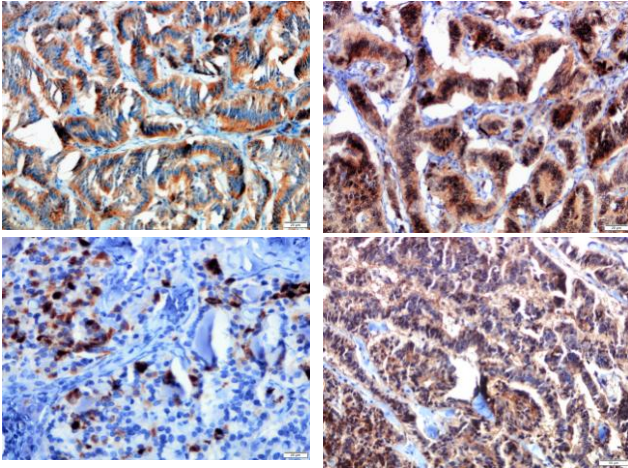


Figure 4: Immunohistochemically tumor cells were positive for: synaptophysin, x40 (left up); NSE, x 40 right up); chromogranin A, x 40 (left down); CD56, x 20 (right down). Figure 4. Immunohistochemically tumor cells were positive for: synaptophysin, x 40 (left up); NSE, x 40 right up); chromogranin A, x 40 (left down); CD56, x 20 (right down)

According to UICC and AJCC 7<sup>th</sup> edition from 2010, the disease was in IA stage. Given her pathological findings, she was referred to an oncologist for consultation but will have a good prognosis, and she is scheduled to be followed up by physical examinations, tumour markers ultrasounds, and CT scans.

## Discussion

Adnexal masses are the most common gynaecological findings. Ovarian tumours, as a part of adnexal tumour masses, represent two - thirds of these cases. Histopathological diagnosis after adequate surgical treatment is the golden standard for a final diagnosis of an adnexal mass. The primary ovarian carcinoid tumours are rare and represent less than 0.1% of ovarian malignancies [2].

According to the WHO classification, they represent a group of ovarian monodermal teratomas [3]. Monodermal teratoma is a benign teratoma composed either solely or predominantly of only one highly specialised tissue type. Those composed predominantly of thyroid tissue are termed struma ovarii [4]. Most tumours present in peri - or postmenopausal women with symptoms of enlarging mass or are just incidental findings [5]. They most

commonly appear as a unilateral mass, but in one - fifth of the cases a contralateral tumour can also be found. More than a half of ovarian carcinoids are found as a part of mature cystic teratoma. Regarding the clinical signs and symptoms, some patients present with typical signs and symptoms of the carcinoid syndrome such as episodic cutaneous flushing, abdominal cramps, diarrhoea, carcinoid heart disease, etc. mediated by bioactive substances that carcinoid tumour cells produce [2]. Carcinoid tumours secrete a wide variety of neurohumoral substances such as serotonin, histamine, tachykinin, bradykinin, kallikrein, corticotrophin, substance P, motilin, and prostaglandins [6]. The above - mentioned complications are almost solely due to the secretion of serotonin. In our case, the patient had no symptoms of carcinoid syndrome, nor symptoms due to the enlarging mass.

Primary ovarian carcinoids are histologically divided into four major types: insular, trabecular, strumal and mucinous. A mixed type has also been reported, which is composed of any combination of the pure types. Primary ovarian carcinoids also arise in association with mature cystic teratomas or mucinous tumours and present various findings on preoperative images. Therefore, the preoperative diagnosis of these tumours may be difficult [7]. Islands of uniform neoplastic cells are typical for insular carcinoids. About 30% of these tumours are associated with the carcinoid syndrome. Trabecular carcinoids are characterised by the growth of tumour cells in trabeculae and only rarely present with endocrine manifestations [2]. Mucinous carcinoid tumours of the ovary are pure tumours, and rarely represent part of the strumal carcinoid. It is considered that primary mucinous carcinoid tumour of the ovary represents a specific histopathologic entity. Unlike other types of primary ovarian carcinoid tumours, it behaves like an aggressive malignant neoplasm [8]. Nevertheless, multiple metastases with a higher mitotic rate and focal necrosis have been reported. The presence of mitoses or necrosis in a tumour is useful for predicting poor prognosis.

Differential diagnoses of primary ovarian carcinoid include metastatic carcinoid, granulosa cell tumours, poorly differentiated primary or metastatic adenocarcinoma, Brenner tumours and androblastoma [2] [13]. Approximately 5% of primary carcinoid tumours of the non-mucinous type have a malignant clinical course, but so far there are no histological parameters that can predict malignancy [2] [9]. Insular carcinoids are among the tumours with low malignant potential. Cases of strumal carcinoid metastases which consist of both the carcinoid and thyroidal type are rarely reported [9]. Mucinous carcinoids tend to be more aggressive in the clinical course.

Premenopausal women with tumours confined to the ovary may be treated with fertility-sparing surgery, as tumors are usually unilateral and

carry a good prognosis, but careful staging to exclude occult metastases is important. However, in the absence of controlled trials to validate this approach, hysterectomy with bilateral salpingo - oophorectomy and surgical debulking of extra-ovarian spread and/or metastases is the treatment of choice [10] [11]. In rare patients with a mucinous variant of the ovarian carcinoid, omentectomy and para - aortic lymph node dissection may also be needed because these tumors spread mainly through lymphatics [10] [12].

However, because of the difficulty of setting an accurate preoperative diagnosis, most cases have been diagnosed based on postoperative pathology findings.

With this case report the correlation between the preoperative clinical assessment and intraoperative assessment and the histopathological diagnosis can be made.

We would like to point out that specific diagnostic tools, as well as serological tests for ovarian malignancy, have low specificity and sensitivity in detection of this rare ovarian malignancy with no clinical symptoms.

## References

1. Antovska V, Trajanova M. An original risk of ovarian malignancy index and its predictive value in evaluating the nature of ovarian tumour. *SAJGO* 2015; 7(2): 52-59. <https://doi.org/10.1080/20742835.2015.1081486>
2. Leniček T, Tomas D, Soljačić-Vraneš H, Kraljević Z, Klarić P, Kos M, et al. Strumal carcinoid of the ovary : report of two cases. *Acta Clin Croat.* 2012; 51:649-653. PMID:23540174
3. Tavassoli A, Devilee P, editors. World Health Organization classification of tumours of the breast and female genital organs. Lyon: IARC Press, 2003: 171. PMID:PMC3957561
4. Hoffman B, Schorge J, Schaffer J, Halvorson L, Bradshaw K, Cunningham G editors. *Williams Gynecology* 2nd edition. New York: McGraw-Hill, 2012:267.
5. Salhi H, Laamouri B, Boujelbène N, Hassouna JB, Dhiab T, Hechiche M, Rahal K. Primary ovarian carcinoid tumor: a report of 4 cases. *Int Surg J.* 2017; 4(8) :2826-2828. <https://doi.org/10.18203/2349-2902.isj20173428>
6. Sharma R, Biswas B, Puri Wahal S, Sharma N, Kaushal N. Primary ovarian carcinoid in mature cystic teratoma: A rare entity. *Clinical Cancer Investigation Journal.* 2014; 3:80-82. <https://doi.org/10.4103/2278-0513.125803>
7. Yamaguchi M, Tashiro H, Motohara K, Ohba T, Katabuchi H. Primary strumal carcinoid tumor of the ovary: A pregnant patient exhibiting severe constipation and CEA elevation. *Gynecol Oncol Case Rep.* 2013; 4: 9–12. <https://doi.org/10.1016/j.gynor.2012.11.003> PMID:24371662 PMID:PMC3862299
8. Alenghat E, Okagaki T, Talerman A. Primary mucinous carcinoid tumor of the ovary. *Cancer.* 1986; 58: 777–783. [https://doi.org/10.1002/1097-0142\(19860801\)58:3<777::AID-CNCR2820580327>3.0.CO;2-I](https://doi.org/10.1002/1097-0142(19860801)58:3<777::AID-CNCR2820580327>3.0.CO;2-I)
9. Robboy SJ. *Pathology of the female reproductive tract.* 2nd ed. USA: Churchill Livingstone, 2009. Petousis S, Kalogiannidis I, Margioulas-Siarkou C, Traianos A, Miliaras D, Kamparoudis A, Mamopoulos A, Rousso D. Mature ovarian teratoma with carcinoid tumor in a 28-year-old patient. *Case reports in obstetrics and gynecology.* 2013; 2013.
10. Metwally H, Elalfy A, Islam A, Reham E, Abdelghani M . Primary ovarian carcinoid: A report of two cases and a decade registry. *Journal of the Egyptian National Cancer Institute.* 2016; 28(4):267-275. <https://doi.org/10.1016/j.jnci.2016.06.003> PMID:27402167
11. Reed NS, Gomez Garcia E, Gallardo Rincon D, Barrette B, Baumann K, Friedlander M, et al. Gynecologic Cancer Inter Group (GIG) consensus review for carcinoid tumors of the ovary. *Int J Gynecol Cancer.* 2014; 24(9 Suppl. 3):35-41. <https://doi.org/10.1097/IGC.000000000000265> PMID:25341578
12. Sharma A, Bhardwaj M, Ahuja A. Rare case of primary trabecular carcinoid tumor of the ovary with unusual presentation. *Taiwanese Journal of Obstetrics & Gynecology.* 2016; 55:748-750. <https://doi.org/10.1016/j.tjog.2015.05.008> PMID:27751431