

# The Outcome of Using a Jamshidi Biopsy Trocar Needle in a Novel Technique for Bone Grafting in Percutaneous Internal Fixation of Scaphoid Non-Union

Syed Bokhari\*, Saifullah Hadi, Fahad Hossain, Bernd Ketzer

*Pinderfields Hospital, Aberford Road, Wakefield, West Yorkshire, United Kingdom*

## Abstract

**Citation:** Bokhari S, Hadi S, Hossain F, Ketzer B. The Outcome of Using a Jamshidi Biopsy Trocar Needle in a Novel Technique for Bone Grafting in Percutaneous Internal Fixation of Scaphoid Non-Union. Open Access Maced J Med Sci. <https://doi.org/10.3889/oamjms.2018.139>

**Keywords:** Scaphoid bone; Bone transplantation; Radius; Fracture fixation internal

**\*Correspondence:** Syed Bokhari, Pinderfields Hospital, Aberford Road, Wakefield, West Yorkshire, United Kingdom. E-mail: [bokhariawais@hotmail.com](mailto:bokhariawais@hotmail.com)

**Received:** 28-Oct-2017; **Revised:** 20-Feb-2018; **Accepted:** 28-Feb-2018; **Online first:** 12-Mar-2018

**Copyright:** © 2018 Syed Bokhari, Saifullah Hadi, Fahad Hossain, Bernd Ketzer. This is an open-access article distributed under the terms of the Creative Commons Attribution-NonCommercial 4.0 International License (CC BY-NC 4.0)

**Funding:** This research did not receive any financial support

**Competing Interests:** The authors have declared that no competing interests exist

**INTRODUCTION:** We report the outcome of using a novel technique of minimally invasive internal fixation and distal radius bone grafting using the Jamshidi Trepine needle and biopsy/graft capture device.

**METHODS:** The technique utilises a 8 mm incision at the distal pole of the scaphoid. The non-union is excavated using the standard Acutrak drill. An 8 gauge Jamshidi trephine needle is used to harvest bone graft from the distal radius which is impacted into the scaphoid and fixed with an Acutrak screw. Fifteen patients were available for retrospective review, 14 male, age mean 29.5 (15-56). Average time from injury to surgery was 167 days (45-72). Fractures classified according to Herbert giving 7 D1 and 8 D2 fractures, 14 waist and 1 proximal pole fractures, all of which had no humpback deformity.

**RESULTS:** Sixty-six percentages of the fractures went onto unite, 4/7 D1 and 6/8 D2 united ( $p > 0.05$ ). Seventy-five percentages of fracture that had surgery in less than 3 months from time of injury went onto unite, whereas only 63% united in patients who had surgery later than 3 months ( $p > 0.05$ ). DASH outcome for all patients improved from 86 down to 32 ( $p < 0.05$ ). With those that united going down from 90 to 6. Those that did not unite went from 81 to 61.

**CONCLUSION:** The Jamshidi bone grafting technique shows comparable results (union rate 66%) to other techniques published in the literature (27-100%) providing the surgeon with an alternative and less demanding procedure than open scaphoid non-union surgery.

## Introduction

The management of scaphoid non - union, continues to be a wide scale problem due to the varying union rates achieved with vascularised and non - vascularised bone grafting. Due to the non-reproducible results outside of specialist centres, vascularised bone graft still has not fully been embraced.

We analysed our results of a novel technique of non - vascularised bone grafting using a Jamshidi biopsy trocar needle in non - unions that had not fallen into a humpback malunion.

## Methods

Between 2009 and 2014, 50 patients with scaphoid fractures who underwent an operative procedure at a busy District General Hospital were identified by computer data capture software (Bluespier, Droitwich, UK). Forty-five patients with an acute fracture, humpback malunion deformity, avascular necrosis, proximal pole fracture or incorrect coding were excluded. This left 15 cases that underwent percutaneous bone grafting and Acutrak screw fixation for our study. There were no formalised inclusion criteria, but we found that after a minimum period of immobilisation of 6 weeks and no definite signs of bony union an informed discussion were undertaken with the patient regarding the risks and

benefits of performing surgery. Most patients who consented to surgery were young, self - employed males. Four shot - scaphoid radiographs were taken preoperatively and then classified according to the Filan and Herbert classification into either D1 - fibrous union or D2 - pseudoarthrosis.

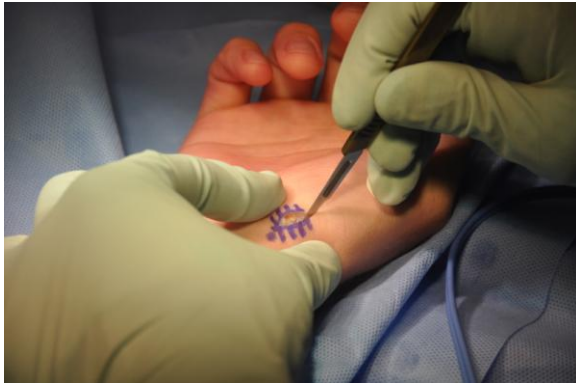

Figure 1: Eight mm incision at distal pole of scaphoid

Initial treatment involved a below elbow plaster or splint immobilisation of at least 6 weeks. Patients who failed to show progression towards union after an initial period of non - operative treatment were then considered for a further conservative measure or operative treatment. In conjunction with patient consultation, a decision was then made to proceed with operative intervention with our described technique. Patients were followed up using clinical and radiological examination either with radiographs or 3 - dimensional reconstruction such as CT or MRI. After surgery, the patient was immobilised in plaster for 6 weeks. At 6 weeks they were followed up with scaphoid series radiographs and clinical examinations while being allowed to mobilise.

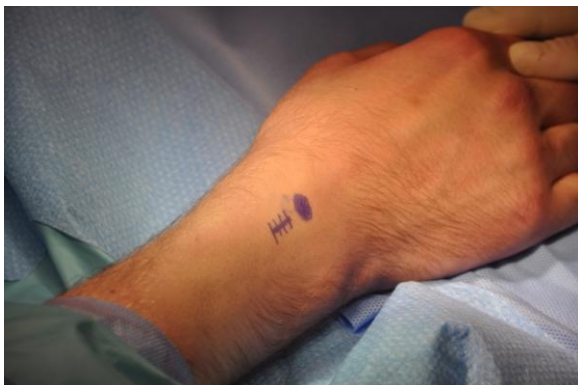

Figure 2: Eight mm incision over listers tubercle

Union was confirmed with clinical and radiological examinations, and patients were asked to complete the Disabilities of Arm, Shoulder and Hand (DASH) questionnaire. Outcomes used for analysis were union rate, time from injury to surgery, the effect of Herbert classification and its effect on union and DASH scores. We defined early surgery from the time

of injury as surgery performed within 120 days of the injury, and hence late surgery after 120 days.

Outcomes were assessed as time to radiological union, or salvage procedure of excision distal pole and using preoperative and postoperative DASH score.

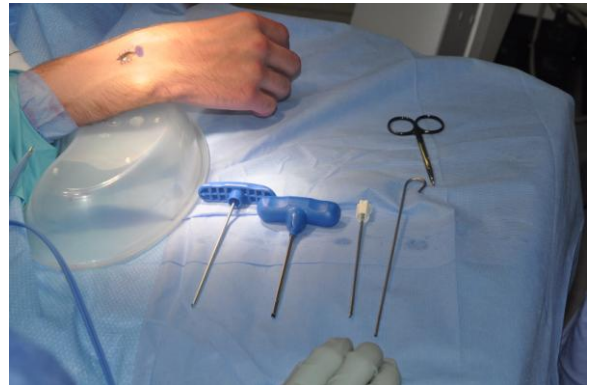

Figure 3: Jamshidi needle and tracer set

We used XLSTAT (Addinsoft, USA) for all statistical tests. Non-parametric tests were used for our results. The chi-squared test was used for categorical variables, and the Wilcoxon Rank test was used for continuous variables.

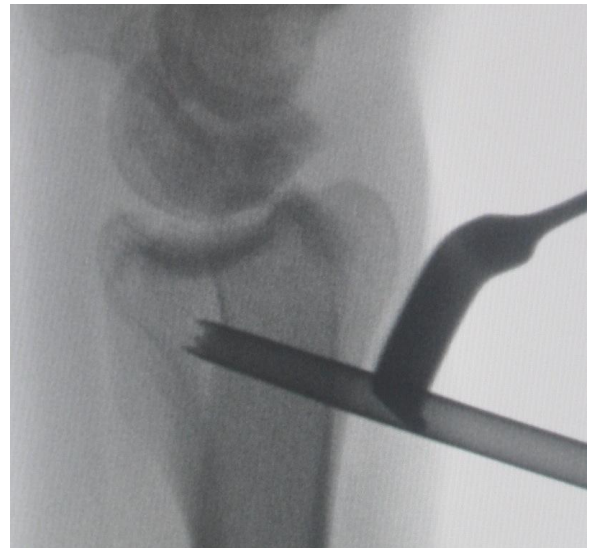

Figure 4: Harvesting of distal radius bone graft under fluoroscopic guidance

The procedure is carried out on a radiolucent arm table with upper arm tourniquet control. Two small incisions are utilised. Fluoroscopy is used to identify the distal pole of the scaphoid and an 8 mm volar incision is made in the line of the scaphoid at the distal pole (Figure 1).

Dissection is continued down to the distal pole and wire is drilled down the scaphoid so that it is located in central position on the AP, Lateral and oblique views. The screw length is measured, and

then the scaphoid is drilled using the 'Standard' Acutrak drill bit. The authors prefer to carry out all drilling on hand power which allows for much more controlled scaphoid excavation. A dorsal incision of 5mm based just proximal to Lister's tubercle is made, and a bare area of bone is identified (Figure 2).

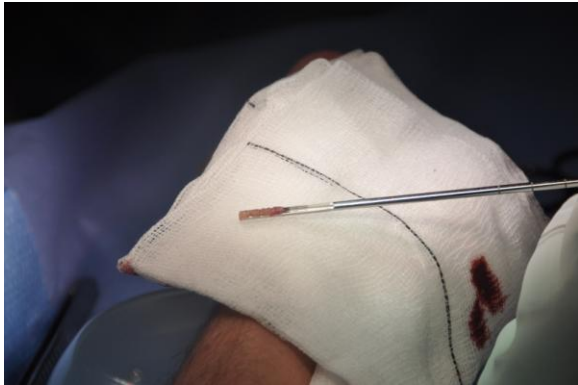

Figure 5: Distal radius bone graft harvest

An 8 Gauge Jamshidi trocar and biopsy needle (Figure 3) is then inserted into the distal radial metaphysis (Figure 4) in a corkscrew motion to capture a column of cancellous tube-shaped autograft (Figure 5).

The capture device fits exactly into the drill hole made by the standard Acutrak drill bit (Figure 6).

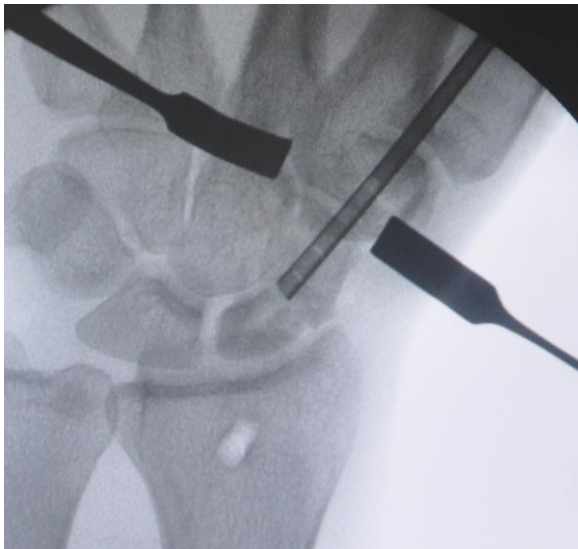


Figure 6: Insertion of tracer into scaphoid Insertion of tracer into scaphoid

The hook-shaped biopsy extractor is then used to expel and impact the cancellous autograft into the scaphoid non-union (Figure 7).

Multiple grafts can be extracted and impacted into scaphoid until it becomes difficult to insert anymore. The guide wire is then re-drilled under fluoroscopy control into the centre-centre position. The screw length does not have to be re-measured as

there is no change in the shape of the scaphoid with the introduction of the graft.

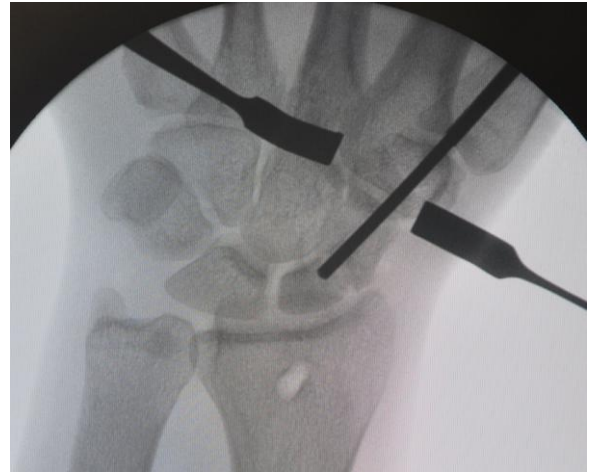

Figure 7: Graft packed into scaphoid using pusher

The drill bit is then passed over the guide wire but in reverse to impact the graft swarf into the scaphoid bone and also make room for the screw. The screw is then inserted, and radiographs were taken to ensure correct positioning (Figure 8).

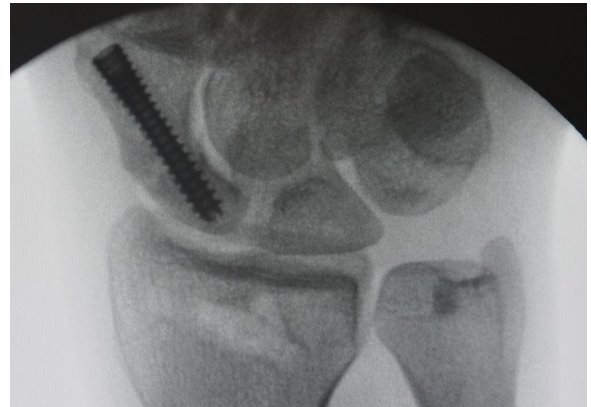


Figure 8: Acutrak screw to compress scaphoid

## Results

In the 14 men and 1 woman, the average time from injury to the time of surgery was 167 days (Range 45 - 472). Mean age of 29.5 years (range 15 - 56). All patients were studying, in employment or actively seeking employment. Two wrist surgeons reviewed the pre-operative radiographs, and any discordance agreed upon after discussion. This classification review resulted in seven D1 (fibrous union) and eight D2 (pseudoarthroses) fractures. Fourteen fractures were of the scaphoid waist and only one proximal pole.

The average time to union was 70.9 days (range 41 - 293). One patient was an outlier at 293

days, and if this patient is excluded, then the average reduces to 46.2 days (range 41 - 58 days).

Ten out of 15 patients went onto unite of which 4 of these were D1 fibrous unions, and 6 were D2 pseudoarthroses. Hence 4 out of 7 D1 fractures united and 6 out of 8 D2 fractures united. Despite D2 having a higher union rate, there is no significant difference between the 2 Herbert groups ( $p > 0.05$ ).

Of the 5 that did not unite the average time from injury to surgery was 138 days (range 55 - 208). This is compared to 180 days for the ten that united (range 45 - 472). The patient with the proximal pole fracture did not unite but was pain-free, with good function.

Comparing the two groups of those having to wait less than 120 days compared to more than 120 days gave a 75% vs 63% union rate, this resulted in no statistical difference between the 2 groups when examining time from injury to surgery and its effect on bony union ( $p > 0.05$ ).

DASH outcomes improved from a mean preoperative score of 86 (68-94) to 32 (0-100) for all patients which were statistically significant ( $p < 0.05$ ). Those patients that united improved from 90 down to 6 whereas those that did not unite went from 81 to 61. The magnitude of improvement following surgery between those that did and those that did not unite was statistically significant ( $p = 0.02$ ).

There is no difference in DASH scores in those who had surgery before 120 days verses those after 120 days ( $P = 0.686$ ).

**Table 1: Outcomes of Surgery**

| Patient | Age | Herbert classfn | Proximal pole or Waist | Outcome    | Time to union | Time from injury to surgery | Pre-op DASH | Post op DASH |
|---------|-----|-----------------|------------------------|------------|---------------|-----------------------------|-------------|--------------|
| JB      | 15  | D2              | Waist                  | United     | 44            | 274                         | 84          | 0            |
| SW      | 22  | D1              | Waist                  | United     | 48            | 472                         | 87          | 18           |
| DS      | 19  | D1              | Waist                  | United     | 293           | 182                         | 93          | 15           |
| CD      | 49  | D2              | Waist                  | United     | 51            | 76                          | 91          | 0            |
| CJ      | 30  | D2              | Waist                  | United     | 41            | 236                         | 88          | 0            |
| LM      | 21  | D2              | Waist                  | United     | 41            | 93                          | 86          | 18           |
| MW      | 20  | D2              | Waist                  | United     | 58            | 157                         | 93          | 0            |
| PW      | 40  | D1              | Waist                  | United     | 42            | 45                          | 94          | 0            |
| DT      | 32  | D2              | Waist                  | United     | 49            | 86                          | 89          | 6            |
| DS      | 34  | D1              | Waist                  | United     | 42            | 187                         | 88          | 0            |
| AF      | 26  | D2              | Waist                  | Non-united | N/a           | 175                         | 88          | 84           |
| PR      | 23  | D1              | Waist                  | Non-united | N/a           | 128                         | 68          | 27           |
| GD      | 24  | D2              | Waist                  | Non-united | N/a           | 208                         | 91          | 76           |
| SS      | 25  | D1              | Waist                  | Non-united | N/a           | 55                          | 94          | 94           |
| PA      | 34  | D1              | Proximal Pole          | Non-united | N/a           | 124                         | 68          | 21           |

## Discussion

The management of scaphoid non-union continues to be a problem for surgeons who deal with scaphoid fractures. The goals of treatment for scaphoid non-union include union, correction of deformity, and relief of symptoms and limitation of arthrosis [7]. Factors that adversely affect the

outcome of scaphoid non - union included the duration of non - union, no punctate bleeding of the proximal pole at the time of surgery and failed previous surgery [11]. Our study involved percutaneous surgery hence we could not identify whether there was punctate bleeding from the proximal pole and none of the patients had undergone previous surgery.

Minimally invasive surgery is indicated in early scaphoid without cystic bone resorption, without appreciable collapse of the scaphoid architecture and avascular necrosis of the proximal pole [2].

Non-vascularised bone graft has varying success in the literature with union rates of 66% iliac crest vs 67% distal radius with donor site pain in the iliac crest group [11]. In a different study of 5246 cases of non-union, the group which was fixed with non-vascularised bone graft showed a union rate of 84%(6). Other groups have found 100% union rates with iliac crest bone graft [1]. Our study shows a rate of 66% which is comparative with the results from Tambe's group [11] but inferior to the other groups.

Comparing bone grafting techniques versus non-bone grafting techniques the authors are aware that there is literature supporting percutaneous fixation without grafting. Union rates are similar to ours published. However, we feel that in our experience the minimal extra surgical time provides a bone graft which speeds up a time to union. Union rates have been reported in non-bone grafting papers as averaging thirteen [5], fourteen [8] and nineteen [9] weeks. In our study the average was ten weeks and when the one outlier is excluded this reduced to six weeks. Hence we feel the advantage of our technique is the speed at which the bone unites compared to non-bone grafting techniques. This is especially important in the population that is being treated, those of young, fit, active males in current employment looking to get back to work as soon as possible.

Vascularised bone grafting techniques seem to achieve superior rates of the union in specialist centres however when these are attempted elsewhere lower rates of the union are attained. Union rates vary from 27% to 100% [9] [10] [12]. Pedicles are usually harvested from the distal radius. However, more advanced techniques such as medial femoral condyle vascularised graft are producing [4] high rates of the union. Taking these superior results from specialist centres into account the jury is still out on whether there is truly an advantage for vascularised against non-vascularised bone graft. In a rare randomised control trial comparing vascularised to non-vascularised grafts, there was no difference between the two groups in union rates, time to union and functional results [1].

We feel that this is a technique which is not technically demanding, reproducible in any centre and has minimal if any donor site morbidity. We are aware that the general outline of the technique has previously been described, but we feel the novelty lies

in 1) the use of a Jamshidi needle, 2) the perfect fit of the Jamshidi harvesting tool into the drill hole created by the Acutrak drill and 3) the ability to use the graft extractor to impact the graft into the non - union site.

We acknowledge limitations in our study being the absence of dynamometry and grip strength testing and also that it is an underpowered study as exhibited by lack of any statistical differences. Interestingly with our technique, there was no significant difference between union rate of surgery before versus those after 120 days, but this is limited by the small numbers of patients in the study.

Our practice has changed after analysing our results, and we are ensuring that patients who are showing any progression towards a delayed union receive early operative intervention and we are only using this technique on waist fractures. If patients present with a marked delay we are now considering iliac crest bone grafting due to the shown increase in union rates in Braga-Silva's group [1].

Our union rate is 66% overall which is comparable to rates across the literature and also results in satisfactory subjective patient outcomes as measured by DASH scores.

## References

- Braga-Silva J, Peruchi FM, Moschen GM, Gehlen D, Padoin AV. A comparison of the use of distal radius vascularised bone graft and non-vascularised iliac crest bone graft in the treatment of non-union of scaphoid fractures. *J Hand Surg Eur.* 2008; 33: 636-40. <https://doi.org/10.1177/1753193408090400> PMID:18977834
- Capo JT, Orillaza NS, Jr., Slade JF, 3rd. Percutaneous management of scaphoid nonunions. *Tech Hand Up Extrem Surg.* 2009; 13 :23-9. <https://doi.org/10.1097/BTH.0b013e3181877644> PMID:19276923
- Inaparthi PK, Nicholl JE. Treatment of delayed/nonunion of scaphoid waist with Synthes cannulated scaphoid screw and bone graft. *Hand.* 2008; 3: 292-6. <https://doi.org/10.1007/s11552-008-9112-4> PMID:18780015 PMID:PMC2584213
- Jones DB, Jr., Moran SL, Bishop AT, Shin AY. Free-vascularized medial femoral condyle bone transfer in the treatment of scaphoid nonunions. *Plast Reconstr Surg.* 2010; 125:1176-84. <https://doi.org/10.1097/PRS.0b013e3181d1808c> PMID:20335867
- Kim JK, Kim JO, Lee SY. Volar percutaneous screw fixation for scaphoid waist delayed union. *Clin Orthop Relat Res.* 2010; 468: 1066-71. <https://doi.org/10.1007/s11999-009-1032-2> PMID:19669847 PMID:PMC2835609
- Munk B, Larsen CF. Bone grafting the scaphoid nonunion: a systematic review of 147 publications including 5,246 cases of scaphoid nonunion. *Acta Orthop Scand.* 2004; 75: 618-29. <https://doi.org/10.1080/00016470410001529> PMID:15513497
- Pao VS, Chang J. Scaphoid nonunion: diagnosis and treatment. *Plast Reconstr Surg.* 2003; 112:1666-76. <https://doi.org/10.1097/01.PRS.0000086090.43085.66> PMID:14578801
- Slade JF, 3rd, Geissler WB, Gutow AP, Merrell GA. Percutaneous internal fixation of selected scaphoid nonunions with an arthroscopically assisted dorsal approach. *J Bone Joint Surg Am.* 2003; 85-A:20-32. <https://doi.org/10.2106/00004623-200300004-00003>
- Steinmann SP, Bishop AT, Berger RA. Use of the 1, 2 intercompartmental supraretinacular artery as a vascularized pedicle bone graft for difficult scaphoid nonunion. *J Hand Surg Br.* 2002; 27:391-401. <https://doi.org/10.1053/jhsu.2002.32077>
- Straw RG, Davis TR, Dias JJ. Scaphoid nonunion: treatment with a pedicled vascularized bone graft based on the 1,2 intercompartmental supraretinacular branch of the radial artery. *J Hand Surg Br.* 2002; 27:413. <https://doi.org/10.1054/jhsb.2002.0808> PMID:12367537
- Tambe AD, Cutler L, Murali SR, Trail IA, Stanley JK. In scaphoid non-union, does the source of graft affect outcome? Iliac crest versus distal end of radius bone graft. *J Hand Surg Br.* 2006; 31:47-51. <https://doi.org/10.1016/J.JHSB.2005.07.008> PMID:16140440
- Zaidenberg C, Siebert JW, Angrigiani C. A new vascularized bone graft for scaphoid nonunion. *J Hand Surg Br.* 1991; 16:474-8. [https://doi.org/10.1016/0363-5023\(91\)90017-6](https://doi.org/10.1016/0363-5023(91)90017-6)