

Comparative Analysis of the Applicability of Island Flap in Primary and Recurrent Basal Cell Carcinomas of Similar Localization

Georgi Tchernev^{1,2*}, Ivanka Temelkova¹, Hristo Mangarov³, Konstantin Stavrov¹

¹Medical Institute of the Ministry of Interior, Medical Institute of Ministry of Interior (MVR), Department of Dermatology, Venereology and Dermatologic Surgery, General Skobelev Nr 79, Sofia, Bulgaria; ²Onkoderma, Polyclinic for Dermatology and Dermatologic Surgery, General Skobelev 26, Sofia, Bulgaria; ³Medical Institute of Ministry of Interior (MVR), Department of Dermatology and Dermatologic Surgery, General Skobelev 79, 1606 Sofia, Bulgaria

Abstract

Citation: Tchernev G, Temelkova I, Mangarov H, Stavrov K. Comparative Analysis of the Applicability of Island Flap in Primary and Recurrent Basal Cell Carcinomas of Similar Localization. Open Access Maced J Med Sci. <https://doi.org/10.3889/oamjms.2018.189>

Keywords: Basal cell carcinoma; Risk factors; Treatment; Island flap; Mohs micrographic surgery

***Correspondence:** Georgi Tchernev, Medical Institute of the Ministry of Interior, Medical Institute of Ministry of Interior (MVR), Department of Dermatology, Venereology and Dermatologic Surgery, General Skobelev Nr 79, Sofia; Onkoderma, Polyclinic for Dermatology and Dermatologic Surgery, General Skobelev 26, Sofia, Bulgaria. E-mail: georgi_tchernev@yahoo.de

Received: 19-Apr-2018; **Revised:** 23-May-2018; **Accepted:** 25-May-2018; **Online first:** 05-Jun-2018

Copyright: © 2018 Georgi Tchernev, Ivanka Temelkova, Hristo Mangarov, Konstantin Stavrov. This is an open-access article distributed under the terms of the Creative Commons Attribution-NonCommercial 4.0 International License (CC BY-NC 4.0)

Funding: This research did not receive any financial support

Competing Interests: The authors have declared that no competing interests exist

BACKGROUND: Basal cell carcinoma belongs to non-melanoma skin cancers and is the most prevalent neoplasia that shows a tendency to increase over the last few decades. It occurs most often in skin areas exposed to sunlight. It is characterised by slow progression, low tendency to metastasising and good prognosis when the right choice of treatment has been made. The difficulty in the treatment of basal cell carcinomas is determined by their localisation and puts to the test the aesthetic potential of dermatosurgeons. Complete surgical excision is the standard approach in most uncomplicated cases. In relapsing basal cell carcinoma or carcinoma with aggressive or unfavourable histopathological characteristics, the clinician faces the dilemma of identifying the most appropriate method of treatment. To find the decision, help comes from the individualisation of each case and the related risk factors.

CASE REPORT: Two cases of basal cell carcinoma of similar localisation are presented, where the carcinomas are removed using island flaps. In spite of the desire to observe the recommended field of surgical security (by the desire for the ultimate esthetic effect for the patient), one of the tumours was not completely removed, and as an alternative, reoperation was proposed using Mohs micrographic surgery (MMS).

CONCLUSION: The choice of a surgical technique, which would guarantee a better outcome and could be applied depending on the individual risk factor in each patient, is discussed.

Introduction

Basal cell carcinoma is the most common malignant tumour composed of cells resembling those of the basal layer of the epidermis [1]. The disease rate is 200/100.000 people on the average [2] [3]. The affection of patients with white skin, fair hair and blue eyes, as well as male patients, prevails [4] [5]. It is believed that the main reason for its occurrence is the long-term exposure to sunlight over the patient's lifetime or accidental intensive exposure to ultraviolet radiation resulting in skin burns [4] [5]. It usually affects the exposed areas of the skin, i.e. the face,

scalp, ears, neck and shoulders [1]. This epidermal tumour rarely metastasises (only certain types), but in the presence of a primary lesion, there is a risk of occurrence of a new lesion at the same site or another part of the body [5] [6]. For this reason, surgical removal of the tumour should be a priority [6].

We at this moment present two cases of basal cell carcinomas with a similar localisation in the area of the face, which are removed by island flap. In one of the patients, the tumour is completely removed, while in the other it is not. The applicability of island flap in various patients is discussed according to their risk profile.

Case Report 1

An 82-year-old woman is presented, with height 156 cm and weight 49 kg, in a good overall condition. There is no evidence of family history, concomitant diseases and medication. The patient was first admitted to the clinic for surgical removal of a neoplasm that occurred approximately 2 years before, which gradually began to increase in the last few months. During the dermatological examination, we found a nodular formation on the left side of the nose, at the border with the nasolabial fold. The lesion had a rigid consistency, nodular, without a pearl edge, located immediately below the nasolabial fold, but at the same time involving the ala nasi on the left (Figure 1a).

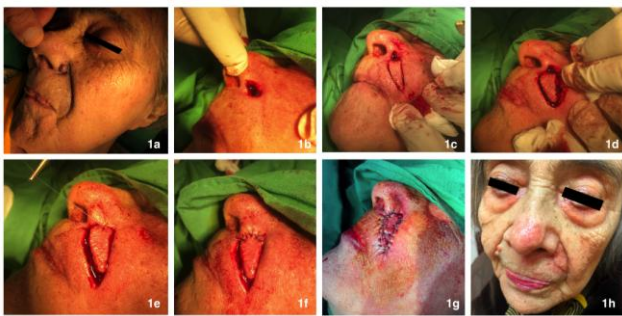

Figure 1: The lesion was removed in the form of the letter O, with a comparatively small field of surgical security of 0.3 cm in all directions. Then contouring of a triangle in the distal direction from the nose was performed, and the contours were gradually prepared to the musculature in depth (1c-d). This was followed by a transposition of the already prepared triangle to the ala nasi and a careful adaptation of the wound edges (1e-g)

There was no clinical evidence of the involvement of the subcutaneous area and the adjacent vascular and nerve bundles. Radical removal was performed under local anaesthesia via island flap (1b-h). The lesion was removed in the form of the letter O, with a comparatively small field of surgical security of 0.3 cm in all directions.

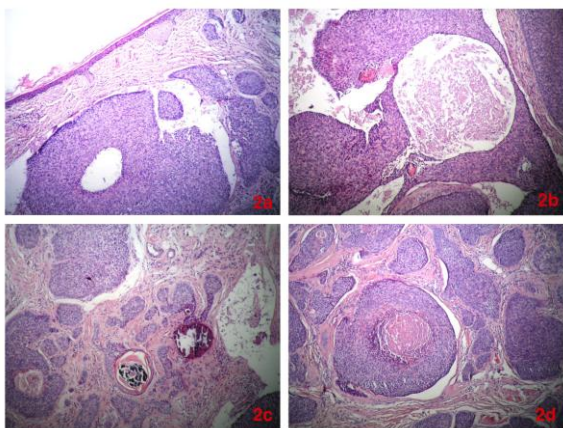


Figure 2: The histological examination confirmed the diagnosis: basal cell carcinoma with free resection edges, size 0.6/0.4 cm (Figure 2a-d). Good cosmetic results were achieved (2h)

Then contouring of a triangle in the distal direction from the nose was performed, and the contours were gradually prepared to the musculature in depth (1c-d).

This was followed by a transposition of the already prepared triangle to the ala nasi and a careful adaptation of the wound edges (1e-g). The histological examination confirmed the diagnosis: basal cell carcinoma with free resection edges, size 0.6/0.4 cm (Figure 2a-d). Good cosmetic results were achieved (2h).

Case Report 2

A 56-year-old man is presented, with height 178 cm and weight 108kg, in a good overall condition. There is no evidence of family history. The patient was first admitted to the clinic for surgical removal of a tumorous formation in the nasal area. In 2006, the patient underwent a primary tumour surgery (a tumour was localised near the described one), and in 2014 there was a relapse, and the patient was operated again using advanced plastic surgery. Histological data showed that the patient had basal cell carcinoma resected in sano. Meanwhile, radiotherapy was also conducted.

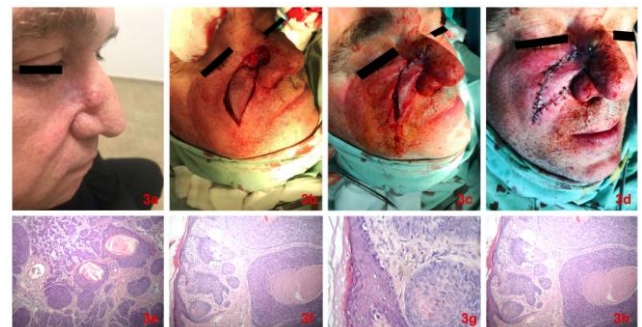


Figure 3: Island flap in patient with recurrent BCC. Similar to case 1 the the tumour lesion was removed, with a comparatively small field of surgical security in all directions. Then contouring of a triangle in the distal direction from the nose was performed, and the contours were gradually prepared to the musculature in depth (3b, 3c). This was followed by a transposition of the already prepared triangle to the ala nasi and a careful adaptation of the wound edges (3d). Histological evidence showed the presence of basal cell carcinoma with multifocal growth, maximum tumor diameter 12mm (Figs 3e-h)

During the dermatological examination, a tumour formation was found, with a solid texture, similar nodular aspect (as in the first female patient described), a clear distinction from the healthy/surrounding tissue, with multiple telangiectasias, located above the ala nasi, in the area of the right nasolabial fold (Figure 3a). Following consultation with an ENT specialist, an involvement of the lateral nasal wall was observed, from a formation adjacent to a cicatrix from a previous intervention,

without adhesion to the underlying cartilage. Island flap was performed similarly to the one described for the first patient (3b-3d). Histological evidence showed the presence of basal cell carcinoma with multifocal growth, maximum tumor diameter 12 mm; tumor infiltration in-depth and along the lateral resection lines (Figure 3e-3h). Tumor remnants were planned for removal using Mohs micrographic surgery.

Discussion

Patients with basal cell carcinoma are susceptible to recurrence of a primary tumour but also to the development of new, not only basal cellular but also other types of carcinomas [7]. Therefore, the identification of additional risk factors is, on the one hand, 1) essential for calculating the individual risk for each patient, and 2) of paramount importance for early stage eradication [2] [7].

Approximately 80% of all basal cell tumours appear in the facial area, with 25-30% of them on the nose [4]. This localisation is related to 2.5 times higher risk of relapse than any other and is considered to be a feature of high-risk carcinoma also because the area is associated with large anatomical features and difficulty in identifying tumour boundaries [4]. Risk factors include: 1) skin phototype, 2) prolonged exposure to ultraviolet radiation, and last but not least 3) genetic predisposition, i.e. xeroderma pigmentosum, albinism, DNA repair deficiencies, family history of cancer, immunosuppression and exposure to carcinogenic substances (arsenic, polycyclic hydrocarbons) [2] [4].

The main goal in the treatment of basal cell carcinomas is the elimination of a tumour with maximum preservation of the normal function and structure of tissues [5]. Therefore, treatment decisions should be individualised according to the specific risk factors for each patient, but should also take into account the respective surgical security zones [5] [6] [7].

What is the most effective treatment approach for small to medium-sized tumours is controversial, and in most cases standard therapy is surgical excision [6][7]? The surgical approach should vary depending on the size, depth and location of the tumour, as well as the individual desire of each patient and his/her physician to be minimally traumatic and at the same time maximally effective [5] [6] [7]. Reconstruction of nasal defects after excision of skin tumours is almost always a challenge due to the complex three-dimensional structure of the nose and the need for the postoperative outcome to be aesthetically acceptable [4] [5].

It is currently believed that MMS or the so-

called Mohs micrographic surgery is a “gold standard” for the treatment of advanced and recurrent basal cell carcinomas, where the tumor and the surrounding skin are visualized microscopically, giving the clearest picture of pathological changes in the periphery of the resected tissue [8] [9].

In our two cases, island flap was performed with good results. Mohs micrographic surgery (MMS) should be a priority for tumours that show histologically infiltrative, sclerosing, micronodular or recurrent features [5] [8] [9]. Basal cell tumours measuring over 1 cm, aggressive histology and age of the patient over 80 years are thought to be the main MMS indicators [4] [5] [8] [9]. The clue of MMS is the complete control of the peripheral and deep resection fields, allowing re-excision and microscopic extension of the resection boundaries in a precisely defined surgical zone [8] [9]. This allows avoiding unnecessary removal of additional tissue, which is a common practice in conservative surgical techniques [5] [8] [9]. These properties make MMS a reliable treatment for carcinomas, especially when it comes to delicate areas such as the face [5] [8] [9]. The results from the studies conducted so far have shown that MMS provides the lowest relapse rate between 0 and 2.5%, and therefore, this treatment should also be the first choice for relapsing basal cell carcinomas of the face [4] [5] [8] [9] [10].

In conclusion, island flap should not be a therapeutic option in patients with recurrent basal cell carcinomas and those who have undergone radiotherapy. Mohs micrographic surgery (MMS) in these patients ensures maximum safety, although the aesthetic results are less acceptable than in island flap. In patients with primary, untreated, small to medium basal cell carcinomas, island flap is a good therapeutic solution.

References

1. Tchernev G, Voicu C, Mihai M, Lupu M, Tebeica T, Koleva N, Wollina U, Lotti T, Mangarov H, Bakardzhiev I, Lotti J, Franca K, Batashki A, W.Patterson J. Basal cell carcinoma surgery: simple undermining approach in two patients with different tumour locations. *Open Access Maced J Med Sci*. 2017; 5(4): 506–510. <https://doi.org/10.3889/oamjms.2017.143> PMID:28785345 PMCid:PMC5535670
2. Hallaji Z, Rahimi H, Mirshams-Shahshahani M. Comparison of risk factors of single basal cell carcinoma with multiple basal cell carcinomas. *Indian J Dermatol*. 2011; 56(4): 398–402. <https://doi.org/10.4103/0019-5154.84766> PMID:21965847 PMCid:PMC3179002
3. Tchernev G, Pidakev I, Lozev I, Lotti T, Cardoso JC, Patterson JW. Undermining plastic surgery as a possible option for treating basal cell carcinoma of the forehead. *Wien Med Wochenschr*. 2017; 167(5-6):131-133. <https://doi.org/10.1007/s10354-017-0542-x> PMID:28194541
4. Wollina U, Bennewitz A, Langner D. Basal cell carcinoma of the outer nose: Overview on surgical techniques and analysis of 312

patients. *J Cutan Aesthet Surg.* 2014; 7(3): 143–150.
<https://doi.org/10.4103/0974-2077.146660> PMID:25538434
PMCID:PMC4271293

5. Tourli I, Langner D, Haroske G, Tchernev G, Lotti T, Wollina U. Basal cell carcinoma of the head-and-neck region: a single center analysis of 1,750 tumors. *Georgian Med News.* 2016; (250):33-9. PMID:26870972

6. Tchernev G, Chokoeva AA, Penev PK, Ananiev J, Nowak A, Bayyoud Y, Philipov S, Cardoso JC, Wollina U. Relapsing advanced metatypical basal cell carcinomas (MTBCC) of the face: surgical modalities. *Wien Med Wochenschr.* 2014; 164(23-24):529-35. <https://doi.org/10.1007/s10354-014-0314-9> PMID:25274011

7. Tchernev G, Pidakev I, Lozev I, Lotti T, Wollina U. Multiple nonsyndromic acquired basal cell carcinomas : Uncommon clinical presentation in a Bulgarian patient. *Wien Med Wochenschr.* 2017; 167(5-6):134-138. <https://doi.org/10.1007/s10354-017-0545-7>

PMid:28220371

8. Hoorens I, Batteauw A, Van Maele G, Lapiere K, Boone B, Ongenaes K. Mohs micrographic surgery for basal cell carcinoma: evaluation of the indication criteria and predictive factors for extensive subclinical spread. *Br J Dermatol.* 2016; 174(4):847-52. <https://doi.org/10.1111/bjd.14308> PMID:26595159

9. Vuyk HD, Lohuis PJ. Mohs micrographic surgery for facial skin cancer. *Clin Otolaryngol Allied Sci.* 2001; 26(4):265-73. <https://doi.org/10.1046/j.1365-2273.2001.00484.x>

10. van Baardwijk A, Verhaegh ME, Krekels GA, Vermeulen AH, Neumann HA. Mohs' method of micrographic surgery as treatment for recurrent basal cell carcinoma. *Ned Tijdschr Geneeskd.* 1997; 141(11):524-9. PMID:9190509