

A Case of Orbital Myositis Presenting With Dizziness

Neville Aquilina*, Vincent Bugeja, Charmaine Zahra

St Vincent de Paul, Ingiered Road, Luqa, Malta

Abstract

Citation: Aquilina N, Bugeja V, Zahra C. A Case of Orbital Myositis Presenting With Dizziness. Open Access Maced J Med Sci. 2018 Jul 20; 6(7):1278-1281. <https://doi.org/10.3889/oamjms.2018.192>

Keywords: Pain; Complex ophthalmoplegia; Unilateral; Steroids; Dizziness

***Correspondence:** Neville Aquilina. St Vincent de Paul, Ingiered Road, Luqa, Malta. E-mail: nevaqui@gmail.com

Received: 09-Jan-2018; **Revised:** 29-Mar-2018; **Accepted:** 30-Mar-2018; **Online first:** 13-Jul-2018

Copyright: © 2018 Neville Aquilina, Vincent Bugeja, Charmaine Zahra. This is an open-access article distributed under the terms of the Creative Commons Attribution-NonCommercial 4.0 International License (CC BY-NC 4.0)

Funding: This research did not receive any financial support

Competing Interests: The authors have declared that no competing interests exist

BACKGROUND: Orbital myositis is an idiopathic, inflammatory, non-infectious condition, typically confined to more than one extraocular muscle and usually targeting young females in their third decade.

CASE REPORT: We describe a case of orbital myositis uncommonly afflicting an adult male. He initially presented with a sensation of dizziness when turning his head and mobilising, together with right-sided orbital pain that failed to respond to the vestibular sedative cinnarizine. Failure to resolve and development of diplopia initially prompted a working diagnosis of ocular myasthenia gravis. On further investigation using HESS charting, paresis in the inferior and medial rectus and superior oblique ocular muscles of the right eye were elicited correlating with clinical examination. However, the lack of response to low dose steroids and acetylcholinesterase inhibitors, together with a negative screen for myasthenia antibodies, precluded a diagnosis of ocular myasthenia gravis from being made. Other investigations included a high creatinine kinase and lactate dehydrogenase which indicated pathology in the extraocular muscles themselves. An MRI scan showed normal extraocular muscle thickness while excluding other orbital pathology. Exclusion of a variety of other conditions subsequently led to a diagnosis of orbital myositis.

CONCLUSION: Response to high dose steroids consolidated this diagnosis with a rapid response ascertained clinically by resolution of pseudo-vertigo and pain, as well as the ophthalmoplegia with follow-up on HESS charting. We aim to raise awareness of this rare condition that carries a good response to steroids.

Introduction

Orbital myositis (OM) is an idiopathic inflammatory, non-infectious condition confined to more than one extraocular muscle (EOM), usually targeting young females in their third decade. It occurs suddenly and affects commonly one eye with pain that is worse on eye movements, in more severe forms eyelid swelling (blepharitis), proptosis and conjunctival injection become prominent. Visual acuity is preserved. Focal or diffuse homogeneous enlargement of EOMs and surrounding structures is often observed on neuroimaging [1] [2].

Some conditions can mimic or have been linked to OM [2] [3] [4]. In our discussion, we will highlight the importance of excluding other diseases before making a diagnosis of OM.

Case presentation

We report a case of a 38-year-old male patient whose initial presentation was a mild sensation of dizziness when turning his head and when mobilising, which he described as a feeling that the room moved about as he shifted his gaze, but this was absent at rest and if he kept his gaze fixed. He also started complaining of pain in the right orbit, which increased with eye movements. These symptoms were attributed to vertigo secondary to acute inner ear pathology by the general practitioner who prescribed the vestibular sedative cinnarizine to no effect. Initially, eyesight was intact however he soon developed diplopia on looking down and medially. This diplopia was intermittent while the motion-related dizziness remained the most frustrating symptom. It was noted that this 'vertiginous-like' dizziness was not

of vestibular origin because if he stopped turning his head, it subsided immediately and was never associated with nausea. Instead, it was associated with a dull right-sided orbital pain and also failed to respond to cinnarizine.

Upon review, the neurologist suspected ocular myasthenia gravis (OMG) and started him on pyridostigmine 60 mg, 4 hourly, together with a small dose of atropine 2 mg twice daily. He was also prescribed 7.5 mg daily of prednisolone (in 3 divided doses) set to titrate up slowly over the following weeks to 20 mg. There was no improvement in the patient's symptoms. Nicotinic acetylcholine receptor antibodies were negative. Other antibodies typical of myasthenia gravis such as anti-Musk (muscle-specific kinase) and anti-striational antibodies were also negative.

Table 1: Investigations

Test	Result	Normal range
S-immunoglobulin G	13.73	7.01-13.05
LCR-immunoglobulin G	46.00	< 40
S-Albumin	45.20	40.84-51.72
LCR-Albumin	327.00	< 350
Link index (IgG index)	0.46	< 0.65
ACE Liquor	0.34	0.06-0.25
Muscle specific tyrosine kinase (MuSK) antibodies	< 0.01	< 0.05 - negative
Calcium channel antibodies (P/Q)	negative	< 0.25
Acetylcholine receptor antibodies	< 0.1	< 0.4 - negative
Thyroid stimulating hormone receptor antibodies	< 0.4	< 0.4 - negative
Angiotensin-converting enzyme	5.3	65-114
Creatinine kinase	286	38-174
Alpha-hydroxybutyric acid	259	72-182
Lactate dehydrogenase	274	135-220
Ferritin	423	28-365

A battery of blood tests was done including renal, liver and thyroid function, inflammatory markers, creatinine kinase (CK), full blood count together with a fasting blood glucose and glycosylated haemoglobin (HbA1c). The CK was somewhat elevated; however, this was initially attributed to his muscular build. Moreover, when compared to previous baseline levels this was the first instance an elevated CK was recorded. Otherwise, all other blood tests, including the diabetes screen, the thyroid function and an autoimmune screen (anti-nuclear and anti-neutrophil cytoplasmic antibodies plus rheumatoid factor) were also normal. Clinically, he had no features of Graves' disease ophthalmopathy. Chest X-ray showed no abnormality in the anterior mediastinum, together with a normal CT (computed tomography) of the head and thorax thereby excluding thymoma. A lumbar puncture was performed whereby his cerebrospinal fluid failed to show any oligoclonal bands and the IgG index was normal thus excluding acute inflammatory demyelinating conditions such as multiple sclerosis. Additionally, a normal MRI (magnetic resonance imaging) of the brain further evidenced such preclusion of these possibilities.

An ophthalmic consultation was made, and HESS charting showed deficits in the medial rectus,

inferior rectus and the superior oblique of the right eye. At this point, OMG was considered as most plausible. However, the movement deficits in the right eye remained fixed, though at times clinically he would show variable features appearing like a 4th (trochlear) nerve palsy.

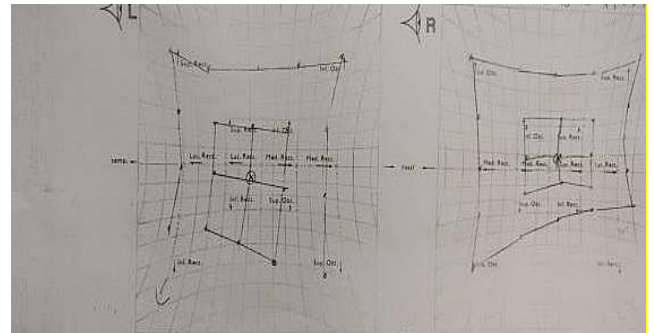


Figure 1: Baseline testing, showing deficits in medial rectus, inferior rectus and the superior oblique of the right eye

Presence of unremitting orbital pain then started to entertain the possibility of other diagnoses. Due to the high CK, chronic progressive external ophthalmoplegia (CPEO) was considered, but lack of other features and a unilateral predominance vouched against mitochondrial cytopathy.

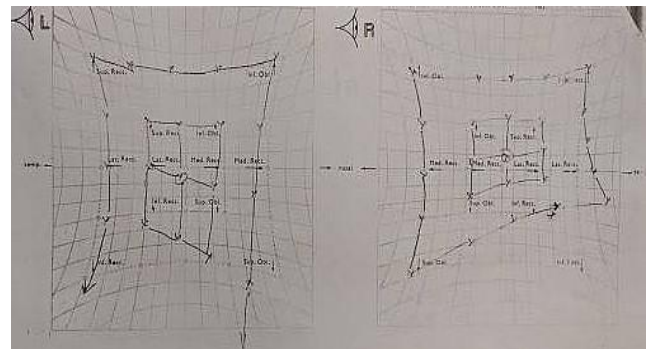


Figure 2: During low dose (7.5 mg) steroids, showing the persistence of the right-sided deficit

Further diagnoses such as Miller Fisher syndrome, Tolosa-Hunt syndrome, oculopharyngeal muscular dystrophy and vasculitides were all excluded [the latter in view of his negative ANCA (anti-neutrophil cytoplasmic antibodies)]. Lambert-Eaton myasthenic syndrome was excluded since a negative voltage-gated calcium channel antibody screen also came back negative, while there were no signs of any associated bronchial malignancy. Neurosarcoidosis was excluded despite a marginally elevated cerebrospinal fluid ACE (angiotensin-converting enzyme) level following lumbar puncture testing. Normal serum ACE levels were also consistent with this.

The only diagnosis left to consider was orbital myositis, which possibility was strengthened given his serum creatinine kinase (CK) and lactate dehydrogenase (LDH) rise. Crucially, since

being administered 50 mg prednisolone daily, the symptoms had resolved completely within 3 days. Then the prednisolone was slowly tapered down over a period of 3 months and stopped. The condition did not recur, and CK returned to normal, further corroborating a working diagnosis of orbital myositis (OM). In this case, the OM would be classified as the milder LOOM (limited oligosymptomatic ocular myositis) variety, considering the absence of scleral injection, ptosis, proptosis and signs of inflammation in this case [9].

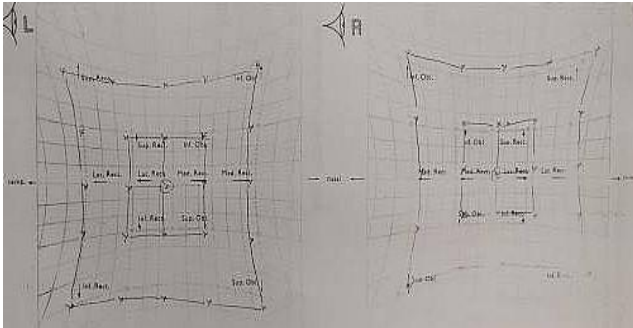


Figure 3: On high dose (50 mg) steroids, demonstrating resolution

We report a case with orbital myositis (OM) presenting initially with a movement related vague dizziness or 'vertiginous-like' sensation due to extraocular muscle weakness, which is a way how diplopia may manifest, from failure of the binocular tracking mechanism when shifting gaze. Diplopia sometimes produces a sensation of movement of the environment which may mimic genuine vertigo. True vertigo could not be present in this case because on sitting still there was no hallucination of movement of the patient himself or his surroundings (which is the *bona fide* description of vertigo), moreover the symptom failed to respond to cinnarizine (a vestibular sedative), whilst there was the added complication of right-sided orbital pain.

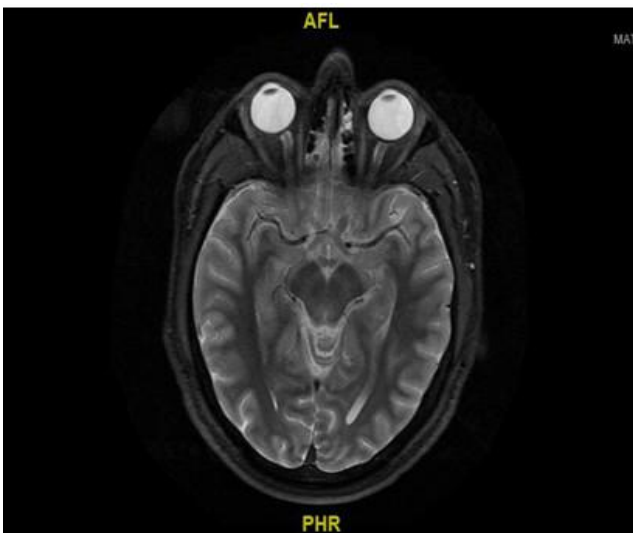


Figure 4: Plain MRI performed while the patient was not on steroid therapy

After a comprehensive exclusion, he was diagnosed with OM. We emphasise that OM should be included in the differential when considering a diagnosis of OMG (especially when atypical features are present). Imaging although helpful is not always useful in diagnosing OM, as in this case, in which enlargement of the EOM or surrounding structures was not visible (Figure 4). However, there was an immediate response to high dose systemic steroids, whereas conversely, in OMG this would have precipitated a myasthenic crisis.

Discussion

Features suggestive of orbital myositis, as opposed to ocular myasthenia gravis include:

- The features were unilateral;
- There was pain especially with eye movements;
- Muscle enzymes were all high (CK, LDH);
- No response was elicited to low dose steroids and pyridostigmine;
- Immediate resolution with high dose steroids;

These cases mandate a full workup including ophthalmic examination, routine blood, inflammatory markers and thyroid function.

Further workup may consist of MRI orbits, CT or ultrasound. Typical radiological features are thickening and contrast enhancement of the EOM and possible surrounding structures such as myotendinous insertion and fat. In a significant number of cases, the orbital muscles appear normal.

Other diagnoses need to be excluded. Bilateral inflammation of EOMs, with sparing of the myotendinous junction is seen in dysthyroid eye disease. Features of Graves' ophthalmopathy comprise proptosis, chemosis and complex diplopia and would be confirmed by positive thyroid-stimulating hormone (TSH) receptor antibodies.

In IgG4-related disease, thyroid function tests are normal, but an enlargement of inferior rectus and both lacrimal glands are observed [3].

In cases of orbital cellulitis or tuberculosis, imaging would show pus collections or caseous necrosis respectively, in addition to the fever and leucocytosis [2] [5]. In our patient, TB was immediately excluded as the patient did not have a history of foreign travel or any TB contacts. Contrast-enhanced MRI is the most sensitive modality for showing individual EOM signal hyperintensity and swelling [7].

Neoplasm/metastasis is a differential in the absence of pain; imaging would show a focal mass or increase in signal intensity of EOM in lymphoma [2]. However, a definite diagnosis would need to be confirmed via extraocular muscle biopsy.

Inflamed EOM due to venous congestion may be diagnosed in patients with low-flow carotid cavernous fistula. Another feature of this condition is enlarged superior ophthalmic veins [4], and there may also be pulsatile exophthalmos.

In lesser severity, orbital myositis of the LOOM (limited oligosymptomatic OM) variety, treatment in non-diplopic patients, or in those having only slight diplopia with mild to moderate pain, utilising high dose non-steroidal anti-inflammatory drugs (NSAIDs) may be considered. Systemic corticosteroids are nevertheless necessary, except perhaps for the mildest non-diplopic forms, because they accelerate recovery and prevent recurrence, albeit relapse rates are still relatively high, being up to 81% in one study [6] despite steroids. In refractory, chronic, or recurrent cases, steroid-sparing agents such as immunosuppressants or radiation therapy may also be considered.

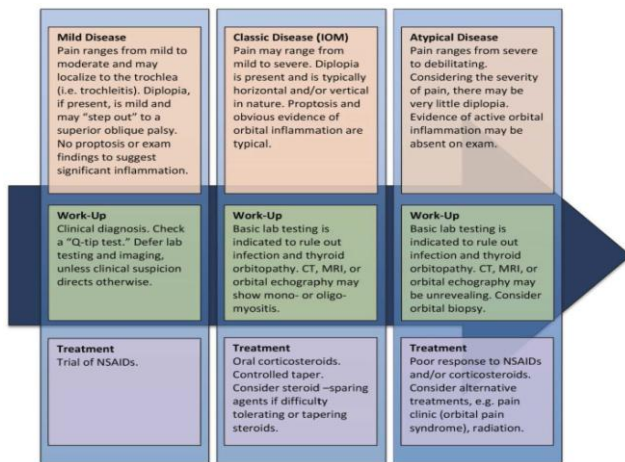


Figure 5: A clinical algorithm for orbital myositis [8]

"Q-tip test": A cotton-tipped applicator applied to the area over the trochlea, and other extraocular muscles may reveal point tenderness that the patient was otherwise unable to describe. This suggests trochleitis, superior oblique myositis/tendonitis, or focal myositis over the tender muscle or tendon.

In conclusion, to our knowledge this is the first published case report of OM presenting with dizziness as the primary symptom. Moreover, HESS charting is sensitive in mapping out any ophthalmoplegia that may not be prominent clinically. We have emphasised the importance of considering this rare inflammatory disease confined to the extraocular muscles and orbital

structures, once ocular myasthenia gravis, dysthyroid eye disease and organic causes (cellulitis, tumours, carotid-cavernous fistula) have been excluded, especially as prognosis with high dose steroid therapy is favourable.

Learning points: (i) the isolated finding of a complex ophthalmoplegia requires ocular myasthenia gravis to be excluded *a prima facie*; (ii) atypical features such as unilateral involvement, EOM or orbital pain, failure to respond to low dose steroids and a negative response to acetylcholinesterase inhibitors preclude ocular myasthenia gravis from the differential; (iii) MRI is essential to exclude other infiltrative conditions of the EOMs, albeit muscle biopsy would provide a definitive histological diagnosis; (iv) elevated muscle enzymes (CK, LDH) indicate a myositis; (v) once ocular myasthenia and organic causes have been excluded a trial of high dose steroids would be appropriate and thence a positive response effectively renders the diagnosis of orbital myositis highly plausible.

References

- Kralik SF, Kersten R, Glastonbury CM. Evaluation of orbital disorders and cranial nerve innervation of the extraocular muscles. *Magn Reson Imaging Clin N Am*. 2012; 20:413–434. <https://doi.org/10.1016/j.mric.2012.05.005> PMID:22877949
- Costa RM, Dumitrascu OM, Gordon LK. Orbital myositis: diagnosis and management. *Curr Allergy Asthma Rep*. 2009; 9:316–323. <https://doi.org/10.1007/s11882-009-0045-y> PMID:19656480
- Inaba H, Hayakawa T, Miyamoto W, Takeshima K, Yamaoka H, Furukawa Y, Kawashima H, Ariyasu H, Wakasaki H, Furuta H, et al. IgG4-related ocular adnexal disease mimicking thyroid-associated orbitopathy. *Intern Med*. 2013; 52:2545–2551. <https://doi.org/10.2169/internalmedicine.52.0902> PMID:24240795
- Chapman PR, Gaddamanugu S, Bag AK, Roth NT, Vattoth S. Vascular lesions of the central skull base region. *Semin Ultrasound CT MR*. 2013; 34:459–475. <https://doi.org/10.1053/j.sult.2013.09.003> PMID:24216454
- Danesh-Meyer HV, Rosser PM. Orbital inflammatory disease. *Int Ophthalmol Clin*. 2007; 47:79–92. <https://doi.org/10.1097/IIO.0b013e3181571eee> PMID:18049282
- Yan J, Wu P. Idiopathic orbital myositis. *J Craniofac Surg*. 2014; 25(3):884-7. <https://doi.org/10.1097/SCS.0000000000000510> PMID:24670274
- Schoser BG. Ocular myositis: diagnostic assessment, differential diagnoses, and therapy of a rare muscle disease - five new cases and review. *Clin Ophthalmol*. 2007; 1(1):37-42. PMID:19668464 PMID:PMC2699981
- Algorithm flowchart taken from: webeye.ophth.uiowa.edu/.../cases/234-Idiopathic-Orbital-Myositis.htm
- Önder Ö, Bilgin RR, Köşkereliöğlu A, Gedizlioğlu M. Orbital myositis: evaluating five new cases regarding clinical and radiological features. *Nöro Psikiyatri Arşivi*. 2016; 53(2):173. <https://doi.org/10.5152/npa.2015.10214> PMID:28360792 PMID:PMC5353024