

Posterior Reversible Encephalopathy Syndrome as a Postpartum Complication

Samra Kadić-Vukas¹, Mirsada Hodžić¹, Lejla Tandir-Lihic¹, Lejla Hrvat¹, Azra Kožo-Kajmaković¹, Nina Kuzmanović¹, Haris Vukas^{2*}

¹Department of Neurology, Cantonal Hospital Zenica, Zenica, Bosnia and Herzegovina; ²Clinic of Vascular Surgery, Sarajevo, Bosnia and Herzegovina

Abstract

Citation: Kadić-Vukas S, Hodžić M, Tandir-Lihic L, Hrvat L, Kožo-Kajmaković A, Kuzmanović N, Vukas H. Posterior Reversible Encephalopathy Syndrome as a Postpartum Complication. Open Access Maced J Med Sci. <https://doi.org/10.3889/oamjms.2018.193>

Keywords: Posterior reversible encephalopathy syndrome (PRES); MRI; Postpartum cesarean; Epileptic seizures; Cortical blindness

***Correspondence:** Haris Vukas. Clinic of Vascular Surgery, Sarajevo, Bosnia and Herzegovina. E-mail: haris.vks77@gmail.com

Received: 25-Mar-2018; **Revised:** 05-Apr-2018; **Accepted:** 06-Apr-2018; **Online first:** 14-May-2018

Copyright: © 2018 Samra Kadić-Vukas, Mirsada Hodžić, Lejla Tandir-Lihic, Lejla Hrvat, Azra Kožo-Kajmaković, Nina Kuzmanović, Haris Vukas. This is an open-access article distributed under the terms of the Creative Commons Attribution-NonCommercial 4.0 International License (CC BY-NC 4.0)

Funding: This research did not receive any financial support

Competing Interests: The authors have declared that no competing interests exist

BACKGROUND: Posterior reversible encephalopathy syndrome (PRES) is a clinical-radiological syndrome with seizures, altered consciousness, visual disturbances and headache among other symptoms. Hinchey et al. first described Pres in 1996, with two other case series published shortly after.

CASE REPORT: A 23-year-old women patient was emergency sent from General Hospital Tešanj due to a crisis of consciousness and repeated epileptic seizures. The patient had a second birth before 10 days (postpartum cesarean) in general endotracheal anaesthesia (two cesarean-born babies). On magnetic resonance imaging (MRI) of cranium described both sides of the symmetrically frontal, parietal (and pre-ventricular gyri) and occipitally visible T2W/FLAIR hyperintensity focuses on the cortex and the thin layer of white mass subcortically. In the projection of the lesions parts, discrete DWI hyperintensity is seen without a reliable ADC correlate. The patient improved after management with intravenous fluids, antibiotics, antiepileptics and monitoring of blood pressure. According to latest experiences delayed diagnosis and treatment may lead to mortality or irreversible neurological deficit. Aggravating circumstances are differential diagnoses that include cerebral infarction (ischemic, haemorrhage), venous thrombosis, vasculitis, pontine or extrapontine myelinolysis.

CONCLUSION: MRI of the brain is key to make this distinction with crucial recognition and an open mind from radiology and neurology specialist.

Introduction

Posterior reversible encephalopathy syndrome (PRES) is a clinical-radiological syndrome with seizures, altered consciousness, visual disturbances and headache among other symptoms [1] [2]. Hinchey et al., first described Pres in 1996, with two other case series published shortly after [3] [4] [5]. Visual disturbance: blurred vision, homonymous hemianopsia and cortical blindness. Altered consciousness: mildly confused or agitated or comatose, seizures and status epilepticus are common, nonconvulsive status epilepticus (may be more frequent). Postictal confusion lasts for hours, but PRES and nonconvulsive status can both persist for several days and be mistaken for psychosis, drug intoxication, or psychogenic states [6].

Case Report

A 23-year-old women patient was emergency sent from General Hospital Tešanj due to a crisis of consciousness and repeated epileptic seizures. The patient had a second birth before 10 days (postpartum cesarean) in general endotracheal anaesthesia (two cesarean-born babies), blood group A Rh⁺. General condition on discharge was (2nd day postpartum) afebrile, TA 110/70 mm Hg, heart frequency 70/min, ordinary diuresis (mictio) and defecation, wound without signs of inflammation, leukocytes: 8.8 x 10⁹/l, erythrocytes 4.15 x 10¹², platelets 195 x 10⁹/l, Hgb 132 g/l. Recommended continuation of therapy after discharge from the hospital enoxaparin 40 mg s.c. x1, cephalixin 500 mg tbl. x2, ergometrine 0.2 mg tbl. x3.

On admission to the Urgency department of Cantonal Hospital Zenica, the patient was unconscious with the presence of an epileptic attack (frozen lower jaw), it was immediately applied to airway, skin and mucous membranes were cyanotic, low frequency and shallow respiration, above the right lungs a sharp lung sound, circular-symmetrical and non-reactive pupils. TA 150/100 mm Hg, heart frequency 110/min, spO_2 88%, febrile $38.2^{\circ}C$, with a fixed permanent urinary catheter, urine dark (concentrated), CT cranium without pathological findings (made in General Hospital Tešanj)

At the Urgency department of Cantonal Hospital, Zenica was administered a solution of 0.9% NaCl a 500 ml (8 ml/min) i.v., diazepam 10 mg i.v. x 1, O_2 3l/min. After epileptic treatment attacks stopped, with the opening of the eye on the call, the pupils symmetrical and reactive, unarticulated speech, the postictally altered state of consciousness. The wound was calm without signs of inflammation after postpartum cesarean; the breasts swarmed with no signs of mastitis. Laboratory on admission: leukocytes $17.8 \times 10^9/l$, erythrocytes $4.77 \times 10^{12}/l$, hemoglobin 142 g/l, platelets $360 \times 10^9/l$, MCV 89.4 fL, MCH 29.8 pg, MCHC 33.3 g/dl, MPV 8.3 fl, RDW 12% CV, glucose 6.6 mmol/l, urea 2.2 mmol/l, creatinine 83 μ mol/l, sodium 143 mmol/l, potassium 3.3 mmol/l, chlorides 106 mmol/l.

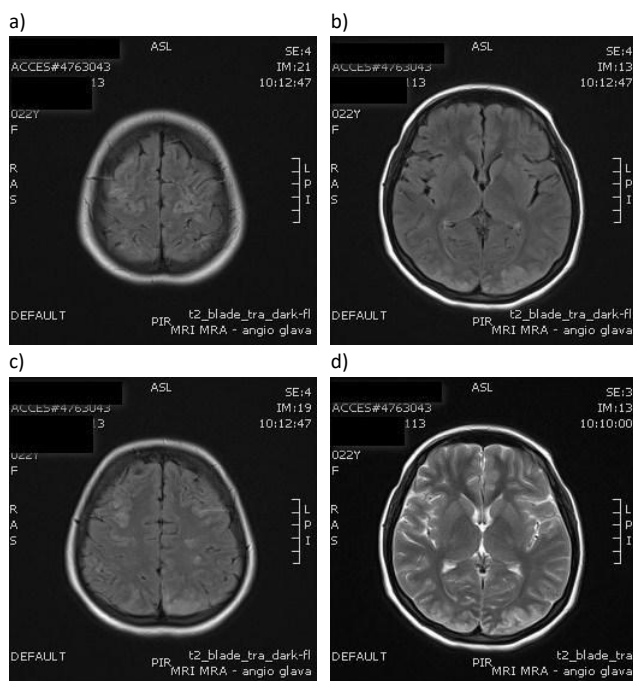


Figure 1: MRI of the cranium

The first day on neurological intensive care, general condition was far from stable, patient continued to febrile $38.1^{\circ}C$, euphoric, dehydrated mucous membranes, cortical blindness, skin without rash and inflammation, meningeal signs negative, somnolent, febrile, cortical loss of vision, cranial

nerve findings neat, on anti-gravitational position no lateralization, muscular and tapered reflexes heightened, pathological reflexes were not induced. Generalized epileptic attacks were repeated twice. Administered therapy was phenobarbitone 100 mg i.m. x 1, 0.9% NaCl a 500 ml i.v. (3 ml/min in total 1500 ml during 24 hours), mannitol 20% and 250 ml x 3 (every 8 hours) continued in next day, metamizole sodium 2.5 g i.v. x 1, diclofenac 100 mg i.v. x 1, KCl ampoules 20 ml i.v. x 2 (20 mmol/hour). Glucose 10% a 500ml (3ml/min in total 1000ml during 24 hours), amoxicillin+clavulan acid 1.2 g x 3 i.v. (every day). On ordered therapy, epileptic attacks stopped again. RTG thorax showed the bilateral Hilo-periciliary, and right Hilo-para-cardio-basal enhances the lung with gentle, murky shadings as part of infiltrative inflammatory changes.

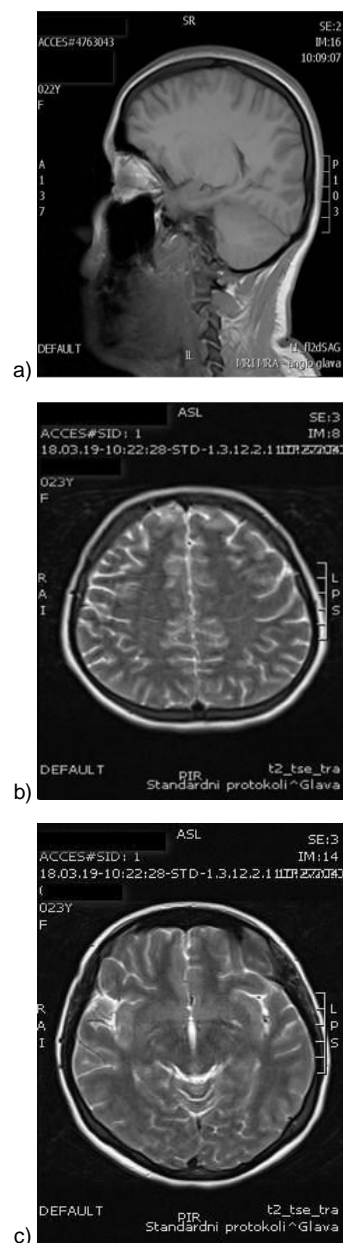


Figure 2: Control MRI of the cranium

On MRI of cranium described both sides of the symmetrically frontal, parietal (and pre-ventricular gyri) and occipitally visible T2W/FLAIR hyperintensity focuses on the cortex and the thin layer of white mass subcortically. In the projection of the lesions parts, discrete DWI hyperintensity is seen without a reliable ADC correlate (Figure 1).

Cerebrospinal fluid was clear, colorless, glucose 2.6 mmol/l (ref. 2.99-4.44), proteins 0.9 g/l (ref. 0.1-0.6), chlorides 125 mmol/l (ref. 115-129), cell number $1.0 \times 10^6/l$ (ref. 0.0-5.0).

From the second to the third day, the overall condition was stabilised without new epileptic attacks, patient aware consciousness, afebrile, sitting alone, recognised movements but still unclear images in the field of vision, in an anti-gravitational position without lateralisation, pathological reflexes were not caused.

Urine cultures were taken immediately after admission, and it was isolated *Pseudomonas aeruginosa*-cefotaxime-resistant, we corrected antibiotic therapy due to antibiogram with ciprofloxacin 500 mg x 2 per os, blood cultures were negative. EEG on the 6th day showed above the front-centre-temporal regions, complexes of the sharp wave-slow wave, sharp waves in groups of 3-4, medium-heavy to severe degree of alternating accentuation of the sides, at one time short-term paroxysm. The epileptic activity dominates the front-centre-temporal regions with the tendency of generalisation.

In the control MRI examination, infra and supratentorial cortically and subcortically were seen gentle areas of in-homogeneously elevated signals regarding almost complete regression of previously recorded changes. Changes did not show diffusion restriction. There was no sequela of haemorrhage (Figure 2).

The patient was discharged conscious, communicative, oriented; cranial nerves found neat in anti-gravity position without lateralisation or pathological reflexes. Laboratory findings were in normal ratio except potassium 3.7 mmol/l. Recommended per os therapy: Lamotrigine 50 mg tbl x 1 (after 7 days 50 mg tbl in the morning and 25 mg tbl at the evening), phenobarbital 25 mg tbl x 1 (7 days then stop), ranitidine 150 mg tbl x 1.

Discussion

There are three proposed hypotheses of PRES pathophysiological mechanism till now: 1) cerebral vasoconstriction causing subsequent infarcts in the brain, 2) failure of cerebral autoregulation with vasogenic edema, and 3) endothelial damage with

blood-brain barrier disruption further leading to fluid and protein transudation in the brain [7] [8] [9]. New reports of permanent neurological impairment and mortality reaching 15% challenge reversible nature of PRES [10] [11].

We do not have need life-sustaining treatments for PRES regarding non-available clinical studies. According to latest experiences delayed diagnosis and treatment may lead to mortality or irreversible neurological deficit [12] [13]. Aggravating circumstances are differential diagnoses that include cerebral infarction (ischemic, haemorrhage), venous thrombosis, vasculitis, pontine or extrapontine myelinolysis.

Blood transfusion may cause a rapid increase in total blood volume, which further leads to cerebral blood flow overload. Abrupt or acute cerebral hyperperfusion exceeding the capacity of auto-regulation of cerebral capillary perfusion pressure might result in vasogenic oedema found in PRES. The possibility of severe anaemia as the predisposing factor, due to an inadequate supply of oxygen to the brain may result in dysfunction of endothelial cells, further causing a functional loss or damage to the integrity of the blood-brain barrier in capillary circulation which cannot be ruled out [14].

There are published case of the patient presented with hypertensive urgency as well as stroke symptoms with hyponatraemia after regression of PRES symptoms patient was discharged with a serum sodium of 132 mmol/l [15].

Qiang Zhang and coworkers published PRES case that had unclear aetiology and they suspected and believed that aseptic meningitis might be a contributing factor. Never the less systemic infection has been linked to PRES only in one pediatric case that PRES associated with aseptic meningitis [16].

Because of that MRI of the brain is a key diagnostic method to make this distinction with crucial recognition and an open mind from radiology and neurology specialist. In the light of the absence of evidence of factors that trigger PRES as well as of the absence of sufficient medical evidence that would lead to the development of preventative and curative treatment methods, we consider that every case must be carefully and thoroughly investigate.

References

- McKinney AM, Short J, Truwit CL, McKinney ZJ, Kozak OS, SantaCruz KS, Teksam M. Posterior reversible encephalopathy syndrome: incidence of atypical regions of involvement and imaging findings. *AJR Am J Roentgenol.* 2007; 189(4):904-912. <https://doi.org/10.2214/AJR.07.2024> PMID:17885064

2. Roth C, Ferbert A. The posterior reversible encephalopathy syndrome: what's certain, what's new? *Pract Neurol*. 2011; 11(3):136-144. <https://doi.org/10.1136/practneurol-2011-000010> PMID:21551107
3. Hinchey J, Chaves C, Appignani B, Breen J, Pao L, Wang A, Pessin MS, et al. A reversible posterior leukoencephalopathy syndrome. *N Engl J Med*. 1996; 334(8):494-500. <https://doi.org/10.1056/NEJM199602223340803> PMID:8559202
4. Schwartz RB, Jones KM, Kalina P, Bajakian RL, Mantello MT, Garada B, Holman BL. Hypertensive encephalopathy: findings on CT, MR imaging, and SPECT imaging in 14 cases. *AJR Am J Roentgenol*. 1992; 159(2):379-383. <https://doi.org/10.2214/ajr.159.2.1632361> PMID:1632361
5. Schwartz RB, Bravo SM, Klufas RA, Hsu L, Barnes PD, Robson CD, Antin JH. Cyclosporine neurotoxicity and its relationship to hypertensive encephalopathy: CT and MR findings in 16 cases. *AJR Am J Roentgenol*. 1995; 165(3):627-631. <https://doi.org/10.2214/ajr.165.3.7645483> PMID:7645483
6. Hobson EV, Craven I, Blank SC. Posterior reversible encephalopathy syndrome: a truly treatable neurologic illness. *Perit Dial Int*. 2012; 32(6):590-594. <https://doi.org/10.3747/pdi.2012.00152> PMID:23212858
PMCID:PMC3524908
7. Vaughan CJ, Delanty N. Hypertensive emergencies. *Lancet*. 2000; 356(9227):411-417. [https://doi.org/10.1016/S0140-6736\(00\)02539-3](https://doi.org/10.1016/S0140-6736(00)02539-3)
8. Shin KC, Choi HJ, Bae YD, Lee JC, Lee EB, Song YW. Reversible posterior leukoencephalopathy syndrome in systemic lupus erythematosus with thrombocytopenia treated with cyclosporine. *J Clin Rheumatol*. 2005; 11(3):164-166. <https://doi.org/10.1097/01.rhu.0000164825.63063.43> PMID:16357738
9. Min L, Zwerling J, Ocava LC, Chen IH, Putterman C. Reversible posterior leukoencephalopathy in connective tissue diseases. *Semin Arthritis Rheum*. 2006; 35(6):388-395. <https://doi.org/10.1016/j.semarthrit.2006.01.003> PMID:16765716