

Brucellosis as the Cause of Non-Viral Bacterial Hepatitis: A Case Report

Bilger Çavuş^{1*}, Özge Çaydaşı², Ahmet Aktan³, Ercan Ayaz³

¹Bingöl State Hospital, Gastroenterology Department, Turkey; ²Bingöl State Hospital, Infectious Diseases, Turkey; ³Bingöl State Hospital, Radiology Department, Turkey

Abstract

Citation: Çavuş B, Çaydaşı Ö, Aktan A, Ayaz E. Brucellosis as the Cause of Non-Viral Bacterial Hepatitis: A Case Report. Open Access Maced J Med Sci. 2018 Jul 20; 6(7):1260-1262. <https://doi.org/10.3889/oamjms.2018.198>

Keywords: Brucellosis; Acute hepatitis; Liver transaminases

***Correspondence:** Bilger Çavuş, Bingöl State Hospital, Gastroenterology Department, Turkey. E-mail: dr_bilgercavus@yahoo.com

Received: 26-Feb-2018; **Revised:** 08-Apr-2018; **Accepted:** 09-Mar-2018; **Online first:** 17-May-2018

Copyright: © 2018 Bilger Çavuş, Özge Çaydaşı, Ahmet Aktan, Ercan Ayaz. This is an open-access article distributed under the terms of the Creative Commons Attribution-NonCommercial 4.0 International License (CC BY-NC 4.0)

Funding: This research did not receive any financial support

Competing Interests: The authors have declared that no competing interests exist

BACKGROUND: Brucellosis can lead to different clinical pictures such as hepatomegaly, granulomatous liver disease, hepatic abscess, and it can cause mild hepatic transaminase elevation in the laboratory investigations.

CASE REPORT: We found out that the etiologic agent was *Brucella* in our two cases admitted with acute hepatitis presentation in the investigations conducted. Liver transaminases were as follows for case 1 and case 2; AST: 306/187U/L, ALT: 368/312U/L, ALP: 355/264U/L, GGT: 116/197U/L, LDH: 887/549U/L, respectively. Sacroiliitis also accompanied the clinical picture in our first case. Our patients showed clinical and laboratory improvement with rifampicin, doxycycline, (additional streptomycin for 21 days in the patient with sacroiliitis) treatment.

CONCLUSION: Brucellosis which may manifest as a clinical picture regarding numerous medical branches should be considered in case of acute hepatitis, especially in endemic regions, along with viral hepatitis.

Introduction

Although hepatotropic viruses are more commonly responsible for the aetiology of acute hepatitis, the clinical picture of acute hepatitis may occur during the courses of many bacterial infections. Brucellosis is a zoonotic infection caused by *Brucella*, a gram-negative coccobacillus, and is estimated to affect about 500,000 humans annually in the world [1]. Brucellosis can manifest itself with very different clinical presentations such as high fever, fatigue, sweating, generalised body pain, arthralgia, depression, and therefore some difficulties may be experienced during its diagnosis [2]. Brucellosis can lead to different clinical pictures such as hepatomegaly, granulomatous liver disease, hepatic abscess, and it can cause mild hepatic transaminase elevation in the laboratory investigations [3] [4]. Brucellosis, especially in endemic areas, should be kept in mind along with viral hepatitis regarding the aetiology of acute hepatitis.

Case presentation

A 55-year-old female patient admitted to the outpatient clinic of internal medicine with the complaints of increasing fatigue, nausea and high fever recently. Her past medical history revealed that she did not have any known chronic disease and that she underwent the hysterectomy due to myoma uteri six months ago. The patient who was dealing with ovine breeding and living in a village was not on any continuous medication. On her physical examination, she was alert, her general status was good. There was an increased tenderness in the epigastric region and right upper quadrant during palpation. The liver was palpated for about 1 cm below the rib. Traube's space was open. Breath sounds were normal bilaterally, arterial blood pressure (BP) was 100/60 mmHg, fever was 37.8°C, S1 and S2 were normal on the auscultation of cardiac sounds. No additional sound and murmur were heard. Tenderness was detected in the left sacroiliac region. The patient had increased fever episodes reaching up to 38°C during clinical follow-up. Her blood and urine cultures were

collected during these febrile periods. In the laboratory investigations, the hemogram showed WBC: 5000 mm³, HGB: 12.7 g/dL and PLT: 184000/mm³. The biochemical parameters were as follows; CRP: 1.89 mg/dL (upper limit: 0.08 mg/dL), AST: 306 U/L, ALT: 368 U/L, ALP: 355 U/L, GGT: 116 U/L, LDH: 887 U/L, Total Bilirubin: 0.4 mg/dl, creatinine: 0.78 mg/dl, albumin: 3.8 g/dl. Of the coagulation tests, INR was 1.21, prothrombin time was 13.7 s. The viral serology of the patient whose complete urine analysis revealed no pathological finding was as follows; HBsAg: Negative, anti HbcIgM: negative, anti HAV IgM: negative, anti HCV: negative, antiHIV: negative. The craniocaudal length of the liver was found to be increased in the abdominal ultrasonography. The Rose Bengal test requested from the patient who was dealing with breeding resulted in positive. It was found to be positive at the titer of 1/1280 in the Brucella tube agglutination test. Brucella spp grew in the blood culture. Apart from the tricuspid insufficiency in a trace amount, transthoracic echocardiography revealed no pathological finding. The sacroiliac MRI requested due to the tenderness of the patient in the left sacroiliac region revealed the finding consistent with sacroiliitis.

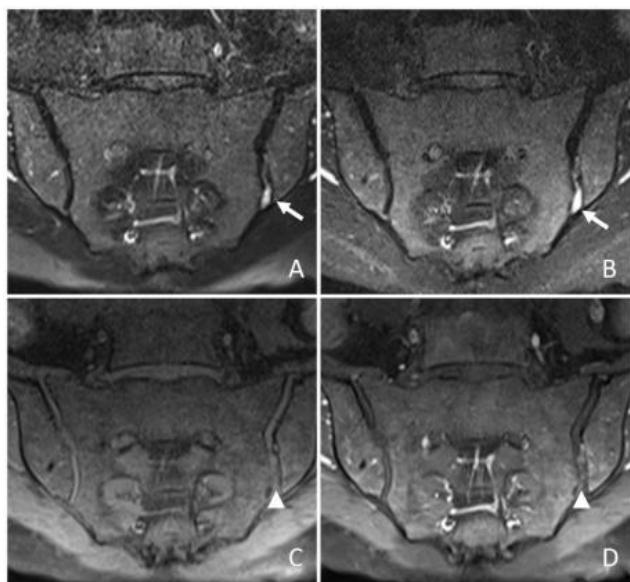


Figure 1: Coronal oblique fat-suppressed T2-weighted (A) and coronal oblique STIR; (B) MR images showed the left sacroiliac joint effusion (arrows) at the lower level; Coronal oblique fat-suppressed T1-weighted MR images obtained before (C), and after (D) the administration of paramagnetic contrast medium showed enhancement (arrowheads) at the left sacroiliac joint consistent with synovitis. There was no bone marrow oedema and joint irregularity

Doxycycline 100 mg 2 x 1, streptomycin 1 g 1 x 1 IM, rifampicin 300 mg 1 x 2 were initiated for the patient. Doxycycline, rifampicin treatment of the patient was given for six weeks while streptomycin treatment was given for three weeks. Improvements were observed in the clinical and laboratory findings of the patient's follow-up.

A 53 -year-old male patient was admitted to the outpatient clinic of internal medicine with the complaints of pain in the right upper quadrant for ten days. The patient who did not have a history of chronic illness and did not have any history of drug use did not have complaints such as fever, weight loss, nausea and vomiting. On the physical examination of the patient, he was alert, cooperated and his general condition was good. Bilateral breath sounds were normal; BP was 130/70 mmHg, S1, S2 were normal during the auscultation of heart sounds, no additional sound and murmur were heard. Tenderness was detected in the right upper quadrant of the abdomen. The liver could be palpated up to 2 cm below the rib. Traube's space was closed laterally. In the laboratory investigations of the patient, hemogram showed that WBC was 4600 mm³, HGB was 14.5 g/dL, PLT was 220000/mm³. Sedimentation was observed to be 16 mm/h. The biochemical values were as follows; AST: 187 U/L, ALT: 312 U/L, ALP: 264 U/L, GGT: 197 U/L, LDH: 549 U/L, Total Bilirubin: 0.5 mg/dL, creatinine: 1.16 mg/dL, albumin: 4.4 g/dL. INR was found to be 1.19. The viral serology of the patient whose complete urine analysis revealed no pathological finding was as follows; HBsAg: Negative, anti HbcIgM: negative, anti HAV IgM: negative, anti HCV: negative, antiHIV: negative. Although the patient had back pain, the sacroiliac MRI of the patient in whose physical examination no pathology was detected was observed to be normal. The Rose Bengal test of the patient who was found out to deal with breeding in the village he lived and that he had relatives being treated due to Brucellosis was positive. The Brucella tube agglutination test was positive at the titer of 1/320. No growth occurred in the blood culture. Doxycycline 100 mg 2 x 1, rifampicin 300 mg 1 x 2 were initiated for the treatment of the patient. An improvement was observed in the tenderness of the right upper quadrant after two weeks, and the liver transaminases were observed to be normal at the end of the patient's treatment which was completed at six weeks.

Table 1: Laboratory findings in the cases with brucellosis

	AST/ALT U/L	ALP/GGT U/L	LDH U/L	T.Bil/D.Bil mg/dL	INR/PTT(s)	WBC/NEU	HGB g/dL	PLT	CRP (mg/dL)
CASE 1 Admission	306/368	355/116	887	0.6/0.25	1.21/14	5000/2800	12.7	184000	1.89
CASE 1 Treatment Second week	79/119	267/104	633	0.3/0.1	1.17/13.5	6400/3500	12.2	410000	1.16
CASE 1 End of Treatment	22/34	180/98	330	0.4/0.1	1.14/13.1	6600/3300	13.1	300000	0.27
CASE 1 Treatment protocol	Doxycycline 100 mg 2 x 1, Streptomycin 1 g 1x1 IM, Rifampicin 300 mg 1 x 2 were initiated. Doxycycline, Rifampicin treatment for six weeks, Streptomycin treatment for three weeks								
	AST/ALT U/L	ALP/GGT U/L	LDH U/L	T.Bil/D.Bil mg/dL	INR/PTT(s)	WBC/NEU	HGB g/dL	PLT	CRP (mg/dL)
CASE 2 Admission	187/312	264/197	549	0.5/0.2	1.19/13.4	6000/4300	15.3	221000	1.45
CASE 2 Treatment Second week	106/298	162/129	253	0.4/0.2	1.16/13.4	4500/2.42	14.2	213000	1.12
CASE 2 End of Treatment	27/45	109/85	300	0.4/0.2	1.09/12.5	7000/4600	16.3	204000	0.6
CASE 2 Treatment protocol	Doxycycline 100 mg 2 x 1, Rifampicin 300 mg 1 x 2 was completed in six weeks.								

Discussion

The incidence of brucellosis, a zoonotic infection considered to affect 500,000 humans annually in the world, is reported to be about 13 in a hundred thousand in our country [5] [6]. Brucellosis, which can manifest with many different clinical presentations, can relate to different scientific branches such as infectious diseases as well as internal diseases, orthopaedics, physical therapy, psychiatry, urology and gastroenterology. Mild transaminase elevation is reported during Brucellosis in 25% of the cases [3]. We observed that liver transaminases were 5-8 times higher than the normal upper limit in two cases that we presented. In a study conducted by Cervantes F. et al. in which liver involvement of brucellosis was assessed in 40 patients, the mean serum AST and ALT levels were 1.5 times higher than the normal upper limit (NUL), and the mean alkaline phosphatase (ALP) was found to be 158U /L [4]. In a study conducted by Gursoy et al. in which they examined 140 patients, mild transaminase elevation was detected in 27.9% of the patients whereas transaminase elevation was detected in 25% of 60 patients with brucellosis in a recent study by Isilak Demir M. et al., [7] [8]. Although mild transaminase elevation is frequently encountered during brucellosis, we obtain our data on moderate-high levels of transaminase elevations rather from the articles published as case reports. Denk A. et al. found that AST was 771 U/L, ALT was 471 U/L, and total bilirubin level was 2.61 mg/dL in a brucellosis case with acute hepatitis and bicytopenia [9]. The bilirubin levels in both of our cases were normal while hepatic transaminases were elevated at acute hepatitis levels and also, lactate dehydrogenase (LDH) levels were observed to be elevated 7-8 times higher than NUL in both of our cases, indicating that this may be primarily associated with increased cell destruction by Brucellosis, which is an intracellular bacteria. Although ALP and LDH levels were 4 to 8 times higher than NUL in both cases, both enzyme levels were higher in our case with sacroiliitis. The treatment of our patient with sacroiliitis and growth in blood culture was arranged as doxycycline 100 mg 2 x 1, rifampicin 300 mg 1 x 2 and streptomycin 1g 1 x 1. The treatment of our second case was completed as

doxycycline 100 mg 2 x 1, rifampicin 300 mg 1 x 2 for six weeks. No drug-related hepatotoxicity occurred during the treatment of both cases, clinical and laboratory cure was achieved in both patients.

In conclusion, brucellosis which may manifest as a clinical picture regarding numerous medical branches should be considered in case of acute hepatitis, especially in endemic regions, along with viral hepatitis.

References

1. Avila-Calderón ED, Lopez-Merino A, Sriranganathan N, Boyle SM, Contreras-Rodríguez A. A history of the development of Brucella vaccines. *BioMed research international*. 2013;2013.
2. Tumwine G, Matovu E, Kabasa JD, Owiny DO, Majalija S. Human brucellosis: seroprevalence and associated risk factors in agro-pastoral communities of Kiboga District, Central Uganda. *BMC public health*. 2015; 15(1):900. <https://doi.org/10.1186/s12889-015-2242-z> PMID:26374402 PMCID:PMC4572625
3. Pappas G, Akritidis N, Bosilkovski M, Tsianos E. the b. melitensis genome. *N Engl J Med*. 2005; 352:2325-36. <https://doi.org/10.1056/NEJMra050570> PMID:15930423
4. Cervantes F, Carbonell J, Bruguera M, Force L, Webb S. Liver disease in brucellosis. A clinical and pathological study of 40 cases. *Postgraduate medical journal*. 1982; 58(680):346-50. <https://doi.org/10.1136/pgmj.58.680.346> PMID:7122367 PMCID:PMC2426342
5. Çiftdoğan DY, Aslan S. Unrecognized pediatric and adult family members of children with acute brucellosis. *The Brazilian Journal of Infectious Diseases*. 2017; 21(5):520-4. <https://doi.org/10.1016/j.bjid.2017.05.006> PMID:28623676
6. Erdem H, Akova M. Leading infectious diseases problems in Turkey. *Clinical Microbiology and Infection*. 2012; 18(11):1056-67. <https://doi.org/10.1111/1469-0691.12000> PMID:23043613
7. Gürsoy B, Tekin-Koruk S, Sırmatek F, Karaağaç L. Bruselloz: 140 olgunun değerlendirilmesi. *Klimik Derg*. 2008; 21(3):101-4.
8. Demir MI, Kader Ç, Çolak NY, Kocabiyik O, Erbay A, Şebnem ER. Evaluation of Brucellosis Cases. *Bozok Tıp Dergisi*. 2017; 7(3):47-51.
9. Denk A, Ozden M. A case of brucellosis presenting with acute hepatitis and bicytopenia. *Le infezioni in medicina: rivista periodica di eziologia, epidemiologia, diagnostica, clinica e terapia delle patologie infettive*. 2015; 23(2):178-81.