

# Eruptive Basaliomas: "Why we have to Perform Surgery? " Or Said Otherwise: "Catch The Metatypical! "

Ivanka Temelkova<sup>1</sup>, Hristo Mangarov<sup>1</sup>, Michael Tronnier<sup>2</sup>, Ivan Terziev<sup>3</sup>, Georgi Tchernev<sup>1,4\*</sup>

<sup>1</sup>Medical Institute of Ministry of Interior (MVR), Department of Dermatology, Venereology and Dermatologic Surgery, Sofia, Bulgaria; <sup>2</sup>Helios Klinikum GMBH, Dermatology, Venereology and Allergology Hildesheim, Germany; <sup>3</sup>Universitetska Mnogoprofilno Bolnitsa za Aktivno Lechenie Tsaritsa Yoanna, Common and Clinical Pathology, Sofia, Bulgaria; <sup>4</sup>Onkoderma, Polyclinic for Dermatology and Dermatologic Surgery General Skobelev 26, Sofia, Bulgaria

## Abstract

**Citation:** Temelkova I, Mangarov H, Tronnier M, Terziev I, Tchernev G. Eruptive Basaliomas: "Why we have to Perform Surgery?" Or Said Otherwise: "Catch The Metatypical! ". Open Access Maced J Med Sci. <https://doi.org/10.3889/oamjms.2018.203>

**Keywords:** Basal cell carcinoma; Metatypical basal cell carcinoma; Radiation; Surgery

**\*Correspondence:** Georgi Tchernev. Medical Institute of Ministry of Interior (MVR), Department of Dermatology, Venereology and Dermatologic Surgery, Sofia, Bulgaria; Onkoderma-Polyclinic for Dermatology and Dermatologic Surgery General Skobelev 26, Sofia, Bulgaria. E-mail: [georgi\\_tchernev@yahoo.de](mailto:georgi_tchernev@yahoo.de)

**Received:** 10-Jul-2018; **Revised:** 17-Jul-2018; **Accepted:** 18-Jul-2018; **Online first:** 30-Jul-2018

**Copyright:** © 2018 Ivanka Temelkova, Hristo Mangarov, Michael Tronnier, Ivan Terziev, Georgi Tchernev. This is an open-access article distributed under the terms of the Creative Commons Attribution-NonCommercial 4.0 International License (CC BY-NC 4.0).

**Funding:** This research did not receive any financial support.

**Competing Interests:** The authors have declared that no competing interests exist.

**BACKGROUND:** Keratinocyte cancers are malignant diseases with a broad incidence of spread which tends to increase during the last couple of decades. The solar radiation plays a dominant role in the occurrence of BCC, but certain genetic phenotypes appear to be risky from an etiological point of view. Metatypical basal cell carcinoma (MTBCC) is a rare variant of BCC which combines the clinical and histological characteristics of BCC and SCC. Clinically they are indistinguishable from the conventional BCC, and only the histological examination can differentiate them. The MTBCC is a histological subtype which is considered more aggressive due to its ability to produce local recurrences or distant metastases.

**CASE REPORT:** We present a 44-year old patient with multiple BCCs disseminated on the face and body. The biopsy established mixed type histology: three metatypical and four solid BCCs. The lesions were removed via elliptical excision with a field of operational security of 0.5 cm in all directions.

**CONCLUSIONS:** The eruptive (multiple) BCCs are a challenge about the choice of a therapy option. This is because clinically completely identical tumours show different histopathological characteristics, namely those with a tendency to metastasise. Having in mind one of the hypotheses of metatypical BCC emergence - the improper or inadequate radiotherapy (as a choice of therapy) could trigger the transition of a conventional tumour to a metastasising one, the surgical treatment appears to be the most secure treatment method.

## Introduction

The BCC is the most common malignant skin disease [1]. The solar radiation, skin phototype 1, as well as certain genetic diseases (albinism, xeroderma pigmentosa, Bazex's syndrome and Gorlin's syndrome), are considered as main risk factors about BCC development [1][2]. From the few existing histological subtypes of BCC, the ones of particular interest are the metatypical MTBCCs which combine the clinical and histological characteristics of BCC and SCC [3]. MTBCC is regarded as the most aggressive due to its ability to cause local recurrences and distant metastases [4]. It is believed that the inappropriate/inadequate radiotherapy of non-melanoma skin tumours could lead to their transition

to a metastatic metatypical variant of BCC [5]. Due to this reason, the first choice of BCC treatment should be the surgical removal [6].

## Case report

A 44-year old man is presented; phototype 1 and many years exposure to solar radiation. Anamnestic data showed 25 years old state of the disseminated lesions on the head and body. Multiple skin lesions of different location and size were seen on examination. In the area of shoulders, face, chest and nape were observed ulcerative lesions (Figure

1a-f) while on the back were set erythema plaques covered with crusty exudate (Figure 2c).

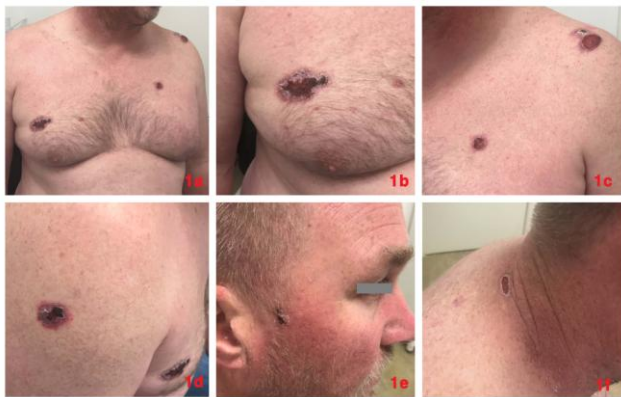

Figure 1: a-f) Multiple BCC with relative similar clinical appearance. Clinical observation during the first medical examination

Seven of the lesions were removed by elliptical excision with a field of operational security of 0.5 cm in all directions (Figure 2a-d). The histological examination showed a mixed histological picture: three multicentric BCCs with clean resection lines and four solid BCCs with free resection lines.

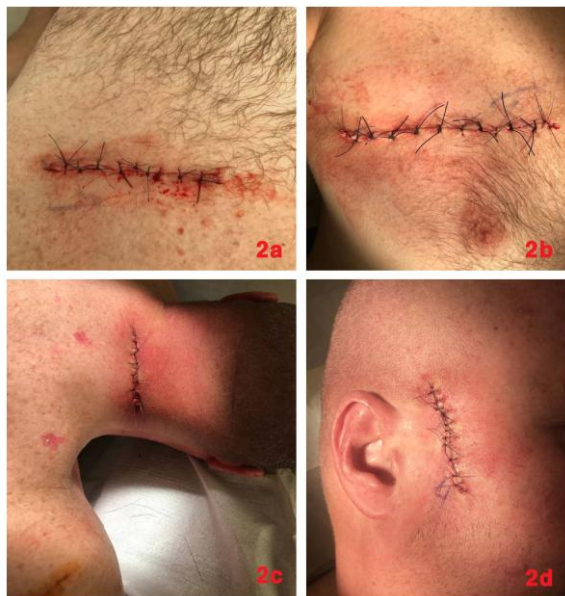

Figure 2: a-d) Clinical status postoperatively

By the histological data was set the diagnosis of metatypical BCCs for two of the surgically removed lesions (Figures 3a-c; 4a-c).

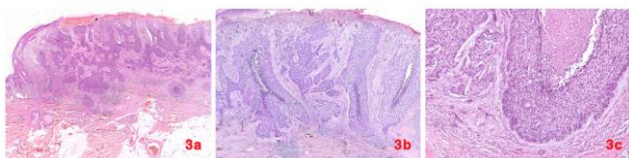


Figure 3: a-c) Metatypical basal cell carcinoma with typical histopathological features

The clinical examination did not find the presence of lymphadenopathy, the lung and heart radiography detected no focal and infiltrative changes, the ultrasound of cervical, axillary and inguinal area did not register enlarged lymph nodes, paraclinical data-with no specificities.

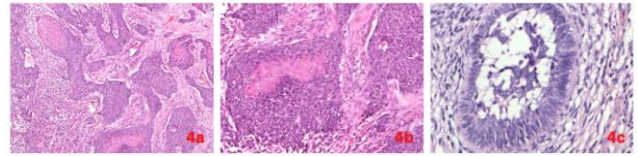


Figure 4: a-c) Metatypical basal cell carcinoma with typical histopathological features

## Discussion

The basal cell carcinoma is the neoplasia with the highest incidence rate among the population worldwide which exhibits the trend to increase in the last couple of decades with an average 10% per annum [1]. The solar radiation is considered as the main etiological factor for BCC occurrence [2]. The other risk factors for the development of basal cell carcinoma include skin phototype 1, blond or red hair, blue or green eyes, sunburnt from childhood, family history of cancer or immunosuppressive treatment [1]. Certain genetic diseases are also associated with a higher risk of basal cell carcinoma development, namely: albinism, xeroderma pigmentosa, Bazex's syndrome and Gorlin's syndrome [1]. Interesting are two phenotypes: 1) patients with clusters of BCC which have between two and five clinically manifested basal cell carcinoma, i.e. multiple presentation phenotypes and 2) patients with basal cell carcinoma on the trunk [7]. In both cases is considered that a genetic predisposition exists [7]. The patients with BCC on the trunk are interesting because it is believed that the development of basal cell carcinoma in this localisation is mediated via different mechanisms in comparison with those that are involved in affecting other parts of the body [8]. Male gender, young age and the number of sunburns are regarded as risk factors for the development of BCC on the trunk [9]. The identification of genes that are linked to the basal cell carcinoma development has great importance for better understanding of their pathogenesis [10]. According to recent research, the changed activation of the Hedgehog pathway is a key step in the carcinogenesis of BCC [10]. It has been established that mutations in the genes PTCH1, SMO as well as LATS1 and PTPN14, from the Hippo-YAP pathway are linked to BCC development [10].

The patients with BCC show differences in the tumours' location on the body, the lesions' number as well as the histological subtype [11]. Histologically the BCC is divided into nodular, superficial, morpheiform,

infiltrating, metatypic, and fibroepithelioma of Pinkus [12]. The metatypical BCC is a histological variant which combines the histological characteristics of BCC and SCC [3]. MTBCC is divided into two histological subtypes: intermediate and mixed [3]. Clinically the metatypical BCC cannot be distinguished from the other variants, and only the histological examination could differentiate them [13]. It is believed that MTBCC shows more aggressive behaviour and apart from local recurrences could also lead to distant metastases [14]. The available literature data points that the metastatic potential of MTBCC is around 7.4% [15]. BCC most commonly metastasise via lymphogenic or haematogenic pathway affecting lymph nodes, lungs or bones [16]. This requires the necessity of a more careful approach and specific treatment of the metatypical BCC.

The standard approach of treatment of basal cell carcinoma is surgical excision, curettage, curettage with electrodesiccation, Mohs micrographic surgery and radiotherapy [17]. Superficial radiation therapy is an alternative treatment of non-melanoma skin tumours, such as BCC and SCC [17]. In that case are considered tumour size, location, histological subtype and the patient's age; the often applied radiotherapy regimen is of a total dose of 4,500cGY (300cGy/fractionx15 fractions) [17]. However, according to clinical research data, few factors are risky for metatypical BCC development: 1) history of BCC for many years, 2) no response to conventional methods of treatment and 3) conducted radiotherapy in the past [5]. Because the radiation therapy is a risk factor for transitioning to the metastatic variant of BCC (MTBCC), the full surgical excision of the basal cell carcinoma is of utmost importance and should be the first choice of the treatment method of those carcinoma [5] [6]. The recommended margins of surgical security, which provide for up to 96% optimal elimination of BCC, are on average 4 mm (3 mm for the face and 5mm for the other body parts) [15]. It is necessary that patients with BCC, especially stage T3 or T4, as well as histologically confirmed MTBCC, to be monitored in the course of 10 or more years for the presence of local recurrences or distant metastases [5] [6].

In conclusion, metatypical BCC is an aggressive variant of BCC which is associated with a higher risk of local recurrences and possibility of developing distant metastases. The diagnosis of MTBCC could be determined only by histological examination. Because radiotherapy of skin tumours poses a risk of transitioning to metatypical BCC, surgical treatment of that carcinoma should be a priority.

The surgical approach is the adequate one as clinically often there are no differences, but often the histology is different. On that basis, BCC could be determined, analogically to other diseases in the dermatology, like a chameleon.

## References

1. Wong C, Strange R, Lear J. Basal cell carcinoma. *BMJ*. 2003; 327(7418):794–798. <https://doi.org/10.1136/bmj.327.7418.794> PMID:14525881
2. Gallagher R, Hill G, Bajdik C. Sunlight Exposure, Pigmentary Factors, and Risk of Nonmelanocytic Skin Cancer. *Arch Dermatol*. 1995; 131(2):157-163. <https://doi.org/10.1001/archderm.1995.01690140041006>
3. Tchernev G, Ananiev J, Cardoso J, Wollina U. Metatypical Basal Cell Carcinomas: a Successful Surgical Approach to Two Cases with Different Tumor Locations. *Maedica (Buchar)*. 2014; 9(1):79–82.
4. Martin R, Edwards M, Cawte T, Sewell C, McMasters K. Basosquamous carcinoma: analysis of prognostic factors influencing recurrence. *Cancer*. 2000; 88(6):1365-9. [https://doi.org/10.1002/\(SICI\)1097-0142\(20000315\)88:6<1365::AID-CNCR13>3.0.CO;2-Y](https://doi.org/10.1002/(SICI)1097-0142(20000315)88:6<1365::AID-CNCR13>3.0.CO;2-Y)
5. Snow S, Sahl W, Lo S, Mohs E, Warner T, Dekkinga A, Feyzi J. Metastatic basal cell carcinoma. Report of five cases. *Cancer*. 1994; 73(2):328-35. [https://doi.org/10.1002/1097-0142\(19940115\)73:2<328::AID-CNCR2820730216>3.0.CO;2-U](https://doi.org/10.1002/1097-0142(19940115)73:2<328::AID-CNCR2820730216>3.0.CO;2-U)
6. Martin R, Edwards J, Cawte G, Sewell L, McMasters M. Basosquamous carcinoma: analysis of prognostic factors influencing recurrence. *Cancer*. 2000; 88(6):1365-9. [https://doi.org/10.1002/\(SICI\)1097-0142\(20000315\)88:6<1365::AID-CNCR13>3.0.CO;2-Y](https://doi.org/10.1002/(SICI)1097-0142(20000315)88:6<1365::AID-CNCR13>3.0.CO;2-Y)
7. Ramachandran S, Fryer A, Lovatt T, Lear J, Smith A, Strange R. Susceptibility and modifier genes in cutaneous basal cell carcinomas and their associations with clinical phenotype. *J Photochem Photobiol B*. 2001; 63(1-3):1-7. [https://doi.org/10.1016/S1011-1344\(01\)00194-4](https://doi.org/10.1016/S1011-1344(01)00194-4)
8. Ramachandran S, Fryer A, Smith A, Lear J, Bowers B, Jones W, Strange R. Cutaneous basal cell carcinomas: distinct host factors are associated with the development of tumours on the trunk and the head and neck. *Cancer*. 2001; 92(2):354-8. [https://doi.org/10.1002/1097-0142\(20010715\)92:2<354::AID-CNCR1330>3.0.CO;2-F](https://doi.org/10.1002/1097-0142(20010715)92:2<354::AID-CNCR1330>3.0.CO;2-F)
9. Neale R, Davis M, Pandeya N, Whiteman D, Green A. Basal cell carcinoma on the trunk is associated with excessive sun exposure. *J Am Acad Dermatol*. 2007; 56(3):380-6. <https://doi.org/10.1016/j.jaad.2006.08.039>
10. Pellegrini C, Maturo M, Nardo L, Ciciarelli V, García-Rodrigo C, Fargnoli M. Understanding the Molecular Genetics of Basal Cell Carcinoma. *Int J Mol Sci*. 2017; 18(11):2485. <https://doi.org/10.3390/ijms18112485>
11. Madan V, Hoban P, Strange R, Fryer A, Lear J. Genetics and risk factors for basal cell carcinoma. *Br J Dermatol*. 2006; 154(Suppl 1):5-7. <https://doi.org/10.1111/j.1365-2133.2006.07229.x>
12. Nakayama M, Tabuchi K, Nakamura Y, Hara A. Basal cell carcinoma of the head and neck. *J Skin Cancer*. 2011; 2011:496910. <https://doi.org/10.1155/2011/496910>
13. Tarallo M, Cigna E, Frati R, Delfino S, Innocenzi D, Fama U, Corbianco A, Scuderi N. Metatypical basal cell carcinoma: a clinical review. *J Exp Clin Cancer Res*. 2008; 27:65. <https://doi.org/10.1186/1756-9966-27-65> PMID:18992138
14. 30. Martin R, Edwards M, Cawte T, Sewell C, McMasters K. Basosquamous carcinoma: analysis of prognostic factors influencing recurrence. *Cancer*. 2000; 88(6):1365-9. [https://doi.org/10.1002/\(SICI\)1097-0142\(20000315\)88:6<1365::AID-CNCR13>3.0.CO;2-Y](https://doi.org/10.1002/(SICI)1097-0142(20000315)88:6<1365::AID-CNCR13>3.0.CO;2-Y)
15. Tarallo M, Cigna E, Frati R, Delfino S, Innocenzi D, Fama U, Corbianco A, Scuderi N. Metatypical basal cell carcinoma: a clinical review. *Journal of Experimental & Clinical Cancer Research*. 2008; 27(1):65. <https://doi.org/10.1186/1756-9966-27-65>
16. Domarus H, Stevens J. Metastatic basal cell carcinoma. Report of five cases and review of 170 cases in the literature. *J Am Acad Dermatol*. 1984; 10(6):1043-60. [https://doi.org/10.1016/S0190-9622\(84\)80334-5](https://doi.org/10.1016/S0190-9622(84)80334-5)
17. McGregor S, Minni J, Herold D. Superficial Radiation Therapy for the Treatment of Nonmelanoma Skin Cancers. *J Clin Aesthet Dermatol*. 2015; 8(12):12–14. PMID:PMC4689506