

A Case of the Co-Existence of Subcorneal Pustular Dermatitis and Pyoderma Gangrenosum and a Review of the Literature

Maria Ferrillo¹, Alessia Villani^{1*}, Gabriella Fabbrocini¹, Massimo Mascolo², Matteo Megna¹, Claudia Costa¹, Maddalena Napolitano³

¹Section of Dermatology, Department of Clinical Medicine and Surgery, Dermatology Unit, University of Naples Federico II, Napoli, Italy; ²Department of Advanced Biomedical Sciences, Pathology Section University of Naples Federico II, Napoli, Italy; ³Department of Medicine and Health Science "Vincenzo Tiberio", University of Molise, Campobasso, Italy

Abstract

Citation: Ferrillo M, Villani A, Fabbrocini G, Mascolo M, Megna M, Costa C, Napolitano M. A Case of the Co-Existence of Subcorneal Pustular Dermatitis and Pyoderma Gangrenosum and a Review of the Literature. Open Access Maced J Med Sci. <https://doi.org/10.3889/oamjms.2018.214>

Keywords: Subcorneal pustular dermatosis; Pyoderma gangrenosum; Sneddon-Wilkinson disease; neutrophilic dermatoses

***Correspondence:** Alessia Villani, Section of Dermatology, Department of Clinical Medicine and Surgery, Dermatology Unit, University of Naples Federico II, Napoli, Italy. E-mail: ali.vil@hotmail.it

Received: 09-Apr-2018; **Revised:** 14-Jun-2018; **Accepted:** 15-Jun-2018; **Online first:** 08-Jul-2018

Copyright: © 2018 Maria Ferrillo, Alessia Villani, Gabriella Fabbrocini, Massimo Mascolo, Matteo Megna, Claudia Costa, Maddalena Napolitano. This is an open-access article distributed under the terms of the Creative Commons Attribution-NonCommercial 4.0 International License (CC BY-NC 4.0)

Funding: This research did not receive any financial support

Competing Interests: The authors have declared that no competing interests exist

BACKGROUND: Subcorneal pustular dermatosis, also known as Sneddon-Wilkinson disease, can be classified as one of the neutrophilic dermatoses together with pyoderma gangrenosum. The development of both SPD and PG in the same patient has rarely been reported and may be a strong indicator of IgA dysglobulinemia

CASE REPORT: We report the case of a 34-year-old woman with a 2-year history of relapsing pustular eruptions mainly affecting the abdomen, gluteus region, elbows, and the extremities. Four years after the onset of subcorneal pustular dermatosis (SPD), she developed pyoderma gangrenosum (PG) on her right hand. In literature, the coexistence of SPD and PG in the same patient has already been described. This co-occurrence might indicate a certain predisposition for immune dysregulation.

CONCLUSION: Although the two NDs are often associated with systemic diseases, these patients should be followed up for any malignancy because of the strong association between these disorders.

Introduction

Subcorneal pustular dermatosis (SPD), also known as Sneddon-Wilkinson disease, can be classified as one of the neutrophilic dermatoses (NDs) together with pyoderma gangrenosum (PG). The development of both SPD and PG in the same patient has rarely been reported and may be a strong indicator of IgA dysglobulinemia [1].

We describe the case of a patient exhibiting SPD lesions associated after two years' duration with typical PG.

Case report

A 34-year-old woman was admitted to our hospital in 2015 with 2 years-history of relapsing pustular eruptions mainly affecting the abdomen, gluteus region, elbows, and the extremities (Figure 1). Clinical examination showed multiple small painful flaccid pustules varying in size from 0.5-2 cm that tended to coalesce to form an annular or circinate pattern and superficial crusts on the normal or mildly erythematous skin. A skin biopsy specimen showed subcorneal neutrophilic infiltrate with occasional eosinophils and absence of spongiosis or acantholysis. In the dermis, there was a dense perivascular infiltrate of neutrophils and occasional

eosinophils (Figure 2). Direct immunofluorescence was negative.

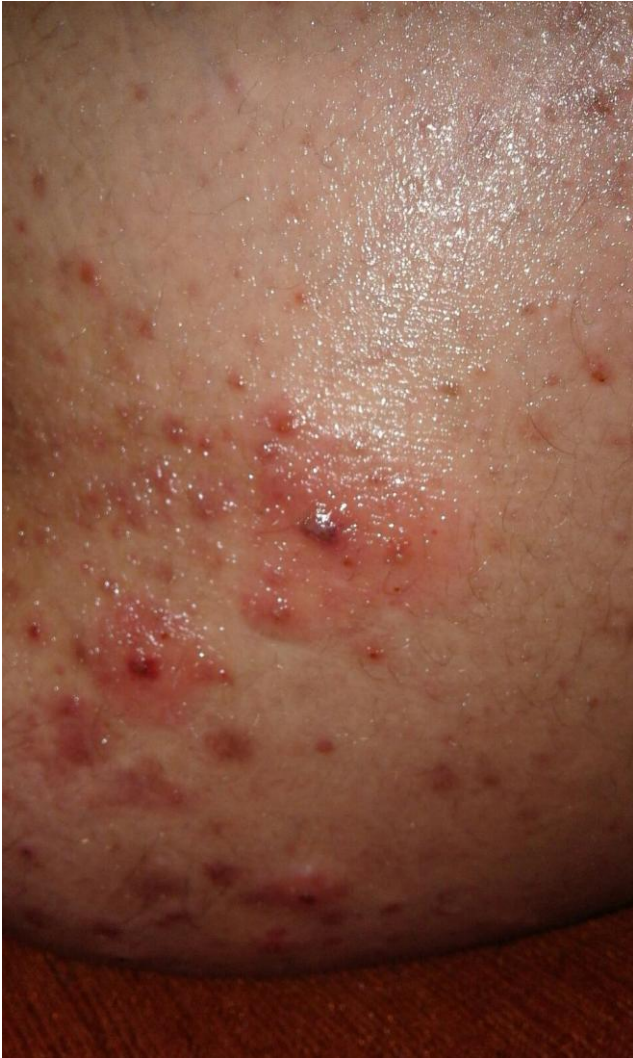

Figure 1: Subcorneal pustular dermatosis. Small flaccid pustules varying in size from 0.5-2 cm that tended to coalesce to form annular or circinate pattern

These findings were consistent with SPD diagnosis. Dapsone was introduced at a dose of 100 mg/daily resulting in gradual improvement of SPD with few residual scarring. She remained on dapsone for 20 months with almost complete remission of the neutrophilic disease.

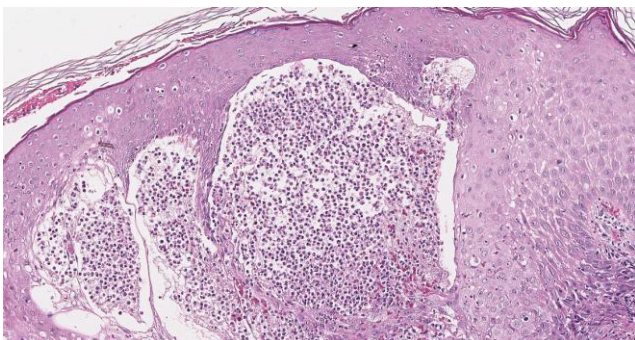


Figure 2: SPD histological examination: subcorneal pustule below the stratum corneum containing mainly neutrophils

In 2017, the patient developed on the right hand an area of painful, rapidly enlarging, ulceration (Figure 3). Clinical examination showed a 2.5 cm diameter-ulceration with violaceous borders and surrounding erythema. Similar lesions were also present on the lower extremities.

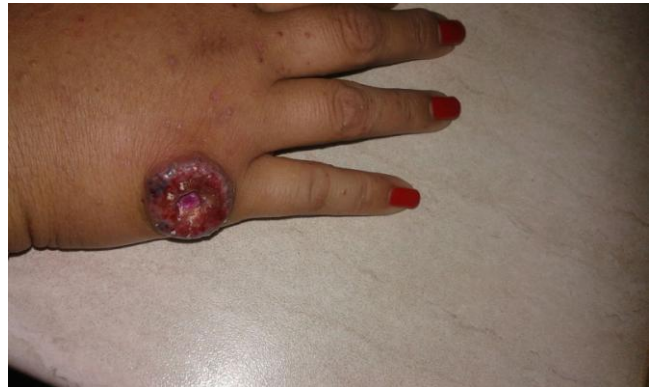

Figure 3: Pyoderma gangrenosum. An area of ulceration with violaceous borders and surrounding erythema

A skin biopsy found a mixed inflammatory infiltrate of neutrophils and lymphocytes, extending into the panniculus (Figure 4).

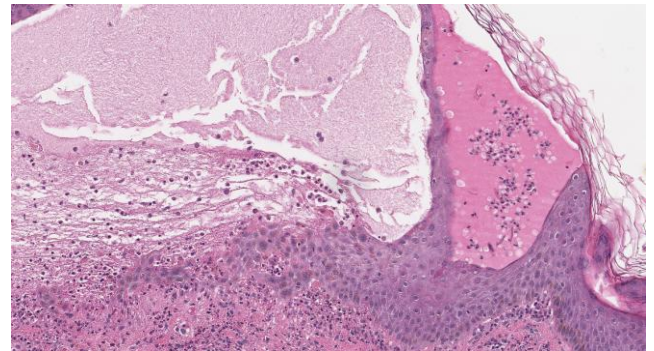


Figure 4: PG histological examination: an intensive mixed inflammatory infiltrate including mainly neutrophils associated with vessel destruction and necrosis of the epidermum

Direct immunofluorescence was negative. Clinical and histopathologic features were compatible with PG diagnosis, according to Delphi Consensus criterion [2]. Laboratory investigations showed an increased white cell count ($11,000/\text{mm}^3$) with a normal differential. Erythrocyte sedimentation rate (ESR) and C-reactive protein (CRP) were elevated (ESR: 20 mm; CRP: 0.72 mg/dL). The blood chemistry, liver function and renal function tests were within the normal limit. Abdominal and pelvic ultrasound and computed tomography were normal. A gastroenterological visit excluded the presence of inflammatory bowel disease. The patient did not respond to topical and oral corticosteroids (prednisone 50 mg/daily for a month); cyclosporine was introduced at a dosage of 150 mg/daily (2 mg/kg) in association with tacrolimus 0.1% ointment, thus resulting in gradual improvement of PG, while SPD remained in remission [3].

Discussion

NDs are a group of heterogeneous skin diseases, with common features and a common histopathologic characterised by polymorphonuclear leukocyte infiltrates at various levels within the epidermis, dermis, or panniculus [4] (Table 1).

Table 1: NDs classification

| NEUTROPHILIC DERMATOSIS [4] | | |
|---|--|---|
| Superficial (epidermal) Subcorneal pustular dermatosis | En plaque (dermal) Sweet's syndrome | Deep (dermal and hypoderma) Pyoderma gangrenosum |
| IgA pemphigus | Neutrophilic eczrine hydratenitis | Neutrophilic panniculitis |
| Bullous neutrophilic dermatoses | Erythema elavatum diutinum | Aseptic abscesses |
| Other pustuloses | Neutrophilic rheumatoid dermatitis | - |
| - | Granulomatous pyoderma gangrenosum | - |

SPD is a rare chronic and relapsing skin disease, characterised by symmetrical sterile pustular eruption typically involving the flexural sites of the trunk and proximal limbs [1]. Although it is typically seen in women over the age of 40 years, there have been a few cases found in children [4] [5]. The etiopathogenesis of SPD remains unknown [6]. A trigger for aberrant neutrophil chemotaxis in SPD has not been identified. Faulty immune mechanisms and genetic susceptibility have been proposed, but no widely accepted hypothesis has been substantiated [3]. PG is a neutrophilic, non-infective skin disorder characterised by pustules or nodules, in which sterile destructive inflammatory process leads to necrotic cutaneous ulceration with violaceous borders and central necrosis. Lesions are mainly localised on the lower legs, especially on pretibial area [7] [8].

In our patient, the SPD preceded the PG onset by 2 years. In literature, the coexistence of SPD and PG in the same patient has been described previously in 12 patients (Table 2) [1]. This co-occurrence might indicate a certain predisposition for immune dysregulation. Although the neutrophilic accumulation appears to be the hallmark of neutrophilic disorders, the exact pathophysiology is still unknown. Probably, it is implicated the production from T cells activated by polymorphonuclear cells of several chemotactic factors, including the pro-inflammatory cytokines: tumour necrosis factor (TNF)- α , interleukin (IL)-8 and complement fragment C5a [4] [9]. Indeed, a complete remission of clinical manifestations, with the off-label use of TNF blocking agents in 29-years old man with SPD, refractory to first-line therapy, has previously been described [10].

The two NDs are often associated with systemic diseases, including inflammatory bowel disease, rheumatoid arthritis, paraproteinemia or haematological malignancy, such as monoclonal

gammopathies, lymphomas and multiple myeloma [11].

Table 2: Articles reporting the coexistence of the two neutrophilic diseases published in the literature

| Authors | Sex | Age | Associated disease | Therapy | Outcome |
|--|-----|-----|--|---|-----------|
| Wolff K. 1971 [12] | - | - | IgA gammopathy | - | - |
| Marsden JR, et al. 1986 [15] | - | - | IgA gammopathy | - | - |
| Venning VA, et al. 1986 [16] | F | 59 | IgA gammopathy | dapsone | remission |
| Freire Murgueyio P, et al. 1989 [17] | - | - | - | - | - |
| Kohl PK, et al. 1991 [18] | F | 60 | IgA gammopathy | - | - |
| Scerri L. 1994 [14] | F | 89 | - | CCS, dapsone, minocycline | remission |
| Cartier H, et al. 1995 [19] | F | 54 | IgA gammopathy | CCS, dapsone | remission |
| Stone MS, et al. 1996 [20] | F | 72 | Multiple myelomas | CCS, dapsone | Remission |
| T.A.Chave, et al. 2001 [21] | M | 82 | IgA paraproteinaemia and IgG antiepitheial antibodies. | CCS | - |
| Puechguiral-Renaud I, et al. 2006 [22] | M | 67 | IgA and IgG gammopathy | CCS | - |
| Ahmad K, et al. 2009 [1] | F | 57 | IgA and IgG gammopathy, multiple myeloma | CCS, dapsone, tacrolimus, acitretin, colchicine, clofazimine, nbUVB cyclosporin, cyclophosphamide | Remission |
| Audemard A, et al. 2012 [23] | M | 82 | Spleen abscess | CCS | Remission |

It is of interest that this diseases combination has been reported in the presence of an IgA monoclonal gammopathy [12]. However, in 2006 a case of a 67-year-old man, affected by both PG and SPD simultaneously, who developed a biclonal benign IgA and IgG kappa gammopathy have been reported [13]. Furthermore, *Ahmad et al.* described the case of a 57-year-old woman, with a 5-year history of PG before she developed SPD, associated with biclonal IgA and IgG gammopathy, that 12 years later, developed myeloma [1]. In our patient, no evidence of myeloma or myeloproliferative disorders has been found. Although PG and SPD may occur without the association of an underlying malignancy as in our case, these patients should be followed up for any malignancy because of the strong association between these disorders [14].

References

- Ahmad K, Ramsay B. Pyoderma gangrenosum associated with subcorneal pustular dermatosis and IgA myeloma. *Clin Exp Dermatol.* 2009; 34(1):46-8. <https://doi.org/10.1111/j.1365-2230.2008.02886.x> PMID:18627386
- Maverakis E, Ma C, Shinkai K, Fiorentino D, Callen JP, Wollina U, Marzano AV, Wallach D, Kim K, Schadt C, Ormerod A, Fung MA, Steel A, Patel F, Qin R, Craig F, Williams HC, Powell F, Merleev A, Cheng MY. Diagnostic Criteria of Ulcerative Pyoderma Gangrenosum: A Delphi Consensus of International Experts. *JAMA Dermatol.* 2018; 154(4):461-466.

- <https://doi.org/10.1001/jamadermatol.2017.5980> PMID:29450466
3. Napolitano M, Megna M, Patri A, Monfrecola G, Balato N. Pyoderma gangrenosum successfully treated with topical tacrolimus. *G Ital Dermatol Venereol*. 2018; 2018.
 4. Watts PJ, Khachemoune A. Subcorneal Pustular Dermatitis: A Review of 30 Years of Progress. *Am J Clin Dermatol*. 2016; 17(6):653-671. <https://doi.org/10.1007/s40257-016-0202-8> PMID:27349653
 5. Scalvenzi M, Palmisano F, Annunziata MC, Mezza E, Cozzolino I, Costa C. Subcorneal pustular dermatosis in childhood: a case report and review of the literature. *Case Rep Dermatol Med*. 2013; 2013:424797. <https://doi.org/10.1155/2013/424797>
 6. Cheng S, Edmonds E, Ben-Gashir M, Yu RC. Subcorneal pustular dermatosis: 50 years on. *Clin Exp Dermatol*. 2008; 33(3):229-33. <https://doi.org/10.1111/j.1365-2230.2008.02706.x> PMID:18355359
 7. Wollina U. Clinical management of pyoderma gangrenosum. *Am J Clin Dermatol*. 2002; 3(3):149-58. <https://doi.org/10.2165/00128071-200203030-00002> PMID:11978136
 8. Powell FC, Schroeter AL, Su WPD, Perry HO. Pyoderma gangrenosum: a review of 86 patients. *QJM*. 1985; 55:173– 86. PMID:3889978
 9. Grob JJ, Mege JL, Capo C, Jancovicci E, Fournier JR, Bongrand P, Bonerandi JJ: Role of tumor necrosis factor-alpha in Sneddon-Wilkinson subcorneal pustular dermatosis. A model of neutrophil priming in vivo. *J Am Acad Dermatol*. 1991; 25:944–947. [https://doi.org/10.1016/0190-9622\(91\)70290-I](https://doi.org/10.1016/0190-9622(91)70290-I)
 10. Kretschmer L, Maul JT, Hofer T, Navarini AA. Interruption of Sneddon-Wilkinson Subcorneal Pustulation with Infliximab. *Case Rep Dermatol*. 2017; 9(1):140-144. <https://doi.org/10.1159/000468917> PMID:28559813 PMCid:PMC5437431
 11. Cohen PR. Neutrophilic dermatoses: a review of current treatment options. *Am J Clin Dermatol*. 2009; 10(5):301-12. <https://doi.org/10.2165/11310730-000000000-00000> PMID:19658442
 12. Wolff K. Subcorneal pustulose Dermatose (Sneddon-Wilkinson): Pyoderma gangrenosum mil IgA-paraproteinämie. *Dermatol Monatsschr* 1971; 157:S42.
 13. Puechguiral-Renaud I, Carpentier O, Piette F, Delaporte E. Subcorneal pustulosis and Pyoderma gangrenosum associated with a biclonal gammopathy. *Eur J Dermatol*. 2006; 16(6):687-90. PMID:17229613
 14. Scerri L, Zaki I, Allen BR. Pyoderma gangrenosum and subcorneal pustular dermatosis, without monoclonal gammopathy. *Br J Dermatol*. 1994; 130(3):398-9. <https://doi.org/10.1111/j.1365-2133.1994.tb02941.x> PMID:8148286
 15. Marsden JR, Miliard LG. Pyoderma gangrenosum. subcorneal pustular dermatosis and IgA paraproteinaemia. *Br J Dermatol*. 1986; 114: 125-9. <https://doi.org/10.1111/j.1365-2133.1986.tb02787.x> PMID:3510651
 16. Venning VA, Ryan TJ. Subcorneal pustular dermatosis followed by pyoderma gangrenosum. *Br J Dermatol*. 1986; 11S:117-18. <https://doi.org/10.1111/j.1365-2133.1986.tb06229.x>
 17. Freire Murgueyio P, Allegue F, Martin Gonzalez M et al. Gangrenous pyoderma associated with subcorneal pustular dermatosis (Sneddon-Wilkinson disease). *Med Cutan Ibero Lat Am*. 1989; 17(2):105-9. PMID:2666795
 18. Kohl PK, Hartschuh W, Tilgen W, Frosch PJ. Pyoderma gangrenosum followed by subcorneal pustular dermatosis in a patient with IgA paraproteinemia. *J Am Acad Dermatol*. 1991; 24(2 Pt 2):325-8. [https://doi.org/10.1016/0190-9622\(91\)70043-2](https://doi.org/10.1016/0190-9622(91)70043-2)
 19. Cartier H, Plantin P, Leroy JP, Larzul JJ. Pyoderma gangrenosum, subcorneal IgA pustulosis and recurrent neutrophilic pleural and pulmonary diseases in a patient with IgA gammopathy. *Ann Dermatol Venereol*. 1995; 122(3):97-101. PMID:7486731
 20. Stone MS, Lyckholm LJ. Pyoderma gangrenosum and subcorneal pustular dermatosis: clues to underlying immunoglobulin A myeloma. *Am J Med*. 1996; 100:663–4. [https://doi.org/10.1016/S0002-9343\(95\)00007-0](https://doi.org/10.1016/S0002-9343(95)00007-0)
 21. Chave TA, Hutchinson PE. Pyoderma gangrenosum, subcorneal pustular dermatosis, IgA paraproteinaemia and IgG antiepithelial antibodies. *Br J Dermatol*. 2001; 145(5):852-4. <https://doi.org/10.1046/j.1365-2133.2001.04450.x>
 22. Puechguiral-Renaud I, Carpentier O, Piette F et al. Subcorneal pustulosis and pyoderma gangrenosum associated with a biclonal gammopathy. *Eur J Dermatol*. 2006; 16:687–90. PMID:17229613
 23. Audemard A, Verger H, Gendrot A, Jeanjean C, Auzary C, Geffray L. Pyoderma gangrenosum, subcorneal pustular dermatosis and aseptic spleen abscess: "a neutrophilic disease". *Rev Med Interne*. 2012; 33(5):e28-30. <https://doi.org/10.1016/j.revmed.2011.04.006> PMID:21821322