

# Proton Pump Inhibitors Diminish Barrett's Esophagus Length: Our Experience

Zaim Gashi<sup>1\*</sup>, Elton Bahtiri<sup>2</sup>, Arjeta Gashi<sup>2</sup>, Fadil Sherifi<sup>1</sup>

<sup>1</sup>University Clinical Center, Clinic of Gastroenterology, Prishtina, Kosovo; <sup>2</sup>University Clinical Center, Institute of Pharmacology, Prishtina, Kosovo

## Abstract

**Citation:** Gashi Z, Bahtiri E, Gashi A, Sherifi F. Proton Pump Inhibitors Diminish Barrett's Esophagus Length: Our Experience. Open Access Maced J Med Sci. 2018 Jun 20; 6(6):1041-1045. <https://doi.org/10.3889/oamjms.2018.232>

**Keywords:** Proton pump inhibitor; Endoscopy; Barrett's oesophagus; Squamous islands

**\*Correspondence:** Zaim Gashi, University Clinical Center, Clinic of Gastroenterology, Prishtina, Kosovo. E-mail: [drzaimgashi@hotmail.com](mailto:drzaimgashi@hotmail.com)

**Received:** 21-Mar-2018; **Revised:** 04-May-2018; **Accepted:** 19-May-2018; **Online first:** 08-Jun-2018

**Copyright:** © 2018 Zaim Gashi, Elton Bahtiri, Arjeta Gashi, Fadil Sherifi. This is an open-access article distributed under the terms of the Creative Commons Attribution-NonCommercial 4.0 International License (CC BY-NC 4.0)

**Funding:** This research did not receive any financial support

**Competing Interests:** The authors have declared that no competing interests exist

**AIM:** Our main objectives were to evaluate the influence of two-year proton pump inhibitors (PPI) therapy in patients with Barrett's oesophagus on its length, in both types, short and long segment.

**METHODS:** In this single-centre, prospective interventional controlled study were analysed data collected prospectively over two years from patients with Barrett's oesophagus diagnosed by endoscopy. Patients who received continuous proton pump inhibitors (PPI) for 2 years were included. At each patient visit symptoms were recorded, and at each endoscopy, the length of Barrett's oesophagus (BE) was measured. Biopsies were taken along the length of the oesophagus at intervals of 1 cm. In total, 50 patients with Barrett's oesophagus were included in the study: 10 of whom had long-segment Barrett's oesophagus, and 40 patients had short-segment Barrett's oesophagus. The mean number of endoscopies performed was 3 per patient.

**RESULTS:** The length of Barrett's esophagus (BE) was influenced by PPI therapy: Circumferential extension in BE patients short-segment Barrett's esophagus (SSBE) (before treatment was 1.5 cm and after treatment was 0.8 cm Maximum proximal extension in SSBE group before treatment was 2.3 cm (SD ± 1.1 cm), and 1.1 cm (SD ± 0.9 cm), respectively. Squamous islands were detected in 25% of patients examined after 2 years on PPIs.

**CONCLUSIONS:** PPIs achieve a reduction to the length of Barrett's oesophagus, in both types, and the development of squamous islands is commonly associated with their use.

## Introduction

In the USA, Barrett's oesophagus (BE) is defined as the displacement of the squamocolumnar junction proximal to the gastro-oesophageal junction with histological evidence of specialised intestinal metaplasia on biopsy specimens [1]. The British Society of Gastroenterology (BSG) has a different definition of Barrett's oesophagus. The BSG defines Barrett's oesophagus as "an endoscopically apparent area above the esophagogastric junction that is suggestive of Barrett's oesophagus (salmon-coloured mucosa) which is supported by the finding of the columnar lined oesophagus on histology". According to this definition, areas of intestinal metaplasia, although often present, are not a requirement for the diagnosis of Barrett's oesophagus [2]. This different definition has arisen for several reasons: results from multiple studies have demonstrated that specialized

intestinal metaplasia may be difficult to detect unless thorough biopsies are taken; there seem to be cases of cancers arising in patients who have noninternalized epithelium; and molecular abnormalities are present even in nondysplastic Barrett's mucosa [3] [4] [5].

The need to standardise the classification of Barrett's oesophagus leads to the development of a system known as the Prague classification of Barrett's oesophagus. The Prague C (circumferential) and M (maximal extent) criteria were developed and validated by Sharma *et al.*, [6] In this classification, both the maximal length (M) (including tongues) of Barrett's esophagus, as well as the length of the circumferential Barrett's segment (C) are measured during endoscopy. These numbers can then be used to track the length of the Barrett segment over time. This system has a high degree of overall validity for the endoscopic assessment of the visualised Barrett oesophagus segment when it is > 1 cm in length. If

the segment is < 1 cm in length, this classification system is less valid in its ability to define the length of the Barrett segment [6]. Gastroenterologists, at least in the USA, agree that endoscopic evidence (salmon-coloured mucosa proximal to the gastro-oesophageal junction) and histologic evidence of specialised intestinal metaplasia (that is, the presence of goblet cells) are required to make the diagnosis of Barrett's oesophagus [1].

The goals of gastroesophageal reflux disease treatment in patients with Barrett's oesophagus include control of symptoms, healing and maintenance of healed esophagitis and prevention of progression of Barrett's oesophagus toward cancer. The first two are fairly easy achievable using either medical therapy with proton pump inhibitors (PPI) or with antireflux surgery. We have much less data on prevention of progression of this disorder, but it would certainly appear that if treatment resulted in regression of the length of Barrett's oesophagus, it might also decrease the risk for progression [7].

This study aimed to show whether proton pump inhibitors have an impact in the reduction of length of Barrett's oesophagus, in both endoscopic types, short segment and long segment Barrett's oesophagus.

## Material and Methods

This study was performed in University Clinical Center of Kosovo, Clinic of Gastroenterohepatology and Institute of Pathology in Prishtina and Skopje. The time of the investigation was June 2009-December 2011.

In this prospective study, 50 patients with BE were included. All patients were interviewed for their age, sex, reflux symptoms chronicity, medications used, weight, smoking and endoscopic determination of hiatal hernia presence. All endoscopic procedures were performed by 1 of 2 experienced endoscopists (having performed > 10.000 gastroscopies each). Upper endoscopy was performed by using the Videogastroscope GIF type Q 145 series.

Endoscopic respondents were investigated by the following dynamics:

In the first endoscopy, endoscopic BE diagnosis was obtained in the terrain of Gastroesophageal Reflux Disease (GERD) changes, the presence of a hiatus hernia was diagnosed, as well as macroscopic classification of Barrett's esophagus as short (SSBE < 3 cm) and long (LSBE > 3 cm) segment of Barrett's esophagus. Patients for two years were treated with PPI with maximal doses (lansoprazole 2 x 30 mg or pantoprazole 2 x 40 mg, 30 min before meals).

Two months following the first endoscopy, repeat endoscopy with multiple biopsies from the BE zone, 10-15 biopsies, according to "settle-protocol". Patients were continued to be treated with PPI for two years. If necessary, in subjects with more pronounced complaints of vomiting and reflux, antiemetic drugs were administered for up to two weeks.

After 2 years of follow-up, period endoscopy was performed on the respondents to determine eventual changes in Barrett's length and to perform (C & M) multiple biopsies for microscopic analysis. Endoscopic assessment is carried out by the so-called Prague C and M criteria, representing endoscopic grading of changes in Barrett's oesophagus. This system includes circumferential (C) and the maximum proximal extension (M) of the columnar epithelium over the gastro-oesophageal junction, which in this case is as defined top (proximal) border of the gastric folds present. The distance to determine changes in length measured from the anterior dental arch expressed in centimetres (cm). Short (SSBE) and long (LSBE) segment of Barrett's oesophagus was determined by the length of the segment containing specialised intestinal epithelium (< 3 cm and > 3 cm, respectively). At each endoscopy, the location of the GEJ is defined as a place that the highest gastric fold in the tubular oesophagus meets. The length of Barrett's oesophagus was measured from the site of the highest point of squamo - cylindric transition. A hiatal hernia was diagnosed when the crural impression was separated from the top of the gastric rugal folds by 2 or more centimetres. The size of a hiatal hernia was recorded in centimetres.

Gastro-oesophageal junction (GEJ) is an imaginary line where the oesophagus ends, and the stomach begins. The highest point line with gastric folds was proposed as a marker for GEJ. The difference between the endoscopically located squamocolumnar junction and the endoscopically estimated gastro-oesophageal junction determined the length of Barrett's oesophagus. The positions of endoscopic markings were determined in centimetres from the incisors in documenting the level of esophagitis and squamocolumnar connection, along with the cylindrical extension of the lower oesophagus and the upper limit of gastric folds.

Histological processing was performed in the Institute of Pathology in Prishtina and Skopje. Biopsies were taken from the mucosa changes at intervals of 2cm, and the samples separately from each level were processed in formalin and paraffin. Afterwards, a series of sections were cut and marked with haematoxylin-eosin, alcian- blue and Giemsa-colour. The same experienced expert pathologist reviewed all biopsy specimens. The pathologist was not aware of the treatment applied. The recognition of intestinal metaplasia by biopsy, especially goblet cells, **can be** facilitated with the use of alcian blue stain of pH 2.5.

Calculation of sample size was made based on the data for patients with BE in the GERD group patients, which was 10% in most of the studies. However, for higher security, the sample size was calculated as 15%.

The results were analysed with modern statistical methods. Data processing was performed with Instant 3 statistical package. Statistical parameters were calculated from the index structure, mean, standard deviation, minimum and maximum value. The test data used parametric t-test (for variables with normal distribution, values were shown as a mean and standard deviation, and the differences between them were tested by the arithmetic mean of the differences). The difference was considered significant if  $P < 0.05$ .

## Results

The study included 50 patients with BE. The average age of patients in Group BE was 52.4 years (SD ± 10.8 yrs). In the group of patients with BE, most common age group was 50-59 years. In the group with BE, 78.0% were men.

Average body height of respondents in BE group was 174.8 cm (SD ± 8.2 cm), although 60% of BE patients were smokers. Patients in BE group smoked more cigarettes, in 60% of patients. Patients in BE group had higher Body mass index (29.5).

The duration of symptoms in BE group was 7.8 years. (SD ± 2.16 yrs). In the BE group, 40 (80%) patients had hiatal hernia, of which 29 or 74.4.0% were < 3 cm (SSBE), and 11 or 100% were > 3 cm (LSBE).

Our results for the presence of a hiatal hernia by endoscopic type of BE are presented in the following table. Although without significant difference, the presence of a hiatal hernia was greater in the subgroup with LSBE.

**Table 1: The presence of a hiatal hernia by endoscopic type of BE**

		A hiatal hernia		Total
		Yes	No	
SSBE	N	29	10	39
	%	74.4	25.6	100.0
LSBE	N	11	-	11
	%	100.0	-	100.0
Total	N	40	10	50
	%	80.0	20.0	100.0
Z-value		Z = 1.87, P = 0.607		

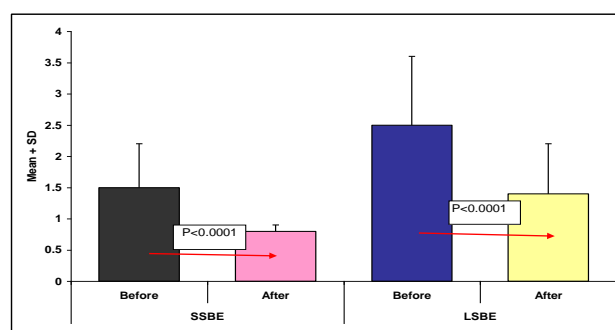
Circumferential extension in BE patients with SSBE before treatment was 1.5 cm (SD ± 0.7 cm), and after treatment was 0.8 cm (SD ± 0.1 cm). The T-test of mediocrity received the significant difference in circumferential spreading the SSBE group before vs

after treatment (T = 7.0, P < 0.0001) (Table 2, Fig. 1 and Fig. 2).

**Table 2: The effect of PPI treatment by Prague C & M classification in patients with BE**

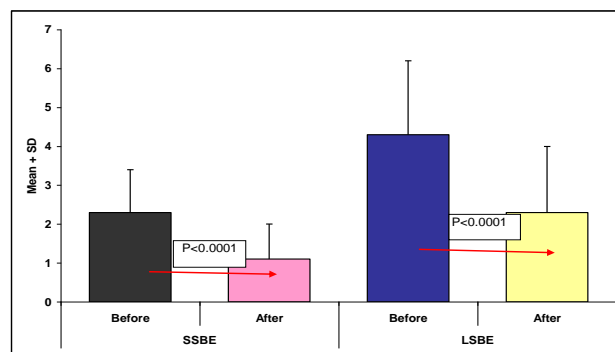
BE	Circumferential extent Median value ± SD		Maximal proximal extent Median value ± SD	
	Before	After	Before	After
SSBE n=39 T-test paired sample	1.5 ± 0.7	0.8 ± 0.1	2.3 ± 1.1	1.1 ± 0.9
	T = 7.0, P < 0.0001		T = 5.97, P < 0.0001	
LSBE n=11 T-test paired sample	2.5 ± 1.1	1.4 ± 0.8	4.3 ± 1.9	2.3 ± 1.7
	T = 5.71, P < 0.0001		T = 5.54, P < 0.0001	

Maximum proximal extension with this group before treatment was 2.3 cm (SD ± 1.1 cm), and after treatment 1.1 cm (SD ± 0.9 cm). The T-test of mediocrity received the significant difference in maximum proximal extension in the group before SSBE vs after treatment (t = 5.97, P < 0.0001).



**Figure 1: Maximal circumference of BE prior and after treatment with PPI based on Prague C & M**

Circumferential extension in BE patients with LSBE before treatment was 2.5 cm (SD ± 1.1 cm), and after treatment was 1.4 cm (SD ± 0.8 cm). The T-test of mediocrity received the significant difference in the stretching group circumferential LSBE before vs after treatment (T = 5.71, P < 0.0001). Maximum proximal extension with this group before treatment was 4.3 cm (SD ± 1.9 cm), and after treatment 2.3 cm (SD ± 1.7 cm). The T-test of mediocrity received the significant difference in maximum proximal extension with LSBE group before vs after treatment (t = 5.54, P < 0.0001).



**Figure 2: Maximal length of BE prior and after treatment with PPI based on Prague C & M**

## Discussion

Therapy with PPI showed that long-term safety reduces exposure to acid and prevents the development of dysplasia [8]. The results of our study may be useful to encourage all patients with Barrett's oesophagus to continue therapy with PPI, for long-term, to prevent dysplasia, even if they had symptoms or esophagitis. Furthermore, cases of Barrett's oesophagus can be divided according to the length of the segment of Barrett's oesophagus. BE patients with a short segment is defined as intestinal metaplasia of the distal oesophagus when the length is less than 3 cm. Disease with long segment refers to cases when intestinal metaplasia of the distal oesophagus is measured 3cm or more. Our results show that the BE circumferential changes in patients with SSBE before treatment was 1.5 cm (SD  $\pm$  0.7 cm), and after treatment has fallen to 0.8cm (SD  $\pm$  0.1 cm) ( $P < 0.0001$ ), circumferential BE extension in patients with LSBE before treatment was 2.5 cm (SD  $\pm$  1.1 cm), and after treatment was 1.4 cm (SD  $\pm$  0.8 cm) ( $P < 0.0001$ ). Maximum proximal extension in this group before treatment was 4.3 cm (SD  $\pm$  1.9 cm), and after treatment 2.3 cm (SD  $\pm$  1.7 cm) ( $P < 0.0001$ ).

There are few studies in the literature on this topic. Sampliner [9] studied 27 patients treated for almost 3 years with lansoprazole 60 mg daily. There was no reduction in the segment of Barrett-oesophagus, but 62% of patients developed islands in plate epithelium. In one study Sharma et al., [10] followed up 13 patients, for an average period of 5.7 years, who received lansoprazole 30 mg twice daily. There was no reduction of Barrett's oesophagus or complete control of acidity in the oesophagus (documented by pH testing). Extensive study with 47 patients treated with different doses of omeprazole also showed the appearance of islets of plate epithelium, but not completely cut the length of the Barrett-s segment of the oesophagus. A 12 months study conducted by Malesci et al., [11] showed a total reduction of 4.5 to 2.1 cm with a 12-month suppression of acidity. These data show the most impressive reduction in the length of Barrett's oesophagus to date and they are difficult to replicate.

Recently, Srinivasan et al., [12] reported about 9 patients who had complete control of oesophageal acidity using PPI twice daily, with a histamine blocker, at night. This treatment resulted in a slight decrease in the average length of Barrett's oesophagus, from 7.2 to 5.2 cm reaching statistical value ( $P < 0.001$ ). Indeed, histamine blockers could not produce any islands of epithelium plate or reduced length of Barrett's oesophagus in these studies. In an extensive review of the literature concerning this topic, only 3 patients described complete withdrawal of Barrett's oesophagus following treatment with PPI.

Interestingly, the short-segment disease is at least 3 times more prevalent than long-segment

disease [13] [14] [15], and the length of the long segment is associated with greater exposure to acid [16]. But once Barrett's oesophagus is present its overall length does not change, so the disease with a short segment normally remains short [17]. The degree of dysplasia is directly related to the length of the segment [18] [19]. However, variants with a long or short segment of Barrett's oesophagus associated with the development of dysplasia and adenocarcinoma regarding monitoring and endoscopic treatment are both treated similarly [20].

In conclusion, the age group of 50-59 years, male gender, smokers and alcohol consumer are important predictive factors for the development of BE among patients with GERD. Obesity, age, male gender, smoking is also an important factor in the development of the BE, so far as it is represented. A hiatal hernia is confirmed to be an important factor in the occurrence of Barrett's oesophagus since it was present in a high rate in both endoscopic types (74% in SSBE and 100% in LSBE). We confirmed that PPI therapy is useful for long-term safety and the regression of macroscopic changes of BE due to reduced exposure of the distal oesophagus to gastric acid.

## Reference

1. Wang KK, Sampliner RE. Updated guidelines 2008 for the diagnosis, surveillance and therapy of Barrett's esophagus. *Am J Gastroenterol.* 2008; 103:788-797. <https://doi.org/10.1111/j.1572-0241.2008.01835.x> PMID:18341497
2. Playford RJ. New British Society of Gastroenterology (BSG) guidelines for the diagnosis and management of Barrett's oesophagus. *Gut.* 2006; 55:442. <https://doi.org/10.1136/gut.2005.083600> PMID:16531521 PMCid:PMC1856188
3. Kerkhof M, Steyerberg EW, Kusters JG, Kuipers EJ, Siersema PD. Predicting presence of intestinal metaplasia and dysplasia in columnar-lined esophagus: a multivariate analysis. *Endoscopy.* 2007; 39:772-778. <https://doi.org/10.1055/s-2007-966737> PMID:17703384
4. Van Baal, Milano F, Rygiel AM, Bergman JJ, Rosmolen WD, van Deventer SJ, et al. A comparative analysis by SAGE of gene expression profiles of Barrett's esophagus, normal squamous esophagus, and gastric cardia. *Gastroenterology.* 2005; 129:1274-1281. <https://doi.org/10.1053/j.gastro.2005.07.026> PMID:16230080
5. Kelty CJ, Gough MD, Van Wyk Q, Stephenson TJ, Ackroyd R. Barrett's oesophagus: intestinal metaplasia is not essential for cancer risk. *Scand J Gastroenterol.* 2007; 42:1271-1274. <https://doi.org/10.1080/00365520701420735> PMID:17852872
6. Sharma P, Dent J, Armstrong D, Bergman JJ, Gossner L, Hoshihara Y. et al. The development and validation of an endoscopic grading system for Barrett's esophagus: the Prague C & M criteria. *Gastroenterology.* 2006; 131:1392-1399. <https://doi.org/10.1053/j.gastro.2006.08.032> PMID:17101315
7. Wang KK, Sampliner RE. Practice guidelines Updated Guidelines 2008 for the Diagnosis, Surveillance and Therapy of Barrett's Esophagus. *American Journal of Gastroenterology,* 2008. <https://doi.org/10.1111/j.1572-0241.2008.01835.x>
8. Weinstein MW. The prevention and treatment of dysplasia in

- gastroesophageal reflux disease: The results and the challenges ahead. *J Gastroenterol Hepatol.* 2002; 17:S113-S124. <https://doi.org/10.1046/j.1440-1746.17.s1.9.x> PMID:12000598
9. Sampliner RE. Effect of up to 3 years of high-dose lansoprazole on Barrett's esophagus. *Am J Gastroenterol.* 1994; 89:1844-1848. PMID:7942680
10. Sharma P, Sampliner RE, Camargo E. Normalization of esophageal pH with high-dose proton pump inhibitor therapy does not result in regression of Barrett's esophagus. *Am J Gastroenterol.* 1997; 92:582-585. PMID:9128303
11. Malesci A, Savarino V, Zentilin P, Belicchi M, Mela GS, Lapertosa G et al. Partial regression of Barrett's esophagus by long-term therapy with high-dose omeprazole. *Gastrointest Endosc.* 1996; 44:700-705. [https://doi.org/10.1016/S0016-5107\(96\)70055-X](https://doi.org/10.1016/S0016-5107(96)70055-X)
12. Srinivasan R, Katz PO, Ramakrishnan A, et al. Maximal acid reflux control for Barrett's oesophagus: feasible and effective. *Aliment Pharmacol Ther.* 2001; 15:519-524. <https://doi.org/10.1046/j.1365-2036.2001.00958.x> PMID:11284781
13. Hirota WK, Loughney TM, Lazas DJ, Maydonovitch CL, Rholl V, Wong RK. *Gastroenterology.* 1999; 116:277-85. [https://doi.org/10.1016/S0016-5085\(99\)70123-X](https://doi.org/10.1016/S0016-5085(99)70123-X)
14. Csendes A, Smok G, Burdiles P, Korn O, Gradiz M, Rojas J, Recio M. Prevalence of intestinal metaplasia according to the length of specialized columnar epithelium lining the distal esophagus in patients with gastroesophageal reflux. *Dis Esophagus.* 2003; 16:24-8. <https://doi.org/10.1046/j.1442-2050.2003.00284.x> PMID:12581250
15. Hanna S, Rastogi A, Weston AP, Totta F, Schmitz R, Mathur S, McGregor D, Cherian R, Sharma P. Detection of Barrett's esophagus after endoscopic healing of erosive esophagitis. *Am J Gastroenterol.* 2006; 101:1416-20. <https://doi.org/10.1111/j.1572-0241.2006.00631.x> PMID:16863541
16. Sharma P, McQuaid K, Dent J, et al. A critical review of the diagnosis and management of Barrett's esophagus: the AGA Chicago Workshop. *Gastroenterology.* 2004; 127(1):310-30. <https://doi.org/10.1053/j.gastro.2004.04.010> PMID:15236196
17. Guidelines for the diagnosis and management of Barrett's columnar-lined oesophagus, British Society of Gastroenterology (BSG), August 2005.
18. Spechler SJ. The natural history of dysplasia and cancer in esophagitis and Barrett esophagus. *J Clin Gastroenterol.* 2003; 36:S2-S5; discussion S26-S28.
19. Garrido SA, Guerrero Igea FJ, Lepe Jimenez JA, Perianes HC. Clinical features and endoscopic progression of gastroesophageal reflux disease. *Rev Esp Enferm Dig.* 2003; 95:712-16.
20. Odze RD. Barrett esophagus: histology and pathology for the clinician. *Nat Rev Gastroenterol Hepatol.* 2009; 6:478-490. <https://doi.org/10.1038/nrgastro.2009.103> PMID:19581906