

An Uncommon Occurrence of Pleomorphic Adenoma in the Submandibular Salivary Gland: A Case Report

Farhat Farhat^{1*}, Rizalina A. Asnir¹, Ashri Yudhistira¹, Elvita Rahmi Daulay², Irwan Pernandi Sagala¹

¹Department of Otorhinolaryngology Head and Neck Surgery, Faculty of Medicine, Universitas Sumatera Utara, 20155, Indonesia; ²Department of Radiology, Faculty of Medicine, Universitas Sumatera Utara, 20155, Indonesia

Abstract

Citation: Farhat F, Asnir RA, Yudhistira A, Daulay ER, Sagala IP. An Uncommon Occurrence of Pleomorphic Adenoma in the Submandibular Salivary Gland: A Case Report. Open Access Maced J Med Sci. <https://doi.org/10.3889/oamjms.2018.248>

Keywords: Pleomorphic adenoma; Benign mixed tumour; Submandibular salivary gland; Salivary gland; Submandibular gland

***Correspondence:** Farhat Farhat, Department of Otorhinolaryngology Head and Neck Surgery, Faculty of Medicine, Universitas Sumatera Utara, 20155, Indonesia. E-mail: farhatmedan@gmail.com

Received: 07-Aug-2017; **Revised:** 15-Feb-2018; **Accepted:** 24-May-2018; **Online first:** 17-Jun-2018

Copyright: © 2018 Farhat Farhat, Rizalina A. Asnir, Ashri Yudhistira, Elvita Rahmi Daulay, Irwan Pernandi Sagala. This is an open-access article distributed under the terms of the Creative Commons Attribution-NonCommercial 4.0 International License (CC BY-NC 4.0)

Funding: This research did not receive any financial support

Competing Interests: The authors have declared that no competing interests exist

BACKGROUND: Pleomorphic adenoma is a salivary gland tumour and mostly found in the parotid gland and quite uncommon in the submandibular gland. Pleomorphic tumours are a mixed tumour (benign mixed tumour) consisted of epithelium, myoepithelium, and mesenchyme and made of a view component variation of it.

CASE REPORT: We reported a fifty-three years old man with pleomorphic adenoma that has been complaining swelling on the left neck for the last twenty years and treated with surgical excision. Computed tomography of the neck showed soft tissue tumour in the left submandibular.

CONCLUSIONS: The best management for pleomorphic adenoma is surgery, the tumour tissue must be removed as a whole because the remaining parts of a tumour can easily become recurrent or turn into a malignant tumour.

Introduction

Pleomorphic adenoma is a salivary gland tumour and mostly found in the parotid gland. A pleomorphic tumour is a mixed tumour (benign mixed tumour) consisted of epithelium, myoepithelium, mesenchyme and made of a view component variation of it [1]. Almost 85% of benign epithelial salivary gland tumours arise from the parotid gland and only 10% in the submandibular gland. Pleomorphic adenoma typically present as a slow growing, unilateral and painless mass of salivary glands, with a predilection for recurrence and risk of malignant transformation (about 1.5% up to 5 years and increases to 9.5% after more than 15 years) [2] [3].

The salivary glands are categorised as major salivary gland and minor salivary gland. There are three kinds of the major salivary gland; they are the parotid gland, submandibular gland, and sublingual

gland. The minor salivary glands were lying along upper aerodigestive submucosal such as the palate, lips, pharynx, nasopharynx, larynx, and parapharyngeal. In the major salivary gland, the pleomorphic adenomas are often seen in the parotid gland, while in the minor salivary gland, it is often seen in palate and upper lip [2] [4].

Pleomorphic adenoma can be found among all ages (kids or adults). It shows about 45% to 75% of neoplasm in saliva gland and the incidence of 2-35 cases per 100,000 people. The comparison between woman and man are 2:1. This tumour usually found in the ages of thirties till sixties with the average of 43-46 years old. In America, this tumour was found 80% of all saliva gland benign tumours [5].

B-catenin was a molecule which has a role in invasion and metastatic process of carcinomas in head, neck, oesophagus, gastric, colon, liver, woman genitalia, prostate, vesica urinary, pancreas and also melanoma [6].

Case Report

A patient, 53 years old man referred from Haji General Hospital to the outpatient clinic of Adam Malik General Hospital with the main complain of swelling on the left neck for the last 20 years prior admission. The mass was enlarging slowly. He denied any pain, nasal blocking, headache, diplopia, hoarseness, dysphagia or odynophagia, no history of bleeding and mucous secret.

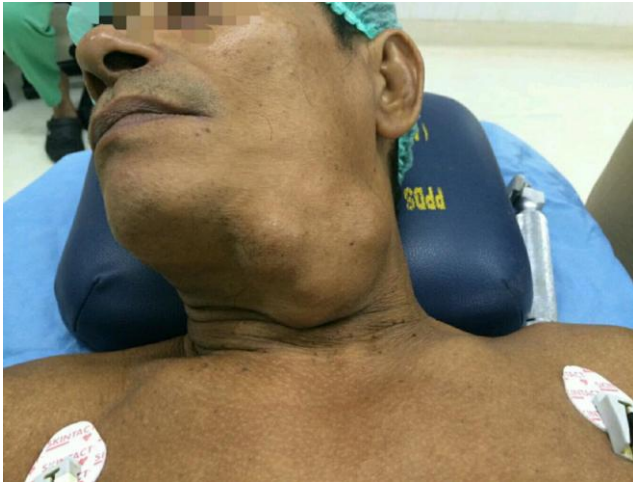

Figure 1: Anteroposterior view of the neck mass

The physical examination noted the patient's sensorium was compos mentis, pulse 80 beats per minute, respiratory rate 20 times per minute and the temperature was 37°C and also presented a solid, immobile, and no painful left neck mass measuring approximately 6 cm x 4 cm x 3 cm. Ear, nose and throat examination showed no abnormalities.

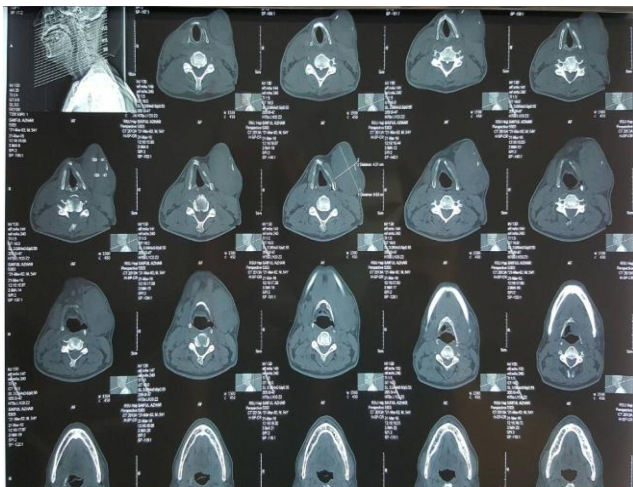


Figure 2: Neck CT Scan (soft tissue tumour size 6.63 x 4.21 cm in the left submandibular)

Fine needle aspiration biopsy found as a pleomorphic adenoma; haematologic laboratory finding was in normal limit. ECG and thorax x-ray

were also showed no abnormalities. Then we performed computed tomography of the neck for this patient, and the result showed soft tissue tumour with the size of 6.63 x 4.21cm in the left submandibular.

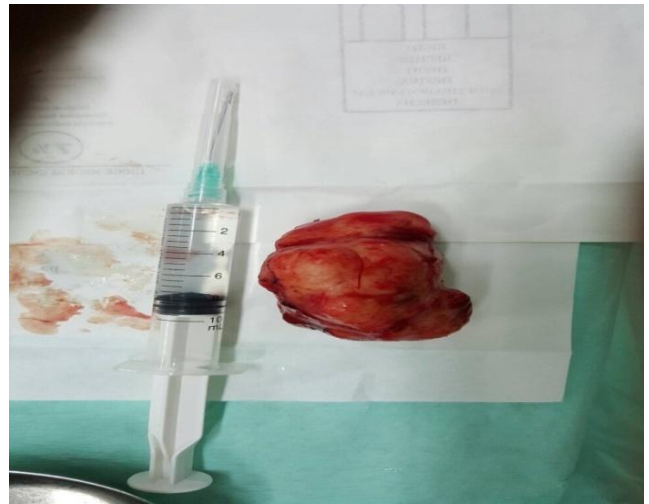

Figure 3: The tumor size 6 x 4 x 3 cm

We diagnosed the patient with submandibular pleomorphic adenoma and conducted surgical excision. The tumour was removed entirely, and the outcome was good. The histopathologic examination after surgery showed a pleomorphic adenoma.

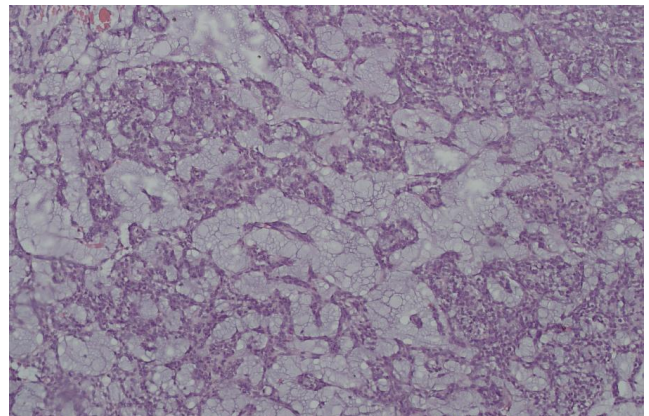


Figure 4: Histopathological examination (x100)

Discussion

Pleomorphic adenoma is the most common benign salivary glands tumour, which is about 65% of all salivary gland tumours. Malignancy in the salivary glands occurs 3-6% of all neoplasms head and neck. White people have a slightly higher risk to suffer pleomorphic adenoma than other races. Women are more dominant with the ratio 3:2.1. Some factors predisposition is suspected of additional exposure to radiation, genetic, users of tobacco, chemicals exposure, and viruses. Patients do not have a history

of smoking or exposure to radiation, but often eating preserved foods such as anchovies and grilled food. The level of accuracy of FNAB in distinguishing malignancy and benign is 79.1%, while the sensitivity of salivary gland neoplasms is about 89.4% [4].

In this case, we found a slow growing, unilateral and painless mass in the submandibular gland.

The aetiology of pleomorphic adenoma in the salivary glands is not known for certain, allegedly because of the involvement of environmental and genetic factors. Radiation exposure associated with the developments of benign tumours and mucoepidermoid malignant carcinoma. One study suggests that the Simian virus (SV 40) plays an important role in the development of pleomorphic adenoma. The Epstein-Barr virus is one of the factors in the development of the tumours of salivary gland lymphoepithelial. Genetic changes, such as allelic loss, monosomy, and polysomy, and realignment of structure [7] [8].

In general, β -catenin plays an important role in the development of pleomorphic adenoma. Not only in the form of malignant change, but also in the regulation of physiological functions. The expression of adhesion molecules in salivary gland neoplasms had been explored. Study now says attempts to clarify the role of cells in oncogenesis and cytodifferentiation pleomorphic adenoma and carcinoma of the salivary glands. The expression of β -catenin is an immunohistochemical test in the lesions and normal salivary gland [6].

Pleomorphic adenoma has clinical features: a single tumour mass, hard, round, mobile, slow growth, painless, single nodule. Although pleomorphic adenoma tumours were classified as benign, it can grow larger and turn into a malignant form of carcinoma. The histopathological examination showed a well-circumscribed and encapsulated mass composed of an admixture of epithelial, myoepithelial and stromal components. One of these components can be found more often than the others, but these three components must be present to make a diagnosis [6] [9]. In this case, from histopathological examination, we found encapsulated mass composed of an admixture of epithelial, myoepithelial and stromal components.

CT picture of pleomorphic adenoma (benign mixed tumour) is a cross-section that is sharp and mostly surrounds homogeneous lesions that have a higher density than the glandular tissue. MRI showed pleomorphic adenoma (benign mixed tumour) with the areas that have relatively low signal intensity (dark area/radiolucent) than glandular tissue. Examination of pleomorphic adenoma with CT and MRI was done

by a radiologist. It is done to determine the location and size of the tumors, lesions detection, borderline tumor, aspects of the lesions, the contrast between lesions with surrounding tissue, the image intensity of the lesion, the success of the use of contrast medium, the aspect of the lesion after injection medium contrast, detection of his capsule and bone resorption occurs around the lesion [7] [10].

The best management of pleomorphic adenoma is surgery; the tumour tissue must be removed as a whole because the parts of a remaining tumour are easy to cause recurrence or turn into a malignancy [11].

References

1. Chaudhari S, Hatwal D, Ashok, Suri V. Pleomorphic Adenoma of Hard Palate: A Report of Four Cases. *IJCRI*. 2013; 4(2):90–94.
2. Civelek S, Ercan B, Cakir B, Basak T, Turgut S. Malignant Myoepithelial Carcinoma Arising in A Pleomorphic Adenoma of The Submandibular Gland. *KBB-Forum*. 2006; 5(4).
3. Mubeen K, Vijayalakshmi K, Abhisek R, Girish B, Singh C. Benign Pleomorphic Adenoma of Minor Salivary Gland of Palate. *Journal of Dentistry and Oral Hygiene*. 2011; 3(6):82-88.
4. Kertanadi N, Sudipta M, Ardika G. Parotidectomy Superficial Pada Adenoma Pleomorfik Parotis. *SMF Ilmu Kesehatan THT-KL Fakultas Kedokteran Universitas Udayana RSUP Sanglah Denpasar. Medicine*. 2014; 45(1).
5. Masanobu A, Mori Y, Kanno Y, Hoshi K, Saijo H, Abe T, Ohkubo K. A Case of Pleomorphic Adenoma of the Parotid Gland with Multiple Local Recurrences through Facial to Cervical Regions. *Open Journal of Stomatology*. 2014; 4: 441-445. <https://doi.org/10.4236/ojst.2014.49059>
6. Gani AN, Shiraz M, Aishah S, Norazizah M, Mazita A, Sharifah NA. Pleomorphic Adenoma Originating from Submandibular Salivary Gland in an 8-year-old Girl: A Case Report. *Med & Health*. 2007; 2(2): 164-168.
7. Firdaus MA, Pulungan MR. Penatalaksanaan Adenoma Pleomorfik Parotis. *Bagian Telinga Hidung Tenggorok Bedah Kepala Leher Fakultas Kedokteran Universitas Andalas / RSUP Dr. M. Djamil Padang*. 2011.
8. Nagaraj H, Raikar R, Rajalakshmi, Taj A, Asha M, Mutgi A. The World's Biggest Benign Parotid Tumour 'Pleomorphic Adenoma': a rare case report. *IOSR Journal of Dental and Medical Sciences (IOSR-JDMS)*. 2014; 13(2):08-12. <https://doi.org/10.9790/0853-13220812>
9. Perkasa MF, Kurniawati D. Adenoma Pleomorfik Kelenjar Saliva Pada Bayi. *Bagian Ilmu Kesehatan THT-KL Fakultas Kedokteran Universitas Hasanuddin Makassar. ORLI* 2013; 43(2).
10. Sheikh S, Aggarwai A, Singh R, Gupta D, Kaur I, Shambulingappa. Pleomorphic Adenoma of Parotid Gland: A Case Report. *International Dental Journal of Student's Research*. 2015; 3(4):151-154.
11. Isacianu L, Miron I, Tansanu I, Apostol. Pleomorphic Adenoma of The Submandibular Gland in A Teenager: A Case Report. *Jurnalul de Chirurgie, Iași*. 2010; 6:1584 – 9341.