

Schizophrenia as Potential Trigger for Melanoma Development and Progression! The Psycho-Neuro-Endocrine-Oncology (P.N.E.O) Network!

Georgi Tchernev^{1,2*}, Ilija Lozev³, Ivanka Temelkova¹, Svetoslav Chernin⁴, Irina Yungareva¹

¹Medical Institute of Ministry of Interior (MVR), Department of Dermatology, Venereology and Dermatologic Surgery, General Skobelev Nr 79, Sofia 1606, Bulgaria; ²Onkoderma, Polyclinic for Dermatology and Dermatologic Surgery, General Skobelev 26, Sofia 1407, Bulgaria; ³Medical Institute of the Ministry of Interior, Surgery, Sofia, Bulgaria; ⁴Medical Institute of the Ministry of Interior, Common, Vascular and Abdominal Surgery, Sofia, Bulgaria

Abstract

Citation: Tchernev G, Lozev I, Temelkova I, Chernin S, Yungareva I. Schizophrenia as Potential Trigger for Melanoma Development and Progression! The Psycho-Neuro-Endocrine-Oncology (P.N.E.O) Network! Open Access Maced J Med Sci. <https://doi.org/10.3889/oamjms.2018.276>

Keywords: Malignant melanoma; Antipsychotics; Levodopa; Advancing

***Correspondence:** Georgi Tchernev, Medical Institute of Ministry of Interior (MVR), Department of Dermatology, Venereology and Dermatologic Surgery General Skobelev Nr 79, Sofia 1606 Bulgaria; Onkoderma-Polyclinic for Dermatology and Dermatologic Surgery General Skobelev 26, Sofia 1407, Bulgaria. E-mail: georgi_tchernev@yahoo.de

Received: 26-Jul-2018; **Revised:** 09-Aug-2018; **Accepted:** 10-Aug-2018; **Online first:** 16-Aug-2018

Copyright: © 2018 Georgi Tchernev, Ilija Lozev, Ivanka Temelkova, Svetoslav Chernin, Irina Yungareva. This is an open-access article distributed under the terms of the Creative Commons Attribution-NonCommercial 4.0 International License (CC BY-NC 4.0)

Funding: This research did not receive any financial support

Competing Interests: The authors have declared that no competing interests exist

BACKGROUND: Skin, nervous tissue, dopamine and melanoma share a common neuroectodermal origin. Hence, processes that modulate nervous tissue formation, patient mental status, motor regulation of individuals, and skin cancerogenesis are inextricably linked. Psycho-neuro-endocrine oncology (or dermato-oncology), i.e. P.N.E.O., is a new model or trend in medicine and science presented for the first time in the world literature by us, that aims to examine the relationship between the mental state, the hormones and the malignant transformation. Schizophrenia and Parkinson's disease are the two main patterns of disease where the main symptoms are related to dopamine levels in the human body. According to our analyses of the available literature, the amount of dopamine is related to the incidence of melanocytic or non-melanocytic cutaneous tumours in patients with central nervous system diseases and those affecting the motor function and coordination. Such patterns of interaction are extremely indicative of the elucidation of the ubiquitous hypothesis or statement: "My illness is on a mental basis, caused by stress ..."

CASE PRESENTATION: We present a 44-year-old patient with untreated schizophrenia for approximately 25 years, associated with advanced acral localised melanoma. Schizophrenia is generally associated with a higher level of dopamine, which is also a key precursor to melanin synthesis. After a careful analysis of all literature on melanoma in patients with 1) treated and untreated schizophrenia, 2) those with untreated and untreated forms of Parkinson's disease, it would be logical to conclude that the high level of dopamine in the described patient groups is a risk factor for the development of melanoma.

CONCLUSIONS: The possible mechanisms for the occurrence of malignant melanoma within the so-called psycho/neuro/endocrine oncology (P.N.E.O.), as well as the effective methods of prevention, are under discussion.

Introduction

Schizophrenia is a mental disorder affecting approximately 1% of the world population [1]. Standard therapy for patients with this disease is given with dopamine antagonists [2]. They are thought to have a protective effect on the development of malignant melanoma in patients with schizophrenia [3].

The statement of the anti-tumour effect of dopamine antagonists is based on the results of various studies which postulate that patients with

Parkinson's disease and dopamine agonist therapy have an increased incidence of malignant melanoma [4] [5].

Case report

We present a 44-year old woman with head trauma suffered in childhood (falling from a bridge), soon afterwards diagnosed with paranoid schizophrenia. Patient complaints began

approximately 26 years ago. Last, about 2 years ago, she received the antipsychotic drug Olanzapine 5mg for 3-4 months. The patient is now receiving Biperiden Hydrochloride 2 mg (1-1-0) and Aripiprazole (antipsychotic) 15 mg (0-0-1) therapy. Her therapy is currently discontinued for schizophrenia. The patient reports the presence of a pigmented lesion on the medial surface of the left lower leg for approximately 10 years. About 6 months ago she noticed the occurrence of nodules on the medial surface of her left lower leg, and subsequently, the pigment lesion progressively increased its size (Figure 1a).

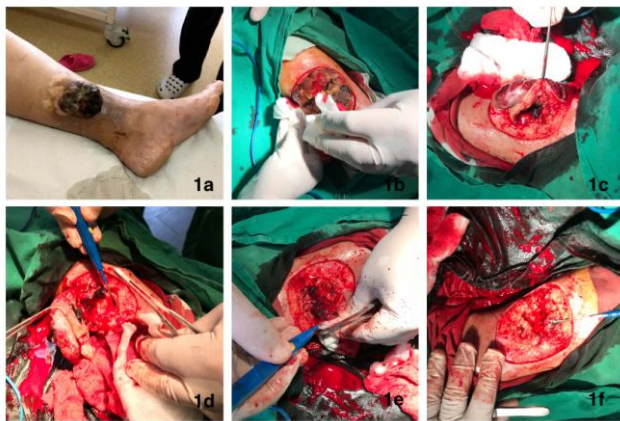

Figure 1: a) Primary cutaneous giant melanoma in a schizophrenic patient; b-f) Surgical excision of the primary tumor under general anaesthesia. A split skin mesh graft was planned after 3 weeks

Subjectively there is a complaint about itching. Approximately 4 months ago, the patient consulted a surgeon for that lesion and was referred for surgical removal of the formation. However, the patient refuses to undergo surgery and is conservatively treated with Povidone-iodine ointment and herbs. A subsequent significant increase in the size of the lesion was observed, which is the reason for hospitalisation. Dermatological examination revealed the presence of an exophytic, tumour-like formation with an erosive surface, in decay, releasing stenching smell, located on the medial surface of the left lower leg (Figure 1a).

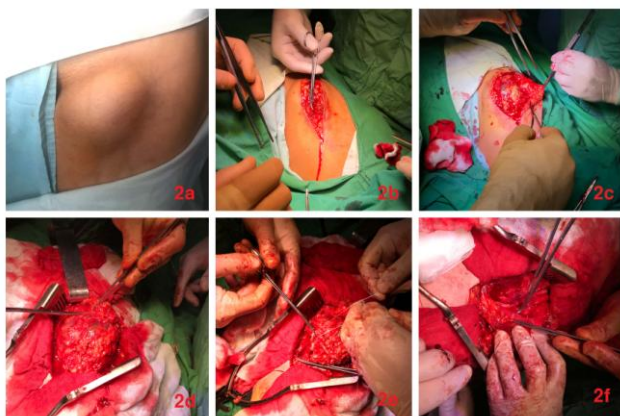

Figure 2: a-f) Inguinal lymph node dissection was carried out

Additionally, the presence of enlarged lymph nodes in the left inguinal region (Figure 2a) was established. Radical removal of the primary tumour formation along with lymph dissection (inguinal and parailliactal) of the enlarged lymph nodes (Figure 1b-1f, 2b-2f, 3a-3f inguinal/4a-4h parailliactal, Figure 5a-5c defect closure after the lymph node dissections) was carried out.

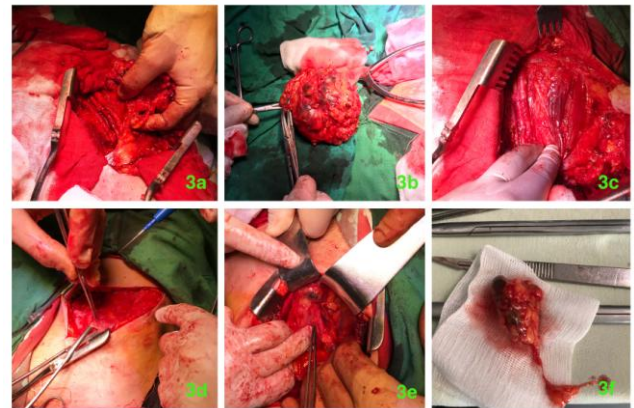


Figure 3: a-c) Arterial and venous vessels were not injured (Fig. 3a); the giant tumorous metastatic formation was completely removed (Fig. 3b, 3c)

Histopathological evidence was for ulcerated nodular type of malignant melanoma, Breslow thickness of 18 mm, Clark IV-V, and 3 metastatic lymph nodes, two of them in the inguinal and 1 of them in the parailliactal area, staged as III D. The patient was redirected to the oncology department and a therapy with Interferon 3 x 3 Mio was planned.

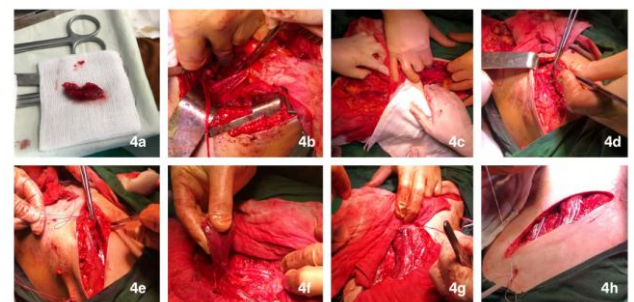


Figure 4: 3d-4h) The parailliactal lymph node dissection was performed parallel with the inguinal one (Fig. 4b). Several pigmented metastatic lymphatic nodes were removed additionally (Figs. 3e, 3f, 4a)

Discussion

Standard care treatment of schizophrenia as a chronic mental illness involves antipsychotic agents [2]. These drugs act as antagonists of the dopamine D2 receptors and serotonin 5-HT2A receptors, respectively, dopamine and serotonin [2]. There is an interesting hypothesis of a possible association

between the intake of antipsychotics and the possibility of subsequent melanoma formation [3]. Already in 1982, an antitumor effect of dopamine antagonists on the development of melanoma was discussed [3]. Melanoma culture research in mice then showed that the antidopaminergic agent (Pimozide) used had an inhibitory effect on mouse melanoma cells [3]. Similarly to other authors, we maintain that schizophrenic patients receiving anti-dopamine therapy show a lower incidence of melanoma [6].

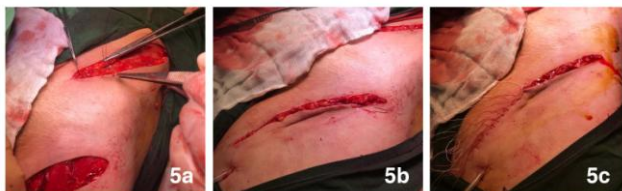

Figure 5: a-c) Defects closure with single cutaneous surgical stitches

Under the effect of sunlight, mutations in melanoma cells occur, thus increasing the risk of melanoma in general [7]. Solar radiation induces mutations in the p53 genome regulator that is capable of inducing a cell block on the one hand (via certain inhibitory proteins such as p21, p27, p16) and, on the other, activating certain pro-apoptotic proteins such as Bax/Bak that in turn, cause cell death in tumor cells [8] [9]. The presence of mutations in p53 deactivates its functions and causes uncontrolled cellular proliferation, lack of possibility of the altered cells being eliminated by the activation of programmed cell death-apoptosis, ultimately resulting in the generation of the corresponding tumour branch [8] [9]. Whether this malignant branch will develop by impaired melanocyte or keratinocyte, at least hypothetically, should depend on the concentration or density of melanocytes localised on the basal level of the epidermis (as well as on the individual sensitivity of each patient that is multifactorial conditional).

When melanin synthesis is enhanced or is enhancing (by external intervention such as dopamine agonist therapy for Parkinson's disease or by internal intervention such as in untreated schizophrenia, for example), then mutations affect melanocytes (which density in the epidermis should have been increased) more often. Melanoma incidence in the two categories of patients described is as shown in other studies [4] [5]. Currently, there are no scientific studies to compare the incidence of melanoma and melanocyte density in patients with Parkinson's disease and schizophrenia both across patients with Parkinson's disease and healthy volunteers.

From an anatomical point of view, albeit somewhat speculatively, the increased number of melanocytes could also be seen as a protective factor in the development of keratinocyte tumours. This is also anatomically determined by the fact that the

network of the increased number of melanocytes, as well as the dendrites of the latter, cover the greater part of keratinocyte cells, thus "absorbing" the majority of the negative effect of solar radiation on "their account". The more melanocytes in the basal layer of the epidermis, the higher the risk of melanoma development (when patients are exposed to UV radiation, and possibly have a genetic predisposition).

In schizophrenic patients with increased levels of dopamine, it should be assumed that the number of melanocytes in the basal part of the epidermis is further increased. In the presence of intensive sunbathing in areas exposed to solar radiation, the cumulative risk of melanoma formation should further increase [10].

According to this hypothesis, antipsychotic drugs should reduce the number of melanocytes in the epidermis by reducing dopamine and hence the risk of melanoma formation. Indirectly, the risk of developing epithelial skin tumours such as basal cell and spinocellular carcinomas [11] should also increase. It is believed that the genes regulating skin pigmentation play a key role in the development of melanoma [12]. How, however, these genes involved in melanin synthesis affect the risk of melanoma development is still the subject of further studies [13]. It is believed that *CDKN2A*, *MC1R*, *MITF* genes are involved in melanocytes differentiation and development and that mutations in these genes are associated with the formation and progression of malignant melanoma, together with pigmentation [14]. Probably the common biochemical pathway of dopamine and melanin (with a common precursor, i.e. tyrosine) is the starting point that should be considered critically regarding the risk of melanoma formation in patients receiving dopamine preparations (antagonists or agonists) [15].

This is the place to mention an equally discussed topic about the risk of malignant melanoma in patients with Parkinson's disease [16]. The therapy of patients with Parkinson's disease includes dopamine agonists that increase dopamine levels and, hence, the risk of melanoma [4] [5] [17].

It is open and somewhat speculative question whether melanomas in patients with increased dopamine in the body develop on the basis of 1) increased melanocytes in the basal part of the epidermis, which determines completely randomly the possibility of mutations (due to the higher probability of occurrence following intense ultraviolet radiation), or this is due to 2) distorted processes within the melanogenesis itself (due to the presence of a certain product in abundance, which would lead to a possible blocking of some and activation of other pathogenic chains)?

If we base our discussion on the described theory of psycho-neuro-endocrine oncology, it should be inevitably confirmed by studies in patients with Parkinson's disease with elevated levels of melanin

precursor dopamine [4]. Available data from a study in Parkinson's patients show a 4.4 to the 7-fold higher risk of melanoma occurrence in these patients [4] [5].

In conclusion, the risk of malignant melanoma development depends on some factors. We believe that in patients receiving dopamine antagonist's therapy, the reduced dopamine level may reduce the potential for melanoma development, and the biomechanisms of this anti-tumour effect are determined by a genetic level. In support of this, there is evidence that dopamine agonists used to treat patients with Parkinson's disease have increased the incidence of melanoma in these patients several times.

References

1. Millier A, Schmidt U, Angermeyer M, Chauhan D, Murthy V, Toumi M, Cadi-Soussi N. Humanistic burden in schizophrenia: a literature review. *J Psychiatr Res*. 2014; 54:85-93. <https://doi.org/10.1016/j.jpsychires.2014.03.021> PMID:24795289
2. Werner F, Cove-as R. Safety of antipsychotic drugs: focus on therapeutic and adverse effects. *Expert Opin Drug Saf*. 2014; 13(8):1031-42. <https://doi.org/10.1517/14740338.2014.935761> PMID:24975932
3. Krummel T, Neifeld JP, Taub N. Effects of dopamine agonists and antagonists on murine melanoma: correlation with dopamine binding activity. *Cancer*. 1982; 49(6):1178-84. [https://doi.org/10.1002/1097-0142\(19820315\)49:6<1178::AID-CNCR2820490619>3.0.CO;2-H](https://doi.org/10.1002/1097-0142(19820315)49:6<1178::AID-CNCR2820490619>3.0.CO;2-H)
4. Bertoni J, Arlette P, Fernandez H, Fitzer-Attas C, Frei K, Hassan N, Isaacson H, Lew F, Molho E, Ondo G, Phillips J, Singer C, Sutton P, Wolf J. Increased melanoma risk in Parkinson disease: a prospective clinicopathological study. *Arch Neurol*. 2010; 67(3):347-52. <https://doi.org/10.1001/archneurol.2010.1> PMID:20212233
5. Inzelberg R, Rabey JM, Melamed E, Djaldetti R, Reches A, Badarny S, Hassin-Baer S, Cohen O, Trau H, Aharon-Peretz J, Milo R, Schwartz M, Huberman M, Gilead L, Barchana M, Liphshiz I, Fitzer-Attas C, Giladi N. High prevalence of malignant melanoma in Israeli patients with Parkinson's disease. *J Neural Transm (Vienna)*. 2011; 118(8):1199-207. <https://doi.org/10.1007/s00702-011-0580-2> PMID:21298300
6. Mortensen P. The occurrence of cancer in first admitted schizophrenic patients. *Schizophr Res*. 1994; 12(3):185-94. [https://doi.org/10.1016/0920-9964\(94\)90028-0](https://doi.org/10.1016/0920-9964(94)90028-0)
7. Craig S, Earnshaw C, Virós A. Ultraviolet light and melanoma. *J Pathol*. 2018; 244(5):578-585. <https://doi.org/10.1002/path.5039> PMID:29380860
8. Tchernev G, Orfanos CE. Downregulation of cell cycle modulators p21, p27, p53, Rb and proapoptotic Bcl-2-related proteins Bax and Bak in cutaneous melanoma is associated with worse patient prognosis: preliminary findings. *J Cutan Pathol*. 2007; 34(3):247-56. <https://doi.org/10.1111/j.1600-0560.2006.00700.x> PMID:17302609
9. Fecker LF, Geilen CC, Tchernev G, Trefzer U, Assaf C, Kurbanov BM, Schwarz C, Daniel PT, Eberle J. Loss of proapoptotic Bcl-2-related multidomain proteins in primary melanomas is associated with poor prognosis. *J Invest Dermatol*. 2006; 126(6):1366-71. <https://doi.org/10.1038/sj.jid.5700192> PMID:16528364
10. Hendi A, Brodland D, Zitelli J. Melanocytes in long-standing sun-exposed skin: quantitative analysis using the MART-1 immunostain. *Arch Dermatol*. 2006; 142(7):871-6. <https://doi.org/10.1001/archderm.142.7.871> PMID:16847203
11. Watson M, Holman D, Maguire-Eisen M. Ultraviolet Radiation Exposure and Its Impact on Skin Cancer Risk. *Semin Oncol Nurs*. 2016; 32(3):241-254. <https://doi.org/10.1016/j.soncn.2016.05.005> PMID:27539279 PMID:PMC5036351
12. Herrero Hernández E. Pigmentation genes link Parkinson's disease to melanoma, opening a window on both etiologies. *Med Hypotheses*. 2009; 72(3):280-4. <https://doi.org/10.1016/j.mehy.2008.10.011> PMID:19027242
13. Pho N, Leachman A. Genetics of pigmentation and melanoma predisposition. *G Ital Dermatol Venereol*. 2010; 145(1):37-45. PMID:20197744
14. Potrony M, Badenas C, Aguilera P, Puig-Butille J, Carrera C, Malvey J. Update in genetic susceptibility in melanoma. *Ann Transl Med*. 2015; 3(15): 210. PMID:26488006 PMID:PMC4583600
15. Fiala K, Whetteckey J, Manyam V. Malignant melanoma and levodopa in Parkinson's disease: causality or coincidence? *Parkinsonism Relat Disord*. 2003; 9(6):321-7. [https://doi.org/10.1016/S1353-8020\(03\)00040-3](https://doi.org/10.1016/S1353-8020(03)00040-3)
16. Disse M, Reich H, Lee P, Schram S. A Review of the Association Between Parkinson Disease and Malignant Melanoma. *Dermatol Surg*. 2016; 42(2):141-6. <https://doi.org/10.1097/DSS.0000000000000591> PMID:26771684
17. Perez-Lloret S, Rascol O. Dopamine receptor agonists for the treatment of early or advanced Parkinson's disease. *CNS Drugs*. 2010; 24(11):941-68. <https://doi.org/10.2165/11537810-000000000-00000> PMID:20932066