

Key Issues in the Management of Multi-Drug Resistant Tuberculosis: A Case Report

Zorica Nanovic^{1*}, Biserka Kaeva-Jovkovska², Gorica Breskovska², Milena Petrovska³

¹*Institute of Lung Diseases and Tuberculosis, Skopje, Republic of Macedonia;* ²*University Clinic of Pulmonology and Allergology, Faculty of Medicine, Ss Cyril and Methodius University of Skopje, Skopje, Republic of Macedonia;* ³*Institute of Microbiology and Parasitology, Faculty of Medicine, Ss Cyril and Methodius University of Skopje, Skopje, Republic of Macedonia*

Abstract

Citation: Nanovic Z, Kaeva-Jovkovska B, Breskovska G, Petrovska M. Key Issues in the Management of Multi-Drug Resistant Tuberculosis: A Case Report. Open Access Maced J Med Sci. 2018 Jul 20; 6(7):1282-1288. https://doi.org/10.3889/oamjms.2018.290

Keywords: MDR-TB; Molecular tests for TB; MDR-TB treatment

***Correspondence:** Zorica Nanovic, Institute of lung diseases and tuberculosis, Skopje, Republic of Macedonia. E-mail: znanovic@hotmail.com

Received: 12-May-2018; **Revised:** 28-Jun-2018; **Accepted:** 03-Jul-2018; **Online first:** 14-Jul-2018

Copyright: © 2018 Zorica Nanovic, Biserka Kaeva-Jovkovska, Gorica Breskovska, Milena Petrovska. This is an open-access article distributed under the terms of the Creative Commons Attribution-NonCommercial 4.0 International License (CC BY-NC 4.0)

Funding: This research did not receive any financial support

Competing Interests: The authors have declared that no competing interests exist

BACKGROUND: Global tuberculosis (TB) epidemic is being driven to an increasing extent by the emergence and spread of drug-resistant strains of *Mycobacterium tuberculosis* complex (MTBC). We present a case of primary multidrug-resistant tuberculosis (MDR-TB), highlighting Macedonian MDR-TB management issues.

CASE REPORT: A 39-year old previously healthy Caucasian male, with no previous history of TB or close contact to TB, was admitted in referral TB-hospital due to respiratory bleeding. Chest X-ray revealed opacity with cavernous lesions in the right upper lobe. Sputum samples showed no presence of acid-fast bacilli (AFB) on fluorescence microscopy, but molecular tests (real-time PCR-based assay and multiplex PCR-based reverse hybridisation Line Probe Assay) confirmed the presence of MTBC, also revealing rifampicin and isoniazid resistance and absence of resistance to second-line anti-tubercular drugs. The strain was considered multidrug-resistant, lately confirmed by conventional methods in liquid and solid culture. Following the protocol of the World Health Organization, we started the longer treatment of MDR-TB comprised of at least five effective anti-tubercular drugs. Due to patient's extreme non-adherence, we had to delay and modify the regimen (i.e. omitting parenteral aminoglycoside) and to discharge him from the hospital a month after directly observed therapy (DOT) in negative pressure room. As there is no legal remedy in our country regarding involuntary isolation, our patient continued the regimen under ambulatory control of referral TB-hospital. Ignoring the risk of additional acquisition of drug resistance and prolonged exposure of the community to MDR-TB strain - for which he was repeatedly advised - he decided to cease the therapy six months after beginning.

CONCLUSION: The benefit of molecular tests in the early diagnosis of TB and drug resistance is unequivocal for adequate treatment of resistant forms of TB. Whole genome sequencing ensures additional knowledge of circulating strains and their resistance patterns. These are essentials of effective TB control programs and can provide evidence to medical and legal authorities for more active policies of screening, involuntary confinement and compliance with therapy, and alternative modalities for successful treatment, as a part of infection control.

Introduction

Global tuberculosis (TB) epidemic is being driven to an increasing extent by the emergence and spread of drug-resistant strains of *Mycobacterium tuberculosis* [1] [2]. Multidrug-resistant TB (i.e. TB resistant to rifampicin and isoniazid, MDR-TB) presents major risk to global tuberculosis control, due to the great discrepancy between real and estimated burden, long-term (18-24 months) and expensive treatment, with less effective and more toxic drugs

then first-line treatment, and low treatment success rate (54% globally) [3] [4] [5] [6].

According to World Health Organization (WHO), of the estimated 600,000 people newly eligible for MDR-TB treatment in 2016 (490,000 cases of MDR-TB and an additional 110,000 with rifampicin-resistant TB, RR-TB), only 129,689 (22%) received appropriate treatment. Of these MDR-TB cases, an estimated 6.2% will develop extensively resistant tuberculosis (i.e. MDR-TB plus resistance to at list one quinolone and list one parenteral anti-tubercular drug, XDR-TB) [6]. Hence, timely and accurate diagnosis of

MDR-TB, particularly among new TB-cases, is essential to initiate appropriate treatment, which can prevent further amplification of drug resistance and break the chain of infection [7].

Exciting developments in the field of molecular diagnosis of TB and drug resistance have led to an era in which rapid testing for TB and rifampicin (RIF) resistance, almost always associated with MDR-TB, have been rolled out on a global scale [8] [9]. The WHO has recommended molecular testing as the standard of care for diagnosis of TB and MDR-TB around the world [8] [10] [11]. Furthermore, recently a new shortened treatment has been introduced for selected MDR-TB patients in terms to the reintegrate optimal balance of adherence and cure of MDR-TB patients, with adverse drug events and overall cost of the treatment [12].

The Republic of Macedonia is a country with a low total number of notified cases of MDR-TB over a ten years period, low incidence of MDR-TB (0.28/100,000 in 2016) and continuously declining TB incidence [6] [13]. However, this enviable epidemiological setting interpreted regarding intensive migration processes in the recent years should raise the vigilance for future.

Here we present a case of primary resistant MDR-TB and most likely imported from abroad, that is particularly useful in highlighting the Macedonian MDR-TB management issues.

Case Report

A 39-year old previously healthy Caucasian male, a smoker, employed as a professional driver on international truck transport, sought medical care at the local hospital due to respiratory bleeding. After initial assessment and supportive treatment, he was referred as an outpatient at referral hospital for TB in Macedonia-the Institute of lung diseases and tuberculosis. Initial examination of two sputum samples showed no presence of acid-fast bacilli (AFB) on fluorescence microscopy, but real-time PCR based molecular method (Xpert MTB/RIF; Cepheid, Sunnyvale CA, USA) confirmed the presence of *Mycobacterium tuberculosis* complex (MTBC) along with detection of RIF resistance (i.e. *rpoB* gene mutation). On patient's request, both analyses were repeated 20 days later in another two samples of sputum, with the same result. By national guidelines and protocol, molecular analyses were extended to testing of susceptibility to isoniazid (INH) and subsequently to second-line anti-tubercular drugs, by using multiplex PCR-based reverse hybridisation Line Probe Assays (LPA). Both assays confirmed the presence of MTBC, revealing mutations of the *rpoB*, *katG* and *InhA* genes, i.e. RIF and INH resistance, as

well as an absence of resistance to second-line anti-tubercular drugs and ethambutol (GenoType MTBDR *plus* and GenoType MTDR*sl*, respectively; Hain Lifescience GmbH, Nehren, Germany). Patient's illness was notified as MDR-TB, and the strain was considered to be multidrug-resistant. In the month that followed, *Mycobacterium tuberculosis* growth was verified with conventional methods in liquid and solid culture (Becton-Dickinson BACTEC MGIT 960 TB system, and Löwenstein Jensen medium, respectively). Resistance to the most important first-line anti-tubercular drugs-RIF and INH- was confirmed by conventional phenotypic drug-susceptibility testing (DST), using the liquid-culture-isolate from the very first sputum sample (Table 1).

Table 1: Microbiological analyses of sputum from the MDR-TB patient during 2016 (before and over the course of treatment)

Date	Sputum specimen	Conventional methods			Molecular methods			
		AFB smear microscopy ^a	Solid medium ^b	Liquid medium ^c	Resistance pattern ^d	Xpert MTB/RIF VG4	HAIN MTBDR <i>plus</i> V2.0	HAIN MTBR <i>sl</i> V1.0
Apr 15	A	Negative	Negative (result released on May 31)	Positive (result released on May 04)	INH - R RIF - R EMB - S SM - S (result released on June 03) ^e	MTB detected, low; RIF resistant (<i>rpoB</i>)		
	B	Negative	Negative (result released on May 31)					
May 04	A	Negative	Positive (2+) (result released on May 31)	Positive (result released on May 16)		MTB detected, low; RIF resistant (<i>rpoB</i>)	INH - R (<i>katG mut2</i>)	FLQ - S AG/CP - S EMB - S
	B	Negative	Negative (result released on May 31)					
May 30	A	Negative	Positive (1+) (result released on Jul 18)	Positive (result released on June 15)				
	B	Negative	Positive (1+) (result released on Jul 18)					
Jun 30	A	Negative	Negative (result released on Aug 22)					
	B	Negative	Negative (result released on Aug 22)					
Aug 22	A	Negative	Negative (result released on Oct 10)					
	B	Negative	Negative (result released on Oct 10)					

Abbreviations: AFB = Acid Fast Bacilli; INH = isoniazid; RIF = rifampicin; EMB = ethambutol; SM = streptomycin; FLQ = fluorochinolones; AG = aminoglycosides; CP = cyclic peptides; MTB = *Mycobacterium tuberculosis*; A = early morning sputum; B = spot sputum specimen; R = resistant; S = sensitive; ^aAuramine-rhodamine staining for fluorescence microscopy (Merck, Darmstadt, Germany); ^bLöwenstein Jensen medium; ^cBACTEC MGIT 960 TB system (Becton-Dickinson); ^dPhenotypic drug-susceptibility test (DST, conventional proportion method on Löwenstein Jensen medium); ^eResistance pattern from the isolate in liquid medium (Apr 15).

Although the patient was repeatedly informed and advised about the seriousness of his health condition and health hazard for his family and community, it took a month and a half before obtaining consent and starting an appropriate anti-tubercular regimen. The major obstacles in this way were the stigma (i.e. denying the presence of disease) and behaved aggressively toward health care providers. At

hospital admission, the patient presented in good health condition, complaining only to rare productive cough. He had no personal or familial history of TB/TB treatment or known close contact, i.e. exposure to TB. Laboratory analyses showed only slightly raised erythrocyte sedimentation rate (ESR) of 36 mm in the first hour, without deviation in complete blood counting and routine blood analyses, and with HIV negative status. Chest X-ray revealed opacity with cavernous lesions in the right upper lobe (Figure 1).

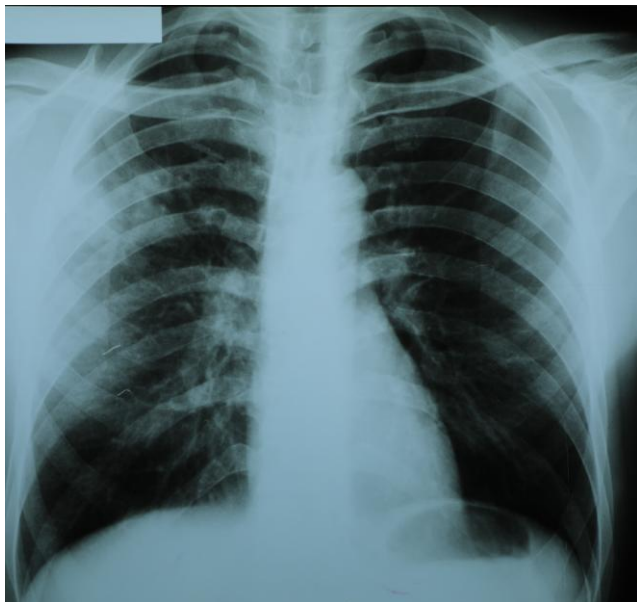


Figure 1: At hospital admission, opacity with cavernous lesions in the right upper lobe

Following the guidelines of the World Health Organization (WHO), we started the so-called longer treatment of MDR-TB composed of at least five effective anti-tubercular drugs. Due to the patient's strictly declining of parenteral drugs, we had to modify the regimen and conduct the intensive phase with three (instead of four) core second-line anti-tubercular drugs (levofloxacin, cycloserine, prothionamide) plus pyrazinamide and ethambutol (i.e. omitting the parenteral aminoglycoside) (Figure 2).

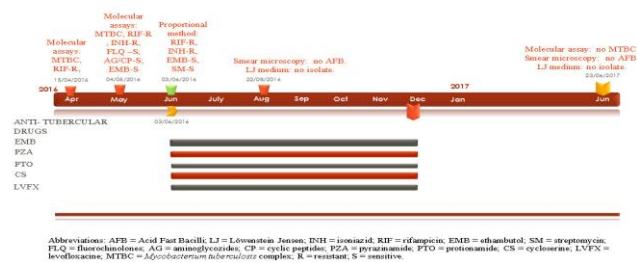


Figure 2: Timetable of therapy

After a month of directly observed therapy (DOT) and isolation in negative pressure room, two follow-up samples of sputum were again smear-negative for AFB, sedimentation rate dropped into the normal range (6 mm in the first hour) and control

chest X-ray showed no regression of changes. The patient was discharged from the hospital against medical advice and advised to continue the intensive phase of the regimen under ambulatory supervision (i.e. monthly control and take up of medicines in the Institute).

Three months after the beginning of the treatment, he stopped making controls. The last available information provided by medical patronage system confirmed that he ceased the therapy early in December 2016. The only control after cessation took place in June 2017: routine laboratory analyses didn't show any deviations, and microbiological examination of two sputum samples (smear microscopy, real-time PCR, liquid and solid medium culture) yielded no positive results. But, the changes in the right upper lobe on chest X-ray were still present, indicating the activity of the process (Figure 3).

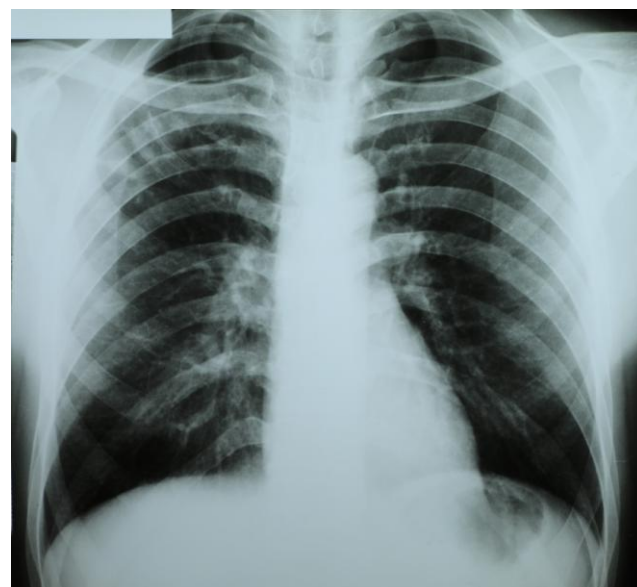


Figure 3: Six months after cessation of treatment: opacity with cavernous lesions and fibrotic changes in the right upper lobe

Discussion

This case report emerges several important issues pertinent to the overall management of MDR-TB.

Sputum smear microscopy is a commonly used test for diagnosis of pulmonary TB in low- and middle-income countries. In addition to the key disadvantage-the low sensitivity of 50-60% - it requires trained staff and at least two sputum samples to analyse while providing no information about drug resistance and distinction of non-tuberculous mycobacteria [14]. In the last decade, WHO set out

the efforts to establish infection control and overcome the problem with drug-resistant forms of TB, by implementing new molecular techniques for detection of *Mycobacterium tuberculosis* complex and drug resistance to anti-tubercular drugs. There are several molecular assays for rapid diagnosis of TB and determination of drug susceptibility profile, endorsed by WHO: Line Probe Assays (LPA) in 2008, and Xpert MTB/RIF assay in 2011 [10] [11]. Shortly after WHO approval, Ling, Zwerling and Pai conducted a meta-analysis to evaluate the performance of most frequently used LPA-GenoType MTBDR [15]. GenoType MTBDR assays demonstrate excellent accuracy for rifampicin resistance (pooled sensitivity and specificity estimates of 98.1% and 98.7%, respectively). While specificity was excellent for isoniazid (99.5%), sensitivity estimates were modest and variable (84.3%). Similarly, the Cochrane review of 27 studies of adults with pulmonary TB, indicated that Xpert MTB/RIF is accurate for detecting rifampicin resistance, sensitive (95%) and specific (98%) [16]. Also, it is more accurate than smear microscopy for diagnosing TB: it is highly sensitive (89%), detecting almost all cases, and specific (99%). Authors concluded that Xpert MTB/RIF provides accurate results which can allow rapid initiation of MDR-TB treatment, pending results from conventional culture and DST. Likewise, the latest release of WHO Manual for Xpert MTB/RIF implementation (2014) contains an extended recommendation for implementing the Xpert MTB/RIF assay, i.e. to be used rather than conventional microscopy and culture as an initial diagnostic test in all adults suspected of having TB [17].

Our case is a good confirmation of accuracy, precision and reproducibility of TB molecular diagnostic tests. Determined by two different molecular (genotyping) methods, drug resistance profile was identical in two separate sputum samples and subsequently confirmed by conventional DST. This gains importance when making therapy decision, especially if based only on conventional methods. Due to sputum low bacterial load (i.e. AFB negative on fluorescence microscopy), one should wait for the culture results (2-6 weeks) to start anti-tubercular therapy, and another 6 weeks to modify the regimen respecting the results of conventional DST. Conversely, molecular tests used in our case allow detection of MTB and RIF resistance in 2 hours, and detection of MTB and resistance to first-and second-line anti-tubercular drugs in 24 hours [15] [18]. This emphasises the importance of molecular tests for the timely and accurate diagnosis of TB and resistance pattern, particularly in smear-negative microscopy [6] [8] [19] [20].

Drug resistance in MTBC is caused by mutations in restricted regions of its genome [21] [22]. As technical possibilities in our laboratory don't allow sequencing of drug-resistance associated regions of MTBC genome and subsequent detailed description

of mutations, detection is limited to mutations already included in molecular tests mentioned above. In terms of this, a clinician must count on occasional false-positive RIF-resistance result on molecular test, which has to be promptly resolved as it seriously implicate therapy decision-to start first line anti-tubercular regimen and take the risk of resistance amplification to pyrazinamide and ethambutol, to conduct the lengthy and much more toxic MDR-TB treatment, or to defer starting any treatment while awaiting results of DST? [23] [24] [25] [26]. This complex problem could be overcome by advanced genotyping methods (DNA fingerprinting, whole genome sequencing). Studying the isolates at molecular level allows not only detection of MTBC and mutations in genes associated with drug resistance, but also discrimination between MTBC strains, distinction of co-infection with multiple strains, endogenous reactivation and exogenous reinfection, existence of subpopulations with different resistance profiles, assessing the possible treatment failure, as well as clustering of isolates to particular genotype family databases (sequencing libraries from genomic DNA)-which may implicate pathogenesis, virulence, propensity to acquire resistance more easily under conditions of suboptimal treatment, and to spread in the community [27] [28] [29] [30] [31] [32] [33]. The importance of former molecular tools for epidemiological tracking in the community (i.e. detecting the sources of infection, pathways of spread of MTBC strains, distinct geographic distribution) is unequivocal and has made the worldwide designing of prevention and control strategies to block further transmission possible [34].

The low bacterial load in spot sputum samples shouldn't underestimate the possibility of variable bacillary as a function of time, and so the persistence of the chain of infection [35]. Occasional sputum positivity in our patient is very likely, considering subjective sample collection for smear microscopy from a non-cooperative person. Moreover, due to negligent patient behaviour (postponing of hospital admission, shortening the regimen much earlier), we have to anticipate not only deterioration of his health condition over time, but the potential prolonged exposure of the environment to MDR-strain of *Mycobacterium tuberculosis* [18]. As the number of MDR-TB cases continues to rise worldwide, so does the amplification of MDR-TB strains during treatment. This amplification is generally assumed as a result from in vivo evolution of drug resistance caused by poor therapy compliance and/or inadequate treatment, considering the prior anti-TB treatment is a major risk factor associated with MDR-TB [7] [22] [36] [39]. Given the fact that our patient had no history of TB or TB treatment, nor he has other apparent risk factors or contacts for TB, it was reasonable to consider the case as TB with primary multidrug resistance [27] [28] [34] [40] [41]. To make the situation even more serious, our patient requested modification of intensive phase of the anti-tubercular regimen, and interrupted it early in the course, before initiation of

continuation phase. It has to be stressed that extreme non-adherence like this, could further compromise the infection control in an international context (i.e. continuous transmission of infection, additional acquisition of drug resistance via “amplification of resistance” and subsequent developing an XDR) [18] [34] [41].

This emphasises the critical importance of clinical monitoring during DOT, introduced and recommended by WHO [30] [42]. However, there are some articles, mainly from the African continent, reporting on the successful alternative modality of treatment of smear-positive pulmonary TB and MDR-TB instead of conventional DOT strategy. The essence of this home-based “family-member variant of DOT” approach, is to involve a reliably family-member with responsibility of providing appropriate conditions (i.e. isolation, natural ventilation), supplying and directly supervising the taking of medicines on regular basis, and providing feedback about patient’s condition to his attending physician [43] [44]. Although this kind of practice is primarily related to resource-limited settings and is not anticipated in current Program for TB control in Macedonia, it certainly deserves attention in future for extreme cases as we presented here.

The previous issue raises the crucial ethical dilemma: how to deal with dual standards and protect the human rights of the minority (i.e. non-adherent TB patient)-at the expense of majority (i.e. community)? Patients generally have the right to refuse to follow professional medical advice. Those with infectious TB disease, however, “may lose the right to refuse such advice if health officials believe these persons are putting the public at risk for infection” [45]. There are rare situations where, despite all reasonable efforts, patients do not adhere to the prescribed course of treatment, or are unwilling or unable to comply with infection prevention and control measures. For such cases, the interests of other members of the community may justify efforts to isolate the patient involuntarily, by a pre-existing law or policy. WHO states that involuntary isolation should never be a routine component of TB-program. Involuntary isolation should be limited to exceptional circumstances, concerning infectiousness and non-adherence of a patient to effective treatment, and after all reasonable measures to ensure adherence have been attempted and proven unsuccessful [46]. Governments have the legal authority to enact laws regarding infectious persons, and TB programs should develop policies in line with the guidance that clearly explains when and how involuntary isolation of TB patients is allowable. Some countries have already implemented the option for legal intervention, i.e. involuntary confinement in such cases [47] [48]. In our country, there is still no solution within the framework of existing legislation regarding involuntary isolation and compliance with the recommended combination of drugs, as well as interruption of therapy.

In the transmission of resistant strains, the greatest individual risk factor is sharing living quarters with individuals who have defaulted on their treatment of TB or relapse cases [49]. Fortunately, close contact screening among household members (spouse, and two children aged 3 and 7) showed no presence of latent tuberculosis infection (LTBI) or active TB. Nevertheless, it raises the question of preventive treatment for contacts with MDR-TB, especially when children involved in this problem, as well as the duration of the follow-up period. The current modest recommendation reflects the limited quality of evidence and comes down to strict clinical observation and close monitoring for the development of active TB for at least two years for contacts with MDR-TB cases [50].

In conclusion, the benefit of molecular tests in the early diagnosis of TB and drug resistance is unequivocal for adequate and in time treatment of resistant forms of TB. Whole genome sequencing of pathogens, also, is becoming part of routine practice for establishing resistance patterns and transmission tracking. To sum up, the current comprehensive technology has the power to clarify our understanding of the links in MDR-TB transmission between low- and high-incidence areas. Given these points, our report implies that MDR-TB represents not just a regional epidemic in some parts of the world, but also a challenge to international health, including countries with low prevalence of MDR-TB. Knowledge of circulating strains and their resistance patterns is essential to developing effective TB control programs within occupational health, to curtail the transmission of TB in the country and the region. The greater certainty of transmission data can provide evidence to justify more active policies of screening and isolation as part of infection control. Increased vigilance for TB among workers whose job description includes frequent border crossing should be surely taken into consideration as a part of these screening policies. Finally, we believe an urgent need is existing for in-depth discussion between medical and legal authorities about the problem of involuntary confinement and enforced treatment of non-adherent patients. While waiting for the legal resolution of this ethical and social problem, clinicians should consider alternative modalities for the successful treatment of patients with MDR-TB and protect the patients themselves, their families and the community. Regarding this, foreign experience in home-based DOT could be adapted to local conditions and would be a good starting point in moving forward.

Acknowledgement

This article was written as a part of the doctoral thesis regarding the use of molecular tests for TB in the Republic of Macedonia.

References

- Outhred AC, Jelfs P, Suliman B, Hill-Cawthorne GA, Crawford AB, Marais BJ, Sintchenko V. Added value of whole-genome sequencing for management of highly drug-resistant TB. *Journal of Antimicrobial Chemotherapy*. 2014; 70(4):1198-202. <https://doi.org/10.1093/jac/dku508>
- Abubakar I, Zignol M, Falzon D, Raviglione M, Ditiu L, Masham S, Adetifa I, Ford N, Cox H, Lawn SD, Marais BJ. Drug-resistant tuberculosis: time for visionary political leadership. *The Lancet infectious diseases*. 2013; 13(6):529-39. [https://doi.org/10.1016/S1473-3099\(13\)70030-6](https://doi.org/10.1016/S1473-3099(13)70030-6)
- Falzon D, Gandhi N, Migliori GB, et al. Resistance to fluoroquinolones and second-line injectable drugs: impact of multi-drug resistant TB outcomes. *Eur Respir J*. 2013; 42(1):156-168. <https://doi.org/10.1183/09031936.00134712> PMID:23100499 PMID:PMC4487776
- Diel R, Vandeputte J, de Vries G, et al. Costs of tuberculosis disease in the European Union: a systematic analysis and cost calculation. *Eur Respir J*. 2014; 43(2):554-565. <https://doi.org/10.1183/09031936.00079413> PMID:23949960
- Garrido MS, Talhari AC, Antunes IA, Matsuda JD, Zaranza ED, Martinez-Espinosa FE, Bühner-Sékula S. Primary multidrug-resistant tuberculosis and its control implications in the State of Amazonas, Brazil: report of 3 cases. *Revista da Sociedade Brasileira de Medicina Tropical*. 2012; 45(4):530-2. <https://doi.org/10.1590/S0037-86822012000400024> PMID:22930053
- World Health Organization. Global tuberculosis report 2017. Geneva, Switzerland: World Health Organization, 2017.
- Munir MK, Rehman S, Iqbal R, Saeed MS. Development of MDR TB in short duration in a patient receiving treatment for simple TB: a case report. *Annals of King Edward Medical University*. 2015; 21(4):301. <https://doi.org/10.21649/akemu.v21i4.779>
- Jonsson G, Furin J. Will molecular diagnosis of drug-resistant tuberculosis improve patient outcomes? [Perspectives]. *The International Journal of Tuberculosis and Lung Disease*. 2012; 16(1):4-5. <https://doi.org/10.5588/ijtld.11.0419> PMID:22236840
- Boehme CC, Nabeta P, Hillemann D, Nicol MP, Shenai S, Krapp F, Allen J, Tahirli R, Blakemore R, Rustomjee R, Milovic A. Rapid molecular detection of tuberculosis and rifampin resistance. *New England Journal of Medicine*. 2010; 363(11):1005-15. <https://doi.org/10.1056/NEJMoa0907847> PMID:20825313 PMID:PMC2947799
- World Health Organization. Policy Statement: Molecular line probe assays for rapid screening of patients at risk of multidrug-resistant tuberculosis (MDR-TB). Geneva, Switzerland: World Health Organization, 2008.
- World Health Organization. Rapid Implementation of the Xpert MTB/RIF diagnostic test. Technical and Operational 'How-to' Practical considerations. Geneva, Switzerland: World Health Organization, 2011.
- World Health Organization. WHO treatment guidelines for drug-resistant tuberculosis, 2016 update. October 2016 revision. Geneva, Switzerland: World Health Organization, 2016.
- European Centre for Disease Prevention and Control/WHO Regional Office for Europe. Tuberculosis surveillance and monitoring in Europe 2016. Stockholm, Sweden: European Centre for Disease Prevention and Control, 2016.
- Siddiqi K, Lambert ML, Walley J. Clinical diagnosis of smear-negative pulmonary tuberculosis in low-income countries: the current evidence. *The Lancet infectious diseases*. 2003; 3(5):288-96. [https://doi.org/10.1016/S1473-3099\(03\)00609-1](https://doi.org/10.1016/S1473-3099(03)00609-1)
- Ling D, Zwerling A, Pai M. Genotype MTBDR assays for the diagnosis of multidrug-resistant tuberculosis: a meta-analysis. *Eur Respir J*. 2008; 32:1165-74. <https://doi.org/10.1183/09031936.00061808> PMID:18614561
- Steingart KR, Schiller I, Horne DJ, Pai M, Boehme CC, Dendukuri N. Xpert® MTB/RIF assay for pulmonary tuberculosis and rifampicin resistance in adults. *The Cochrane database of systematic reviews*. 2014; 21(1):1. <https://doi.org/10.1002/14651858.CD009593.pub3>
- World Health Organization. Xpert MTB/RIF implementation manual. Technical and operational 'how-to': practical considerations. Geneva, Switzerland: World Health Organization, 2014.
- Atre S. An urgent need for building technical capacity for rapid diagnosis of multidrug-resistant tuberculosis (MDR-TB) among new cases: A case report from Maharashtra, India. *J Infect Public Health*. 2015; 8(5):502-5. <https://doi.org/10.1016/j.jiph.2015.04.021> PMID:25956026
- Ioannidis P, Papventsis D, Karabela S, Nikolaou S, et al. Cepheid GeneXpert MTB/RIF assay for Mycobacterium tuberculosis detection and rifampin resistance identification in patients with substantial clinical indication of tuberculosis and smear-negative microscopy results. *J Clin Microbiol*. 2011; 49:3068-70. <https://doi.org/10.1128/JCM.00718-11> PMID:21677069 PMID:PMC3147726
- Yano S, Kobayashi K, Ikeda T. Reminder of important clinical lesson: Multidrug-resistant tuberculosis that required 2 years for diagnosis. *BMJ case reports*. 2012; 2012.
- Zhang Y, Telenti A. Genetics of drug resistance in Mycobacterium tuberculosis. In: Hatfull G, Jacobs W R, eds. *Molecular genetics of Mycobacteria*. Washington DC, USA: ASM Press, 2000: 235-254.
- Meacci F, Orrù G, Iona E, et al. Drug Resistance Evolution of a Mycobacterium tuberculosis Strain from a Noncompliant Patient. *J Clin Microbiol*. 2005; 43(7):3114-3120. <https://doi.org/10.1128/JCM.43.7.3114-3120.2005> PMID:16000422 PMID:PMC1169130
- Van Rie A, Mellet K, John M-A, et al. False-positive rifampicin resistance on Xpert® MTB/RIF: case report and clinical implications. *Int J Tuberc Lung Dis*. 2012; 16(2): 206-8. <https://doi.org/10.5588/ijtld.11.0395> PMID:22236921 PMID:PMC3680645
- Boehme CC, Nicol MP, Nabeta P, Michael JS, Gotuzzo E, Tahirli R, Gler MT, Blakemore R, Worodria W, Gray C, Huang L. Feasibility, diagnostic accuracy, and effectiveness of decentralised use of the Xpert MTB/RIF test for diagnosis of tuberculosis and multidrug resistance: a multicentre implementation study. *The Lancet*. 2011; 377(9776):1495-505. [https://doi.org/10.1016/S0140-6736\(11\)60438-8](https://doi.org/10.1016/S0140-6736(11)60438-8)
- Marlowe EM, Novak-Weekley SM, Cumpio J, et al. Evaluation of the Cepheid Xpert MTB/RIF assay for direct detection of Mycobacterium tuberculosis complex in respiratory specimens. *J Clin Microbiol*. 2011; 49(4):1621-3. <https://doi.org/10.1128/JCM.02214-10> PMID:21289151 PMID:PMC3122817
- Hoek KG, Schaaf HS, Gey van Pittius NC, et al. Resistance to pyrazinamide and ethambutol compromises MDR/XDR-TB treatment. *S Afr Med J*. 2009; 99(11):785-7. PMID:20218473
- Pfiffer GE, Strässle A, Brändli O, Shang H. Three Episodes of Tuberculosis—To Multidrug Resistance and Back to Susceptibility. *Clinical infectious diseases*. 1998; 26(1):219-20. <https://doi.org/10.1086/517030> PMID:9455558
- Turett GS, Fazal BA, Justman, JE, Alland D, Duncalf RM, and Telzak EE. Exogenous Reinfection with Multidrug-Resistant Mycobacterium tuberculosis. *Clin Inf Dis*. 1997; 24:513-4. <https://doi.org/10.1093/clinids/24.3.513>
- Singh A, Gopinath K, Sharma P, et al. Comparative proteomic analysis of sequential isolates of Mycobacterium tuberculosis from a patient with pulmonary tuberculosis turning from drug sensitive to multidrug resistant. *Indian J Med Res*. 2015; 141(1): 27-45. <https://doi.org/10.4103/0971-5916.154492> PMID:25857493 PMID:PMC4405938
- Mendez MP, Landon ME, McCloud MK, Davidson P, Christensen PJ. Co-infection with pansensitive and multidrug-

- resistant strains of *Mycobacterium tuberculosis*. *Emerging infectious diseases*. 2009; 15(4):578. <https://doi.org/10.3201/eid1504.080592> PMID:19331736 PMCid:PMC2671451
31. Williams OM, Abeel T, Casali N, Cohen K, Pym AS, Mungall SB, Desjardins CA, Banerjee A, Drobniowski F, Earl AM, Cooke GS. Fatal nosocomial MDR TB identified through routine genetic analysis and whole-genome sequencing. *Emerging Infectious Diseases*. 2015; 21(6):1082. <https://doi.org/10.3201/eid2106.141903> PMID:25988581 PMCid:PMC4451893
32. Diarra B, Siddiqui S, Sogoba D, Traore B, Maiga M, Washington J, Tounkara A, Polis MA. *Mycobacterium tuberculosis* Beijing Strain, Bamako, Mali. *Emerging infectious diseases*. 2010; 16(2):362. <https://doi.org/10.3201/eid1602.090501> PMID:20113590
33. Ahmad S. Molecular fingerprinting reveals familial transmission of rifampin-resistant tuberculosis in Kuwait. *Ann Saudi Med*. 2005; 25(2):150-3. PMID:15977695
34. Umubyeyi A, Shamputa IC, Rigouts L, Dediste A, Struelens M, Portaels F. Evidence of 'amplifier effect' in pulmonary multidrug-resistant tuberculosis: report of three cases. *International journal of infectious diseases*. 2007; 11(6):508-12. <https://doi.org/10.1016/j.ijid.2007.01.009> PMID:17376726
35. Tostmann A, Kik SV, Kalisvaart NA, Sebek MM, Verver S, Boeree MJ, van Soolingen D. Tuberculosis transmission by patients with smear-negative pulmonary tuberculosis in a large cohort in the Netherlands. *Clinical Infectious Diseases*. 2008; 47(9):1135-42. <https://doi.org/10.1086/591974> PMID:18823268
36. Hingley-Wilson SM, Casey R, Connell D, Bremang S, Evans JT, Hawkey PM, Smith GE, Jepson A, Philip S, Kon OM, Lalvani A. Undetected multidrug-resistant tuberculosis amplified by first-line therapy in mixed infection. *Emerging infectious diseases*. 2013; 19(7):1138. <https://doi.org/10.3201/eid1907.130313> PMID:23764343 PMCid:PMC3713993
37. Maia KRO, de Castro Viana GM, Custódio Neto da Silva MA, do Desterro Soares Brandão Nascimento M, de Souza VL, Monteiro SG. Resistant tuberculosis in Maranhão, Brazil: a case series. *BMC Res Notes*. 2016; 9:260. <https://doi.org/10.1186/s13104-016-2063-x> PMID:27145827 PMCid:PMC4857409
38. Sharma SK, Mohan A. Multidrug-resistant tuberculosis: a menace that threatens to destabilize tuberculosis control. *Chest*. 2006; 130(1):261-72. [https://doi.org/10.1016/S0012-3692\(15\)50981-1](https://doi.org/10.1016/S0012-3692(15)50981-1)
39. Toyota E, Sekiguchi JI, Shimizu H, et al. Further acquisition of drug-resistance in multidrug-resistant tuberculosis during chemotherapy. *Jpn J. Infect. Dis*. 2004; 57: 292-294. PMID:15623961
40. Tiberi S, D'Ambrosio L, De Lorenzo S, Viggiani P, Centis R, Migliori GB. Tuberculosis elimination, patients' lives and rational use of new drugs: revisited. *European Respiratory Journal*. 2016; 47(2): 664-7. <https://doi.org/10.1183/13993003.01297-2015> PMID:26541536
41. Jeyakumar D. A case of primary drug resistant tuberculosis. *Med J Malaysia*. 2000; 55 (1): 129-31. PMID:11072497
42. Elkomy H, Awad M, El-Shora A, Elsherbeni B. Assessment of the efficacy of Directly Observed Treatment with short course (DOTS) for pulmonary tuberculosis in Sharkia governorate. *Egyptian Journal of Chest Diseases and Tuberculosis*. 2013; 62(2):257-61. <https://doi.org/10.1016/j.ejcdt.2013.04.003>
43. Igbudu TJ, Egwuda L, Mbaave TP. Family-Member Variant of Directly Observed Therapy Short Course (DOTS) in Current Pulmonary Tuberculosis (PTB) Management: A Way Out in Resource-Constrained Settings – A Case Report. *Int J Med Res*. 2015; 3(3): 13-15. <https://doi.org/10.5455/ijmr.20160724051241>
44. Luyirika E, Nsohya H, Batamwita R, Busingye P, Musoke W, Nabiddo L, Karamagi Y, Mukasa B. A home-based approach to managing multi-drug resistant tuberculosis in Uganda: a case report. *AIDS research and therapy*. 2012; 9(1):12. <https://doi.org/10.1186/1742-6405-9-12> PMID:22524486 PMCid:PMC3349607
45. Centers for Disease Control and Prevention. Patient adherence to tuberculosis treatment, 1999. Available at: http://www.heartlandnhtbc.org/assets/training/mini-fellowship/PediatricToolBox/CDC/ed_training/publications/ssmodules/pdfs/9.pdf (Accessed January 8, 2018).
46. World Health Organization. Ethics guidance for the implementation of the End TB strategy. Geneva, Switzerland: World Health Organization, 2017.
47. Muigano MN. Involuntary detention and compulsory treatment of non-adherent tuberculosis patients in Kenya: an ethical discourse. *Int J Community Med Public Health*. 2016; 3(9):2677-2682. <https://doi.org/10.18203/2394-6040.ijcmph20163095>
48. Weiler-Ravell D, Leventhal A, Coker RJ, Chemtob D. Compulsory detention of recalcitrant tuberculosis patients in the context of a new tuberculosis control programme in Israel. *Public health*. 2004; 118(5):323-8. <https://doi.org/10.1016/j.puhe.2003.10.005> PMID:15178138
49. Becerra MC, Appleton SC, Franke MF, Chalco K, Arteaga F, Bayona J, Murray M, Atwood SS, Mitnick CD. Tuberculosis burden in households of patients with multidrug-resistant and extensively drug-resistant tuberculosis: a retrospective cohort study. *The Lancet*. 2011; 377(9760):147-52. [https://doi.org/10.1016/S0140-6736\(10\)61972-1](https://doi.org/10.1016/S0140-6736(10)61972-1)
50. WHO, World Health Organization. Guidelines on the management of latent tuberculosis infection. World Health Organization, 2015.