

# Frontal Sinus Obliteration Utilizing Autogenous Abdominal Fat Graft

Abla Eledeissi<sup>1\*</sup>, Mamdouh Ahmed<sup>2</sup>, Emad Helmy<sup>2</sup>

<sup>1</sup>Oral and Maxillofacial Surgery Department, Nasser Institute Hospital, Cairo, Egypt; <sup>2</sup>Oral and Maxillofacial Surgery Department, Faculty of Oral and Dental Medicine, Cairo University, Cairo, Egypt

## Abstract

**Citation:** Eledeissi A, Ahmed M, Helmy E. Frontal Sinus Obliteration Utilizing Autogenous Abdominal Fat Graft. Open Access Maced J Med Sci. <https://doi.org/10.3889/oamjms.2018.295>

**Keywords:** Frontal sinus fractures; Frontal sinus obliteration; Abdominal fat graft

**\*Correspondence:** Abla Eledeissi. Oral and Maxillofacial Surgery department, Nasser Institute Hospital, Cairo, Egypt. E-mail: [ablaedc@hotmail.com](mailto:ablaedc@hotmail.com)

**Received:** 20-Apr-2018; **Revised:** 03-Jul-2018; **Accepted:** 05-Jul-2018; **Online first:** 21-Jul-2018

**Copyright:** © 2018 Abla Eledeissi, Mamdouh Ahmed, Emad Helmy. This is an open-access article distributed under the terms of the Creative Commons Attribution-NonCommercial 4.0 International License (CC BY-NC 4.0).

**Funding:** This research did not receive any financial support.

**Competing Interests:** The authors have declared that no competing interests exist.

**BACKGROUND:** Frontal sinus fractures have always been unique because of the controversy surrounding their ideal treatment protocol and the fatal complications that could follow if the wrong treatment opts.

**AIM:** The purpose of this study was to assess clinically and radiographically frontal sinus obliteration technique utilising autogenous abdominal fat graft.

**PATIENTS AND METHODS:** This study was carried out on 20 patients having anterior table fracture of their frontal sinuses indicated for sinus obliteration. All sinuses were obliterated using autogenous abdominal fat graft. Post-operatively, patients were clinically evaluated for any signs or symptoms of intracranial infections, wound dehiscence, sinus affections, or aesthetic deformity. Computerized tomography (CT) radiographic evaluations were carried out immediately and 12 months postoperatively to evaluate any uneventful healing of the graft.

**RESULTS:** Clinical follow-up showed no cerebrospinal fluid leak, no postoperative infection or wound dehiscence in 18 cases. There were two cases however that showed infection. Radiographic follow-up revealed uneventful healing of the abdominal fat grafts with no abnormality detected in the sinus cavity throughout the whole postoperative period.

**CONCLUSION:** Autogenous abdominal fat graft appears to be a successful obliteration material in the frontal sinus cavity and is beneficial in fractures of the anterior table.

## Introduction

Frontal sinus fractures represent a challenge and are relatively infrequent. The incidence of frontal sinus fracture ranges from 2% to 15% of all facial fractures [1] [2]. Restoring esthetics and function and preventing complications to the frontal sinus and other critical related structures are the major objectives intended in the treatment of frontal sinus injuries. Reported complications included chronic sinusitis, meningitis, brain abscess and mucocele formation [3] [4] [5] [6].

One of the most commonly accepted management algorithms is that proposed by Rohrich and Hollier in 1992 [7] Injury of the nasofrontal duct and CSF leak were the key determinants in deciding

the treatment plan in this algorithm. Rohrich and Hollier suggested that patients with frontal sinus fractures were treated in four different ways based on the type of injury: 1 no surgical intervention, when the fractures were non comminuted, nondisplaced, not accompanied by cerebrospinal fluid leaks, and not involving the nasofrontal duct; 2 open reduction and internal fixation of the anterior table with sinus preservation in patients with fractures not involving the nasofrontal duct; 3 open reduction and internal fixation of the anterior table with sinus obliteration in fractures involving the nasofrontal duct; and 4 cranialization, when the posterior table had to be removed during exploration of intracranial lesions [3].

It is well agreed in all treatment protocols proposed in the literature that violation of the nasofrontal duct requires sinus obliteration.

Obliteration consists of eliminating the frontal sinus cavity while maintaining the anterior and posterior tables [8].

Various materials both autogenous and alloplastic have been advocated in the literature with varying degrees of success for the obliteration of the frontal sinus and the nasofrontal ducts. These include adipose tissue, bone, temporalis fascia, gelfoam pericranium, bio-glass, oxidised cellulose and others [8] [9]. Although each graft material has its merits and perils, autogenous grafts are favoured over allogeneic materials because of their generous clinical history and positive long-term treatment results [10].

Bergara and Itoiz [11] endorsed the use of autogenous fat for obliterating the frontal sinus. They showed that viable implanted adipose tissue along with the meticulous removal of the sinus lining mucosa typically prevented regrowth of the mucoperiosteum. After Bergara's proposition, autogenous fat has been approved as a reliable material for obliterating the frontal sinus and had been widely used.

The purpose of our study was to evaluate the abdominal fat graft and assess its complication rates when used as an obliteration material in the frontal sinus obliteration technique.

## Materials and Methods

The present study was conducted on 20 adult patients admitted to the Cranio-Maxillofacial Surgery Department, Nasser Institute hospital and faculty of Oral and Dental Medicine, Cairo University. The criteria for patient selection included fractures indicated for duct obstruction and frontal sinus obliteration. These included anterior table frontal sinus fractures associated with injury to the nasofrontal duct with no or little involvement of the posterior table (not requiring cranialization).

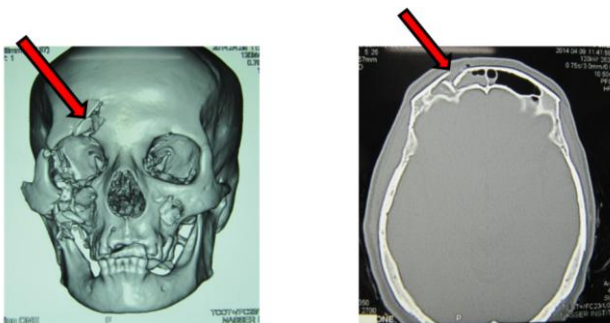


Figure 1: a) Preoperative 3D CT showing a right side anterior table fracture of the frontal sinus with comminuted right ZMC and orbital floor Fracture; b) An axial cut CT showing the unilateral displaced anterior table fracture of the right frontal sinus cavity

General rules of emergency care were applied to all patients presented to the emergency department. Frontal sinus fractures were assessed as part of general head injury evaluation. Neurological and ophthalmological consultations were performed to rule out associated injuries.

Computed tomography (CT) was done for all patients with coronal, axial, sagittal and 3-dimensional reconstructions preoperatively. Based on radiographic findings, the degree of injury to the anterior and posterior tables as well as the nasofrontal duct was determined (Figure 1a, b).

All surgical procedures were performed under general anaesthesia. Exposure of the sinus was done via a bi-coronal incision or through an existing laceration (Figure 2).

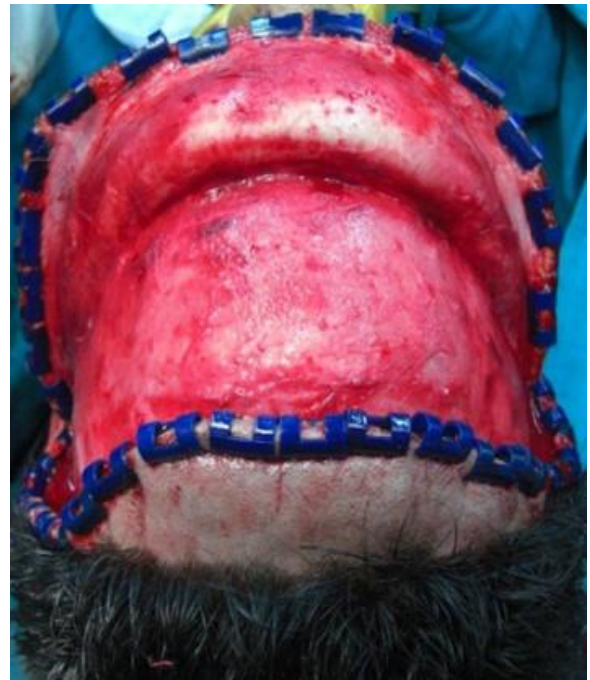

Figure 2: Coronal incision and dissection in the subgaleal plane from one superior temporal line to the other and flap reflection to approach the fractured frontal sinus

The fractured anterior table fragments were removed and debrided of any mucosal linings with rotary drill under copious irrigation and stored in normal saline. The frontal sinus cavity was then addressed where debridement of the sinus membrane was performed using curette then a bur for curettage of the bony cavity of the sinus together with the removal of the inner cortex of the sinus wall to remove any invaginations of the sinus membrane from the foramina of Breschet (Figure 3).

The nasofrontal ducts were finally obstructed using either pericranium, temporalis muscle, or fascia together with bone chips.

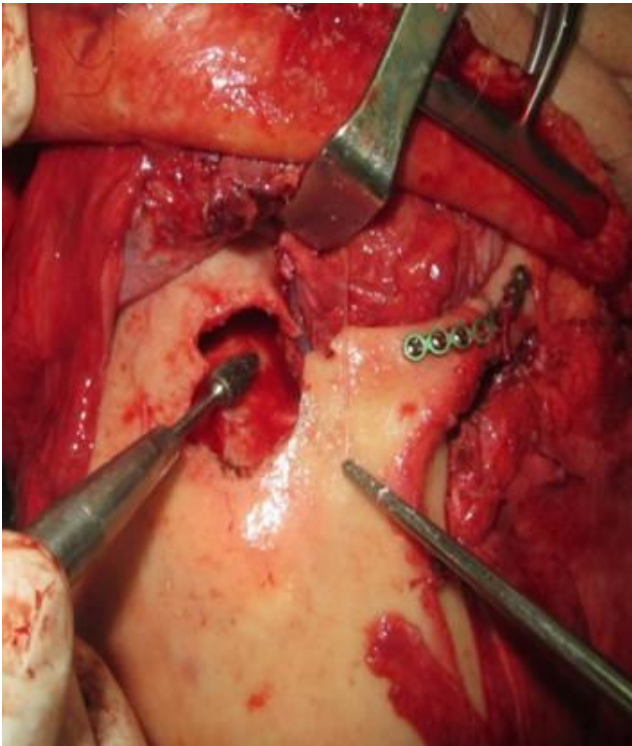


Figure 3: After anterior table removal, the frontal sinus membrane and the nasofrontal duct epithelium were removed with rotary bur

Harvesting the abdominal fat graft was performed using a 4 cm transverse, midline or side incision below the umbilicus (Figure 4a). An appropriate amount of fat was harvested and the wound closed by subcutaneous and skin sutures. The harvested fat was then used to obliterate the sinus (Figure 4b).

Finally, the anterior table was reconstructed using a 1.0 or 1.5 mm plating system or a titanium mesh depending on the degree of comminution (Figure 5). The bi-coronal incision or the forehead laceration was closed in layers, and a pressure dressing was placed for 48 hours. A drain was placed whenever a bi-coronal incision was used.

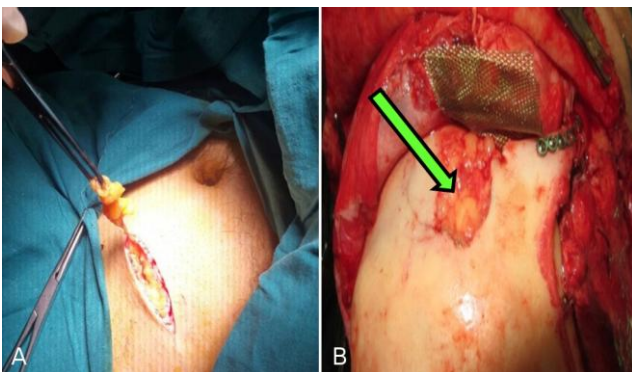


Figure 4: a) Harvesting of the abdominal fat graft using a 4cm transverse side incision below the umbilicus; b) Frontal sinus right side cavity obliteration with abdominal fat graft

Immediately post-operatively, patients were

given antibiotics (Amoxicillin/Clavulanate Potassium) 1.2 gm, every 12 hours for 5 days, steroids (Dexamethasone) 8 mg, 4 times daily then gradually withdrawn in the following days according to a standard protocol, and methylprednisolone acetate 80 mg intramuscular injection once with the last dose of dexamethasone.

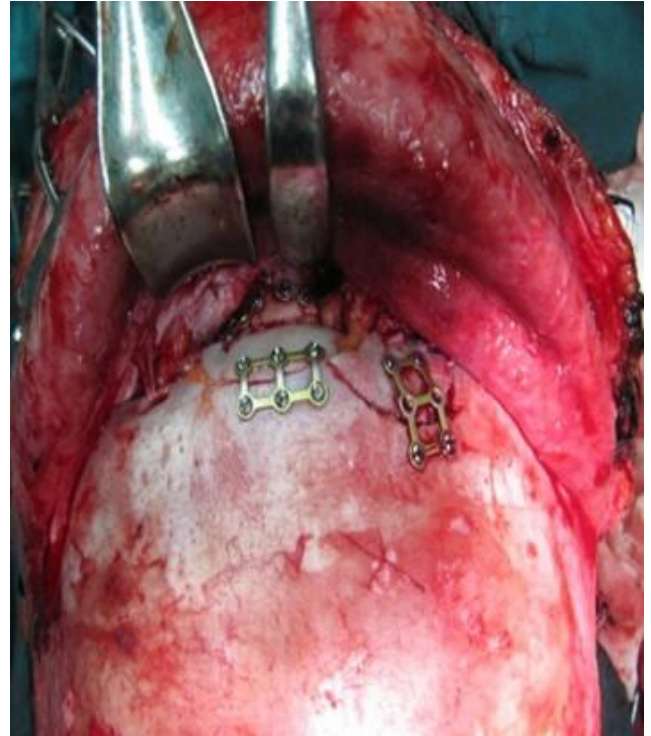


Figure 5: Reduction of anterior table fragments of the fractured frontal sinus and rigid fixation with plates and screws

Analgesics (Diclofenac sodium) were also given twice daily for a week. Antihistaminics (Loratadine) twice daily for five days following the surgery, and nasal decongestants (Oxymetazoline), nasal drops 3 times daily were also prescribed.

Patients were discharged 3 days after their surgery, during this time at their stay at the hospital, they were seen every day and clinically evaluated (days 1 to 3). They were then seen after 1 week from the day of discharge (week 1) then 1 week afterwards (week 2) followed by a visit after 6 months and finally after 12 months.

The postoperative clinical evaluation was carried out to evaluate the following: intracranial Infections (brain abscess or meningitis), Wound Infection, osteomyelitis, wound dehiscence, aesthetic deformity and sinus affections (sinusitis, mucocele, pyomucocele). Radiographic evaluation was done using computerised tomography (CT) scanning immediately and at 12 months postoperatively. Cases were considered radiographically successful when sinuses were free of pathology, and the anterior table was correctly reduced.

## Results

This study included 20 adult patients (18 males and 2 females) with the mean age of 29.5 years (19-50). The mechanism of injury was road traffic accident in 18 patients, and two patient's injury was a result of a fall from height.

In the current study, isolated anterior table fracture of the sinus was found in half of the patients (10 patients) while combined anterior and posterior fractures were found in the other half (10 patients). Eighteen frontal sinuses were approached through a coronal incision, and two approached through an existing laceration.

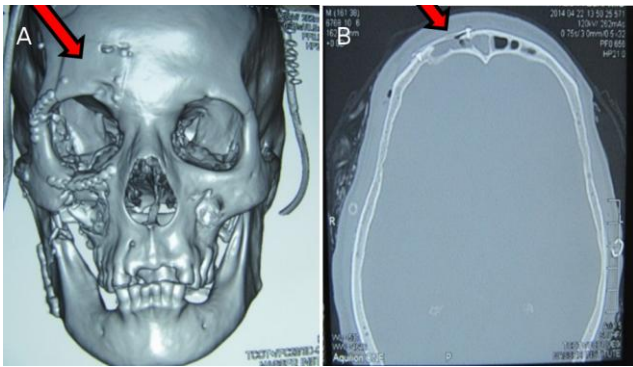


Figure 6: a) 3D CT showing titanium mesh reconstruction of the anterior table of frontal sinus and reduction and fixation of the right ZMC with plates and screws; b) Immediate Postoperative Axial CT, showing a reduced anterior table of the frontal sinus and fat in the sinus cavity

Clinical follow-up showed no signs of infection or wound dehiscence in 18 cases while two cases were infected at 1 and 2 weeks postoperatively with oedema and pus oozing through the wound. Those cases showed no signs of infection pre-operatively. In both cases, the sinus was approached through an existing laceration. The treatment consisted of incision and drainage, irrigation and antibiotic treatment with an uneventful course afterwards. No CSF leak or mucocoeles were observed during the 1 year follow-up period in any of the twenty cases. Radiographically, all the abdominal fat grafts underwent uneventful healing, and no abnormality was detected in the sinus cavity throughout the whole postoperative period (Figure 6a, b). One year follow-up showed no evidence of complications, bone occupying lesions or infection (Figure 7).

## Discussion

Frontal sinus trauma is a heated topic because there are considerable controversy and dispute in the literature regarding what defines the

“appropriate” management. Recommended treatment principles are aiming at restoring the preoperative frontal contour and facial aesthetics, isolating the brain and preventing any CSF leak, and preventing early and avoiding delayed postoperative complications from the central nervous system [12].

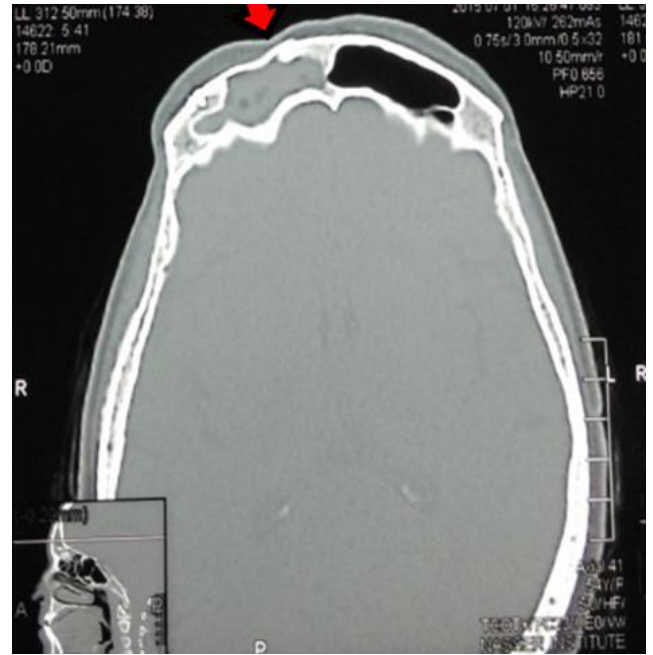


Figure 7: One year postoperative axial CT showing no evidence of complications, bone occupying lesions or infection, good maintenance of fat graft volume and complete frontal sinus obliteration after repair of the right frontal sinus cavity, and good drainage of the non-operated left side sinus cavity

In the past, physical examination in combination with plain films were the key tools in diagnosing frontal sinus fractures; these tools were inaccurate in predicting the degree of frontal bone or intracranial injury. Earlier, many prominent authors made treatment decisions based on these tools alone and most likely operated on patients more often than was needed. Nowadays, CT scan images present an accurate, 3-dimensional image by which the clinician can assess the need for and extent of operative intervention. It is now widely agreed upon that CT evaluation is mandatory in all patients with clinical findings suspicious for frontal sinus injury [13].

Computed tomography (CT) imaging was used in evaluating the fractures in our study. The choice between the surgical or nonsurgical treatment of frontal sinus fractures is crucial. This choice is dependent on some factors which subsequently influence the risk of complications. These factors include fracture type, the presence of comminution, cerebrospinal fluid leakage, the extent of posterior table involvement, neurological status of the patient, preference of the treating physician and the nasofrontal outflow tract (NFOT) injury. CT is an essential tool in evaluating several of these factors [3] [4].

Regarding the NFOT, diagnostic criteria have been recently described in an attempt to identify specific findings on CT imaging that carry a high suspicion for injury and obstruction of the NFOT. These criteria include fracture of the frontal sinus floor, fracture of the medial aspect of the anterior table (anterior ethmoid cells), and frank bony outflow tract obstruction. These criteria were relied upon in our study to diagnose the NFOT injury [3] [4].

Fracture repair depends on good exposure and complete identification of the fractured components. Reports from the literature show that exposure via a standard coronal incision is favoured over using an existing laceration. Exposure via existing lacerations is usually an inadequate approach and should be reserved for only small fractures of the anterior table. The bicoronal approach, on the other hand, seems to have a lower recurrence rate and better aesthetic results. Moreover, complications such as numbness, frontal branch (cranial nerve VII) weakness, dural damage with cerebrospinal fluid leakage, and damage of the orbital contents or intracranial structures, are not so common and have seldom been reported [14] [15].

It is well agreed among most authors that a understanding of the sinus drainage apparatus is the key element to successful management of frontal sinus fractures. The nasofrontal duct is the structure responsible for drainage of the frontal sinus. It is more vulnerable to injury because of its posteromedial position in the sinus causing it to be injured in as many as one-third of patients presenting with frontal sinus trauma. Clinical and experimental evidences suggest that obstruction of the nasofrontal duct is a significant predisposing factor in the development of complications such as mucocele or mucopyocele formation and that this risk is life-long. The seriousness of the NFD compromise in frontal sinus fractures was shown through the work of Zonis et al., [16] who noted that all 4 cases of untreated fractures with NFD injury developed suppurative sequelae.

Consequences following NFD injury can be fatal. When frontal sinus drainage is impaired, and mucus is retained, a mucocele may develop and act as an expanding tumour causing erosion of the bony walls of the frontal sinus, orbits, and skull base. An anaerobic environment may subsequently develop, causing frontal sinusitis that may lead to osteomyelitis, meningitis, or brain abscess. These grave sequelae led to the recommendation that fractures resulting in NFD obstruction should generally be treated in the manner as to create a "safe sinus" by complete sinus membrane removal and obliteration of the sinus cavity [17].

In our study, it was decided that every displaced anterior table fracture (isolated or combined with a non-displaced posterior table fracture not requiring cranialization) defined as bony displacement more than or equal to the width of the outer table

associated with NFD fracture was an indication for Frontal sinus obliteration. This is by the conclusion of Heller et al., [17].

There is a myriad of methods and biomaterials available for frontal sinus obliteration. These include obliteration by spontaneous regeneration, autogenous grafts such as bone, fat, and muscle, and alloplasts such as hydroxyapatite bone cement, methyl methacrylate, calcium phosphate bone cement, and glass ionomer. Although advocates for each of these techniques or materials exist, autogenous abdominal fat is the most well-studied and has the longest track record of success [2] [18].

The technique of obliteration with freshly removed abdominal fat dates back to Bergara [19] and Tato et al., [20]. Goodale and Montgomery [21] however established the technique of frontal sinus obliteration with fat obliteration as the standard approach for managing the difficult cases. Their results showed no cases of infection or recurrence and a lack of osteogenesis on plain x-ray films 5 years after surgery.

The work of Tato et al., [20] further endorsed the technique of fat obliteration formerly described. They reported a failure rate of only 3% and stated that adipose tissue survives in the sinus and also that an unobliterated sinus cavity completely cleansed of its lining membrane may obliterate spontaneously with fibrous tissue.

Fat obliteration was further validated by the study of Montgomery and Pierce [22] with only one failure among 61 cases. Calcaterra and Strahan [23] again reported successful obliteration with fat with only one case requiring reoperation and no recurrences. Another study by Sessions et al., [24], showed a 3.7% rate of postoperative infection and no postoperative mucocele.

The most comprehensive series and follow-up were that of Hardy and Montgomery [25]. Two hundred eight (208) patients had their frontal sinuses obliterated with abdominal fat. 4% of cases had to be revised, and the overall complication rate was 18%: there were abdominal wound complications in 5.2%, acute postoperative infections with necrosis of the implanted fat in 3%, and recurrent chronic sinusitis in 3% of patients. No mucoceles were reported throughout the length of the study. In the series, 93% of the patients had no significant symptoms, 6% had persistent pain, and 1% had persistent neuralgia. Our results confirm the high success rate of frontal sinus fat obliteration very comparable to other previous studies [19].

In conclusion, our treatment results suggest that the frontal sinus obliteration utilising autogenous abdominal fat is a highly effective method in the management of fractures of the anterior table. Short term complications were uncommon in our study.

However, the effectiveness of fat obliteration for frontal sinus treatment on the long term cannot be predicted from our study, and further studies are recommended with longer follow-up periods. Moreover, the sample in our study is small, and further studies should be considered with a greater sample.

## References

- Manolidis S. Management of frontal sinus trauma. *Semin Plast Surg.* 2002; 16:261–271. <https://doi.org/10.1055/s-2002-34429>
- Xie C, Mehendale N, Barrett D, Bui CJ, Metzinger SE. 30- year retrospective review of frontal sinus fractures: The charity hospital experience. *J Craniomaxillofac Trauma.* 2000; 6:7–15. PMID:11373741
- Rodriguez ED, Stanwix MG, Nam AJ, St Hilaire H, Simmons OP, Christy MR et al. Twenty-six-year experience treating frontal sinus fractures: a novel algorithm based on anatomical fracture pattern and failure of conventional techniques. *Plast Reconstr Surg.* 2008; 122(6):1850–1866. <https://doi.org/10.1097/PRS.0b013e31818d58ba> PMID:19050539
- Stanwix MG, Nam AJ, Manson PN, Mirvis S, Rodriguez ED. Critical computed tomographic diagnostic criteria for frontal sinus fractures. *J Oral Maxillofac Surg.* 2010; 68(11):2714–272. <https://doi.org/10.1016/j.joms.2010.05.019> PMID:20727640
- Haug RH. Management of fractures of the frontal bone and sinus. *Principles of oral and maxillofacial surgery.* 1992; 1:575-91.
- Haug RH, Adams JM, Conforti PJ, Likavec MJ. Cranial fractures associated with facial fractures: a review of mechanism, type, and severity of injury. *J Oral Maxillofac Surg.* 1994; 52(7):729–733. [https://doi.org/10.1016/0278-2391\(94\)90488-X](https://doi.org/10.1016/0278-2391(94)90488-X)
- Rohrich RJ, Hollier LH. Management of frontal sinus fractures. Changing concepts. *Clinics in plastic surgery.* 1992; 19(1):219-32. PMID:1537220
- D'Addario M, Haug RH, Talwar RM. Biomaterials for use in frontal sinus obliteration. *J Long Term Eff Med Implants.* 2004; 14(6):455–65. <https://doi.org/10.1615/JLongTermEffMedImplants.v14.i6.30> PMID:15698374
- Dornhoffer J, Simmons O. Canal wall reconstruction with mimix hydroxyapatite cement: Results in an animal model and case study. *Laryngoscope.* 2003; 113:2123. <https://doi.org/10.1097/00005537-200312000-00012> PMID:14660914
- Eppley B, Hollier L, Stal S. Hydroxyapatite cranioplasty: 2. Clinical experimental with a new quick-setting material. *J Craniofac Surg.* 2003; 10:209. <https://doi.org/10.1097/00001665-200303000-00014>
- Bergara AR, Itoiz OA. Experimental study of the behavior of adipose tissue within the frontal sinus of the dog. *Argent Rev Otorhinolaryngol.* 1951; 12:184-92.
- Ioannides C, Freihofer HP, Friens J. Fractures of the frontal sinus: a rationale of treatment. *Journal of Plastic, Reconstructive & Aesthetic Surgery.* 1993; 46(3):208-14. [https://doi.org/10.1016/0007-1226\(93\)90170-G](https://doi.org/10.1016/0007-1226(93)90170-G)
- Donald PJ, Bernstein L. Compound frontal sinus injuries with intracranial penetration. *The Laryngoscope.* 1978; 88(2):225-32. <https://doi.org/10.1288/00005537-197802000-00002> PMID:621988
- Gerbino G, Roccia F, Benech A, Caldarelli C. Analysis of 158 frontal sinus fractures: current surgical management and complications. *Journal of Cranio-maxillo-facial Surgery.* 2000; 28(3):133-9. <https://doi.org/10.1054/jcms.2000.0134> PMID:10964548
- Weber R, Draf W, Constantinidis J, Keerl R. Current aspects of frontal sinus surgery. IV: On therapy of frontal sinus osteoma. *HNO.* 1995; 43(8):482-6. PMID:7558905
- Zonis RD, Montgomery WW, Goodale RL. Frontal sinus disease: 100 cases treated by osteoplastic operation. *The Laryngoscope.* 1966; 76(11):1816-25. <https://doi.org/10.1288/00005537-196611000-00008> PMID:5924328
- Heller EM, Jacobs JB, Holliday RA. Evaluation of the frontonasal duct in frontal sinus fractures. *Head & neck.* 1989; 11(1):46-50. <https://doi.org/10.1002/hed.2880110109>
- Wiltfang J, Kessler P, Buchfelder M, Merten HA, Neukam FW, Rupprecht S. Reconstruction of skull bone defects using the hydroxyapatite cement with calvarial split transplants. *Journal of oral and maxillofacial surgery.* 2004; 62(1):29-35. <https://doi.org/10.1016/j.joms.2003.02.002> PMID:14699545
- Bergara R. Osteoplastic operation on the large frontal sinus in chronic suppurative sinusitis; end results. *Transactions-American Academy of Ophthalmology and Otolaryngology. American Academy of Ophthalmology and Otolaryngology.* 1947; 51:643-7.
- Tato JM, Sibbald DW, Bergaglio OE. Surgical treatment of the frontal sinus by external route. *Laryngoscope.* 1954; 64:504-521. <https://doi.org/10.1288/00005537-195406000-00008> PMID:13175517
- Goodale RL, Montgomery WW. LXV Anterior Osteoplastic Frontal Sinus Operation: Five Years' Experience. *Annals of Otolaryngology & Rhinology.* 1961; 70(3):860-80. <https://doi.org/10.1177/000348946107000318> PMID:13900256
- Montgomery WW. Anterior osteoplastic fat obliteration for frontal sinus; clinical experience and animal studies. *Trans Am Acad Ophthalmol Otolaryngol.* 1963; 67:46-57.
- Calcaterra TC, Strahan RW. Osteoplastic flap technique for disease of the frontal sinus. *Surgery, gynecology & obstetrics.* 1971; 132(3):505. PMID:5546308
- Sessions RB, Alford BR, Stratton C, Ainsworth JZ, Roswell NM, Shill O. Current concepts of frontal sinus surgery: An appraisal of the osteoplastic flap-fat obliteration operation. *The Laryngoscope.* 1972; 82(5):918-30. <https://doi.org/10.1288/00005537-197205000-00021> PMID:5026904
- Hardy JM, Montgomery WW. Osteoplastic frontal sinusotomy: an analysis of 250 operations. *Annals of Otolaryngology & Rhinology.* 1976; 85(4):523-32. <https://doi.org/10.1177/000348947608500414> PMID:949159