

# Non Catheter Induced Renal and Inferior Vena Cava Thrombosis in a Neonate: A Case Report

Natasha Aluloska<sup>1\*</sup>, Snezana Janchevska<sup>2</sup>, Velibor Tasic<sup>3</sup>

<sup>1</sup>Neonatology Department, University Children Hospital, Skopje, Republic of Macedonia; <sup>2</sup>NICU, University Clinic for Gynecology and Obstetrics, Skopje, Republic of Macedonia; <sup>3</sup>Nephrology Department, University Children Hospital, Skopje, Republic of Macedonia

## Abstract

**Citation:** Aluloska N, Janchevska S, Tasic V. Non-Catheter Induced Renal and Inferior Vena Cava Thrombosis in a Neonate: A Case Report. Open Access Maced J Med Sci. 2018 Sep 25; 6(9):1678-1681. <https://doi.org/10.3889/oamjms.2018.306>

**Keywords:** Renal thrombosis; Venous thrombosis; Newborn; Hematuria; Ultrasound

**\*Correspondence:** Natasha Aluloska. Neonatology Department, University Children Hospital, Skopje, Republic of Macedonia. E-mail: [aluloska@gmail.com](mailto:aluloska@gmail.com)

**Received:** 18-Jun-2018; **Revised:** 23-Jul-2018; **Accepted:** 27-Jul-2018; **Online first:** 23-Aug-2018

**Copyright:** © 2018 Natasha Aluloska, Snezana Janchevska, Velibor Tasic. This is an open-access article distributed under the terms of the Creative Commons Attribution-NonCommercial 4.0 International License (CC BY-NC 4.0)

**Funding:** This research did not receive any financial support

**Competing Interests:** The authors have declared that no competing interests exist

**BACKGROUND:** Neonatal renal vein thrombosis is the most common vascular condition in the newborn kidney, which could lead to serious complication in infants.

**CASE REPORT:** We report a case of the unilateral renal vein and inferior vena cava thrombosis, presented with gross hematuria and thrombocytopenia in a neonate. The neonate was a macrosomic male born to a mother with hyperglycemia in pregnancy. The baby was born with perinatal asphyxia and early neonatal infection and massive hematuria. Clinical and laboratory examination showed enlarged kidney having corticomedullary differentiation diminished and azotemia. Diagnosis of renal vein thrombosis was suspected by renal ultrasound and confirmed by magnetic urography. Prothrombotic risk factors were evaluated. The child is being managed conservatively. Measures aimed at the prevention of end-stage renal disease because of its poor outcome were highlighted. Despite anticoagulant therapy, the right kidney developed areas of scarring and then atrophy.

**CONCLUSION:** In this work, we present a patient with multiple entities in the aetiology of non-catheter induced renal and vena cava thrombosis in a neonate. Clinicians should suspect renal vein thrombosis in neonates when presented with early postnatal gross hematuria, palpable abdominal mass and thrombopenia.

## Introduction

Renal vein thrombosis is a rare condition in neonates, usually as a consequence of perinatal asphyxia, maternal diabetes mellitus, hypovolemia, hyperosmolarity and coagulopathies. Less often the cause of renal vein thrombosis is congenital heart disease, disseminated coagulopathy, prematurity and infection. External risk factors include central arterial and venous catheters. Neonates are most susceptible age group for renal vein thrombosis; premature infants are a most susceptible neonatal group.

Neonates are most susceptible for renal vein thrombosis due to the physiology of neonatal hemostasis and lower levels of anticoagulants also low levels of fibrinolytic components. The prevalence is 2.2 per 100,000 lives and around 0.5 per 1000

newborn babies treated in NICU. The prevalence of inferior vena cava thrombosis in neonates is the main symptoms are gross hematuria, palpable abdominal mass due to enlarged kidney and thrombocytopenia.

Diagnosis is suspected based on specific symptoms, ultrasonography and additional imaging studies such as venography, CT and MR urography confirm the diagnosis. Aetiology of hypercoagulable state should be searched for and treated. Inherited prothrombotic anomalies have been reported in association with neonatal renal vein thrombosis. Signs and symptoms of acute kidney injury should be monitored, and long-term follow up is mandatory. We present a patient with multiple entities in the aetiology of non-catheter induced renal and vena cava thrombosis in a neonate.

## Case report

We report a case of the unilateral renal vein and inferior vena cava thrombosis, presented with gross hematuria and thrombocytopenia in a neonate. The neonate was a macrosomic male, born to a mother with hyperglycemia in pregnancy. The family history was negative for coagulopathies. He was born in 40<sup>th</sup>-week gestation with perinatal asphyxia, Apgar scores were 6/7/7. The baby was large for gestational age; the birth weight was 5270 gr. He was plethoric, had hemoconcentration, polycythemia and had signs early neonatal sepsis (leukocytosis, thrombopenia) with massive hematuria. Fluid management and antibiotic treatment were started. Initial treatment included broad-spectrum antibiotics and anticoagulant therapy, with careful attention to fluid balance and nutrition.

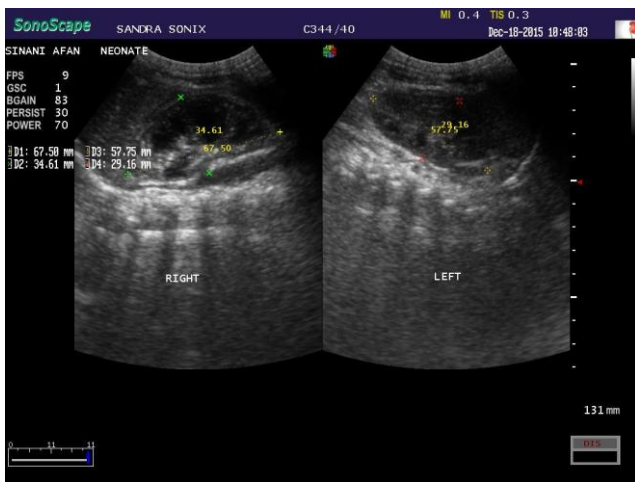


Figure 1: Swollen right kidney and normal sized left kidney in the initial phase of renal vein thrombosis

Diagnosis of renal vein thrombosis was suspected by renal ultrasound and confirmed by magnetic urography. Abdominal ultrasound showed enlarged right kidney having corticomedullary differentiation diminished (right kidney 70 x 48 mm, left kidney 58 x 30 mm), normal values of serum creatinine (49 micromoles/l) and uric acid (179.5 micromole/l). Magnetic urography showed enlarged edematous right kidney with a subcapsular hematoma. Thrombus is seen in the right renal vein and vena cava inferior (25 mm) distally from the renal vein. Prothrombotic risk factors were evaluated.

Protein C and antithrombin III activity were normal for the age. Thrombophilic genes were tested, and heterozygosity of *FBG 455 G/A*, *MTHFR C677T* and *MTRR A66G* polymorphisms was found. Mutations causing arterial and thrombotic anomalies were tested. Heterozygous mutation *C677T* was found in the methylene tetra hydro folate reductase gene (*MTHFR*), a heterozygous mutation in the *LTA* and *455 G>A* in the B-fibrinogen gene were found.

The child is being managed conservatively. Anticoagulant therapy continued with subcutaneous low molecular mass heparin (LMWH) twice a day. Laboratory tests of kidney function showed a transient rise in serum creatinine and urea, proteinuria, and hematuria. Inflammatory parameters gradually normalised and the subsequent blood culture was negative.

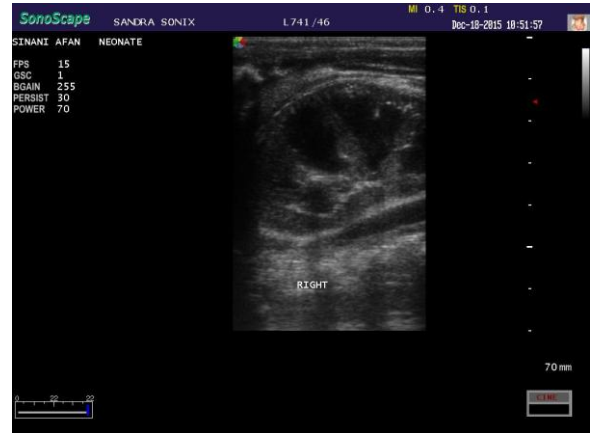

Figure 2: Longitudinal ultrasound scan shows a swollen right kidney with a suparenal anechoic cyst-like lesion and hyperechoic intramedullary streaks in the initial phase of renal vein thrombosis

Afterwards, the boy has been attending the outpatient clinic. Anticoagulant therapy continued with subcutaneous low molecular mass heparin (LMWH) for three months and subsequently discontinued when the coagulation profile was normal. Despite anticoagulant therapy, the right kidney developed areas of scarring and then atrophy. Kidney volumes after 4 months of treatment showed right kidney 34 x 20 mm and left kidney measuring 68 x 35 mm). His follow-up laboratory results showed normal kidney function. At the age of 8 months, DMSA scan showed no renal tissue on the right side, as a consequence of renal atrophy.

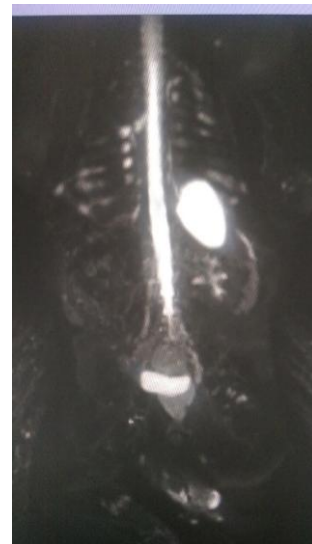

Figure 3: Magnetic resonance- magnetic urography in the early phase of renal and inferior vena cava thrombosis

## Discussion

We present a rare case of non-catheter induced inferior vena cava and renal vein thrombosis in a neonate. Factors predisposing this neonate to RVT include maternal diabetes, early onset infection and complicated labour. The neonate was with no family history of thrombotic disorders or fetal losses, although the child was found to have prothrombotic risk factors.

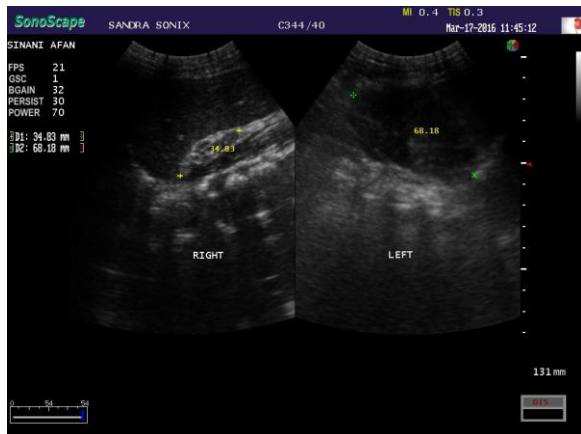


Figure 4: Small right kidney and compensatory hypertrophied left kidney, five months after birth

Neonates are prone to thrombosis in comparison to other age groups. This is because they have decreased levels of anticoagulants and fibrinolytic components. Factors predisposing to neonatal venous thrombosis are genetic and environmental. Maternal factors predisposing vein thrombosis in neonates are maternal hyperglycemia and diabetes, preeclampsia, chorioamnionitis and autoimmune diseases. Early neonatal infection, perinatal asphyxia, hypovolemia and hemoconcentration due to dehydration, polycythemia, hypercoagulability lead to renal vein thrombosis [1]. The most important cause is central arterial and venous catheters, especially umbilical venous catheterisation, reporting 75-95% of thrombotic events were catheter-related [2].

A Dutch study refers to 66% of all thrombi in catheter-induced thrombosis was found in the inferior vena cava, but they didn't find inferior vena cava thrombi in the non-catheter related thrombosis [3]. Studies reporting non-catheter induced inferior vena cava thrombosis are rare and usually report an association with extensive renal vein thrombosis, inferior vena cava anomalies or external pressure. Inherited prothrombotic anomalies have been reported in association with neonatal renal vein thrombosis. Studies report prothrombotic anomalies associated with renal vein thrombosis but less often with inferior vena cava thrombosis [4]. Our patient had a rare set of genetic and external factors leading to renal vein thrombosis but also inferior vena cava thrombosis.

Symptoms usually include gross hematuria, thrombopenia, palpable abdominal mass and renal failure. They frequently overlap with the signs and symptoms of neonatal infection and shock. Clinicians need to monitor closely to prevent renal damage. The diagnosis is suspected on renal ultrasonography (showing renal enlargement) but proven with computed tomography or magnetic urography and radioisotope scans [5] [6]. Treatment of neonatal vein thrombosis remains controversial, and the benefits and the possible side effects need to be measured. Surgical intervention is not indicated in the early phases of renal vein thrombosis [7]. Thrombectomy is rarely possible due to the small blood vessel calibre. Treatment modalities include thrombolysis using heparin, urokinase and recombinant plasminogen activator (r-tPA) [8] [9] [10] [11]. Large randomised controlled studies using anticoagulant treatment in newborns are still missing. Low molecular weight heparin (LMWH) is mostly used as an anticoagulant agent in infants due to fewer side effects and the easy way of subcutaneous administration [12] [13] [14].

Although different modalities have been used treating neonatal vein thrombosis, the outcome is often unsatisfactory, and renal damage and renal loss are what remains afterwards [15] [16] [17].

In conclusion, in this work, we present a patient with multiple entities in the aetiology of non-catheter induced renal and vena cava thrombosis in a neonate. Clinicians should suspect renal vein thrombosis in neonates when presented with early postnatal gross hematuria, palpable abdominal mass and thrombopenia. Measures aimed at prevention of end-stage renal disease must be overtaken because of its poor outcome despite the anticoagulant treatment used.

## References

- Heller C, Schobess R, Kurnik K, Junker R, Gunther G, Kreuz W, et al. Abdominal venous thrombosis in neonates and infants: the role of prothrombotic risk factors e a multicentre case-control study. For the Childhood Thrombophilia Study Group. *Br J Haematol.* 2000; 111:534e9.
- Bhat R, Kumar R, Kwon S, Murthy K, Liem RI. Risk Factors for Neonatal Venous and Arterial Thromboembolism in the Neonatal Intensive Care Unit—A Case Control Study. *The Journal of pediatrics.* 2018; 195:28-32. <https://doi.org/10.1016/j.jpeds.2017.12.015> PMID:29398052
- van Ommen CH, Heijboer H, Buller HR, Hirasing RA, Heijmans HS, Peters M. Venous thromboembolism in childhood: a prospective two-year registry in The Netherlands. *J Pediatr.* 2001; 139(5):676–81. <https://doi.org/10.1067/mpd.2001.118192> PMID:11713446
- Hausler M, Duque D, Merz U, et al. The clinical outcome after inferior vena cava thrombosis in early infancy. *EurJ Pediatr.* 1999; 158:416-420. <https://doi.org/10.1007/s004310051105>
- Hibbert J, Howlett DC, Greenwood KL, et al. The ultrasound appearances of neonatal renal vein thrombosis. *BrJ Radiol.* 1997;

- 70:1191-1194. <https://doi.org/10.1259/bjr.70.839.9536915> PMID:9536915
6. Laplante S, Patriquin HB, Robitaille P, et al. Renal vein thrombosis in children: evidence of early flow recovery with Doppler US. *Radiology*. 1993; 189:37-42. <https://doi.org/10.1148/radiology.189.1.8372216> PMID:8372216
7. Bresolin NL, Essig LC, Kleis RL. Renal vein thrombosis in newborn infants. *J Pediatr*. 1996; 72:44-48. <https://doi.org/10.2223/JPED.603>
8. Monagle P, Chan AK, Goldenberg NA, Ichord RN, Journeycake JM, Nowak-Göttl U, Vesely SK. Antithrombotic therapy in neonates and children: antithrombotic therapy and prevention of thrombosis: American College of Chest Physicians Evidence-Based Clinical Practice Guidelines. *Chest*. 2012; 141(2):e737S-801S. <https://doi.org/10.1378/chest.11-2308> PMID:22315277 PMCid:PMC3278066
9. Messinger Y, Sheaffer JW, Mrozek J, Smith CM, Sinaiko AR. Renal outcome of neonatal renal venous thrombosis: review of 28 patients and effectiveness of fibrinolytics and heparin in 10 patients. *Pediatrics*. 2006; 118:e1478e84.
10. Beaufils F, Schlegel N, Brun P, Loirat C. Treatment of renal vein thromboses in the newborn. *Ann Pediatr*. 1993; 40: 57e60.
11. Law C, Raffini L. A guide to the use of anticoagulant drugs in children. *Paediatr Drugs*. 2015; 17:105–14. <https://doi.org/10.1007/s40272-015-0120-x> PMID:25711916
12. Kim JH, Lee YS, Kim SH, Lee SK, Lim MK, Kim HS. Does umbilical vein catheterization lead to portal venous thrombosis? Prospective US evaluation in 100 neonates. *Radiology*. 2001; 219:645–50. <https://doi.org/10.1148/radiology.219.3.r01jn17645> PMID:11376248
13. Bauman ME, Belletrutti MJ, Bajzar L, Black KL, Kuhle S, Bauman ML, et al. Evaluation of enoxaparin dosing requirements in infants and children. Better dosing to achieve therapeutic levels. *Thromb Haemost*. 2009; 101:86–92. <https://doi.org/10.1160/TH08-03-0148> PMID:19132193
14. Chander A, Nagel K, Wiernikowski J, Paes B, Chan AK. Evaluation of the use of low-molecular-weight heparin in neonates: a retrospective, single-center study. *Clin Appl Thromb Hemost*. 2013; 19:488–93. <https://doi.org/10.1177/1076029613480557> PMID:23478571
15. Bökenkamp A, Von Kries R, Nowak-Göttl U, Göbel U, Hoyer PF. Neonatal renal venous thrombosis in Germany between 1992 and 1994: epidemiology, treatment and outcome. *European journal of pediatrics*. 2000; 159(1-2):44-8. <https://doi.org/10.1007/s004310050008> PMID:10653328
16. Lau KK, Stoffman JM, Williams S, McCusker P, Brandao L, Patel S, Chan AK. Neonatal renal vein thrombosis: review of the English-language literature between 1992 and 2006. *Pediatrics*. 2007; 120(5):e1278-84. <https://doi.org/10.1542/peds.2007-0510> PMID:17974721
17. Niada F, Tabin R. Spontaneous neonatal renal vein thromboses: Should we treat them all? A report of five cases and a literature review. *Pediatrics & Neonatology*. 2018; 59(3):281-7. <https://doi.org/10.1016/j.pedneo.2017.09.009> PMID:29097267