

The outcome of Pregnancy with Fetal Primitive Neuroectodermal Tumor

Vesna Livrinova^{1*}, Igor Petrov², Adela Stefanija¹, Jasminka Josheva³, Viktorija Jovanovska¹, Igor Samardziski¹, Selim Komina⁴, Rubens Jovanovic⁴, Ana Daneva-Markova¹, Slagjana Simeonova-Krstevska¹, Irena Todorovska¹, Ajla Shabani¹

¹University Clinic for Obstetrics and Gynecology, Skopje, Republic of Macedonia; ²University Clinic for Neurology, Skopje, Republic of Macedonia; ³Private Hospital Acibadem Sistina, Skopje, Republic of Macedonia; ⁴Institute for Pathology, Faculty of Medicine, Ss Cyril and Methodius University of Skopje, Skopje, Republic of Macedonia

Abstract

Citation: Livrinova V, Petrov I, Stefanija A, Josheva J, Jovanovska V, Samardziski I, Komina S, Jovanovic R, Daneva-Markova A, Simeonova-Krstevska S, Todorovska I, Shabani A. The outcome of Pregnancy with Fetal Primitive Neuroectodermal Tumor. Open Access Maced J Med Sci. 2018 Aug 20; 6(8):1450-1453. <https://doi.org/10.3889/oamjms.2018.316>

Keywords: Fetus; Brain tumour; Outcome

***Correspondence:** Vesna Livrinova. University Clinic for Obstetrics and Gynecology, Skopje, Republic of Macedonia. E-mail: livrinovii@yahoo.com

Received: 15-May-2018; **Revised:** 22-Jul-2018; **Accepted:** 27-Jul-2018; **Online first:** 17-Aug-2018

Copyright: © 2018 Vesna Livrinova, Igor Petrov, Adela Stefanija, Jasminka Josheva, Viktorija Jovanovska, Igor Samardziski, Selim Komina, Rubens Jovanovic, Ana Daneva-Markova, Slagjana Simeonova-Krstevska, Irena Todorovska, Ajla Shabani. This is an open-access article distributed under the terms of the Creative Commons Attribution-NonCommercial 4.0 International License (CC BY-NC 4.0)

Funding: This research did not receive any financial support

Competing Interests: The authors have declared that no competing interests exist

BACKGROUND: Fetal intracranial tumours are very rare. The overall incidence is 0.34 per one thousand live birth newborns. According to the new classification of central nervous system tumour (2016), a primitive neuroectodermal tumour of (PNETs) is an embryonal tumour group; these are tumours with high malignancy and belong to group IV (WHO). In our case, we will present a case of PNETs in 28 gestation week old fetus, diagnosed antenatally and confirmed postnatally.

CASE REPORT: We present the third pregnancy in 29 years old patient, with two previous term deliveries of healthy newborn. She came to University clinic at 27+3 gestational week for fetal hydrocephalus. After an ultrasound and MRI scan, possibilities were explained to the parents. During the medico-ethical counselling, explain to the parents the need for operation and the possibility of postoperative adjuvant therapy, quality of life with potential future disabilities. They choose to terminate the pregnancy. Postmortem the diagnosis was PNETs. Summary of analysis: peripheral neuroectodermal tumour with ganglion and neuronal differentiation

CONCLUSION: Antenatal management depends on the gestational week in the time of diagnosis and the decision of parents. If the lesion is before viability fetus, it should be offered termination of pregnancy. Another important factor is the mode of delivery, because of increased intracranial pressure although this aggressive combined modality of treatment, recurrence is often. Tree year of survival is between 53% and 73% when the adjuvant radiotherapy is included. For that, they should be diagnosed as soon as possible before achieving fetal viability. Only 18% of those tumours presenting in the first year of life are diagnosed before or at delivery.

Introduction

Fetal intracranial tumours are very rare. The overall incidence is 0.34 per one thousand live birth newborns. It is very difficult to determinate the origin of tumour mass during the pregnancy due to its big dimension and supratentorial location. In older children, the brain tumours are often infratentorial. According to the new classification of central nervous system tumour (2016), a primitive neuroectodermal tumour of (PNETs) is an embryonal tumour group; these are tumours with high malignancy and belong to group IV (WHO) [1]. Primitive Neuroectodermal Brain

Tumor together with Medulloblastoma and Atypical teratoid/ a rhabdoid tumour, belong to a subgroup of Embryonal tumours which originate from neuroepithelial tissue which consist 29.9% of all a brain tumour. Embryonal tumours consist of 6.62%. PNETs account for less than 5 % of embryonic CNS tumours. Most occur during childhood, with 80 % diagnosed before age 10 years, and 25 % present within the first two years. An analysis of PNETs in adults suggests that these tumours are molecularly different from the more common childhood PNETs. Only 18% of those tumours presenting in the first year of life are diagnosed before or at delivery.

In our case, we will present a case of PNETs in 28 gestation week old fetus, diagnosed antenatally and confirmed postnatally.

Case report

This was the third pregnancy in 29 years old patient, with two previous spontaneous term deliveries of healthy newborn. She came to University Clinic for Obstetrics and Gynecology in Skopje at 27+3 gestational week, after the suggestion of her ordinate gynaecologist because of his suspicion for fetal hydrocephalus. The patient had previous 3 ultrasound examinations. The ultrasound was performed, and the diagnosis by the US was: Tu cerebri. Hydrocephalus internet. Agenesis corporis callosi. Cardiopatia (VSD). Ultrasound exam: fetal biometric measurements shown 28 g.w. Fetal head: in right brain hemisphere, supratentorial located there is heterogonous texture tumour-like mass with a dimension of 70x66mm, with whole dilated right ventricle with a dimension of the posterior horn of 26 mm and shift of cerebral falx on the left (Fig. 1).

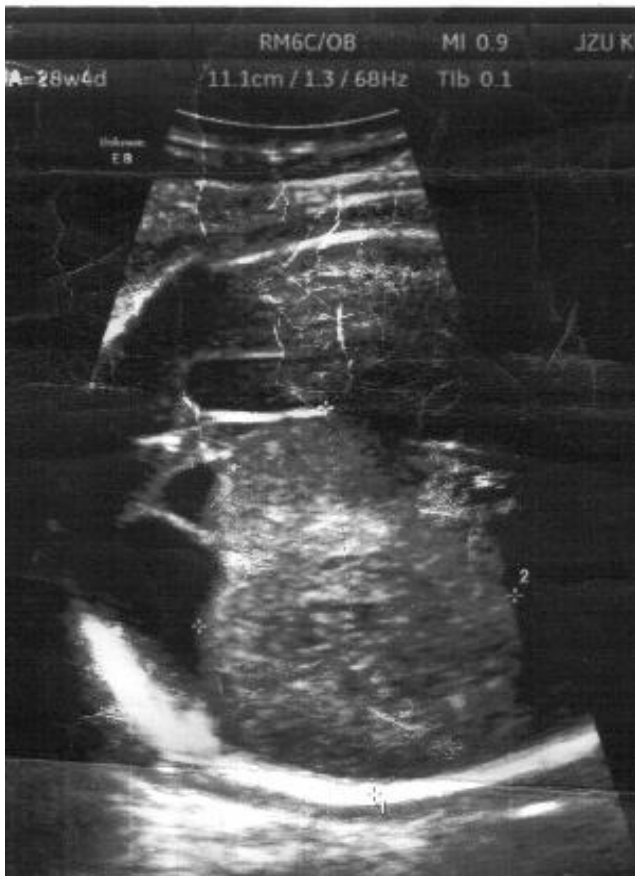

Figure 1: Ultrasound 2-D image of the fetal head

Additional imaging technique was performed such as MRI of the fetus. The report from MRI: single

pregnancy in cephalic presentation. Fetal cranium: posterior cranial fossa with normal appearance. On the right side partly solid, a partly cystic tumour mass which has a heterosexual appearance in T2 pulse sequence with hypo signal solid part and the cystic peripheral part which is extended in frontoparietal direction. On T2 pulse sequence this lesion is from isosignal till hyposignal with existing linear peripheral hyper signal toward parietal, suggesting necrosis and haemorrhage.

The lesion has an extensive mass effect, resulting in dilatation of the right ventricle more evident in occipital horn with a diameter of 29 mm with reduction of brain tissue. The left hemisphere is with regular gyration. Also, there is digenesis of the colossal body. According to the above description and appearance, the lesion suggests PNET s with differential diagnosis glioblastoma (Fig. 2).

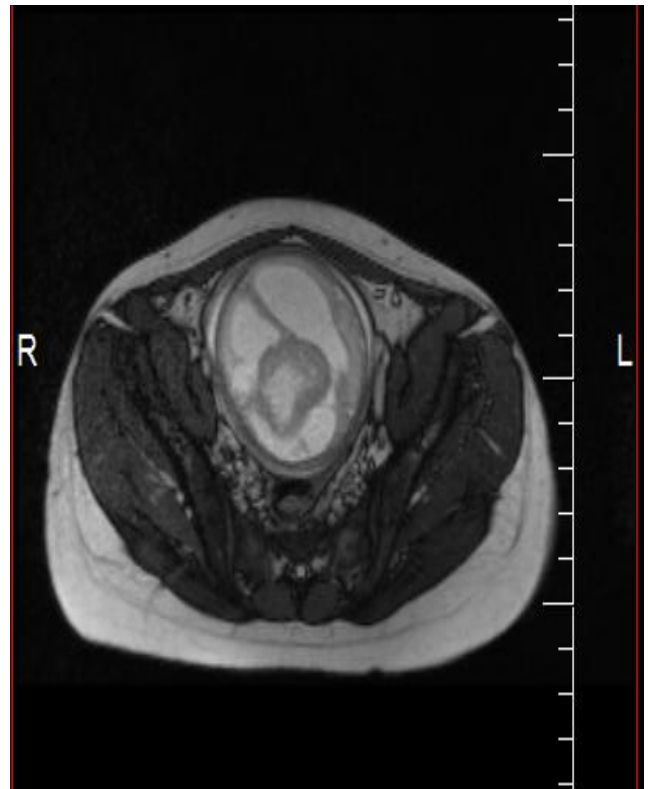


Figure 2: MRI of the fetal head

During the medico-ethical counselling, we performed testing for aneuploidies and explain to the future parents about the need for operation and possibility for postoperative adjuvant therapy, quality of life with potential future disabilities according to the data of literature.

They decide to terminate the pregnancy with intrauterine feticide. The dead male newborn weighted 1700 g and 42 centimetres long. The newborn was evaluated by pathologists. Diagnosis was: Primitive neuroectodermal tumour lobe parietalis cerebri lateris dextri. Hydrocephalus internus. Encephalomalacia cerebri precipice lobi parietal-occipitalis bilateral.

Haemorrhagia subarachnoidal parietooccipital
bilateral (Fig. 3, 4).

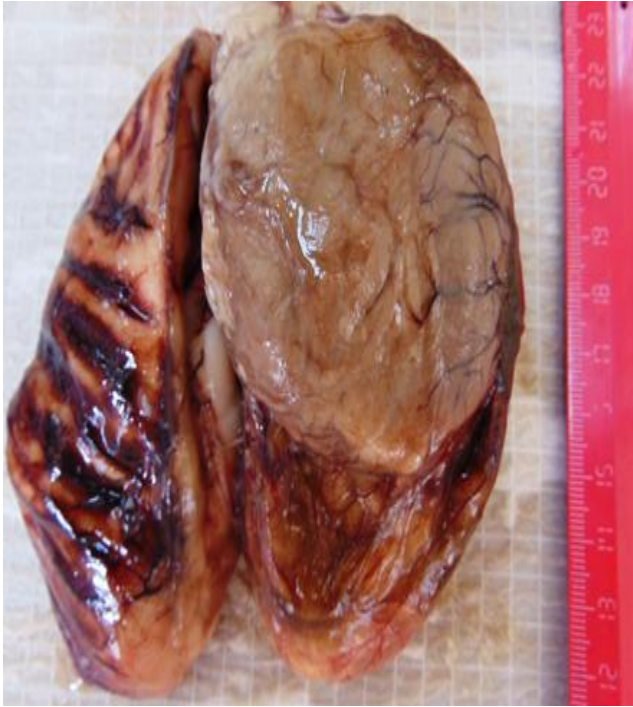

Figure 3: Macroscopic appearance of the lesion

Photomicrograph of a tumour demonstrating Homer-Wright rosette formations, composed of moderately differentiated, round to oval cells with moderately abundant eosinophilic to the amphophilic cytoplasm and hyperchromatic nuclei, surrounding central core of neurofibrillary material, (haematoxylin-eosin, original magnification x 400) (Fig. 4).

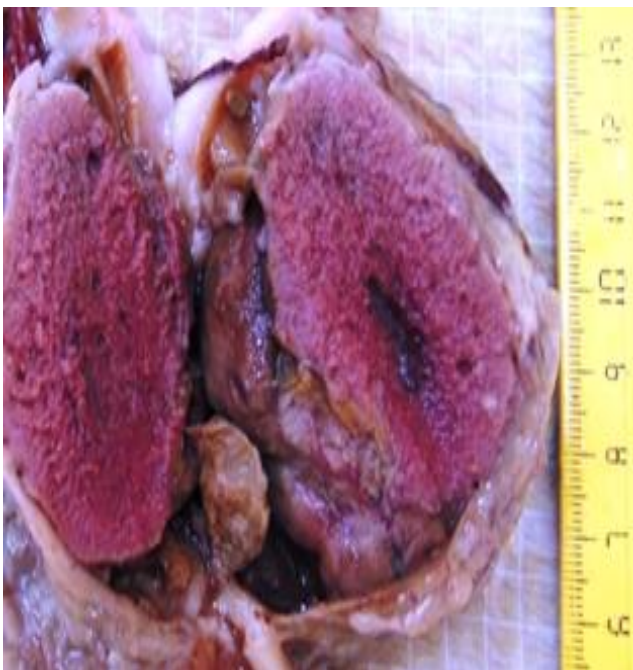


Figure 4: Macroscopic changes of lesion

Additionally, immune histochemical staining of tumor lesion shown this profile: Vimentin(+), S100(+), CD34(-), GFAP(+), Actin(-/+), Desmin(-), CD99(-), EMA(-), CKWS(-), Chromogranin(-), NSE(+), WT1(+), Synaptophysin: positive single cells with their dendrits, Ki 67 proliferative index: 2-3%. Summary of analysis: peripheral neuroectodermal tumor with ganglionic and neuronal differentiation.

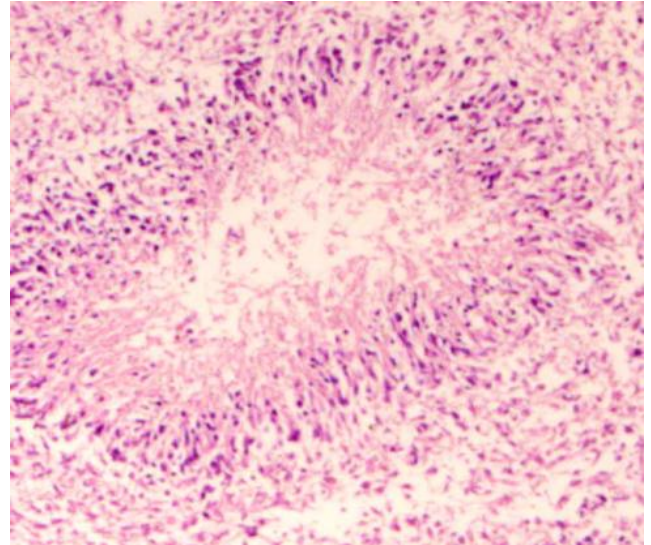


Figure 5: Microscopic picture of lesion

Discussion

PNETs of CNS are low differentiated (WHO-gr.IV) [1], rapid growth, neuroepithelial tumours which originated from the germinative matrix of the primitive neural tube. They have a potential to differentiate in more different cell lines. Tumours with clear neuronal differentiation are classified as neuroblastoma of CNS and others with mixed differentiation of neuronal and glial cells, classified as CNS ganglioneuroblastomas. Some PNETs could be classified of their tissue origin-retinoblastoma, pineoblastoma, but the most of them originate from cerebral hemisphere tissue (suprasellar parts), and for that, they were classified as supratentorial PNETs. Primitive neuroectodermal tumours constitute less than 5% of embryonal CNS tumours. Lot of them are with clinical manifestations in childhood, 80% before 10 years ago, one quarter are present in the first two years of life. The tumours that occurred in adult life are molecularly different from PNETs in childhood [2].

On MRI scans there are heterogenous formations with hypodense regions correlating with hemosiderin deposition or calcifications; T1 hyperdense regions correspondents with haemorrhage and T2 bright region reflected cystic

components. The relative absence of peritumor oedema is persisted [3].

Antenatal management depends on the gestational week in the time of diagnosis and the decision of parents. If the lesion is before viability fetus, it should be offered termination of pregnancy. Because these tumours have rapid growth potential, often they are diagnosed in advanced gestational age [4]. Another important factor is mode of delivery in the cases when the parent will decide to deliver such babies. Because of increased intracranial pressure due to hydrocephalus and intracranial lesion. With an aim to minimise the additional increase of intracranial pressure, the cesarean section should be offered, before being of uterine contraction [5].

The management includes aggressive surgical resection followed with radiotherapy [6] [7] [8]. Although this aggressive combined modality of treatment, recurrence are often. Three year of survival is between 53% and 73% when the adjuvant radiotherapy is included [9]. The children under three years and with pineal PNETs have a worse prognosis [10].

For that, they should be diagnosed as soon as possible before achieving fetal viability. Only 18% of those tumours presenting in the first year of life are diagnosed before or at delivery [11].

In conclusion, fetal tumours are usually different in their histological characteristics, anatomical distributions, pathophysiology and biological behaviour, compare with the same tumour in children.

Routine antenatal ultrasound exams lead to increase the rate of detection of fetal tumours, especially MRI could be useful in differential diagnosis in some cases. Very important is the skills of obstetrician and ultrasonographer and their experience. This could be very important in the course of changing decisions of parent and management of these pregnancies and postnatally. PNETs are low differentiated malignant tumours of the central nervous system with unfavourable prognosis. Although these are very rare tumours, the importance is their prognosis.

References

1. Louis DN, Ohgaki H, Wiestler OD, Cavenee WK (Eds). WHO Classification of Tumours of the Central Nervous System, 4th ed, IARC, 2016.
2. Gessi M, Setty P, Bisceglia M, et al. Supratentorial primitive neuroectodermal tumors of the central nervous system in adults: molecular and histopathologic analysis of 12 cases. *Am J Surg Pathol.* 2011; 35:573. <https://doi.org/10.1097/PAS.0b013e31820f1ce0> PMID:21378543
3. Depper MH, Hart BL. Pediatric Brain Tumors. In: Neuroimaging, Orrison WW (Ed), WB Saunders, Philadelphia, 2000:1625.
4. Schlembach D, Bornemann A, Rupprecht T, Beinder E. Fetal intracranial tumors detected by ultrasound: a report of two cases and review of the literature. *Ultrasound in Obstetrics and Gynecology: The Official Journal of the International Society of Ultrasound in Obstetrics and Gynecology.* 1999; 14(6):407-18. <https://doi.org/10.1046/j.1469-0705.1999.14060407.x> PMID:10658280
5. Yilmaz E, et al: Fetal intracranial tumor with antenatal diagnosis. *Perinatal Journal.* 2008; 16(1):36-39.
6. Tomita T, McLone DG, Yasue M. Cerebral primitive neuroectodermal tumors in childhood. *J Neurooncol.* 1988; 6:233. <https://doi.org/10.1007/BF00163707> PMID:3066855
7. Albright AL, Wisoff JH, Zeltzer P, et al. Prognostic factors in children with supratentorial (nonpineal) primitive neuroectodermal tumors. A neurosurgical perspective from the Children's Cancer Group. *Pediatr Neurosurg.* 1995; 22:1. <https://doi.org/10.1159/000121292> PMID:7888387
8. Pérez-Martínez A, Lassaletta A, González-Vicent M, et al. High-dose chemotherapy with autologous stem cell rescue for children with high risk and recurrent medulloblastoma and supratentorial primitive neuroectodermal tumors. *J Neurooncol.* 2005; 71:33. <https://doi.org/10.1007/s11060-004-4527-4> PMID:15719272
9. Cohen BH, Zeltzer PM, Boyett JM, et al. Prognostic factors and treatment results for supratentorial primitive neuroectodermal tumors in children using radiation and chemotherapy: a Children's Cancer Group randomized trial. *J Clin Oncol.* 1995; 13:1687. <https://doi.org/10.1200/JCO.1995.13.7.1687> PMID:7602359
10. Reddy AT, Janss AJ, Phillips PC, et al. Outcome for children with supratentorial primitive neuroectodermal tumors treated with surgery, radiation, and chemotherapy. *Cancer.* 2000; 88:2189. [https://doi.org/10.1002/\(SICI\)1097-0142\(20000501\)88:9<2189::AID-CNCR27>3.0.CO;2-G](https://doi.org/10.1002/(SICI)1097-0142(20000501)88:9<2189::AID-CNCR27>3.0.CO;2-G)
11. Cho JY, Lee YH. Fetal tumors: prenatal ultrasonographic findings and clinical characteristics. *Ultrasonography.* 2014; 33(4):240. <https://doi.org/10.14366/usg.14019> PMID:25116458 PMID:PMC4176115