

“Two Stones on One Bird”: A Case Report on Severe Biphasic Anaphylaxis Masquerading as Life-Threatening Acute Asthma

Alvin Oliver Payus^{1*}, Azliza Ibrahim², Norlaila Mustafa²

¹Faculty of Medicine and Health Science, Universiti Malaysia Sabah (UMS), Jalan UMS, 88400 Kota Kinabalu, Sabah, Malaysia; ²Department of Internal Medicine, Universiti Kebangsaan Malaysia Medical Centre (UKMMC), Jalan Yaacob Latif, 56000 Cheras, Kuala Lumpur, Malaysia

Abstract

Citation: Payus AO, Ibrahim A, Mustafa N. “Two Stones on One Bird”: A Case Report on Severe Biphasic Anaphylaxis Masquerading as Life-Threatening Acute Asthma. Open Access Maced J Med Sci. <https://doi.org/10.3889/oamjms.2018.317>

Keywords: Anaphylaxis; Acute asthma; Biphasic reaction; Shortness of breath; Intramuscular adrenaline 0.5mg

***Correspondence:** Alvin Oliver Payus, Faculty of Medicine and Health Science, Universiti Malaysia Sabah (UMS), Jalan UMS, 88400 Kota Kinabalu, Sabah, Malaysia. E-mail: dralvinpayus@ums.edu.my

Received: 07-Oct-2018; **Revised:** 03-Nov-2018; **Accepted:** 04-Nov-2018; **Online first:** 19-Nov-2018

Copyright: © 2018 Alvin Oliver Payus, Azliza Ibrahim, Norlaila Mustafa. This is an open-access article distributed under the terms of the Creative Commons Attribution-NonCommercial 4.0 International License (CC BY-NC 4.0)

Funding: This research did not receive any financial support

Competing Interests: The authors have declared that no competing interests exist

BACKGROUND: Anaphylaxis often misdiagnosed and treated as acute asthma, especially when it has a predominant respiratory symptom, and there are no obvious precipitants or previous allergic history. This morbid outcome is preventable if the level of suspicion for anaphylaxis is high among healthcare provider when treating a patient who is not responding to the standard management of acute asthma. A proportion of anaphylactic patient shows a biphasic reaction which potentially fatal when it is under-anticipated and prematurely discharge without adequate observation period after the recovery of the initial episode.

CASE REPORT: Here, we present a case of a young man who has childhood asthma with the last attack more than 10 years ago presented with symptoms suggestive of acute exacerbation of bronchial asthma. As the symptoms failed to improve after standard asthma management, anaphylaxis was suspected, and he was given intramuscular adrenaline 0.5 mg which leads to symptom improvement. However, he developed another attack shortly after improvement while under observation.

CONCLUSION: The objective of this case report is to emphasise the importance of keeping anaphylaxis in mind whenever a patient has treatment-refractory asthma, and also the anticipation of biphasic reaction that warrants adequate observation period especially those who are likely to have developed it.

Introduction

Acute asthma and anaphylactic reaction have a clinical presentation that similar to each other. Therefore, it is not uncommon for a patient with anaphylaxis to be treated as acute asthma and not given the appropriate treatment [1]. This potentially fatal misdiagnosis can be prevented if health care provider has a higher suspicion level for anaphylaxis when treating an acute asthma patient that refractory to standard treatment. Biphasic anaphylaxis is one of the morbid sequelae of an anaphylactic reaction, which is still poorly understood and said to occur in 1 in every 5 cases of anaphylaxis [2]. The fatality of this phenomenon can be avoided if the patient is

subjected to adequate observation after the recovery of the initial symptoms, especially those who have a history of bronchial asthma or another risk factor.

Case Report

A 21-year old army officer presented with progressive shortness of breath and left-sided pleuritic chest pain for the past three days. He had a fever with coryzal symptoms five days before the onset of breathlessness which he seeks treatment from a private clinic. He has given oral amoxicillin 500 mg

three times daily, oral chlorpheniramine 4 mg three times daily, oral paracetamol 1 gm four times daily and oral salbutamol 2 mg three times daily. He was also nebulised twice during the clinic visit. There was no spirometry test done during the visit. Upon further history noted that he had childhood asthma before and was only on a single short-acting reliever treatment with salbutamol inhaler, and never had a proper follow-up. The last asthma attack was more than 10 years ago. On arrival to the emergency department, he was tachypnoeic and had multiple bouts of a cough, but otherwise alert and conscious. There was a marked periorbital swelling noted as well. According to the patient, he noticed that his face was increasing swollen in the past few days, and there were some itchiness and redness too, but he did not seek any treatment for it. He was allergic to cashew nuts and diclofenac which he did not take before the complaint. His vital signs were stable with a blood pressure of 130/90 mmHg, heart rate of 140 beats per minute and oxygen saturation rate of 100% on room air via a pulse oximeter. On examination of the chest noted there was a very poor air entry over the whole both lungs with occasional rhonchi heard. Preliminary blood investigation was taken (as shown in Table 1). His chest radiograph image did not show pneumothorax or consolidation (as shown in Figure 1).

Table 1: Preliminary blood investigation taken on arrival to the emergency department showed mild leucocytosis and eosinophilia. Otherwise the haemoglobin and platelet count was normal. There is no deranged electrolyte level, and no liver or renal impairment

TEST	VALUE	NORMAL RANGE
Haemoglobin	14.1 g/d	12 – 18 g/dL
Haematocrit	43.5 %	35 – 48 %
White cell count	$11.8 \times 10^9/L$	$4.0 - 11.0 \times 10^9/L$
Eosinophil	$0.6 \times 10^9/L$	$0.2 - 0.5 \times 10^9/L$
Platelet	$294 \times 10^9/L$	$150 - 400 \times 10^9/L$
Urea	5.4 mmol/L	1.7 – 8.0 mmol/L
Creatinine	104 μ mol/L	60 – 120 μ mol/L
Sodium	138 mmol/L	135 – 150 mmol/L
Potassium	3.9 mmol/L	3.5 – 5.0 mmol/L
Calcium	2.3 mmol/L	2.10 – 2.55 mmol/L
Magnesium	0.90 mmol/L	0.75 – 1.10 mmol/L
ALT	42 u/L	5 – 35 u/L
ALP	70 u/L	30 – 100 u/L
pH	7.38	7.35 – 7.45
Arterial PaO ₂	82 mmHg	80 – 100 mmHg
PaCO ₂	40 mmHg	35 – 45 mmHg
HCO ₃ ⁻	26 mEq/L	22 – 28 mEq/L

ALT: Alanine Aminotransferase; ALP: Alkaline Phosphatase; PaO₂: Partial Pressure of Oxygen; PaCO₂: Partial Pressure of Carbon Dioxide; HCO₃⁻: Bicarbonate

Given the symptoms and the background history of childhood asthma, the initial impression was severe to life-threatening acute exacerbation of bronchial asthma. He was immediately given multiple nebulizations of combined salbutamol and ipratropium bromide along with intravenous (IV) hydrocortisone 200 mg bolus, IV chlorpheniramine 10 mg bolus, and IV magnesium sulphate 2.47 mg slow infusion. Despite all the medications, the patient still has severe bronchospasm and worsening tachypnoea.

At this point, the possibility of severe anaphylaxis was entertained given the facial swelling and itchiness, and also the symptoms were refractory to the standard bronchodilator management.

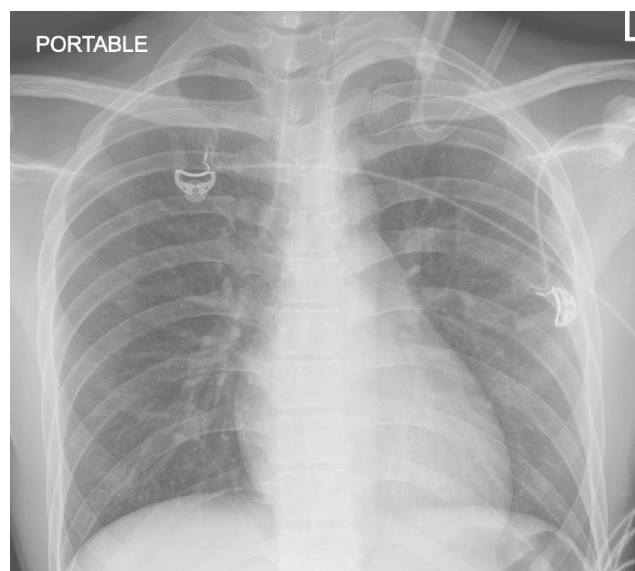


Figure 1: Chest radiograph image taken on arrival to the emergency department was normal

It could be secondary to the antibiotic he took a few days ago or may be triggered by recent upper respiratory tract infection. Therefore, intramuscular (IM) adrenaline 0.5 mg was given, and it provides rapid improvement. However, it only provides a temporary relief whereby the bronchospasm and tachypnoea resumed and necessitates a repeated IM adrenaline to be given twice. The facial swelling reduced but the bronchospasm persisted. Repeated arterial blood gas at that time showed type 1 respiratory failure with the slow rising of carbon dioxide retention. The nebulization was escalated to continuous nebulization. As the patient was increasingly fatigue and there were impending type 2 respiratory failures, the patient was subjected to invasive assisted ventilation. While intubated and mechanically ventilated, the bronchodilator nebuliser was continued. After being on assisted ventilation for 12 hours, he was then extubated and kept on closed observation in the intensive care unit. He managed to keep good oxygenation via spontaneous respiratory effort, and there was no further bronchospasm attack. He was discharged after a few days of admission with an emergency epinephrine pen and will be investigated for the potential triggers of his anaphylaxis episode in the outpatient clinic appointment. Spirometry test done before discharge was normal.

Discussion

Anaphylaxis is an acute, systemic, potentially fatal allergic reaction which driven by type I hypersensitivity reaction that requires both immediate recognition and rapid treatment. It is clinically

manifested as hives, flushing, itchiness, angioedema, wheezing, stridor, breathlessness, vomiting, diarrhoea or shock. Given the nature of its presentation, anaphylaxis with respiratory symptom predominant can be easily misdiagnosed as severe acute asthma. According to an original article by J. Rainbow and G.J. Browne (2002), patients who have the symptom of severe acute asthma may be suffering from anaphylaxis. Therefore, they mentioned a few recommendations, which are to suspect anaphylaxis in a patient with rapid onset of wheeze or not responding to the standard asthma treatment, to use adrenaline early when anaphylaxis is suspected, to confirmed anaphylaxis with radioimmunoassay and mast cell tryptase level, and to screen for precipitating allergens [1].

Some patient with anaphylaxis may show a biphasic reaction. Biphasic anaphylaxis refers to the second episode of anaphylaxis that follows the brief resolution of symptoms period after the initial anaphylaxis reaction without further exposure to the triggering factors. It is a poorly understood allergic phenomenon that has a fatal outcome and has been reported to develop in up to 20% of all cases of anaphylactic reactions [2]. There are a few possible risk factors has been suggested that increases the likelihood of biphasic anaphylaxis, namely severe initial symptoms, delayed administration of adrenaline during the initial treatment, a longer time for the initial reaction to resolve, delayed onset of the initial symptoms after exposure to the antigen, and exposure to allergens in the form of oral ingestion [3]. However, all these factors are still yet to be proven further by more study in the future. Confino-Cohen R and Goldberg A (2010) in their research of biphasic reactions following allergen immunotherapy suggested that the only difference between biphasic and uniphasic reactions was that a higher incidence of asthma and low peak expiratory flow rate could be identified in those with biphasic reactions [4]. The clinical severity of the second phase of biphasic anaphylaxis does not necessarily resemble the first. Some reported that it could be more severe or even fatal [5]. The period between the recurrence of symptoms and the initial resolution of initial symptom varies substantially and can go up to 72 hours.

In this article, our patient presented with symptoms of severe to life-threatening acute exacerbation of bronchial asthma. After treated promptly with bronchodilator nebuliser and other systemic medications, the bronchospasm failed to improve. Therefore, given the presence of a history of allergy and also taking antibiotic before the presentation, there was a possibility of severe anaphylaxis instead of acute asthma which may be induced by the antibiotic. Therefore, intramuscular (IM) adrenaline 0.5 mg was given, and it leads to rapid

improvement. However, the patient showed a biphasic anaphylactic reaction whereby there was only a brief period where the bronchospasm and facial swelling improved after the first dose of IM adrenaline before the bronchospasm recur again while he was under observation, which severe enough that he needs to be intubated and mechanically ventilated.

In conclusion, this case report served to emphasise the importance of having a high level of suspicion for severe anaphylaxis whenever treating a non-responsive life-threatening bronchial asthma. Therefore, it is imperative to give a trial of adrenaline in a severe to life-threatening acute asthma patient who is refractory to standard treatment, with or without allergy history. Apart from that, it is also crucial to anticipate a biphasic reaction in a patient with a high likelihood to develop it, for example, who has underlying bronchial asthma. Therefore, a period of observation after the resolution of attack is warranted and potentially save a life.

Acknowledgement

The authors would like to thank the patient and his family for their cooperation about the writing of this report. The authors would also like to thank the Director General of Health Malaysia for his permission to publish this article.

References

1. Rainbow J, Browne GJ. Fatal asthma or anaphylaxis? *Emergency Medicine Journal*. 2002; 19(5):415-7. <https://doi.org/10.1136/emj.19.5.415> PMID:12204988 PMCID:PMC1725974
2. Muraro A, Roberts G, Worm M, et al. Anaphylaxis: guidelines from the European Academy of Allergy and Clinical Immunology. *Allergy*. 2014; 69:1026-45. <https://doi.org/10.1111/all.12437> PMID:24909803
3. Lieberman PL, Feldweg A, Simons F. Biphasic and protracted anaphylaxis, 2016.
4. Confino-Cohen R, Goldberg A. Allergen immunotherapy-induced biphasic systemic reactions: incidence, characteristics, and outcome: a prospective study. *Ann Allergy Asthma Immunol*. 2010; 104:73. <https://doi.org/10.1016/j.anai.2009.11.001> PMID:20143649
5. Cortellini G, Corvetta A, Campi P, et al. A case of fatal biphasic anaphylaxis secondary to multiple stings: adrenalin and/or a longer observation time could have saved the patient? *Eur Ann Allergy Clin Immunol*. 2005; 37:343. PMID:16453966