

# Intralesional Neodymium YAG laser to Treat Complications of Polymethylmethacrylate

Alberto Goldman<sup>1</sup>, Uwe Wollina<sup>2\*</sup>

<sup>1</sup>*Clinica Goldman and Hospital Moinhos de Vento, Porto Alegre, Brazil;* <sup>2</sup>*Städtisches Klinikum Dresden, Academic Teaching Hospital Dresden, Department of Dermatology and Allergology, Dresden, Germany*

## Abstract

**Citation:** Goldman A, Wollina U. Intralesional Neodymium YAG laser to Treat Complications of Polymethylmethacrylate. Open Access Maced J Med Sci. <https://doi.org/10.3889/oamjms.2018.348>

**Keywords:** Permanent fillers; Polymethylmethacrylate; Adverse reactions; Intralesional Nd: YAG laser; Management of adverse filler events

**\*Correspondence:** Uwe Wollina. Städtisches Klinikum Dresden, Academic Teaching Hospital Dresden, Department of Dermatology and Allergology, Dresden, Germany. E-mail: [uwollina@gmail.com](mailto:uwollina@gmail.com)

**Received:** 18-Jul-2018; **Revised:** 23-Aug-2018; **Accepted:** 08-Sep-2018; **Online first:** 23-Sep-2018

**Copyright:** © 2018 Alberto Goldman, Uwe Wollina. This is an open-access article distributed under the terms of the Creative Commons Attribution-NonCommercial 4.0 International License (CC BY-NC 4.0)

**Funding:** This research did not receive any financial support

**Competing Interests:** The authors have declared that no competing interests exist

**BACKGROUND:** Dermal fillers are widely used for facial and body contouring. Polymethylmethacrylate (PMMA) is a permanent biphasic filler for soft tissue augmentation. In case of unwanted side effects, drug therapy and surgical excision have been commonly used with mixed results.

**AIM:** We report on a series of patients with adverse events to PMMA and an innovative minor invasive procedure to reduce disfigurement by nodules and lumps.

**METHODS:** We employed a subdermal, intralesional 1,064 nm neodymium-doped yttrium aluminium garnet (Nd:YAG) laser in combination with suction using a blunt liposuction cannula of 2.0-2.5 mm of diameter.

**RESULTS:** For 12 years, a total of 81 consecutive subjects (79 females and 2 males) were treated. The average age of the patients was 43.7 years (range 26 to 76 years). Granulomas and lumps could be removed in a minor invasive procedure with tumescent anaesthesia. In a minority of cases, the procedure had to be repeated. The results were impressive and not adverse events related to intralesional laser therapy were observed, 86.4% of patients were satisfied.

**CONCLUSION:** The procedure should be used before or in combination with classical surgery to remove PMMA in case of adverse tissue reactions to PMMA.

## Introduction

Dermal or soft tissue fillers are versatile tools for correction of wrinkles, loss of volume and facial sagging. A broad range of filler materials is available from biodegradable to permanent products [1] [2]. Polymethylmethacrylate (PMMA) is a hydrophobic permanent biphasic filler for soft tissue augmentation. PMMA microspheres are suspended in either collagen (like in ArteFill® or Artecoll®) or methylcellulose (like in MetaCrill®) [3]. PMMA (Bellafill®) is the only FDA-approved filler for the correction of atrophic acne scars [4] [5]. PMMA injections have become a fashion in Brazil and other Latin American countries during recent years, and various adverse events have been noted.

Filler injections complications have been classified as early (0–14 days), late (14 days to 1 year), or delayed (> 1 year) [6]. PMMA implants have the potential to elicit a cellular immune response in humans, although the mechanism of the late and ongoing inflammation, granuloma formation or nodules is not well understood [7]. One factor contributing to adverse events is the type and localisation of injection. In an animal study, submucosal injections were prone to nodularity in contrast to subcutaneous injections [8]. In humans, granulomatous reactions to PMMA are well-known. Other factors that are being discussed include infections, foreign body formation, and biofilms [7] [9] [10].

Early adverse events after PMMA injections include erythema, swelling and itching. PMMA has

been reported to cause in particular delayed and late adverse effect. In a study from Goiás, Brazil, the authors identified 11 cases of complications of PMMA injections to the midface which started from two to 24 months after the injection. Oedema, erythema, and contour irregularity were seen in 100% of patients, followed by nodules (64%), yellowish xanthomatous pigmentations (36%), and eyelid malposition (18%). Histopathology demonstrated an ongoing inflammation with giant cells. Corticosteroid injection was of minimal effect. Surgical removal was performed in 82% of cases and resulted in an improvement of oedema, erythema, and nodules [11]. Salles et al., [12] observed 32 complications during 15 years of PMMA injections for soft tissue augmentation. They reported acute tissue necrosis (n = 5), delayed granulomas (n = 10), and late chronic inflammatory reactions (n = 10). Lymphedema of the lips was noted in 6 patients, and infection was seen in a single patient [12]. The most severe adverse events observed with PMMA are extended soft tissue necrosis and blindness due to unintended intravascular injection [13] [14].

Many treatments were suggested to improve these symptoms including corticosteroids and other drugs injections, open surgeries, suction etc. Each adverse event requires a specific treatment or a combination of more than one approach. Acute infections warrant an adequate and specific antibiotics. Culture - if it possible - is mandatory. Granulomatous and inflammatory reactions can be treated with injections of steroids. However, the response is usually very poor. Side effects using steroids injection are very frequent including neovascular formation and subcutaneous adipose tissue atrophy. 5-Fluoracil also represents an alternative injection treatment for granuloma reaction. Oral allopurinol is occasionally employed for the treatment of inflammatory reaction. In our experience, the response was also very poor or limited. Traditional plastic surgery is trying to remove some amount of PMMA what usually represents a challenge. Fibrosis, subcutaneous tissue scarring and the proximity to important vascular and nerves plexus can lead to catastrophic complications. Specific regions such as the lips, nose, glabella, buttocks, legs, hands and penis are probably the most difficult areas to be treated [11] [12] [15].

## Patients and Methods

We analysed patients with adverse effects to polymethylmethacrylate (PMMA) injections in the face and body which had been treated between June 2006 and July 2018 at Clinica Goldman de Cirurgia Plastica and Hospital Moinhos de Vento, in Porto Alegre, Brazil. The great majority of our patients already used all the above-cited treatments without result, with very

poor improvement or event with exacerbation of the symptoms and deformities.

Often the adverse events had been delayed or late with the first occurrence even after 10, 15 or more years. Adverse late events suddenly appeared with erythema, unevenness, dislocation or migration of the product, pain, inflammatory reactions, deformities (sometimes bizarre deformities), nodules and granulomas, functional limitations and others. In our series, longer lasting redness is a very frequent adverse event. For many years such cases have been treated (initially in the face and after in breast, buttocks, chest, legs) using the subdermal 1,064nm neodymium-doped yttrium aluminium garnet (Nd: YAG) laser in continuous-wave mode. The treatment is based on the same concept as laser-lipolysis and laser-assisted liposuction.

With this procedure PMMA granulomas were treated by Nd: YAG laser in a total of 81 consecutive subjects who underwent the intralesional laser procedure, 79 were female and 2 male. The average age of the patients was 43.7 years (range 26 to 76 years).

All subjects underwent pre-operative assessment including autoimmune evaluation. All subjects provided informed consent. Imaging techniques were also employed in selected patients preoperatively (Figure 1). The procedures were performed in tumescent anaesthesia after subcutaneous infiltration of a solution containing lidocaine with vasoconstrictor and warm saline solution. The solution varies according to the area to be treated. Usually, all procedures in the face were made under local anaesthesia and sedation. Body procedures, including chest, penis, legs or buttocks were performed under general anaesthesia (intravenous anaesthesia). The laser power varied from 6 to 18W.

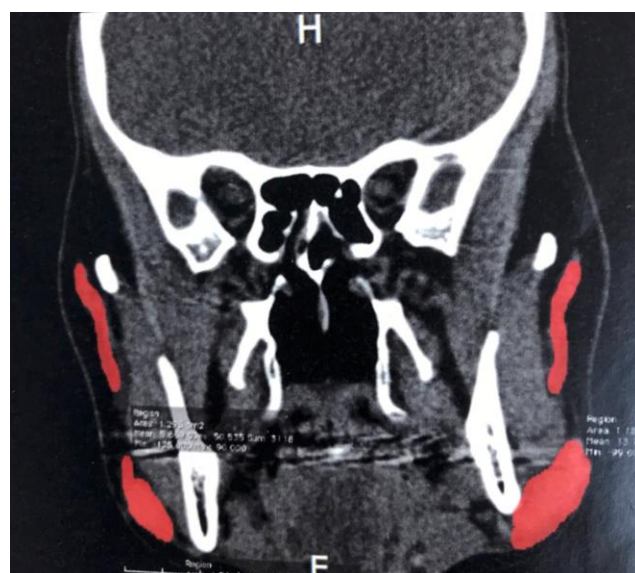


Figure 1: Magnetic resonance imaging demonstrating intense contrast impregnation in the mandibular region and pterygoid muscle (PMMA)

The laser energy is delivered to the affected tissue through a 300-600-micron fibre optic, embedded in a 1 or 1.6 mm diameter stainless steel micro-cannula of variable length. The distal portion of the fibre optic is extended approximately 2 mm beyond the distal end of the cannula allowing the direct contact of the laser energy with the organic tissue and synthetic material/granuloma. The helium-neon (He: Ne) laser source is combined into the laser beam allowing a precise visualisation of the region where the energy is acting, due to cutaneous transillumination (Figure 2).

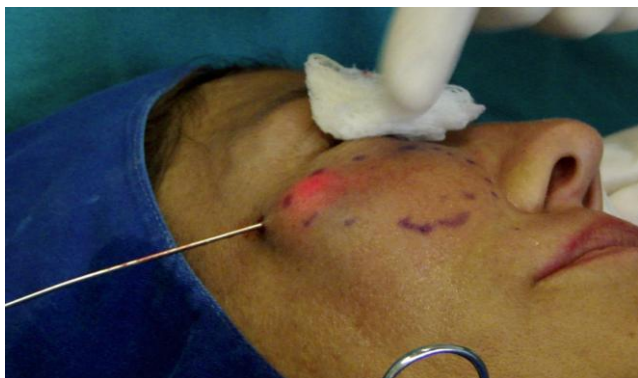

Figure 2: Granuloma in the malar region due to PMMA injection. Treatment by intralesional Nd: YAG laser

The cannula is moved intralesional within the tissue. The external skin temperature is controlled using a digital thermometer. The upper limit of skin temperature is 42° Celsius to avoid a potential skin burn. In some subjects, a thermal camera was used at the same time as the laser action, which provides an accurate and instantaneously skin and tissue temperature control. Cold compresses were applied in the treated laser region to maintain skin integrity and avoid skin damage. Laser treatment is delivered over a variable length of time according to the amount of granuloma, facial or body location, previous treatments, external scar, internal fibrosis and resistance.

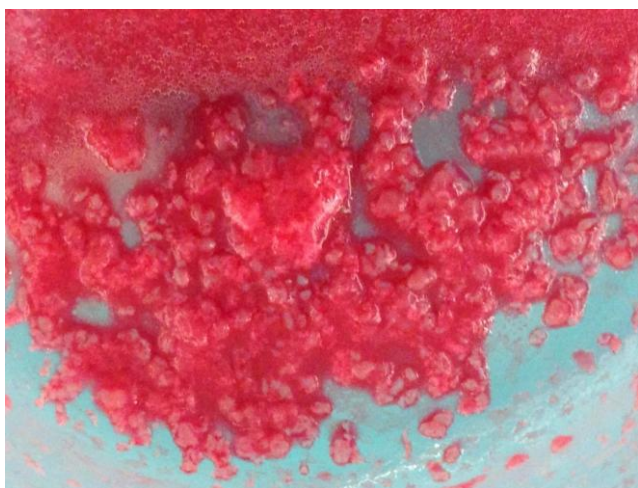

Figure 3: a Typical aspect of aspirated PMMA material after laser action

The main concept and aim of the internal laser treatment are to produce tunnels in the affected region and to disrupt the synthetic alloplastic filler facilitating the suction or its surgical excision.

Usually, the endpoint for the laser action is the temperature and mainly the resistance during cannula advancement in the fibrous tissue. The product of the laser action is removed using the negative pressure of around 450 mm Hg in conjunction with suction using a blunt liposuction cannula of 2.0-2.5 mm of diameter. The quantity of material removed from the patient varies according to each situation (Figure 3). The procedure lasts from 30 minutes to 3 hours.

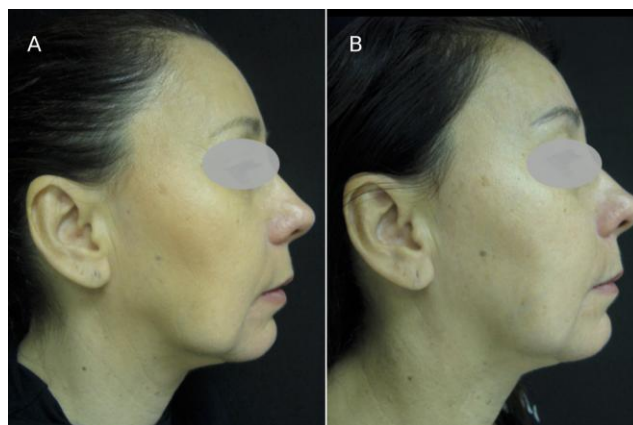

Figure 4: Before (a) and after (b) intralesional Nd: YAG laser therapy of PMMA-induced nodule on the mandibular margin

We have observed patients with a very small quantity of PMMA in the face but severe complications. At the same time, patients with a larger quantity of injected PMMA in the chest/breasts had no inflammatory problems, foreign body granulomas or other clinical manifestations after long years. Probably there is no relationship between the amount of removed material using laser and the clinical improvement as well. Many patients with very small PMMA volume injections in the face had an impressive clinical and aesthetic improvement after laser therapy (Figures 4, 5 and 6).

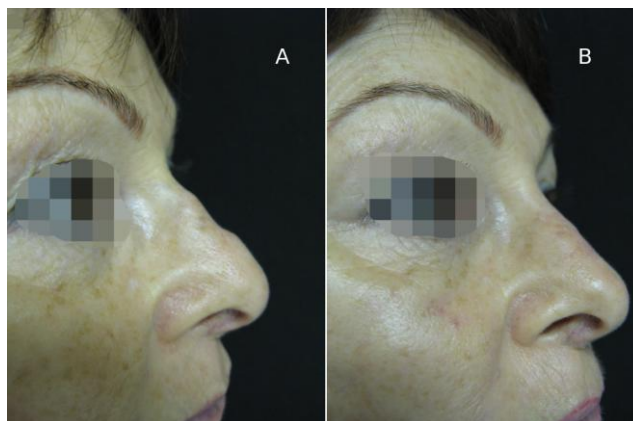

Figure 5: PMMA nodule of the nasal dorsum (a); After treatment with an intralesional laser (b)

Histological studies were performed in all subjects, focusing on the effects of the laser. The laser produces channels along the fatty tissue and fibrous tissue including the granulomas and the alloplastic filler material (Figure 7).

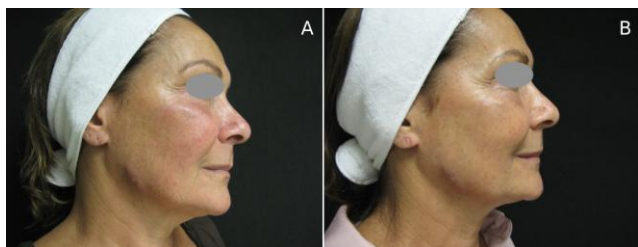

Figure 6: a Typical aspect of a patient with problems related to PMMA injection; (a) Plethoric face, inflammatory aspect, granulomas, deformities and some neovascular formations; (b) Result after intralesional laser treatment on the mandibular border, the malar and zygomatic region

The procedure had to be repeated twice in 8.6%, three times (4.9%), and four times (1.2%; chest and buttocks) for optimum results. Complications included four cases of late seroma. All solved with serial aspiration. No case of infection, burn or necrosis was observed. Transient unilateral temporary paresis of nerve branches was observed in 7 subjects. The paresis disappeared completely during a period of 3 weeks to 3 months.

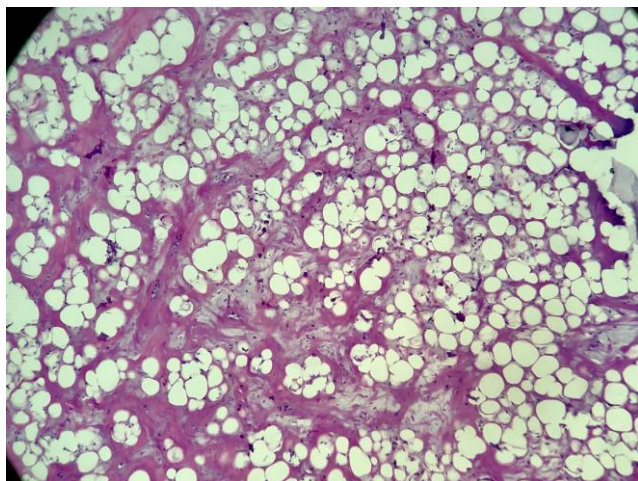


Figure 7: Histology demonstrates spherical particles of exogenous material morphologically compatible with PMMA surrounded by foreign body type granulomas, lymphocytic infiltrates and connective tissue with hyalinization (Hematoxylin-eosin, x4)

Since PMMA induces tissue fibrosis, the main idea was to create tunnels splitting (cleavage isolating the product) the material and fibrosis from the muscle, subcutaneous tissue, fascia, skin or mucosa using the laser as well as trying to disrupt the methacrylate into small particles facilitating the suction using small cannulas. After the laser action, a small cannula was used to aspirate this material. The aspirated material was always sent to the pathologist. In all cases, it was easily possible to identify foreign body material (PMMA) in great quantity and practically no fibrosis or

organic tissue around the PMMA. The quantity of PMMA removed without laser was much less than with laser energy.

Seventy of 81 patients (86.4%) were very satisfied by the outcome with an important improvement of the deformities in the mandibular border, malar region, lips and other body rejoin. We noted a substantial improvement of the clinical symptoms like pain, inflammation, nodules and redness.

Some of the patients suffered from other extra-cutaneous complaints such as hypercalcemia and renal dysfunction (creatinine elevation). These patients had PMMA in the breast, chest (male patient), and buttocks. All patients were submitted to subdermal laser treatment. In some patients, the procedure was repeated some months after the prior surgery. All patients had important clinical improvement, calcium level control and improvement in renal function. In another words - PMMA removal probably improved not only face and body deformities but systemic clinical complications produced or aggravated by the presence of PMMA.

The follow-up was up to 12 years without any relapse or later complications after Nd: YAG laser therapy.

## Discussion

In case of complications caused by filler injections systemic drugs (e.g. corticosteroids, antibiotics etc.) and surgical removal of the material are the most widely used methods [16]. For fillers based on hyaluronic acid, the injection of hyaluronidase is an efficient option [17].

Another possible treatment option would be the removal of the material by intralesional laser treatment. The first group using intralesional laser therapy to handle filler complications was Cassuto et al., [18]. They brought to action the 808 nm diode laser at 6 to 8W with a pulse duration of 500 ms to 1000 ms. Their laser fibre had a diameter of 200  $\mu$ m. The first twenty patients who were treated, reported a significant improvement of pain, tenderness, stiffness, and size of the nodules or granulomas [18]. The same group published a second paper including 219 patients. Complete disappearance of nodules and lumps was observed in 62%, partial improvement in 30% of patients [19].

Schalke et al., [20] combined an 810 nm diode laser (3-6 W) with a 1,470nm diode laser (0.6-0.8 W) in continuous-wave mode. They used fibre diameters between 200  $\mu$ m and 600  $\mu$ m for intralesional treatment of nodules and granulomas in 242 patients. In 92% of cases, they achieved an

improvement, in 9% a complete resolution.

The present study is the first one, using the intralesional Nd-YAG laser in analogy to laser lipolysis with the special focus on PMMA complications [21]. 86.4% of our patients were very satisfied. This is remarkable since we treated only patients with complications after PMMA injection in contrast to the other studies mentioned [18] [19] [20]. PMMA is more resistant to treatment than hyaluronic acid-fillers. With 81 patients treated for PMMA complications, this is one of the largest trials.

After puncturing the skin, a bare laser fibre is used to ensure a focused subdermal energy delivery. In this trial, the skin temperature was measured during laser action to prevent skin burns. It is important to avoid carbonisation of PMMA as well [18] [19] [20]. For removal of filler material, a blunt suction cannula with negative pressure was used in contrast to squeeze as suggested by others [18] [19] [20].

The laser energy interacts with adipose or connective tissue or - as in the present study - with PMMA. With the support of a pilot beam, the depth of the bare fibre can be visualised. The interaction of laser energy and polymer ions like PMMA can be described by the following formula:  $R + A + T = 1$ . The intensity of laser energy on the irradiated surface is  $I_0$ , the intensity of the reflected irradiation is  $I_R$ , and the intensity of the absorbed irradiation is coined  $I_A$ . The intensity of the transmitted irradiation is named  $I_T$ .  $R$  ( $I_R/I_0$ ) is the ratio of reflection,  $A$  ( $I_A/I_0$ ) the ratio of absorption, and  $T$  ( $I_T/I_0$ ) the ratio of the transmission.  $R$  is higher in crystalline structures than in amorphous structures such as PMMA [22]. The 1,064 nm Nd: YAG laser has a high transmission for PMMA. During laser contact to the polymer surface the temperature increases rapidly, but after cessation of laser irradiation the temperature drops down beneath the melting point of the polymer [23].

The laser energy can cause fragmentation of PMMA by (1) charge-directed fragmentations, (2) charge-remote rearrangements, and (3) charge-remote fragmentations via radical intermediates [24]. The Nd: YAG laser irradiation results in a shallow focal trough with radiating fractures [25] [26]. In a liquid microenvironment, microchannels can be produced [27].

We suppose that microchannels are part of the intralesional laser action in living tissue. Eventual fragmentation of the material allows its evacuation. The liquefaction, we and other observed, is partly due to laser lipolysis.

Intralesional laser therapy is a safe technique in the hands of experienced users. We observed 4 cases of seroma (5%) after the procedure. Burning, post-inflammatory hyperpigmentation, and scarring could be avoided by skin temperature monitoring. We have not observed sterile abscess formation in contrast to other studies [18] [19] [20]. Transient minor

impairment of facial nerves disappeared completely without intervention.

Our data argue for significantly improved removal of PMMA in subcutaneous tissue by Nd: YAG intralesional laser application. The procedure - if necessary - can be repeated.

Patients with adverse reactions to PMMA injection usually feel very insecure and depressed [28]. There is not a single definitive, safe and efficient treatment for all cases. Because of this, patients need to be informed regarding the limitation and expectation of each treatment. The necessity or convenience of retreatment using this intralesional laser treatment or even a combined approach must be discussed. It is important to be very clear about the fact that it is usually impossible to remove PMMA completely from the body or face. Clinical and immunologic associated problems such as hypercalcemia, lupus or rheumatic problems must also be treated. An interdisciplinary team, including dermatologist, plastic surgeon, rheumatologist, psychiatrist and other specialists, can lead to an improved and more effective global treatment. Although the intralesional Nd: YAG laser treatment has been shown to be effective and safe in this series, further studies are necessary to improve and clarify the utility of this technique.

Esthetic filler injections become increasingly popular. Those who perform injections of fillers need to know about potential adverse events, their prevention and treatment. The efficacy and favourable safety profile of intralesional laser treatment to treat PMMA-related complications suggest the use of this method before or in combination to classic surgery.

## References

1. Wollina U, Goldman A. Dermal fillers: facts and controversies. *Clin Dermatol*. 2013; 31(6):731-6. <https://doi.org/10.1016/j.clindermatol.2013.05.010> PMID:24160278
2. Attenello NH, Maas CS. Injectable fillers: review of material and properties. *Facial Plast Surg*. 2015; 31(1):29-34. <https://doi.org/10.1055/s-0035-1544924> PMID:25763894
3. Wollina U, Goldman A. Fillers for the improvement in acne scars. *Clin Cosmet Investig Dermatol*. 2015; 8:493-9. <https://doi.org/10.2147/CCID.S86478> PMID:26491364 PMID:PMC4598204
4. Karnik J, Baumann L, Bruce S, Callender V, Cohen S, Grimes P, et al. A double-blind, randomized, multicenter, controlled trial of suspended polymethylmethacrylate microspheres for the correction of atrophic facial acne scars. *J Am Acad Dermatol*. 2014; 71(1):77-83. <https://doi.org/10.1016/j.jaad.2014.02.034> PMID:24725475
5. Lemperle G, Sadick NS, Knapp TR, Lemperle SM. ArteFill permanent injectable for soft tissue augmentation: II. Indications and applications. *Aesthetic Plast Surg*. 2010; 34(3):273-86. <https://doi.org/10.1007/s00266-009-9414-0> PMID:19787393 PMID:PMC2872008
6. Sciafani AP, Fagien S. Treatment of injectable soft tissue filler

- complications. *Dermatol Surg.* 2009; 35 Suppl 2:1672-80.
7. Medeiros CC, Borghetti RL, Nicoletti N, da Silva VD, Cherubini K, Salum FG, et al. Polymethylmethacrylate dermal fillers: evaluation of the systemic toxicity in rats. *Int J Oral Maxillofac Surg.* 2014; 43(1):62-7. <https://doi.org/10.1016/j.ijom.2013.06.009> PMID:23871301
8. Park TH, Seo SW, Kim JK, Chang CH. Clinical experience with polymethylmethacrylate microsphere filler complications. *Aesth Plast Surg.* 2012; 36(2):421-6. <https://doi.org/10.1007/s00266-011-9803-z> PMID:21909864
9. de Jesus LH, de Campos Hildebrand L, Martins MD, da Rosa FM, Danilevicz CK, Sant'Ana Filho M. Location of injected polymethylmethacrylate microspheres influences the onset of late adverse effects: an experimental and histopathologic study. *Clin Cosmet Investig Dermatol.* 2015; 8:431-6. <https://doi.org/10.2147/CCID.S81467> PMID:26346665 PMCid:PMC4531029
10. Sadashivaiah AB, Mysore V. Biofilms: their role in dermal fillers. *J Cutan Aesthet Surg.* 2010; 3(1):20-2. <https://doi.org/10.4103/0974-2077.63257> PMID:20606988 PMCid:PMC2890130
11. Limongi RM, Tao J, Borba A, Pereira F, Pimentel AR, Akaishi P, et al. Complications and management of polymethylmethacrylate (PMMA) injections to the midface. *Aesthet Surg J.* 2016; 36(2):132-5. <https://doi.org/10.1093/asi/sjv195> PMID:26446059
12. Salles AG, Lotierzo PH, Gemperli R, Besteiro JM, Ishida LC, Gimenez RP, et al. Complications after polymethylmethacrylate injections: report of 32 cases. *Plast Reconstr Surg.* 2008; 121(5):1811-20. <https://doi.org/10.1097/PRS.0b013e31816b1385> PMID:18454007
13. Castro AC, Collares MV, Portinho CP, Dias PC, Pinto Rd. Extensive facial necrosis after infiltration of polymethylmethacrylate. *Braz J Otorhinolaryngol.* 2007; 73(6):850. [https://doi.org/10.1016/S1808-8694\(15\)31184-8](https://doi.org/10.1016/S1808-8694(15)31184-8)
14. Silva MT, Curi AL. Blindness and total ophthalmoplegia after aesthetic polymethylmethacrylate injection: case report. *Arq Neuropsiquiatr.* 2004; 62(3B):873-4.
15. Wolfram D, Tzankov A, Piza-Katzer H. Surgery for foreign body reactions due to injectable fillers. *Dermatology.* 2006; 213(4):300-4. <https://doi.org/10.1159/000096193> PMID:17135735
16. Urdiales-Gálvez F, Delgado NE, Figueiredo V, Lajo-Plaza JV, Mira M, Moreno A, et al. Treatment of soft tissue filler complications: Expert Consensus Recommendations. *Aesthetic Plast Surg.* 2018; 42(2):498-510. <https://doi.org/10.1007/s00266-017-1063-0> PMID:29305643 PMCid:PMC5840246
17. Rzany B, Becker-Wegerich P, Bachmann F, Erdmann R, Wollina U. Hyaluronidase in the correction of hyaluronic acid-based fillers: a review and a recommendation for use. *J Cosmet Dermatol.* 2009; 8(4):317-23. <https://doi.org/10.1111/j.1473-2165.2009.00462.x> PMID:19958438
18. Cassuto D, Marangoni O, De Santis G, Christensen L. Advanced laser technique for filler-induced complications. *Dermatol Surg.* 2009; 25(Suppl 2):1689-95.
19. Cassuto D, Pignatti M, Pacchioni L, Boscaini G, Spaggiari A, De Santis G. Management of complications caused by permanent fillers in the face: A treatment algorithm. *Plast Reconstr Surg.* 2016; 138:215e-27e.
20. Schelke LW, Decates TS, van der Lugt CIM, Pelzer L, de Mey G, Velthuis PJ. Intralesional laser treatment for dermal filler complications. *Plast Reconstr Surg.* 2018; 141(6):1361-9. <https://doi.org/10.1097/PRS.0000000000004428> PMID:29750756
21. Goldman A, Gotkin RH, Sarnoff DS, Prati C, Rossato F. Cellulite: a new treatment approach combining subdermal Nd: YAG laser lipolysis and autologous fat transplantation. *Aesthet Surg J.* 2008; 28(6):656-62. <https://doi.org/10.1016/j.asj.2008.09.002> PMID:19083594
22. Hänsch D. Die optischen Eigenschaften von Polymeren und ihre Bedeutung für das Durchstrahlschweißen mit Diodenlaser. *Berichte aus der Lasertechnik.* Aachen: Shaker-Verlag, 2001.
23. Schulze J-E. Material, process and component investigations at laser beam welding of polymers. *Rheinisch-Westfälische Technische Hochschule Aachen, Thesis,* 2002.
24. Wesdemiotis C, Solak N, Polce MJ, Dabney DE, Chaicharoen K, Katzenmeyer BC. Fragmentation pathways of polymer ions. *Mass Spectrom Rev.* 2011; 30(4):523-59. <https://doi.org/10.1002/mas.20282> PMID:20623599
25. Bath PE, Romberger AB, Brown P. A comparison of Nd:YAG laser damage thresholds for PMMA and silicone intraocular lenses. *Invest Ophthalmol Vis Sci.* 1986; 27(5):795-8.
26. Dick B, Schwenn O, Pfeiffer N. Extent of damage to different intraocular lenses by neodymium:YAG laser treatment - an experimental study. *Klin Monbl Augenheilkd.* 1997; 211(4):263-71. <https://doi.org/10.1055/s-2008-1035133> PMID:9445915
27. Acherjee B, Prakash S, Kuar AS, Mitra S. Grey relational analysis based optimization of underwater Nd: YAG laser micro-channeling on PMMA. *Procedia Engineering.* 2014; 97:1406-15. <https://doi.org/10.1016/j.proeng.2014.12.422>
28. Kunjur J, Witherow H. Long-term complications associated with permanent dermal fillers. *Br J Oral Maxillofac Surg.* 2013; 51(8):858-62. <https://doi.org/10.1016/j.bjoms.2013.06.013> PMID:23962591