

# Cyclooxygenase-2 Expression and Its Correlation with Primary Tumor Size and Lymph Node Involvement in Nasopharyngeal Carcinoma

Jessy Chrestella<sup>1</sup>, Farhat Farhat<sup>2\*</sup>, Elvita Rahmi Daulay<sup>3</sup>, Rizalina Arwinati Asnir<sup>2</sup>, Ashri Yudhistira<sup>2</sup>, Indah Afriani Nasution<sup>2</sup>

<sup>1</sup>Universitas Sumatera Utara, Fakultas Kedokteran, Pathology, Sumatera Utara, Indonesia; <sup>2</sup>Universitas Sumatera Utara Fakultas Kedokteran, Otorhinolaryngology Head and Neck Surgery Jl. Dr T. Mansyur No. 9, Medan, North Sumatera 20155, Indonesia; <sup>3</sup>Universitas Sumatera Utara Fakultas Kedokteran, Radiology, Medan, Sumatera Utara, Indonesia

## Abstract

**Citation:** Chrestella J, Farhat F, Daulay ER, Asnir RA, Yudhistira A, Nasution IA. Cyclooxygenase-2 Expression and Its Correlation with Primary Tumor Size and Lymph Node Involvement in Nasopharyngeal Carcinoma. Open Access Maced J Med Sci. 2018 Nov 25; 6(11):2001-2005. <https://doi.org/10.3889/oamjms.2018.356>

**Keywords:** Overexpression; Cyclooxygenase (COX)-2; Nasopharyngeal carcinoma; Tumor Size; Lymph node involvement

**\*Correspondence:** Farhat Farhat. Universitas Sumatera Utara Fakultas Kedokteran, Otorhinolaryngology Head and Neck Surgery Jl. Dr T. Mansyur No.9, Medan, North Sumatera 20155, Indonesia. E-mail: farhat@usu.ac.id

**Received:** 04-Sep-2018; **Revised:** 01-Nov-2018; **Accepted:** 04-Nov-2018; **Online first:** 19-Nov-2018

**Copyright:** © 2018 Jessy Chrestella, Farhat Farhat, Elvita Rahmi Daulay, Rizalina Arwinati Asnir, Ashri Yudhistira, Indah Afriani Nasution. This is an open-access article distributed under the terms of the Creative Commons Attribution-NonCommercial 4.0 International License (CC BY-NC 4.0)

**Funding:** This research did not receive any financial support

**Competing Interests:** The authors have declared that no competing interests exist

**AIM:** This study aimed to observe the cyclooxygenase-2 expression and its correlation with tumour size and lymph node involvement in nasopharyngeal carcinoma.

**METHODS:** This study was cross-sectional, that enrolled 126 samples diagnosed with nasopharyngeal carcinoma in Haji Adam Malik General Hospital, Medan, Indonesia which fulfilled the inclusion criteria.

**RESULTS:** Based on this study, we found that the age peak incidence of nasopharyngeal carcinoma patients about a 41-60-year-old group (57.1%), dominated by men (71.4%). Through histopathological examination, non-keratinizing squamous cell carcinoma is the most predominant type (79.4%). We also found T3 is the most prevalent primary tumour size (32.5%) with prominent lymph node involvement N3 (45.2%), and stage IV (54.8%). Cyclooxygenase-2 overexpression is prevalent among nonkeratinizing squamous cell carcinoma (81.1%), T3 primary tumour size (41.1%), N3 node involvement (60.0%), and IV clinical stage (71.6%). In addition, we found a significant relationship between cyclooxygenase-2 expressions towards tumor size ( $p < 0.001$ ) and lymph node involvement ( $p < 0.001$ ) in nasopharyngeal carcinoma.

**CONCLUSION:** It is proved that the overexpression of cyclooxygenase-2 will increase the susceptibility of nasopharyngeal carcinoma patients having advanced primary tumour size and lymph node involvement.

## Introduction

Nasopharyngeal carcinoma (NPC) is a malignancy originating from nasopharyngeal epithelial cells [1]. NPC incidence is dominated by Asia population, especially South China and South-East Asia [2]. In Indonesia, there are approximately 6.2 of 100,000 people diagnosed with NPC. Based on the data in 2008, NPC becomes the fifth leading cause of cancer mortality with annual incidence 13,000 [3].

Cyclopentane-fatty acid derivatives, largely known as prostaglandin, are produced in the human cell. It is well-known as a chemical mediator

of inflammation. Meanwhile, COX or prostaglandin endoperoxidase synthase is an enzyme involved in the formation of prostaglandin [4], [5]. COX has two isoforms: COX-1 and COX-2. For maintaining homeostasis, COX-1 is expressed by most cells. In contrast, COX-2 expression related to some pathological conditions, particularly in malignancy. COX-2 can induce angiogenesis and inhibit apoptosis. Also, COX-2 has a certain role in resistance to cancer immunotherapy [6], [7], [8], [9]. COX-2 converts arachidonic acid into five major prostanoids: PGE<sub>2</sub>, PGD<sub>2</sub>, PGI<sub>2</sub> (prostacyclin), PGF<sub>2</sub>α, and thromboxane A<sub>2</sub> (TXA<sub>2</sub>) [10], [11].

A number of studies have shown that COX-2 will induce angiogenesis by several mechanisms, such as (1) VEGF, it has been explained in the previous section; (2) formation of eicosanoid product (TXA<sub>2</sub>, PGI<sub>2</sub>, PGE<sub>2</sub>), it will directly stimulate endothelial formation, growth, and migration; (3) endothelial cell will be less susceptible to apoptotic by elevation anti-apoptotic Bcl-2 protein expression and activation of the PI3K-Akt pathway; (4) matrix metalloproteinase (MMP) will increase its expression, related to vascular invasion; (5) function of angiogenic protein will increase  $\alpha v \beta 3$  integrin; (6) IL-12 expression as angiogenesis inhibitor will decrease [2], [12], [13], [14], [15], [16], [17]. In another side the effect of COX-2 on angiogenesis, the effect of COX-2 on lymph nodes involvement still poorly understood but there is an opinion that said macrophages had been suggested as a major source of lymphangiogenic growth factor appeared chronic inflammatory lesions [18].

Our study will show that PGE<sub>2</sub> expression, the only one prostanoid, increase as a response to the COX-2 overexpression. COX-2/PGE<sub>2</sub> pathway proved its importance in stimulating myeloid-derived suppressor cells production. Myeloid cells can support tumour growth by suppressing immune function and induce angiogenesis [19], [20], [21], [22]. COX or prostaglandin endoperoxidase synthase is an enzyme involved in prostaglandin formation, and its existence is related to inflammation and tumour growth.

We looked at the COX-2 overexpression and compared them COX has two isoforms: COX-1 and COX-2. COX-2 is associated with prostaglandin synthesis in inflammatory tissues and neoplastic processes. In the previous study, COX-2 overexpression is well-documented involved in oncogenesis for certain malignancy, especially NPC [6], [23], [24], [25].

## Material and Methods

In this study researchers aimed to observe the cyclooxygenase-2 expression and its correlation with tumour size and lymph node involvement in nasopharyngeal carcinoma. This cross-sectional study enrolled 126 samples diagnosed with nasopharyngeal carcinoma in Haji Adam Malik General Hospital, Medan, Indonesia which fulfilled the inclusion criteria. This study was conducted to analyse the correlation between cyclooxygenase-2 overexpression with tumour size and lymph node involvement in nasopharyngeal carcinoma. It was also expected that it could be used as one of the factors that affect the prognosis in patients with nasopharyngeal carcinoma.

This cross-sectional study conducted in Haji Adam Malik General Hospital and pathology department, Medical Faculty of Universitas Sumatera Utara (USU), Medan, Indonesia. This study enrolled 126 patients diagnosed with NPC by doing anamnesis, physical examination, imaging studies, and histopathological examination.

Then, the samples had to fulfil the inclusion criteria, such as NPC patient diagnosed by histopathological examination and also had never undergone radiotherapy, chemotherapy, or in combination. If the paraffin blocks were not in good condition and the patients were positive with other malignancy, the subject would be excluded from the study. We used non-probability consecutive sampling to avoid tendency and bias and provided the demographic data including gender, age, and some variables related to the samples, condition, including histopathologic type (based on World Health Organization/WHO).

While primary tumour size (T), lymph node involvement (N), and clinical staging were listed based on the American Joint Committee on Cancer (AJCC) 2010 classification. Tissue sections from paraffin block embedded NPC biopsies were stained with Genetex Human COX-2 Antibody. Slides were incubated with the universal peroxidase-labelled polymer (PolyVuePlus) HRP/DAB Detection System and counterstained with hematoxylin. Then, the result classified into four categories by using broad and intensity score, such as 0 = negative, 1 = < 10% of the cell stained or weak-stained, 2 = 10-50% of cells stained or moderate-stained, 3 = > 50% of cells stained or strong-stained. COX-2 immunostaining expression on tissue sections of paraffin block NPC biopsies can be seen in Figure 1.

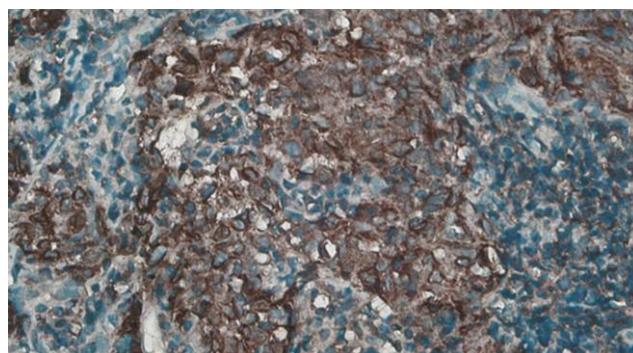


Figure 1: Strong cytoplasmic expression of COX-2 in non-keratinizing squamous cell nasopharyngeal carcinoma (x 400)

Eventually, the final score was obtained by multiplying broad scores with intensity scores. The score was called as immunoreactive scores, 4 or more defined as positive or overexpression. Histopathological examination and the process related to immunohistochemical staining were done by three professional pathologists.

The statistical analysis was done by using SPSS 16.0 software (SPSS, Chicago, IL). Demographic data were listed in a univariate variable. Then, bivariate analysis was performed using chi-square ( $\chi^2$ ) test to determine the relationship between COX-2 overexpression with primary tumour size and lymph node involvement in NPC. This study also had been approved by the Health Research Ethical Committee of Medical Faculty of Universitas Sumatera Utara, Medan, Indonesia.

## Results

This study was conducted on 126 NPC patients who fulfilled the inclusion criteria. The highest prevalence of NPC was found in the age group of IV to VI decades (57.1%), dominated by males (71.4%) with non-keratinizing squamous cell carcinoma (79.4%), primary tumor size T3 (32.5%), lymph node involvement N3 (45.2%), and clinical stadium IV (54.8%). Based on immunohistochemical examination overexpression of COX-2 were also found in nonkeratinizing squamous cell carcinoma, primary tumour size T3, lymph node involvement N3, and clinical stadium IV. Based on the results of this study, we found a significant relationship between COX-2 expression with tumour size and enlarged lymph nodes with a value of  $p < 0.001$ .

**Table 1: COX-2 overexpression frequency based on histopathology type, lymph node involvement (N) frequency, and clinical staging**

Type	COX-2 Expression			P**
	Over-expression	Negative	%	
<b>Histopathology</b>				0.253
Keratinizing SCC*	7	1	(12.5)	
Non-keratinizing SCC*	77	23	(23)	
Undifferentiated carcinoma	11	7	(38.9)	
<b>Primary Tumor Size (T)</b>				0.000
T1	5	20	(64.5)	
T2	24	8	(25.8)	
T3	39	2	(6.5)	
T4	27	1	(3.2)	
<b>Lymph node involvement (N)</b>				0.000
N0	9	18	(58.1)	
N1	14	5	(16.1)	
N2	15	8	(25.8)	
N3	57	0	(0.0)	
<b>Clinical staging</b>				0.000
I	2	15	(48.4)	
II	7	9	(29.0)	
III	18	6	(19.4)	
IV	68	1	(3.2)	

\*SCC: Squamous Cell Carcinoma

\*\*p: P-value

explains COX-2 overexpression is more common in advanced primary tumour size and lymph node involvement. Bin Yang et al., also discovered the same result related to COX-2 overexpression and malignant process, including metastasis [26]. A study conducted by Gui Yang et al., also found that COX-2 and advanced clinical stage of NPC are positively correlated (OR 5.39; 95% CI: 3.79-7.66) [27]. Also, One study conducted by Li et al. found by using nasopharyngeal carcinoma cell lines treated with nonsteroid anti-inflammatory drugs (NSAIDs), particularly celecoxib, invasion, and migration will decrease through suppression of MMP-2 and -9 activity [28]. Fendri et al., also discovered the similar result related to COX-2 overexpression that There was a significant association between COX-2 expression with lymph node involvement (N+) in NPC patients with  $p < 0.0001$  [29].

Besides VEGF, Epidermal growth factors (EGF) also play an important role in tumour proliferation and invasion. Ross found that COX-2 overexpression occurred in 79% of NPC patients, and it related to EGFR status but not with latent membrane protein (LMP) -1 or inducible NOS. Meanwhile, Tan K-B prevailed that COX-2 might be involved in the multistep process of NPC carcinogenesis since the COX-2 expression is more common in a dysplastic nasopharyngeal cell [30], [31]. It is also stated by Kwong et al. which enrolled 53 NPC patients, all patients who had intense staining for COX-2 were dysplastic [32]. Many clinical studies have shown that COX-2 induces angiogenesis, but there is no evidence to prove the relationship between COX-2 and lymph node involvement although many previous studies suggested that expression of COX-2 correlated with lymph node metastasis [18].

Also, a prognostic study conducted by Pan et al. uncovered that survival rate, including overall survival, disease-free survival, locoregional control, and distant metastasis-free survival are also related to COX-2 overexpression. Chen et al. conducted a study in T4 NPC patients treated with radiation therapy, 5-year survival rates for patients who have COX-2 overexpression was 27% compared with 60% in low COX-2 expression group. Furthermore, Xinhua et al., also stated that COX-2 might be used to predict prognosis, particularly local recurrence and distant metastasis [33], [34], [35]. Prognostic study related to COX-2 overexpression was evident in many cancer one of them is glottis cancer, COX-2 overexpression related to more aggressive tumour and low survival rate [36], [37], [38]. Otherwise, Long et al., and Y. J. Kim et al. found a contradictive result in our study. By using smaller sample sizes, both studies concluded that COX-2 expression and tumour size did not correlate [39], [40].

Our study provided evidence that the correlation between COX-2 overexpression with primary tumour size and lymph node involvement

## Discussion

In our study, a positive correlation between COX-2 overexpression with primary tumour size and lymph node involvement was proved in NPC. It

are significant ( $p < 0.001$ ). The COX-2 expression will increase as the tumor size increases. COX-2 overexpression is one of the tumor lymphangiogenesis factors. Also, COX-2 contributes in the process of carcinogenesis, and it allows COX-2 to be used as a therapeutic target in the future for nasopharyngeal carcinoma.

## References

- Chua ML, Wee JT, Hui EP, Chan AT. Nasopharyngeal carcinoma. *The Lancet*. 2016; 387(10022):1012-24. [https://doi.org/10.1016/S0140-6736\(15\)00055-0](https://doi.org/10.1016/S0140-6736(15)00055-0)
- Wang Z, Dabrosin C, Yin X, Fuster MM, Arreola A, Rathmell WK, Generali D, Nagaraju GP, El-Rayes B, Ribatti D, Chen YC. Broad targeting of angiogenesis for cancer prevention and therapy. *In Seminars in cancer biology*. 2015; 35:S224-S243. <https://doi.org/10.1016/j.semcancer.2015.01.001> PMID:25600295 PMCid:PMC4737670
- Adham M, Kurniawan AN, Muhtadi AI, Roezin A, Hermani B, Gondhwiardjo S, Tan IB, Middeldorp JM. Nasopharyngeal carcinoma in Indonesia: epidemiology, incidence, signs, and symptoms at presentation. *Chinese journal of cancer*. 2012; 31(4):185. <https://doi.org/10.5732/cjc.011.10328> PMID:22313595 PMCid:PMC3777476
- Divvela AK, Challa SR, Tagaram IK. Pathogenic role of cyclooxygenase-2 in cancer. *Journal of Health Science*. 2010; 56(5):502-16. <https://doi.org/10.1248/jhs.56.502>
- Smith WL, Song I. The enzymology of prostaglandin endoperoxide H synthases-1 and-2. Prostaglandins & other lipid mediators. 2002; 68:115-28. [https://doi.org/10.1016/S0090-6980\(02\)00025-4](https://doi.org/10.1016/S0090-6980(02)00025-4)
- Chen W, Hu GH. Biomarkers for enhancing the radiosensitivity of nasopharyngeal carcinoma. *Cancer biology & medicine*. 2015; 12(1):23. PMID:25859408 PMCid:PMC4383846
- Sobolewski C, Cerella C, Dicato M, Ghibelli L, Diederich M. The role of cyclooxygenase-2 in cell proliferation and cell death in human malignancies. *International journal of cell biology*. 2010; 2010.
- Liu B, Qu L, Yan S. Cyclooxygenase-2 promotes tumor growth and suppresses tumor immunity. *Cancer cell international*. 2015; 15(1):106. <https://doi.org/10.1186/s12935-015-0260-7> PMID:26549987 PMCid:PMC4635545
- Dixon DA. Regulation of COX-2 expression in human cancers. *COX-2*. 2003; 37:52-71).
- Rouzer CA, Marnett LJ. Cyclooxygenases: structural and functional insights. *Journal of lipid research*. 2009; 50(Suppl):S29-34. <https://doi.org/10.1194/jlr.R800042-JLR200> PMID:18952571 PMCid:PMC2674713
- Clària J. Cyclooxygenase-2 biology. *Current pharmaceutical design*. 2003; 9(27):2177-90. <https://doi.org/10.2174/1381612033454054> PMID:14529398
- Gately S, Li WW. Multiple roles of COX-2 in tumor angiogenesis: a target for antiangiogenic therapy. *Seminars in Oncology*. 2004; 31:2-11. <https://doi.org/10.1053/j.seminoncol.2004.03.040> PMID:15179620
- Imig JD. Epoxyeicosatrienoic acids and 20-hydroxyeicosatetraenoic acid on endothelial and vascular function. *Advances in Pharmacology*. 2016; 77:105-141. <https://doi.org/10.1016/bs.apha.2016.04.003> PMID:27451096 PMCid:PMC5510644
- Liu CH, Chang SH, Narko K, Trifan OC, Wu MT, Smith E, Haudenschild C, Lane TF, Hla T. Overexpression of cyclooxygenase-2 is sufficient to induce tumorigenesis in transgenic mice. *Journal of Biological Chemistry*. 2001; 276(21):18563-9. <https://doi.org/10.1074/jbc.M010787200> PMID:11278747
- Huang T, Chen MH, Wu MY, Wu XY. Correlation between expression of extracellular matrix metalloproteinase inducer and matrix metalloproteinase-2 and cervical lymph node metastasis of nasopharyngeal carcinoma. *Annals of Otolaryngology, Rhinology & Laryngology*. 2013; 122(3):210-5. <https://doi.org/10.1177/000348941312200311> PMID:23577575
- Lasek W, Zagożdżon R, Jakobisiak M. Interleukin 12: still a promising candidate for tumor immunotherapy? *Cancer Immunology, Immunotherapy*. 2014; 63(5):419-435. <https://doi.org/10.1007/s00262-014-1523-1> PMID:24514955 PMCid:PMC3994286
- Gately S. The contributions of cyclooxygenase-2 to tumor angiogenesis. *Cancer and metastasis reviews*. 2000; 19(1-2):19-27. <https://doi.org/10.1023/A:1026575610124> PMID:11191059
- Iwata C, Kano MR, Komuro A, Oka M, Kiyono K, Johansson E, Morishita Y, Yashiro M, Hirakawa K, Kaminishi M, Miyazono K. Inhibition of cyclooxygenase-2 suppresses lymph node metastasis via reduction of lymphangiogenesis. *Cancer Research*. 2007; 67(21):10181-9. <https://doi.org/10.1158/0008-5472.CAN-07-2366> PMID:17974958
- Lu X, Qian CN, Mu YG, Li NW, Li S, Zhang HB, Li SW, Wang FL, Guo X, Xiang YQ. Serum CCL2 and serum TNF- $\alpha$ —Two new biomarkers predict bone invasion, post-treatment distant metastasis and poor overall survival in nasopharyngeal carcinoma. *European journal of cancer*. 2011; 47(3):339-46. <https://doi.org/10.1016/j.ejca.2010.09.025> PMID:20951575
- Elliott LA, Doherty GA, Sheahan K, Ryan EJ. Human tumor-infiltrating myeloid cells: phenotypic and functional diversity. *Frontiers in immunology*. 2017; 8:86. <https://doi.org/10.3389/fimmu.2017.00086> PMID:28220123 PMCid:PMC5292650
- Schmid MC, Varner JA. Myeloid cells in the tumor microenvironment: modulation of tumor angiogenesis and tumor inflammation. *Journal of oncology*. 2010; 2010.
- Cotechini T, Medler TR, Coussens LM. Myeloid cells as targets for therapy in solid tumors. *Cancer journal (Sudbury, Mass.)*. 2015; 21(4):343. <https://doi.org/10.1097/PP0.0000000000000132> PMID:26222088 PMCid:PMC4948591
- Iacovelli N, et al. Emerging prognostic factors in Nasopharyngeal carcinoma. *Journal of Nasopharyngeal Carcinoma*. 2014; 1(8).
- Kim TJ, Lee YS, Kang JH, Kim YS, Kang CS. Prognostic significance of expression of vegf and cox-2 in nasopharyngeal carcinoma and its association with expression of C-erbB2 and EGFR. *Journal of surgical oncology*. 2011; 103(1):46-52. <https://doi.org/10.1002/jso.21767> PMID:21031415
- Chou J, Lin YC, Kim J, You L, Xu Z, He B, Jablons DM. Nasopharyngeal carcinoma—review of the molecular mechanisms of tumorigenesis. *Head & Neck: Journal for the Sciences and Specialties of the Head and Neck*. 2008; 30(7):946-63. <https://doi.org/10.1002/hed.20833> PMID:18446839 PMCid:PMC3046044
- Wu YD, Zhou BP. TNF- $\alpha$ /NF- $\kappa$ B/Snail pathway in cancer cell migration and invasion. *British journal of cancer*. 2010; 102(4):639. <https://doi.org/10.1038/sj.bjc.6605530> PMID:20087353 PMCid:PMC2837572
- Yang G, Deng Q, Fan W, Zhang Z, Xu P, Tang S, Wang P, Yu M. Cyclooxygenase-2 expression is positively associated with lymph node metastasis in nasopharyngeal carcinoma. *PloS one*. 2017; 12(3):e0173641. <https://doi.org/10.1371/journal.pone.0173641> PMID:28301518 PMCid:PMC5354404
- Soo R, Putti T, Tao Q, Goh BC, Lee KH, Kwok-Seng L, Tan L, Hsieh WS. Overexpression of cyclooxygenase-2 in nasopharyngeal carcinoma and association with epidermal growth factor receptor expression. *Archives of Otolaryngology—Head &*

- Neck Surgery. 2005; 131(2):147-52. <https://doi.org/10.1001/archotol.131.2.147> PMID:15723947
29. Fendri A, Khabir A, Hadhri-Guiga B, Sellami-Boudawara T, Ghorbel A, Daoud J, Frikha M, Jlidi R, Gargouri A, Mokdad-Gargouri R. Overexpression of COX-2 and LMP1 are correlated with lymph node in Tunisian NPC patients. *Oral oncology*. 2008; 44(7):710-5. <https://doi.org/10.1016/j.oraloncology.2007.09.006> PMID:18061524
30. Li WW, Long GX, Liu DB, Mei Q, Wang JF, Hu GY, Jiang JZ, Sun W, Gan L, Hu GQ. Cyclooxygenase-2 inhibitor celecoxib suppresses invasion and migration of nasopharyngeal carcinoma cell lines through a decrease in matrix metalloproteinase-2 and-9 activity. *Die Pharmazie-An International Journal of Pharmaceutical Sciences*. 2014; 69(2):132-7.
31. Tan KB, Putti TC. Cyclooxygenase 2 expression in nasopharyngeal carcinoma: immunohistochemical findings and potential implications. *Journal of clinical pathology*. 2005; 58(5):535-8. <https://doi.org/10.1136/jcp.2004.021923> PMID:15858127 PMCID:PMC1770665
32. Kwong DL, Nicholls J, Sham J. Cyclooxygenase-2 expression in nasopharyngeal carcinoma. *International Journal of Radiation*. 2007.
33. Pan J, Tang T, Xu L, Lu JJ, Lin S, Qiu S, Chen G, Tham IW. Prognostic significance of expression of cyclooxygenase-2, vascular endothelial growth factor, and epidermal growth factor receptor in nasopharyngeal carcinoma. *Head & neck*. 2013; 35(9):1238-47. <https://doi.org/10.1002/hed.23116> PMID:22972415
34. Chen WC, McBride WH, Chen SM, Lee KF, Hwang TZ, Jung SM, Shau H, Liao SK, Hong JH, Chen MF. Prediction of poor survival by cyclooxygenase-2 in patients with T4 nasopharyngeal cancer treated by radiation therapy: Clinical and in vitro studies. *Head & Neck: Journal for the Sciences and Specialties of the Head and Neck*. 2005; 27(6):503-12. <https://doi.org/10.1002/hed.20178> PMID:15772955
35. Xinhua XU, Guoqing HU, Song LI, Feng XU, Daojun LI, Delan DA, Yan CH. Expression of cyclooxygenase-2 in nasopharyngeal carcinoma and its relation to angiogenesis and prognosis. *The Chinese-German Journal of Clinical Oncology*. 2006; 5(2):104-7. <https://doi.org/10.1007/s10330-005-0400-y>
36. Chang BW, Kim DH, Kowalski DP, Burleson JA, Son YH, Wilson LD, Haffty BG. Prognostic significance of cyclooxygenase-2 in oropharyngeal squamous cell carcinoma. *Clinical cancer research*. 2004; 10(5):1678-84. <https://doi.org/10.1158/1078-0432.CCR-03-0354> PMID:15014019
37. Gallo O, Masini E, Bianchi B, Bruschini L, Paglierani M, Franchi A. Prognostic significance of cyclooxygenase-2 pathway and angiogenesis in head and neck squamous cell carcinoma. *Human pathology*. 2002; 33(7):708-14. <https://doi.org/10.1053/hupa.2002.125376> PMID:12196922
38. Loong SL, Hwang JS, Li HH, Wee JT, Yap SP, Chua ML, Fong KW, Tan TW. Weak expression of cyclooxygenase-2 is associated with poorer outcome in endemic nasopharyngeal carcinoma: analysis of data from randomized trial between radiation alone versus concurrent chemo-radiation (SQNP-01). *Radiation Oncology*. 2009; 4(1):23. <https://doi.org/10.1186/1748-717X-4-23> PMID:19591688 PMCID:PMC2715417
39. Kim YJ, Lee SH, Wu HG, Go H, Jeon YK. Immunohistochemical study to evaluate the prognostic significance of four biomolecular markers in radiotherapy of nasopharyngeal carcinoma. *J Korean Soc Ther Radiol Oncol*. 2010; 28(2):57-63. <https://doi.org/10.3857/jkstro.2010.28.2.57>
40. Sackett MK, Bairati I, Meyer F, Jobin É, Lussier S, Fortin A, Gélinas M, Nabid A, Brochet F, Têtu B. Prognostic significance of cyclooxygenase-2 overexpression in glottic cancer. *Clinical Cancer Research*. 2008; 14(1):67-73. <https://doi.org/10.1158/1078-0432.CCR-07-2028> PMID:18172254