

# Computer-Aided Design/Computer-Aided Manufacturing Cutting Guides for Odontectomy of Deeply Impacted Mandibular Third Molars

Mamdouh Ahmed<sup>\*</sup>, Mariam Kamel Salah, Nesrine Khairy

*Faculty of Dentistry, Cairo University, Oral and Maxillofacial Department 11 Al Saraya, Al Manial, Giza Governorate 11553, Egypt*

## Abstract

**Citation:** Ahmed M, Salah MK, Khairy N. Computer-Aided Design/Computer-Aided Manufacturing Cutting Guides for Odontectomy of Deeply Impacted Mandibular Third Molars. *Open Access Maced J Med Sci.* <https://doi.org/10.3889/oamjms.2018.371>

**Keywords:** Deeply impacted mandibular third molar (DIMITM); Inferior alveolar nerve (IAN) injury; Computer guided cutting guide; External oblique ridge

**\*Correspondence:** Mamdouh Ahmed, Faculty of Dentistry, Cairo University, Oral and Maxillofacial Department 11 Al Saraya, Al Manial, Giza Governorate 11553, Egypt. E-mail: [mamdouh.ahmed@dentistry.cu.edu.eg](mailto:mamdouh.ahmed@dentistry.cu.edu.eg)

**Received:** 06-Oct-2018; **Revised:** 06-Nov-2018; **Accepted:** 09-Nov-2018; **Online first:** 19-Dec-2018

**Copyright:** © 2018 Mamdouh Ahmed, Mariam Kamel Salah, Nesrine Khairy. This is an open-access article distributed under the terms of the Creative Commons Attribution-NonCommercial 4.0 International License (CC BY-NC 4.0)

**Funding:** This research did not receive any financial support

**Competing Interests:** The authors have declared that no competing interests exist

**AIM:** To evaluate a new technique for surgical removal of deeply impacted mandibular third molars (DIMITM), using computer-guided cutting guide to maintain inferior alveolar nerve (IAN) integrity and the covering buccal bone.

**PATIENTS AND METHODS:** Eighteen cases indicated for removal of DIMITM. Cone-beam Computed Tomography (CBCTs) used to determine the tooth's relation to the IAN. Computer-guided software used for fabrication of surgical cutting guide stent to expose the impacted tooth and repositioning of bone after odontectomy without fixation. Clinical assessment included a neurosensory deficit of IAN, pain using a visual analogue scale (VAS), facial swelling, and maximal mouth opening (MMO). CBCTs were taken immediately and six months postoperatively to evaluate position and healing of bone.

**RESULTS:** None of the patients showed a permanent neurological deficit of IAN while all patients showed normal parameters of pain, facial swelling and MMO.

**CONCLUSION:** this technique has shown the accurate determination of the bony window cuts with subsequent preservation of IAN and external oblique ridge.

## Introduction

Impaction of mandibular third molars is a commonly encountered condition that often proves to be problematic and with a higher incidence of iatrogenic complications during its removal. Newly published data revealed that 72, 2% of the entire world's population has at least one impacted tooth (usually lower third molar) [1], [2], [3], [4]. Santosh P in 2015 [5] stated that IAN injury post third molar extraction is a well-recognised complication with the reported risk of 0.26–8.4%. Tingling, numbness, burning or throbbing sensations in the ipsilateral lower

lip, chin and gingiva are customary manifestations. The contributing factors reported include; age, infection history, rotatory tool utilisation, operator skills and location of the impaction. However, the most important factor is the anatomic approximation of the molar roots to the nerve [5], [6], [7].

Nowadays 3d cone beam computed tomography (3D CBCT) are becoming preferable for proper treatment planning and assessment of difficulty indices to digital panoramic radiographs [8], [9].

Numerous methods were proposed for surgical removal of deeply impacted mandibular wisdom including the lingual split-bone technique, coronoidectomy technique, orthodontic extraction

technique and even an extra-oral approach. Nonetheless, the two most encountered complications are still excessive bone removal and high possibility of inferior alveolar nerve (IAN) affection [10], [11], [12], [13], [14], [15], [16].

To simultaneously preserve the buccal bone at the external oblique ridge and afford accessibility for deeply impacted third molars; many case reports have been published that suggested sagittal split ramus osteotomy (SSRO) for odontectomy, followed by fixations of bony segments [18], [19], [20], [21].

The technique published by Ahmed M. in 2016 [22] was innovative in combining two different surgical procedures through harvesting the overlying buccal plate of bone at the external oblique ridge and its relocation after odontectomy without fixation. Although CBCTs were suitable in determining the position and relation of impacted molars to the IAN, linear measurements were made and transferred to the rectangular design of the osteotomized bony segment targeting to expose the impacted tooth till its furcation adequately. However, determining the position of the osteotomy and the angulation was based on arbitrary measurements [22].

Computer-aided design/computer-aided manufacturing (CAD/CAM) techniques are virtual planning software tools which provide anatomically accurate samples of a patient's hard tissue structures. The CAD/CAM cutting guides fabrication can provide adequate information regarding proper cutting planes and maintain the IAN integrity; thus, they may help in treatment planning and outcome prediction of a wide variety of oral and maxillofacial surgeries [22], [23], [24].

In the present study, we aimed to evaluate CAD/CAM cutting guide fabrication for simple osteotomy positioning and segment realignment during odontectomy of deeply impacted third molar tooth for adequate tooth exposure and maximum nerve protection.

## Patients and Methods

We confirm that the present study runs in concordance with international ethical guidelines and applicable local regulatory laws. The ethical approval was obtained from the institutional review board (IRB) of Oral and Maxillofacial Surgery Department, Faculty of Dentistry, Cairo University (ethical approval number: 17-11-10). Informed written consent was obtained from every eligible patient before study enrollment.

The present prospective cohort study was conducted on eighteen cases selected from outpatient clinics of the Oral and Maxillofacial

Surgery Department, Faculty of Dentistry, Cairo University. The sample size was determined by the medical biostatistics unit (MBU) in the Faculty of Dentistry, Cairo University. Patient's age ranged from 20 to 29 years with a mean of 24.5 years. We included adult patients who met the following criteria: 1) patients with deeply impacted mandibular third molar tooth who were complicated for extraction according to Juodzbalys and Daugela [3]; 2) patients who were classified as American Society of Anesthesiologist's (ASA) [1]; and

3) patients who were fit for surgical removal under general anesthesia. Patients with medically compromised conditions or pregnant women were excluded from the study.

Preoperatively, patients were subjected to detailed medical history and full clinical examination. Then, preoperative CBCTs (Scanora 3D Soredex Finland 85kv-15Ma) were obtained for diagnosis, determining IAN proximity, and developing the cutting guide fabrication respectively (Figure 1A and B).

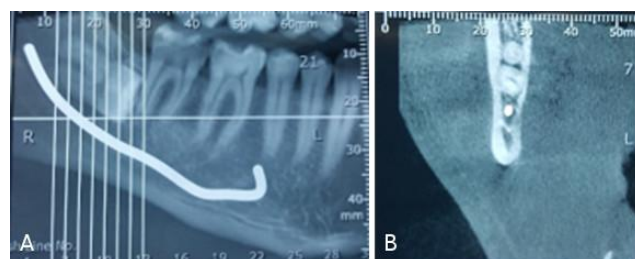


Figure 1: A) and B) Radiographic pictures of pre-operative CBCTs to determine the position of the impacted molar about the IAN

The CBCT-based DICOM images were imported into virtual surgical planning software (Mimics Edition15, Materialise Innovations, Leuven, Belgium). The area of interest at the mandibular external oblique ridge was delineated, and three virtual cutting (two vertical and one horizontal) planes were designed simulating the positions of the two vertical and inferior osteotomies of the bony window. These virtual cuts were planned guided by the position of the impacted molar about the IAN, and the adjacent second molar aiming to expose the crown till the furcation area (Figure 2A).

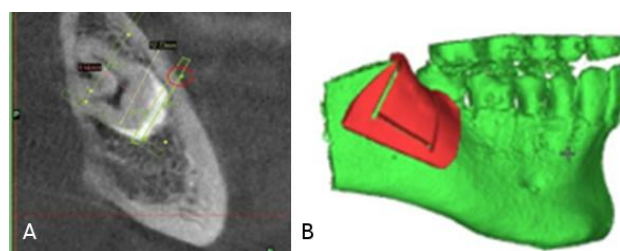


Figure 2: A) CBCT as DICOM files with virtual surgical planning determining the vertical cutting plans; B) Matic software with bone - borne cutting guide with the virtual cutting slots

The two vertical cuts were planned with lingual convergence. This step was followed by exporting the surgical plan to the next specialised software, 3-Matic (Materialise Innovations, Leuven, Belgium), this software was used to design a bone – borne cutting guide with the three virtual osteotomies slots (Figure 2B). 3D printing by Fused Deposition Modeling (FDM) technique (Ultimaker 2 3D printer, model number: UM2) was used to fabricate a 2 mm thick guide of polylactide (PLA); this thickness offered enough rigidity while not interfering with the radius of the cutting disc. The overall average working time of virtual planning and 3D printing was 70-85 minutes.

The cutting guide was designed by the Corresponding author using Mimics Edition15 and 3-Matic software. It took 20-30 minutes to finish the design, and the printing of the cutting guide cost about 15 dollars for each case.

All surgical procedures were performed by the same operator, to minimise the technical variables. Preoperatively, patients received a loading dose (1.5 gm) of Ampicillin/Sulbactam intravenously and local infiltration of 4% articaine HCL with 1:100,000 vasoconstrictor (Septanest SP, Septodont pharmaceutical Industries, France). A three-line mucoperiosteal flap was performed to expose the field. The surgical guide was fixed in place using a single 2.0 mini screw (Figure 3A). Two vertical cuts with lingual convergence were made through the buccal bony plate, using a reciprocating saw (Figure 3B). The inferior horizontal cut was performed perpendicularly or with slight downward divergence, connecting the two vertical cuts, using 0.3mm thickness FRIOS Micro Saw disc. The radius of the Micro Saw disc is 3.2 mm; this permitted monocortical bone osteotomy (Figure 3C). To finish off the rectangular design, the surgical guide was removed, and the superior horizontal cut was done using the reciprocating saw. Lastly, the disc and saw were used to revise all the cuts. Adopting the same technique of Ahmed M [22], chisels were used for splitting the bony window (Figure 3D and E).

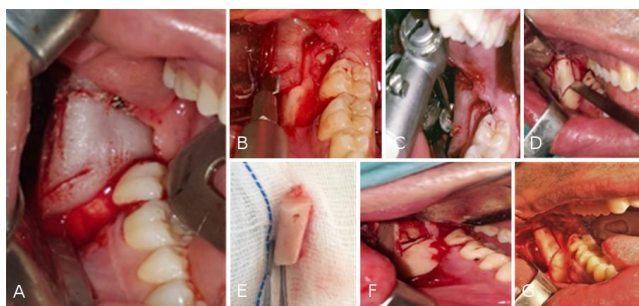


Figure 3: A) The surgical cutting guide in place; B) the reciprocating saw; C) The FRIOS micro saw disc; D) The bony window cuts and the chisel for splitting the segment; E) The osteotomized bony segment; F) The impacted molar with the furcation after separation; G) The repositioning of the osteotomized bony segment after odontectomy

Following odontectomy, the surgical site was debrided, irrigated; and accurate repositioning of the osteotomized bone segment was carried out without fixation (Figure 3F and G). Closure of the flap was performed with 3-0 Vicryl sutures. Postoperative instructions were given, and patients were prescribed antibiotics, analgesics, and mouthwash.

Patients were followed-up postoperatively at 3, 7 and 14 days. Neurosensory testing, including an objective assessment of patients using the pinprick and light touch tests, were used, at 7th day postoperatively and the results were categorised as normal or abnormal [25]. The study's outcomes were:

1) The radiographic parameters for the osteotomy position and bone healing which were evaluated using CBCTs immediately and six months postoperatively.

2) The severity of postoperative pain using visual analogue scale (VAS), the VAS is a psychometric 0-10 scale with '0' being 'No Pain' and '10' being 'Most Severe Pain [26].

3) Facial swelling was recorded using 2-0 nylon threads and a millimetre ruler. Measurements were done bilaterally from the tip of the tragus to the gonium, three times for each patient and the average value recorded in centimetres [27].

4) Maximal mouth opening (MMO) which was measured using a digital millimetre scale pre and postoperatively on the 3rd, 7th and 14th day, values were recorded in centimetres [27].

5) Incidence of alveolar osteitis and wound dehiscence.

Data were analysed using SPSS software (Statistical Package for the Social Sciences, version 24, SSPS Inc, Chicago, IL, USA). Frequency tables with percentages were used for categorical variables, and descriptive statistics (either means with standard deviation or median with range) were used for numerical variables, according to the normality of the data. Paired t-test was used to compare the change in VAS scores, while repeated measures analysis of variance (ANOVA) test was used to compare facial swelling and the change in MMO. This was followed by Tukey's post hoc test when ANOVA revealed a significant difference for numerical variables. A p-value less than 0.05 was considered statistically significant.

ANOVA was used for statistical analysis as the data were numerical data about facial swelling and maximal mouth opening while paired t-test was used for non-numerical data about visual analogue scale.

## Results

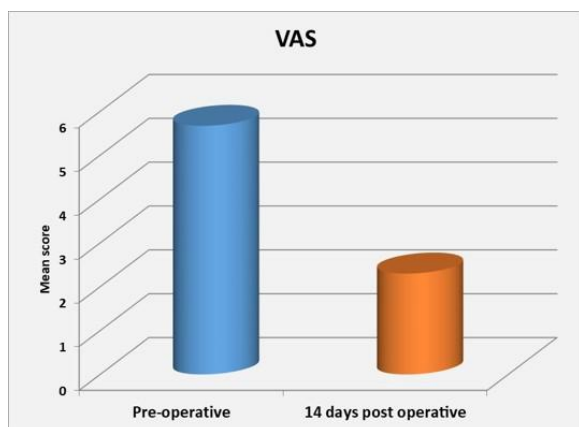
The present study included 18 cases with a mean age of  $24.5 \pm 3.4$  years. The majority of patients were females (61%). Intraoperatively, the cutting guide fit accurately in all cases without additional adjustment or further flap extension. The bony segment at the external oblique ridge was successfully harvested as one piece in all cases without fracture, offering adequate exposure of the crown to the root furcation. After odontectomy, the harvested bone was repositioned and was stable and self-retentive with no need for fixation. Uneventful primary wound healing was observed in all patients; no signs of infection, flap dehiscence or bone exposure were seen. Postoperatively, lower lip paresthesia was only encountered in three patients, probably owing to pressure during root removal. The patients were followed up until recovery which was achieved within three months.

**Table 1: VAS score pre-and post-operatively and significance of the difference using Paired t-test for Equality of Means**

VAS Time	Mean	SD	T	P value
Pre-operative	5.6667	2.30089	5.279	< 0.0001*
14 <sup>th</sup> day post-operative	2.3333	0.7199		

Significance level  $p < 0.05$ , \* significant

Regarding the pain score, the Visual Analogue Scale mean (VAS) demonstrated improvement by decreasing from  $5.67 \pm 2.33$  pre-operatively to  $2.33 \pm 0.72$  two weeks postoperatively. Paired t-test revealed a statistically significant difference at ( $p < 0.0001$ ), (Table1, Figure 4).



**Figure 4: Column chart showing mean VAS score pre-and post-operatively**

The maximum mouth opening's mean score decreased from  $3.98 \pm 0.36$  pre-operatively to  $2.27 \pm 0.11$  after three days postoperatively. However, a gradual increase to  $3.08 \pm 0.049$  till the 7th postoperative day was seen, and then finally reached  $3.93 \pm 0.034$  at 14 days postoperatively. Repeated measures analysis of variance (ANOVA) test revealed that the difference was statistically

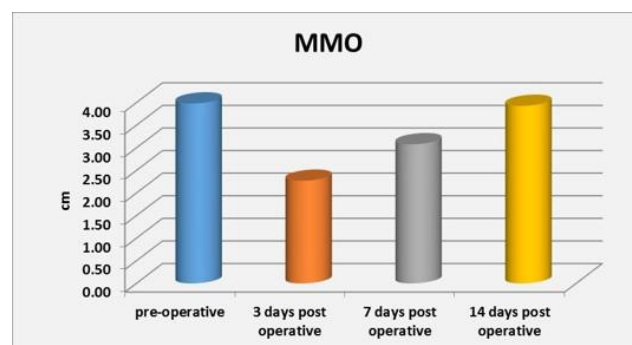
significant at ( $p < 0.0001$ ). While, Tukey's post hoc test revealed no significant difference between values recorded at 7 and 14 days postoperatively (Table 2, Figure 5).

**Table 2: MMO (cm) pre-and post-operatively and significance of the difference using repeated measures analysis of variance (ANOVA) test**

MMO	Mean	SD	P value
pre-operative	3.9833 <sup>a</sup>	.35687	
3 <sup>rd</sup> day post-operative	2.2722 <sup>b</sup>	.46628	
7 <sup>th</sup> day post-operative	3.083 <sup>c</sup>	.04938	< 0.0001*
14 <sup>th</sup> day post-operative	3.928 <sup>c</sup>	.03461	

Significance level  $p < 0.05$ , \* significant; Tukey's post hoc test: means with different superscript letters are significantly different.

Facial Swelling; the mean value increased from  $13.76 \pm 1.15$  pre-operatively to  $15.26 \pm 1.21$  after three days, but decreased to  $13.68 \pm 1.18$  after 7 days postoperatively, repeated measures analysis of variance (ANOVA) test revealed that the difference was statistically significant at ( $p < 0.0001$ ).



**Figure 5: Column chart showing mean MMO (cm) pre-and post-operatively**

However, Tukey's post hoc test revealed no significant difference between values recorded pre-operatively and at 7 days postoperatively (Table 3, Figure 6).

**Table (3) Facial swelling (cm) pre-and post-operatively and significance of the difference using repeated measures analysis of variance (ANOVA) test**

Facial swelling	Mean	SD	P value
pre-operative	13.7611 <sup>b</sup>	1.14950	
3 <sup>rd</sup> day post-operative	15.2556 <sup>a</sup>	1.20987	
7 <sup>th</sup> day post-operative	13.6778 <sup>b</sup>	1.17851	< 0.0001*

Significance level  $p < 0.05$ , \* significant; Tukey's post hoc test: means with different superscript letters are significantly different.

Reviewing the radiographic results; immediate postoperative CBCTs showed proper repositioning of the harvested bony segment (Figure 7). Six months postoperative CBCTs showed adequate cortication of the buccal plate of bone at the external oblique ridge and normal bone healing of the sockets in all cases (Figure 8A and B).

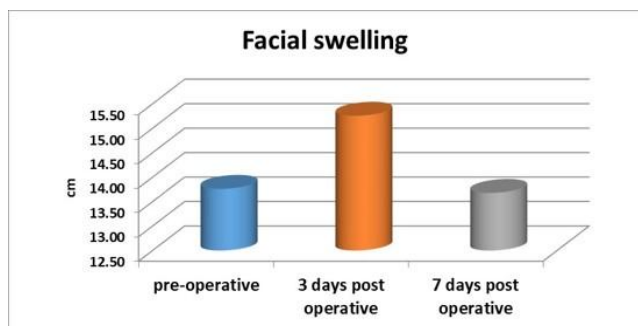


Figure 6: Column chart showing mean facial swelling (cm) pre- and post-operatively

## Discussion

Deeply impacted mandibular third molar (DIMTM) removal is surgery with difficulty ranging from excessive bone removal to the high liability of injury to IAN either directly or indirectly with subsequent hypoesthesia of the lower lip. This study was conducted to assess the novel idea of harvesting bone covering the DIMTM and the use of a CAD/CAM cutting guide in its removal, aiming at preserving the integrity of the IAN and repositioning the harvested external oblique ridge after odontectomy [28], [29], [30], [31], [32].

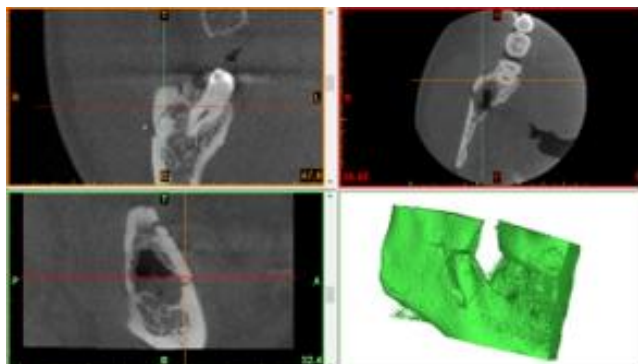


Figure 7: Immediate postoperative CBCTs radiograph

Although CBCTs were very useful in determining the spatial relation of DIMTMs to the IAN, [22] however, the introduction of the CAD/CAM cutting guide guaranteed accurate osteotomy positioning, maximum protection of the IAN and adequate exposure of the impacted tooth making this procedure a more applicable alternative for oral and maxillofacial surgeons [33].

In the present study, a CAD/CAM cutting guide was used to plan out the rectangular bony window with proper dimensions and directional orientation of the osteotomies to ensure adequate exposure of the impacted molar. This was achieved using the FRIOS Micro Saw disc, with 0.3 mm

thickness, keeping the thickness of the inferior osteotomy to a minimum. Also, the maximum cutting depth of the Micro Saw disc is 3.2 mm; this permitted monocortical bone osteotomy with preservation of the IAN integrity.

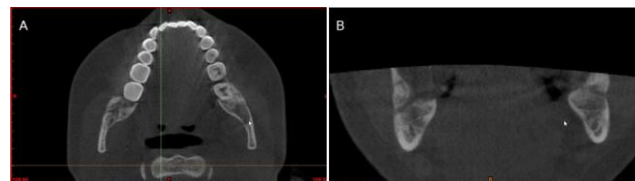


Figure 8: A), B) CBCTs; A) axial and B) coronal cuts 6 months postoperative showing normal bone healing

The thickness of the cutting guide was 2 mm. This particular thickness was chosen to ensure enough rigidity of the stent, while at the same time allowing the inferior osteotomy to be made with no interference. The orientation of the osteotomies' bevel converges lingually to allow bony segment removal as one piece and making it self-seated and retentive without any means of fixation upon its repositioning [28]. Normal bone healing was confirmed radiographically by the presence of bony trabeculae six months postoperatively which indicated graft revascularization and consolidation. This was also supported clinically by the absence of any signs and symptoms of infection or wound dehiscence [34].

Previous reports have shown that the surgical extraction of mandibular third molars is associated with considerable frequency of minor and severe complications, especially with extended operative time and deep impaction. Extended operative time, and excessive flap reflection causes a significant rise in the level of inflammatory mediators, which in return aggravate postoperative pain, facial oedema and limit mouth opening. The average operative time was reported to be around 25 minutes (range from 10 to 40 minutes). In the present study, we performed a classical flap extension to allow seating of the cutting guide which was valuable in reducing the surgical time in relation to position of the impacted molar; the new approach reduced the operative time by 20% lower than the average operative time for extraction of deeply impacted third molar tooth [2], [7], [35], [40].

The current published literature shows that the surgical extraction of impacted third molars usually leads to postoperative pain, facial swelling, and reduced mouth opening; with subsequent deterioration in health-related quality of life [41], [42]. Yuasa and Sugiura [43] reported that the occurrence of postoperative pain and swelling depend on patients age and difficulty index. In the present study, there was a significant improvement in postoperative pain; while the maximal mouth opening and facial swelling were within the normal range 14 days postoperatively. Such favourable postoperative

outcomes may be attributed to the short operative time assisted by the using of CAD/CAM cutting guides [1], [2], [7], [31], [32], [36].

In conclusion, this study proposes the joining of two new, different modalities in lower wisdom odontectomy, the first of which is the temporary harvesting of bone at the external oblique ridge, to provide access and a path of removal of the impacted tooth. The second proposition is the use of computer-guided technology in the fabrication of the surgical cutting guide, with measurements that eliminate chances of IAN injury and allows repositioning of this harvested bone without fixation. In addition to decreasing operative time, postoperative pain, facial swelling and trismus, this technique preserved the external oblique ridge's bone for future use in oral cavity augmentation. Although there was no nerve injury and good graft consolidation, which reflects the success of the technique, it is necessary to mention, however, that computer-guided surgery does not eliminate the operator dependent part for tooth exposure and odontectomy regarding the pressure exerted by the apical fragments on the nerve.

## References

- Motamedi K, Hosein M. A Textbook of Advanced Oral and Maxillofacial Surgery Complications Following Surgery of Impacted Teeth and Their Management. 2013.
- Divya T, Themozhi MS. Third molar impaction- a review. J Pharm Sci Res. 2014; 6(11):363-367.
- Juodzbaly G, Daugela P. Mandibular third molar impaction: review of literature and a proposal of a classification. J Oral Maxillofac Res. 2013; 4(2):e1. PMID:24422029 PMID:PMC3886113
- Popli G, Kiran D.N, Iyer N, Sethi S, Bansal V, Bansal A. Influence of Pederson score and its constitutional anatomical parameters to predict the postoperative morbidity after Lower Third Molar Removal: a prospective cohort study. Am J Oral Maxillofac Surg. 2014; 2(1): 7-14.
- Santosh P. Impacted mandibular third molars: Review of literature and a proposal of a combined clinical and radiological classification. Ann Med Health Sci Res. 2015; 5(4):229. <https://doi.org/10.4103/2141-9248.160177> PMID:26229709 PMID:PMC4512113
- Kim JW, Cha IH, Kim SJ, Kim MR. Which risk factors are associated with neurosensory deficits of inferior alveolar nerve after mandibular third molar extraction? J Oral Maxillofac Surg. 2012; 70(11):2508-14. <https://doi.org/10.1016/j.joms.2012.06.004> PMID:22901857
- Pippi R, Santoro M. A multivariate statistical analysis on variables affecting inferior alveolar nerve damage during third molar surgery. British dental journal. 2015; 219(4):E3. <https://doi.org/10.1038/sj.bdj.2015.661> PMID:26315197
- Blaeser BF, August MA, Donoff RB, Kaban LB, Dodson TB. Panoramic radiographic risk factors for inferior alveolar nerve injury after third molar extraction. Journal of oral and maxillofacial surgery. 2003; 61(4):417-21. <https://doi.org/10.1053/joms.2003.50088> PMID:12684956
- Umar G, Bryant C, Obisesan O, Rood JP. Correlation of the radiological predictive factors of inferior alveolar nerve injury with cone beam computed tomography findings. Oral Surg. 2010; 3(3):72-82. <https://doi.org/10.1111/j.1752-248X.2010.01088.x>
- Palma-Carrió C1, García-Mira B, Larrazabal-Morón C, Pe-arrocha-Diago M. Radiographic signs associated with inferior alveolar nerve damage following lower third molar extraction. Med Oral Patol Oral Cir Bucal. 2010; 15(6):e886- 90. PMID:20526245
- Wang WQ, Chen MY, Huang HL, Fuh LJ, Tsai MT, Hsu JT. New quantitative classification of the anatomical relationship between impacted third molars and the inferior alveolar nerve. BMC Medical Imaging. 2015; 15(1):59. <https://doi.org/10.1186/s12880-015-0101-0> PMID:26643322 PMID:PMC4672479
- Milner N and Baker A. Extra oral removal of a lower third molar tooth. Br Dent J. 2005; 199(6):345-6. <https://doi.org/10.1038/sj.bdj.4812693> PMID:16184106
- Lewis JE. Modified lingual split technique for extraction of impacted mandibular third molars. J Oral Surg. 1980; 38(8):578-83. PMID:6930459
- Smith WP. The risk of neurosensory deficit following removal of mandibular third molar teeth: the influence of radiography and surgical technique. Oral Surg Oral Med Oral Pathol Oral Radiol. 2013; 115(1):18-24. <https://doi.org/10.1016/j.oooo.2012.03.017> PMID:22921833
- Sarikov R, Juodzbaly G. Inferior alveolar nerve injury after mandibular third molar extraction: a literature review. Journal of oral & maxillofacial research. 2014; 5(4). <https://doi.org/10.5037/jomr.2014.5401> PMID:25635208 PMID:PMC4306319
- Wang Y, He D, Yang C, Wang B, Qian W. An easy way to apply orthodontic extraction for impacted lower third molar compressing to the inferior alveolar nerve. J Craniomaxillofac Surg. 2012; 40(3):234-7. <https://doi.org/10.1016/j.jcms.2011.05.001> PMID:21641229
- Dolanmaz D, Yildirim G, Isik K, Kucuk K, Ozturk A. A preferable technique for protecting the inferior alveolar nerve: coronectomy. J Oral Maxillofac Surg. 2009; 67(6):1234-8. <https://doi.org/10.1016/j.joms.2008.12.031> PMID:19446209
- Cansiz E, Isler SC, Gultekin BA. Removal of Deeply Impacted Mandibular Molars by Sagittal Split Osteotomy. Case Reports in Dentistry. 2016; 2016.
- Toffanin A, Zupi A, Cicognini A. Sagittal split osteotomy in removal of impacted third molar. J Oral Maxillofac Surg. 2003; 61(5):638-40. <https://doi.org/10.1053/joms.2003.50124> PMID:12730848
- Jones TA, Garg T, Monaghan A. Removal of a deeply impacted mandibular third molar through sagittal split ramus osteotomy approach. Br J Oral Maxillofac Surg. 2004; 42(4):365-8. <https://doi.org/10.1016/j.bjoms.2004.02.022> PMID:15225962
- Sencimen M, Varol A, Guses A. Extraction of a deeply impacted lower third molar by sagittal split osteotomy. Oral Surg Oral Med Oral Pathol Oral Radiol Endod. 2009; 108(5):e36-8. <https://doi.org/10.1016/j.tripleo.2009.07.003> PMID:19836712
- Ahmed M. Surgical removal of deeply impacted mandibular third molar with the preservation of external oblique ridge (preliminary study). Egy Dent J. 2016; 62(4):4781-4788.
- Chim H, Wetjen N, and Mardini S. Virtual Surgical Planning in Craniofacial Surgery. Semin Plast Surg. 2014; 28(3):150-8. <https://doi.org/10.1055/s-0034-1384811> PMID:25210509 PMID:PMC4154978
- Mehra P, Miner J, D'Innocenzo R, Nadershah M. Use of 3-D Stereolithographic Models in Oral and Maxillofacial Surgery. J Maxillofac Oral Surg. 2011; 10(1):6-13. <https://doi.org/10.1007/s12663-011-0183-3> PMID:22379314 PMID:PMC3177510
- Meshram VS, Meshram PV, Lambade P. Assessment of nerve injuries after surgical removal of mandibular third molar: a prospective study. Asian Journal of Neuroscience. 2013; 2013.

26. Seymour RA. The use of pain scales in assessing the efficacy of analgesics in post-operative dental pain. *Eur J Clin Pharmacol.* 1982; 23(5):441-4. <https://doi.org/10.1007/BF00605995> PMID:7151849
27. Bamgbose BO, Akinwande JA, Adeyemo WL, Ladeinde AL, Arotiba GT, Ogunlewe MO. Effects of co-administered dexamethasone and diclofenac potassium on pain, swelling and trismus following third molar surgery. *Head & Face Medicine.* 2005; 1(1):11. <https://doi.org/10.1186/1746-160X-1-11> PMID:16274480 PMID:PMC1291385
28. Masri R, Driscoll CF, editors. *Clinical applications of digital dental technology.* John Wiley & Sons; 2015. <https://doi.org/10.1002/9781119045564>
29. Hasegawa T, Ri S, Umeda M, Komori T. Multivariate relationships among risk factors and hypoesthesia of the lower lip after extraction of the mandibular third molar. *Oral Surg Oral Med Oral Pathol Oral Radiol Endod.* 2011; 111(6):e1-7. <https://doi.org/10.1016/j.tripleo.2011.02.013> PMID:21569985
30. Martin A, Perinetti G, Costantinides F, Maglione M. Coronectomy as a surgical approach to impacted mandibular third molars: a systematic review. *Head & face medicine.* 2015; 11(1):9. <https://doi.org/10.1186/s13005-015-0068-7> PMID:25890111 PMID:PMC4397866
31. Ezoddini F, Booshehri M, Azam, Ardakani F. Diagnostic accuracy of panoramic radiography in determining the position of impacted third molars in relation to the inferior dental canal compared with surgery. *Iran J Radiol.* 2010; 7(2):92-6.
32. Chuang SK, Perrott DH, Susarla SM, Dodson TB. Risk Factors for inflammatory complications following third molar surgery in adults. *J Oral Maxillofac Surg.* 2008; 66(11):2213-8. <https://doi.org/10.1016/j.joms.2008.06.067> PMID:18940482
33. Grossi GB, Maiorana C, Garramone RA, Borgonovo A, Creminelli L, Santoro F. Assessing postoperative discomfort after third molar surgery: a prospective study. *J Oral Maxillofac Surg.* 2007; 65(5):901-17. <https://doi.org/10.1016/j.joms.2005.12.046> PMID:17448840
34. Wang D, Lin T, Wang Y, Sun C, Yang L, Jiang H, Cheng J. Radiographic features of anatomic relationship between impacted third molar and inferior alveolar canal on coronal CBCT images: risk factors for nerve injury after tooth extraction. *Arch Med Sci.* 2018; 14(3):532-540. <https://doi.org/10.5114/aoms.2016.58842> PMID:29765439 PMID:PMC5949900
35. Ellis E. Rigid skeletal fixation of fractures. *J Oral Maxillofac Surg.* 1993; 51(2):163-73. [https://doi.org/10.1016/S0278-2391\(10\)80016-3](https://doi.org/10.1016/S0278-2391(10)80016-3)
36. Benediktsdottir IS, Wenzel N, Peterson JK, Hintze H. Mandibular third molar removal: Risk indicators for extended operation time, postoperative pain, and complications. *Oral Surg Oral Med Oral Pathol Oral Radiol Endod.* 2004; 97(4):438-46. <https://doi.org/10.1016/j.tripleo.2003.10.018> PMID:15088029
37. Renton T, Smeeton N, McGurk M. Factors predictive of difficulty of mandibular third molar surgery. *Br Dent J.* 2001; 190(11):607-610. <https://doi.org/10.1038/sj.bdj.4801052a>
38. Conrad SM, Blakey GH, Shugars DA, Marciani RD, Phillips C, White RP. Patients' perception of recovery after third molar surgery. *J Oral Maxillofac Surg.* 1999; 57(11):1288-1296. [https://doi.org/10.1016/S0278-2391\(99\)90861-3](https://doi.org/10.1016/S0278-2391(99)90861-3)
39. McGrath C, Comfort MB, Lo EC, Luo Y. Changes in life quality following third molar surgery—the immediate postoperative period. *British dental journal.* 2003; 194(5):265. <https://doi.org/10.1038/sj.bdj.4809930> PMID:12658303
40. Bede SY. Factors affecting the Duration of Surgical Extraction of Impacted Mandibular Third Molars. *World J Dent.* 2018; 9(1):8-12.
41. Seymour RA, Kelly PJ, Hawkesford JE. The efficacy of ketoprofen and paracetamol (acetaminophen) in postoperative pain after third molar surgery. *Br J Clin Pharmacol.* 1996; 41(6):581-585. <https://doi.org/10.1046/j.1365-2125.1996.34015.x> PMID:8799525 PMID:PMC2042618
42. Slade GD, Foy SP, Shugars DA, Phillips C, White RP. The impact of third molar symptoms, pain, and swelling on oral health-related quality of life. *J Oral Maxillofac Surg.* 2004; 62(9):1118-1124. <https://doi.org/10.1016/j.joms.2003.11.014> PMID:15346364
43. Yuasa H, Sugiura M. Clinical postoperative findings after removal of impacted mandibular third molars: Prediction of postoperative facial swelling and pain based on preoperative variables. *Br J Oral Maxillofac Surg.* 2004; 42(3):209-214. <https://doi.org/10.1016/j.bjoms.2004.02.005> PMID:15121265