

# Clinical and Morphological Aspects in Assessing the Safety of OSPL-502 with Repeated Dose Administration

Sergey A. Zhuchkov<sup>1\*</sup>, Alexandr S. Kinzirsky<sup>2</sup>, Irina V. Koroleva<sup>2</sup>, Yuriy B. Vicharev<sup>2</sup>

<sup>1</sup>Department of Histology, Cytology, and Embryology, Orel State University, Orel, Russia; <sup>2</sup>Laboratory of Pharmacology, Institute of Physiologically Active Compounds of the Russian Academy of Sciences (IPAC RAS), Moscow, Russia

## Abstract

**Citation:** Zhuchkov SA, Kinzirsky AS, Koroleva IV, Vicharev YB. Clinical and Morphological Aspects in Assessing the Safety of OSPL-502 with Repeated Dose Administration. Open Access Maced J Med Sci. 2018 Sep 25; 6(9):1581-1587. <https://doi.org/10.3889/oamjms.2018.398>

**Keywords:** OSPL-502; N,N'-substituted 3,7-diazabicyclo[3.3.1]nonanes; Subchronic toxicity; Preclinical studies; Target organs

**\*Correspondence:** Sergey A. Zhuchkov, Department of Histology, Cytology, and Embryology, Orel State University, Orel, Russia. E-mail: zhuchkov@ymservices.ru

**Received:** 11-Jul-2018; **Revised:** 05-Sep-2018; **Accepted:** 07-Sep-2018; **Online first:** 23-Sep-2018

**Copyright:** © 2018 Sergey A. Zhuchkov, Alexandr S. Kinzirsky, Irina V. Koroleva, Yuriy B. Vicharev. This is an open-access article distributed under the terms of the Creative Commons Attribution-NonCommercial 4.0 International License (CC BY-NC 4.0)

**Funding:** This research did not receive any financial support

**Competing Interests:** The authors have declared that no competing interests exist

**BACKGROUND:** OSPL-502 is a new potential medicinal drug which stimulates a cognitive function. It is necessary to reveal clinical manifestations of its general toxic effect and determine organs that are most heavily affected by this pharmacological substance.

**AIMS:** To describe and estimate clinical and histopathological changes in the organism of experimental animals in response to the repeated administration of pharmacological substance OSPL-502.

**MATERIAL AND METHODS:** The study was conducted by the OECD Guidelines (Test No. 407) on Sprague-Dawley rats. The drug was administered at the dose of 20, 60 and 180 mg/kg.

**RESULTS:** The repeated doses of OSPL-502 have not caused any toxic effects on the growth of body weight, food and water consumption of the tested animals, or affected the musculoskeletal system and exploratory behaviour of the rats in the doses of 20 and 60 mg/kg. The dose of 180 mg/kg (1800 times larger than the therapeutic dose) has shown clinical signs of toxicity in females but has not resulted in the death of the animals. Due to morphological methods, we have found histostructural changes in the liver, kidneys and adrenal glands of the rats that were treated with the test substance in the maximum dose. These changes are reversible and reduce within 14 days after the admission of the studied substances is cancelled.

**CONCLUSION:** OSPL-502 at the dose of 180 mg/kg has a weakly pronounced toxic effect, the dose of 60 mg/kg is the threshold, and that of 20 mg/kg is no-observable-adverse-effect-level (NOAEL); the liver, kidneys and adrenal glands can be considered target-organs for the tested substance.

## Introduction

According to epidemiological data, at least 50% of people over 65 years old have cognitive disorders of different intensities, and the risk of such disorders increase with age. Upward of 100 different neurological disorders are accompanied by cognitive dysfunctions which, in some cases, develop into dementia. The latest population studies demonstrate that there are about 46 million people living with dementia, with 50-70% of them diagnosed with Alzheimer's disease [1]. In 2006, there were about 15-20 million patients [2]. According to the estimates provided by the Alzheimer's Association (2016), 5.4 million Americans have Alzheimer's disease [3].

These facts make it vital to search for, synthesise and study pharmacological properties of substances which can compensate neurological deficits and possess neuroprotective properties.

It is known that glutamate receptors (AMPA and NMDA) play an important role in the formation of memory, which is one of the most important cognitive functions. The stimulation of AMPA-receptors improved the memory process [4]. Some substances that are modulators of AMPA receptors (including derivatives of N, N'-substituted 3,7-diazabicyclo[3.3.1]nonanes), which has neuroprotective and cognitive-stimulating effects [5] [6], have been discovered and studied relatively recently [7] [8].

OSPL-502 is a new derivative of N,N'-substituted 3,7-diazabicyclo[3.3.1]nonanes and is a highly active positive modulator of AMPA-receptors. It is a new potential medicinal drug from the pharmacotherapeutic group of nootropics. Since OSPL-502 should be used as a medicinal drug, it is necessary to reveal clinical manifestations of its general toxic action in case of repeated administration and determine organs and organismal systems that are most heavily affected by this pharmacological substance to estimate the safety of this potential medicinal drug.

Considering the data mentioned above, the current study aims to characterise and estimate clinical and pathological changes in the organism of experimental animals in response to the repeated administration of pharmacological substance OSPL-502.

In this regard, we planned to study clinical and morphofunctional changes of internal organs and the degree of reversibility of discovered changes after repeated oral administration of OSPL-502 to Sprague-Dawley rats of both sexes.

## Material and Methods

The study was conducted by the OECD Guidelines (Test No. 407: Repeated Dose 28-day Oral Toxicity Study in Rodents). The tested, and control substances were administered to animals on a daily basis seven days a week within 28 days, which is in strict compliance with the research protocol. The substance administration into the stomach was provided by a probe at the same time before noon. The volume of the administered drug did not exceed 10 ml/kg of the animal's weight.

The volume and concentration of the administered pharmacological substance solution were daily corrected in response to mass body gain to maintain a constant dose of the substance in necessary proportions to the body mass of a growing animal. The drug was administered at the dose of 20, 60 and 180 mg/kg, and the control animals were administered with a dispersion medium in the same volume.

We used 10 animals (five female and five male) at each dose level and control. The satellite group of ten animals (five per sex) is used in control and the top dose group for observation of reversibility, persistence, or delayed the occurrence of toxic effects, for at least 14 days post-treatment (Table 1). The necropsy was performed in 24 hours after the end of treatment for the main groups (40 animals) and 14 days later for satellite groups (20 animals).

**Table 1: Description of the study group**

Group / Dose	Male			Female		
	The numerical indexes of animals	The volume for administration (ml/kg)	The concentration of a substance (mg/ml)	The numerical indexes of animals	The volume for administration (ml/kg)	The concentration of a substance (mg/ml)
1 / control	11-20	1.6	-	11-20	2.8	-
2 / 20 mg/kg	21-25	1.6	12.4	21-25	2.8	7.7
3 / 60 mg/kg	31-35	1.6	37.9	31-35	2.8	22.3
4 / 180 mg/kg	41-50	1.6	109.4	41-50	2.8	64.4

To conduct this research, we used *animal species Rattus spp.* (Sprague-Dawley rats: males and females which have never given birth or been pregnant) at the age of five weeks, (101 ± 2 gramme of body weight in female, 139 ± 2 gramme of body weight in male) received from a licensed source which has a valid AAALAC accreditation (Research and Production Enterprise "Laboratory animals farm", Branch of the Institute of Bio-Organic Chemistry, the Russian Academy of Science, Moscow Region, Pushchino). Before the experiment, the animals were quarantined in cages for five days to adapt to group housing conditions. The care and keeping of the rats and all procedures with them were done in a vivarium of IPAC RAS (Institute of Physiologically Active Compounds of the Russian Academy of Science) strictly following the current ethical norms and regulations according to the research protocol and regulatory documents [9] [10] [11].

The animals were housed in groups of three in ventilated microisolator units One Cage 2100 (Lab. Products Inc., the USA) on the flooring LIGNOCEL Rinofix MK 2000 (JRS, Germany). In the animal housing rooms, we used the "day-night" lighting regime (12-hour cycle) and controlled the environment (temperature 18-25°C; relative humidity 30-70%).

We fed the animals with standard sterile granulated compound feeding stuff for SPF animals entitled "Chara" (OOO "MultiTorg", Russia) which was balanced in nutrients and vitamins, and autoclaved at 121°C. The control over the autoclave functioning in feeding stuff sterilisation was performed using dipsticks in every cycle of autoclaving. The rats were given autoclaved water for drinking which had undergone additional purification against excessive salt and ferrous ions. The food and water were given to the rats without any restrictions.

Throughout the research, we were registering clinical signs of intoxication, body mass and food consumption. At the same time, we were recording effects of the tested substance on locomotor activity, muscle strength, and orienting behaviour through special physiological tests. We also carried out the ophthalmological examination.

OSPL-502 is a derivative of N,N'-substituted 3,7-diazabicyclo[3.3.1] nonanes (3,7-bis (1,3-benzodioxol-5-carbonyl)-1,5-dimethyl-3,7-diazabicyclo [3.3.1]nonane-9-OH) and is a highly active positive modulator of AMPA-receptors which synthesis in IPAC RAS and has neuroprotective and cognitive-stimulating effects [5] [6] [12] (Figure1). The

pharmacological substance is crystals of white colour which are insoluble in water but well soluble in organic solvents. The substance purity is > 95%.

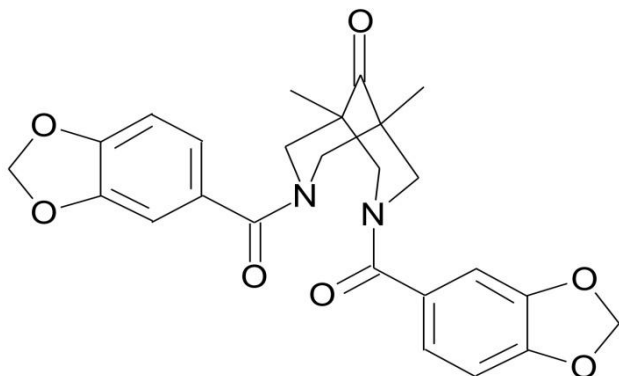


Figure 1: The structural formula of the OSPL-502

Doses were prepared by a provisor on a daily basis just before the administration. The administration solutions were the tested substance suspended in a dispersion medium of 1% starch gel with distilled water. The dose calculation, as well as the regime and duration of the drug administration, were done according to the current regulating documents [13] [14] [15] [16] [17] and results of the previous research [18].

In 24 hours after the final administration of the substance (main groups of animals) and 14 days of the recovery period (satellite groups of animals), the animals underwent CO<sub>2</sub>-euthanasia with the following exsanguinating using blood draw from the inferior vena cava. Then we provided the complete examination of external conditions of a body and internal organs. During the necropsy, all changes in organs and tissues were registered. Also, brains, thyroid glands, hearts, lungs, thymus, spleens, livers, kidneys, bladders, stomachs, duodenum, colons, adrenal glands and gonads were taken for histological tests from each animal.

The biomaterial for the pathomorphological study was kept in 10% neutral formalin (pH 7.4). Processing, embedding, microtomy, and staining of specimens was done according to standard techniques [19] [20] with some alterations. The organ slices were put into standard marked cassettes for further procedures.

The processing of samples with an embedding medium was carried out using an automatic tissue processor Leica ASP 200S (Leica, Germany). After the preparation tissue samples were embedded into paraffin wax using tissue embedding system Leica EG1160 and then each block was cut by motorised rotary microtome Leica RM 2265 with microtome blades A35 (Feather, Japan). The produced standard cross sections five microns thick were placed on slides of common thickness (Menzel-Glazer, Germany) and stained by haematoxylin and

eosin. Staining of all the samples was simultaneously provided by multicoloured stainer Leica ST5020 Multistainer in automatic mode. The stained samples were covered by standard coverslips.

The further morphological analysis of the slides was provided using light microscopes Leica CME (Leica, Germany) and Micros MC100 (XP 5MP) (Micros, Austria). Concurrently, we used computer image analysis program Microvisible (Image Analyzing Software v. 1.11.10) together with Freeware Image Tool (the USA, University of Texas) calibrated by a stage micrometre for transmitted light OMP with spacing between tick marks equal to 0.005mm.

The study was carried out by the Directive 2010/63/EU of the European Parliament and Council (2010) on the protection of animals used for scientific purposes [21] and with The Guide for the Care and Use of Laboratory Animals [10] [11]. The research protocol was approved by the Ethics Committee of IPAC RAS on August 15, 2012 (Protocol No. 8).

Group arithmetic means (M) and standard deviation (SD) were calculated for quantitative data. The statistical analysis was performed with program Statistic Base for Windows on Russian version 6.4. Male and female rates were tested independently. Differences were detected when a significant point was  $p < 0.05$ , tendencies were found when a significant point was  $p < 0.1$  using the Student's t-test for independent samples and the Mann-Whitney nonparametric test.

## Results

Throughout the research, the survival rate of the animals was 100% which proves the accuracy of the chosen dose regimes. The general state of health of the animals receiving the tested substance was also satisfactory. Intoxication manifestations differed depending on the animal's sex.

The retardation in mass body gain could be seen in female rats when the maximum dose of the tested substance was administered starting from the seventh day of the experiment. This retardation (averagely by 7%) remained within the whole period of the pharmacological substance administration.

In 14 days after the substance administration, the mass body gain of all experimental groups receiving the maximum dose did not differ from that of the control group (Figures 2 and 3). The tested substance given in three different doses did not cause any significant effect on the animals' feed and water consumption.

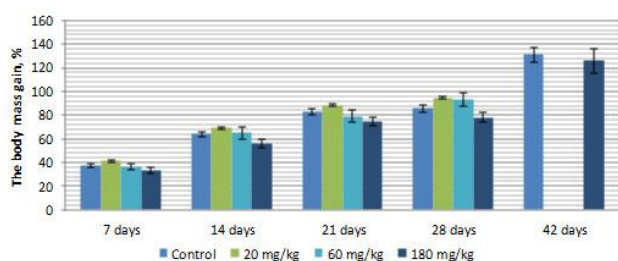


Figure 2: The mass body gain in the female rats during the experiment ( $n = 5$ )

We have found no locomotive system disturbances. The female rats administered the tested substance at the dose of 60 mg/kg were able to hang on the cage with increased strength. After the 28-day period of the drug administration, the orienting behaviour of both male and female rats in experimental groups was not different from the orienting behaviour of rats in the control group.

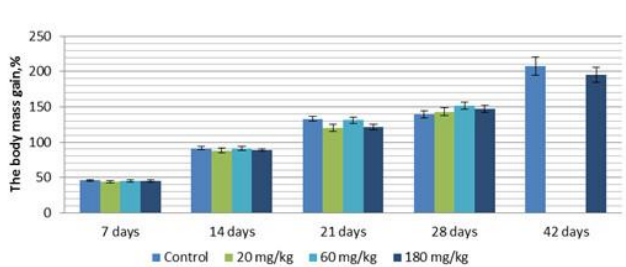


Figure 3: The mass body gain in the male rats during the experiment ( $n = 5$ )

The ophthalmological examination showed no exophthalmos, sclera reddening, corneal and lens opacity or any other changes in the retina. The pupillary light reflex retained.

In two weeks after the withdrawal of the pharmacological substance OSPL-502, no clinical signs of intoxication were found that can indicate the absence of cumulative properties in the tested pharmacological substance.

The animals' necropsy showed no haemorrhages, visible pathological changes of internal organs, etc. The microstructure of the brain, heart, thymus, spleen, lungs, thyroid glands and bladder also corresponded to the norms. We have revealed no pathological changes in these organs related to the toxic influence of the substance.

There were no macroscopic signs of mucous degeneration, ulcerations and necrosis in the stomach (where the substance was administrated to) of the animals receiving pharmacological substance OSPL-502 at the doses of 20, 60 and 180 mg/kg. The histologic structure of a stomach wall of the animals in the control group and the animals receiving pharmacological substance OSPL-502 at the doses 20, 60 and 180 mg/kg intragastrically corresponds to the norm, i.e. all four envelopes of the alimentary duct

(mucous, submucous, muscular and serous) have a typical structure with no signs of degeneration or necrosis. Also, no ulcerogenic effect was detected as a result of the drug administration. The data mentioned above indicates the absence of the toxic influence on stomach walls during the 28-day administration of the tested substance. The structure of the duodenum wall showed no pathological changes caused by the drug influence. This organ had a typical structure with four envelopes, including the mucous, submucous, muscular and serous. We have also found no signs of epithelium necrosis.

Duodenal glands had a typical structure. The insignificant plethora of microcirculatory vessels was detected. The colons of both male and female rats receiving the intragastrical administration of the tested substance at the doses of 20, 60 and 180 mg/kg had a typical structure and were not different from the structure of the colon of the rats in the control group. No signs of degeneration or necrosis were found. Inflammatory changes were absent. Therefore, OSPL-502 at the tested doses produces no effect on walls of the digestive tract of the tested rats.

The list structure of adrenal glands samples of the intact animals and the animals receiving OSPL-502 was unharmed. In the studied samples, the cortex was distinguished from the medulla, the border between them was clear, but the latter was not always visible in all the cross-sections. There were cells with hydropic degeneration (from a small number of cells to moderate) in the upper third of the zona fasciculata of the suprarenal cortex of all the animals. Nearly all cross-sections demonstrated cell clusters with small oval nuclei and oxyphilic cytoplasm. We have noted the moderate defatting of suprarenal cortex cells cytoplasm. The cells deprived of lipids were clustered in the form of triangular cords which started from the region where the zona glomerulosa bordered the zona fasciculata and then went down to the reticular zone. The zona reticularis and medulla were largely vascularized. The noted changes were reversible and reduced in 14 days after the substance was withdrawn. The histostructure of the adrenal glands of the animals receiving OSPL-502 at the doses of 20 and 60 mg/kg was not much different from that of the animals in the control group. The histostructure of adrenal glands of the female rats receiving OSPL-502 at the dose of 180 mg/kg had more acute changes in comparison to the rats in the control group. The cells with signs of hydropic degeneration were located diffusely and mainly in the upper third of the zona fasciculata (Figure 4).

The morphological examination of the liver and kidneys has shown some morphofunctional changes.

The histologic structure of the liver in the rats receiving OSPL-502 at the doses of 20 and 60 mg/kg was not different from that of the intact rats, i.e. the structure of the lobules with radially arranged plates of

hepatocytes was visible with no signs of fibrosis, infiltrates, etc. Hepatocytes were of a regular size and shape. However, there were single cells with signs of degeneration of different degrees (to the extent of hydropic). The hepatocytes nuclei were normochromic without pathological changes.

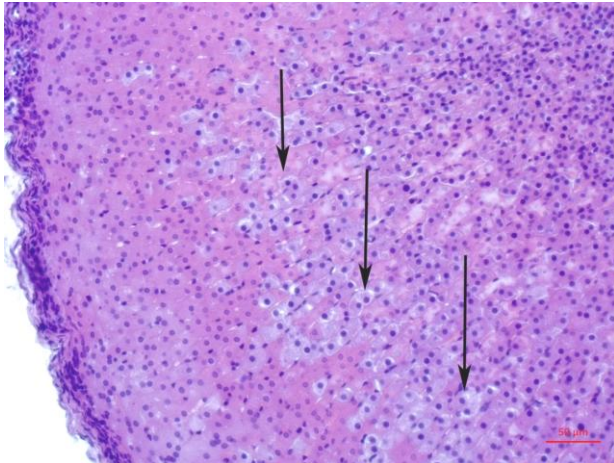


Figure 4: A fragment of the rat's adrenal glands administered with 180mg/kg body weight of OSPL-502. Staining with hematoxylin and eosin. Magnification x200 showing the cells deprived of lipids and the cells with hydropic degeneration (with points)

The intralobular sinusoids were without changes; other vascular system components were also in the same conditions. The female rats receiving OSPL-502 at the dose of 180 mg/kg intragastrically had an increased number of degenerated hepatocytes in comparison to the control group. There were signs of regeneration processes activation which manifested itself by an increased number of immature hepatocytes radially moving down along the lobules in periportal areas and the region of terminal plates. We should note that these changes were reversible and were not found in the animals in after the 14-day substance administration withdrawal, or if the dose of the administered substance was 20 and 60 mg/kg (Figure 5).

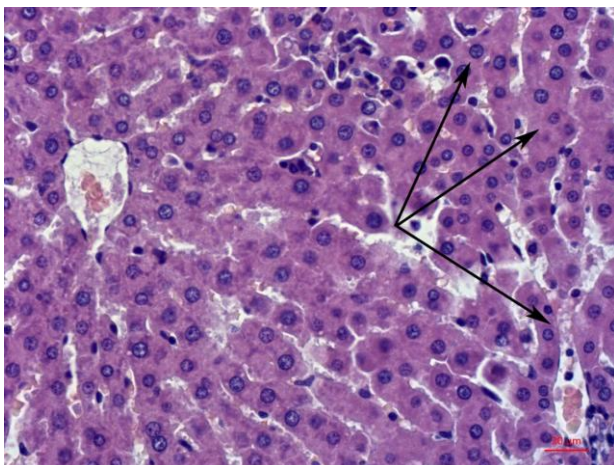


Figure 5: A fragment of the rat's liver administered with 180mg/kg body weight of OSPL-502. Staining with hematoxylin and eosin. Magnification x400. Showing the immature hepatocytes (with points)

The rats from intact groups and the rats receiving the substance at the doses of 20 and 60 mg/kg had no differences in the histostructure of their kidneys. The kidney parenchyma had a typical structure; renal corpuscles were slightly increased, though, their histological structure was without any changes. Glomerular capillaries were filled with blood, the capsule of glomerulus was without changes. There were single shrunken and obsolete glomerulus (one or two in a cross-section).

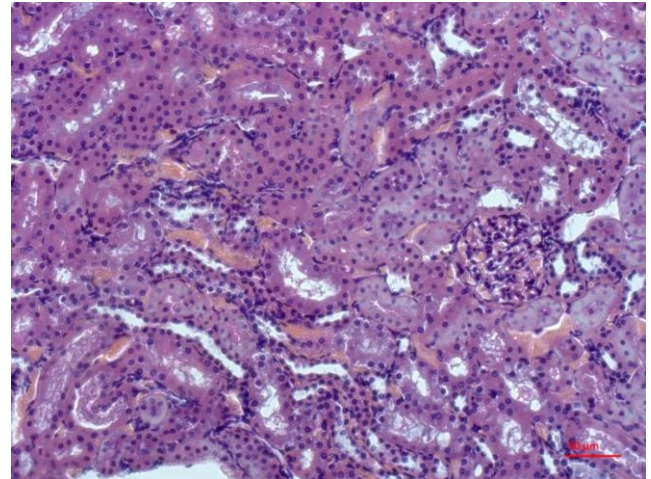


Figure 6: A fragment of the rat's kidney administered with 180mg/kg body weight of OSPL-502. Staining with hematoxylin and eosin. Magnification x200. Showing the tubules with albuminous and hydropic degeneration

Nephron tubules remained unchanged, though, there were single tubules with signs of hydropic degeneration, especially in the subcapsular area. The medullary substance of kidneys was without changes. The female rats receiving OSPL-502 at the dose of 180mg/kg intragastrically had most of their renal corpuscles unchanged, their glomerular capillaries were filled with blood, and the glomerular capsule was without changes (Figure 6 and 7).

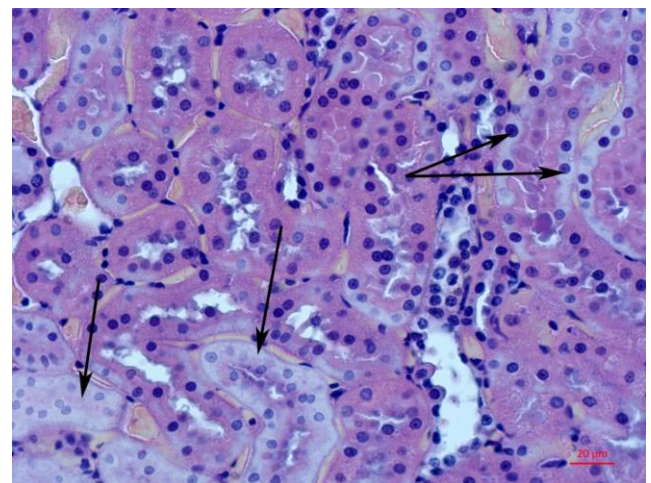


Figure 7: A fragment of the rat's kidney administered with 180 mg/kg body weight of OSPL-502. Staining with hematoxylin and eosin. Magnification x400. Showing the tubules with albuminous degeneration (with points)

In half of the cases, there were tubules with albuminous and hydropic degeneration in cortical and medullary substances with some desquamation of tubules epithelium. There was no swelling of the interstitium. Within 14 days after the withdrawal of the substance administration the kidney structure of the animals in experimental groups was the same as that in the control group.

## Discussion

The results of the undertaken study indicate mild morphofunctional changes in the liver and kidneys of the female rats receiving OSPL-502 at the dose of 180 mg/kg, which exceeds the therapeutic dose by 1800 times. The liver had signs of regeneration processes activation which manifested itself in the increase of immature hepatocytes radially moving down along the lobules in periportal areas and the region of terminal plates. Their kidneys had single tubules with albuminous and hydropic degeneration in cortical and medullary substances. It is necessary to denote that these changes were reversible and could not be found in the animals after the 14-day substance administration withdrawal of the dose of 20 and 60 mg/kg. Therefore, the noted changes are reversible which corresponds to the known data [22]. Histostructural changes in adrenal glands of the rats receiving a maximum dose (the moderate defatting of cytoplasm of suprarenal cortex cells, mild degenerative processes) can either indicate that the pharmacological substance has a very weak toxic effect, or be a response to the stress caused by the long-time intragastric administration of the tested substance. We should note that morphofunctional changes are expressed mildly; they are not widespread and appear in both control and experimental groups. The changes mentioned above seem to be a result of tension as a response to the long-time external influence accompanied by stress which can lead to a decrease in cortisol level and signs of suprarenal cortex insufficiency [23] [24]. The noted changes are reversible and reduce within 14 days after the substance administration is withdrawn. The research results are comparable with another study [18] and literature data about the toxicity of N, N'- substituted 3,7-azabicyclo[3.3.1]nonanes [5] [6] [7].

We can conclude that the repeated doses of OSPL-502 have not shown any toxic effects on the growth of body weight, food and water consumption of the tested animals or affected the musculoskeletal system and exploratory behaviour of the rats in doses of 20 and 60 mg/kg. The dose of 180 mg/kg (1800 times larger than the therapeutic dose) resulted in only clinical signs of toxicity in the female rats but did not cause the animals' death. We have only found

histostructural changes using morphological methods in the liver, kidneys and adrenal glands of the rats treated to the test substance in the maximum dose. These changes are reversible and reduce within 14 days after the cancellation of the studied substances. Therefore, our studies have revealed that the target organs for the test substances are the liver, kidneys and adrenal glands.

The identified changes are reversible after the withdrawal of the substance; OSPL-502 at the dose of 180 mg/kg has a weak toxic effect, the dose of 60 mg/kg is the threshold, and 20 mg/kg is no-observable-adverse-effect-level (NOAEL).

In conclusion, the female rats are more sensitive to the tested substance than the male ones when it comes to the repeated oral administration of the substance, but this gender difference is evident only in case of the maximum tested dose of 180 mg/kg. Considering the obtained data, the liver, kidneys and adrenal glands can be regarded as target-organs for the tested substance. The dose of 20 mg/kg exceeding the therapeutic dose by 200 times is non-toxic (NOAEL-No-Observable-Adverse-Effect-Level). Morphofunctional changes in the liver, kidneys and adrenal glands are reversible and reduce within 14 days after the substance withdrawal.

## References

1. Yauzina NA, Komleva YuK, Salmina AB, Petrova MM, Morozova GA, Malinovskaya NA. Epidemiology of Alzheimer's disease in the world. *Neurological Journal*. 2012; 5:32–37.
2. Zakharov VV. Cognitive dysfunction as a medical and social problem. *Doktor Ru*. 2006; 5:19–23.
3. Gaugler J, James B, Johnson T, Scholz K, Weuve J. Alzheimer's disease facts and figures. *Alzheimer's and Dementia*. 2016; 12(4):459–509. <https://doi.org/10.1016/j.jalz.2016.03.001>
4. Staubli U, Rogers G, Lynch G. Related Articles, Facilitation of glutamate receptors enhances memory. *Proc Natl Acad Sci U S A* 1994; 91(2): 777–781. <https://doi.org/10.1073/pnas.91.2.777> PMID:8290599 PMCID:PMC43032
5. Bachurin SO, Grigor'ev VV, Zefirov NS, Lavrov MI, Lapteva VL, Paljulin VA. N,N'-substituted 3,7-diazabicyclo[3,3,1] nonanes with pharmacological effect, pharmacological compositions on their base, and application method. Patent of invention RU No. 2333211 C1. Effective date for property rights: 01.11.2006. Also published as CN101589042(A), EP 2088149 A1, WO 2008054252 (A1), JP2010508343 (A), 2006.
6. Anokhin KV, Bachurin SO, Grigor'ev VV, Zefirov NS, Komisarova NV, Lavrov MI, Paljulin VA, Tiunova AA. N, N' - substituted 3, 7-diazabicyclo[3,3,1]nonane drug for memory regeneration In health and disease in patients of all age groups, based pharmaceutical, composition and method of application thereof. Patent of invention RU. No. 2417082 C2; 2009.
8. Raevskii KS, Eremin KO. Allosteric modulators of AMPA type glutamate receptors a novel subclass of physiologically active substances. *Biomed Khim*. 2004; 50(6):523–538. PMID:15707268
9. Zapadnyuk IP, Zapadnyuk VI, Zakhariya EA, Zapadnyuk BV. *Laboratornye zhivotnye. Razvedenie, soderzhanie, ispol'zovanie v eksperimente* [Laboratory animals. Breeding, maintenance, use in

- the experiment]. K: Vishcha shkola, 1974:383.
10. National Research Council; Division on Earth and Life Studies; Commission on Life Sciences; Institute for Laboratory Animal Research. Guide for the Care and Use of Laboratory Animals. National Academy Press, Washington, D.C., 1996.
  11. National Research Council. Guide for the care and use of laboratory animals. National Academies Press, 2010.
  12. Lavrov M, Lapteva V, Bachurin S, Palyulin V, Grigoriev V, Zefirov N. New picomolar ampa receptor modulators: design, synthesis and studies. *frontiers in medicinal chemistry: emerging targets, novel candidates and innovative strategies. Drugs of the future, Suppl A.* 2009; 34:4–6.
  13. Gus'kova TA. Toxicology of drugs. Moscow: Russian doctor, 2003.
  14. Jonsson M, Atosuo J, Jestoi M, Nathanail AV, Kokkonen UM, Anttila M, Koivisto P, Lilius EM, Peltonen K. Repeated dose 28-day oral toxicity study of moniliformin in rats. *Toxicology letters.* 2015; 233(1):38-44. <https://doi.org/10.1016/j.toxlet.2014.11.006> PMID:25482064
  15. Mironov AN. (Ed.) The guidelines for preclinical studies of pharmaceuticals. Part I. Moscow: Grif & K, 2012.
  16. Habriyev RU. (Ed.) The guidelines for experimental (preclinical) study of new pharmacological substances. Moscow: Medicine, 2005.
  17. Organisation for Economic Co-operation and Development. Test No. 407: Repeated Dose 28-day Oral Toxicity Study in Rodents. OECD Publishing, 2008.
  18. Zhuchkov SA, Kinzirskiy AS, Bachurin SO, Snimshikova IA. The study of parameters of acute toxicity of new drug OSPL-502. *Russian journal of Immunology.* 2013; 7(16):197.
  19. Merkulov GA. Course of pathohistological techniques. Leningrad: Medicine, 1969.
  20. Korzhevski DE, Gilyarov AV. Basics of histological technique. SPb: Speclit, 2010.
  21. Directive 2010/63/EU of the European Parliament and of the Council of 22 September 2010 on the protection of animals used for scientific purposes. European Parliament, Council of the European Union, 2010.
  22. Haschek WM, Rousseaux CG, Wallig MA. (Eds.). *Fundamentals of Toxicologic Pathology.* Elsevier Science. Academic Press, 2009.
  23. Ivanova IK, Lonshakova KS, Shantanova LN. The influence of immobilization stress on histological structure of white rats' adrenal. *Bulletin ESSC SB RAMS.* 2009; 2:258–260.
  24. Solodkova OA, Zenkina VG, Karedina VS. Effect's extract of cucumaria japonica on structure adrenal glands white rats at cold stress. *Fundamental research.* 2012; 8(Pt2):419–423.